بسم الله الرحمـٰن الرحيم

(وَفَوْقَ كُلِّ ذِي عِلْمٍ عَلِيمٌ)

CVS Physiology | MID 5

ECG pt.2



Written & Reviewed by : Shorouq Matalkah

Electrocardiography – Normal 1

Faisal I. Mohammed, MD, PhD

Objectives

1. Describe the different “waves” in a normal electrocardiogram.
2. Recall the normal P-R and Q-T interval time of the QRS wave.
3. Distinguish the difference in depolarization and repolarization waves.
4. Recognize the voltage and time calibration of an electrocardiogram chart.
5. Point out the arrangement of electrodes in the bipolar limb leads, chest leads, and unipolar leads.
6. Describe Einthoven’s law.

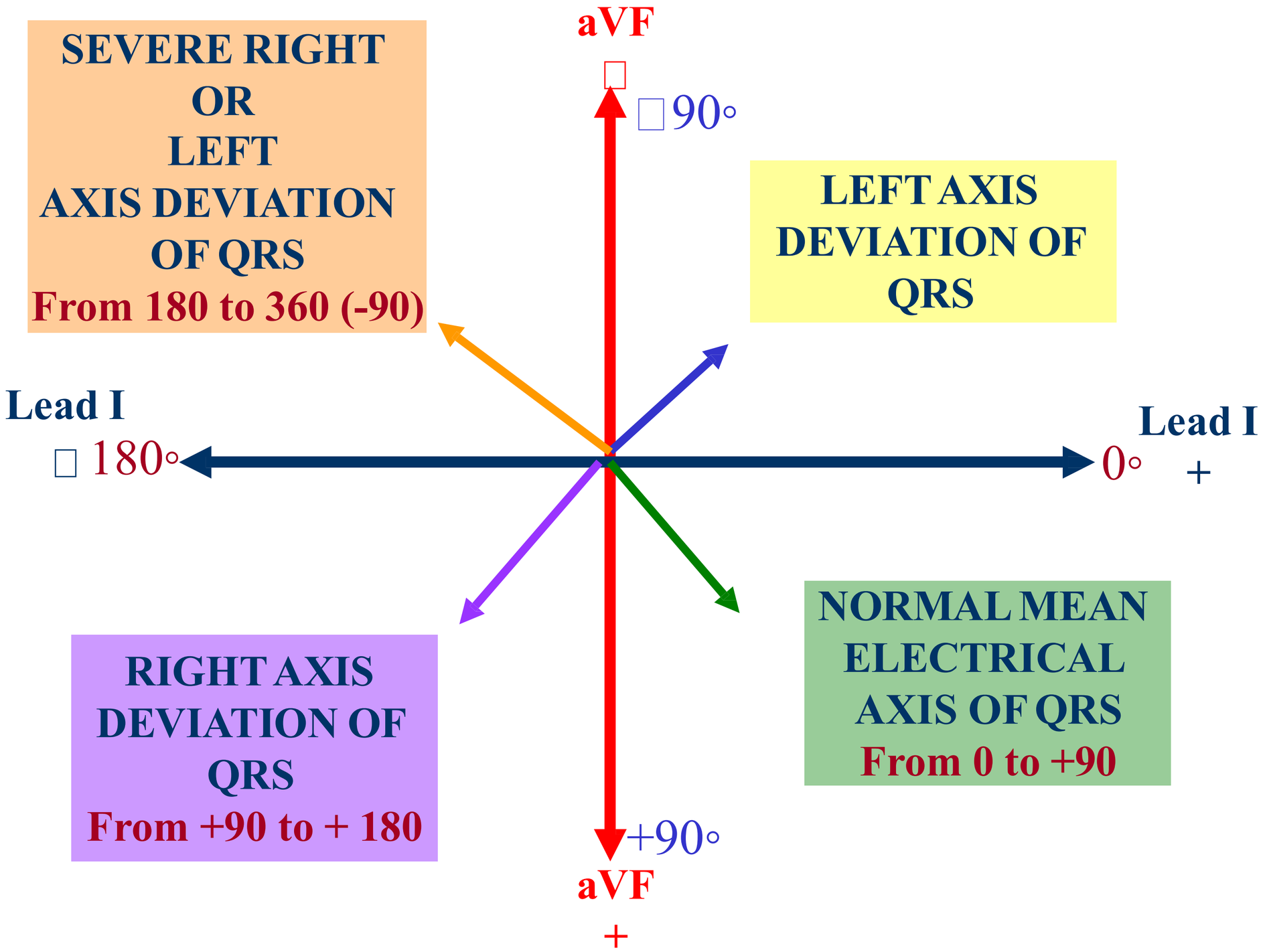
SEVERE RIGHT
OR
LEFT
AXIS DEVIATION
OF QRS
From 180 to 360 (-90)
aVF
□
□90◦
LEFT AXIS
DEVIATION OF
QRS
Lead I
□ 180◦
Lead I
0◦
+
NORMAL MEAN
ELECTRICAL
AXIS OF QRS
From 0 to +90
RIGHT AXIS
DEVIATION OF
QRS
From +90 to + 180
+90◦
aVF
+

Determining the Mean QRS (Cardiac) Axis

1. Case Example

· **Given ECG Measurements (Net QRS Amplitude):**

· **Lead I:** +10 { mm} (strongly positive)

· **Lead aVF:** +2 { mm} (slightly positive)

· **Interpretation:**

· Because Lead I (0) has a much larger positive deflection than Lead aVF (+90), the mean electrical vector points predominantly toward Lead I, sitting at an angle of approximately +10 **to** +11.

· **Clinical Conclusion: Normal Cardiac Axis** (no axis deviation). A normal QRS axis lies between −30 **and** +90.

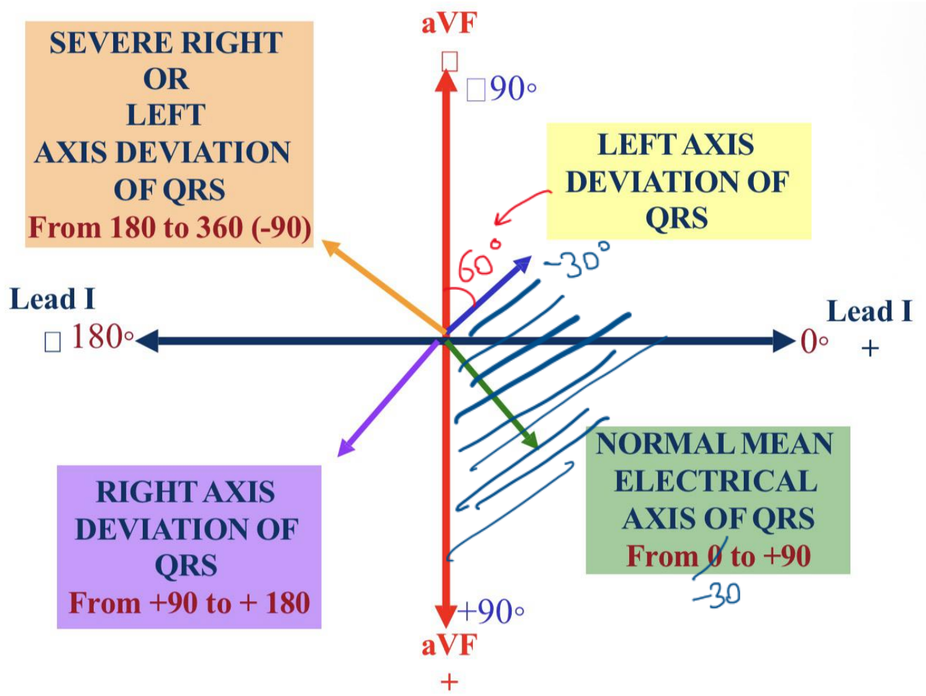

2. Three Methods to Determine the Cardiac Axis

Method 1: The Quadrant Method (Visual Inspection of Leads I & aVF)

Lead I represents the horizontal axis (O^\circ), and Lead aVF represents the vertical axis (+90). Together, they divide the hexaxial reference system into four quadrants:

Lead I	Lead aVF	Quadrant Location	Axis Interpretation
Positive (+)	**Positive (+)**	Lower-Left ($0°$ to $+90°$)	**Normal Axis**
Positive (+)	**Negative (–)**	Upper-Left ($0°$ to $-90°$)	**Physiologic Left ($0°$ to $-30°$)** or **Left Axis Deviation ($-30°$ to $-90°$)** *(requires checking Lead II)*
Negative (–)	**Positive (+)**	Lower-Right ($+90°$ to $+180°$)	**Right Axis Deviation (RAD)**
Negative (–)	**Negative (–)**	Upper-Right ($-90°$ to $\pm 180°$)	**Extreme Axis Deviation** ("Northwest" Axis)

Method 2: The Tangent (Trigonometric) Method

For an exact angle calculation, treat Lead I (x-axis) and Lead aVF (y-axis) as perpendicular components of the cardiac vector:

$$\tan(\theta) = \frac{\text{Net QRS in aVF}}{\text{Net QRS in Lead I}}$$

$$\theta = \arctan\left(\frac{\text{aVF}}{\text{Lead I}}\right)$$

· **Applying the Lecture's Numbers:**

$$\theta = \arctan\left(\frac{+2}{+10}\right) = \arctan(0.2) \approx +11.3^\circ \text{ (roughly } 10^\circ)$$

Method 3: The Perpendicular Lead Method (Using Lead aVL and Lead II)

When Lead I is positive and Lead aVF is negative (0 to -90), you must distinguish between a **normal axis** (0 **to** -30) and **Left Axis Deviation** (-30 **to** -90) by checking the boundary line at -30:

1. **Identify the** -30^\circ **Lead: Lead aVL** is oriented at -30.

2. **Find the Lead Perpendicular to aVL:** A line perpendicular (90 away) to -30 runs along +60 **and** -120, which corresponds to **Lead II** (+60)

3. **Evaluate Lead II:**
· **Lead II is Positive (+):** The cardiac vector is on the positive side of the perpendicular line (closer to +60, meaning the angle is between -30 **and** +90) \rightarrow **Normal Axis**.
· **Lead II is Isoelectric (Equiphasic,** *R* *approx S***):** The vector is perpendicular to Lead II \rightarrow Axis is exactly -30 (borderline normal).
· **Lead II is Negative (-):** The vector is pointing away from +60 (more negative than -30) \rightarrow **Left Axis Deviation (LAD)**.

Determining Mean Electrical Axis

- Use 2 different leads
- Measure the sum of the height and the negative depth of the QRS complex
- Measure that vaule in mm onto the axis of the lead and draw perpendicular lines
- The intersection is at the angle of the mean axis.

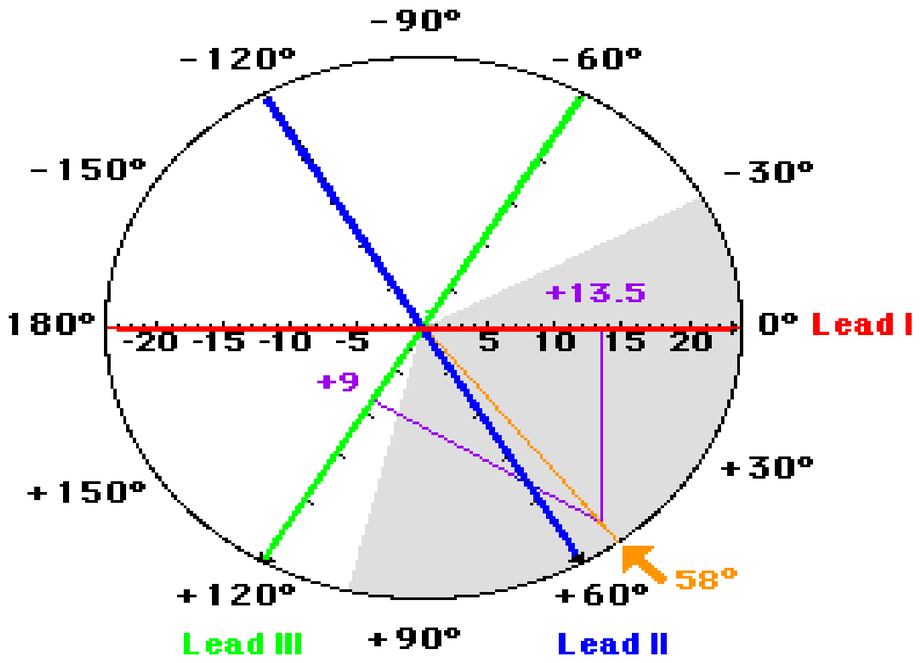

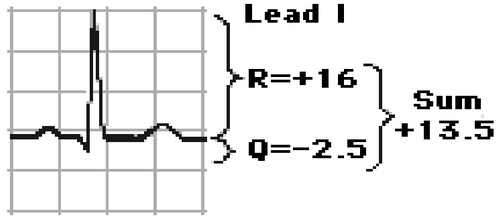

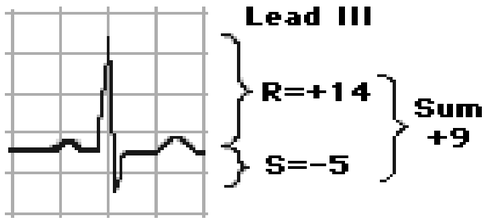

- To plot the cardiac vector on the hexaxial reference system, first calculate the **net QRS deflection** (sum of positive and negative waves) for two limb leads—here, **Lead I** and **Lead III**:
- **Lead I (0 axis):**
- **R wave (upward/positive deflection):** +16 { mm} *(Note: the doctor casually rounded this to* \sim 15 – 1*, while the slide shows the exact values)*
- **Q wave (downward/negative deflection):** -2.5 { mm}
- **Net Sum:** +16 + (-2.5) = +13.5 { mm}
- **Lead III (+120^\circ axis):**
- **R wave (upward/positive deflection):** +14 { mm}
- **S wave (downward/negative deflection):** -5 { mm}
- **Net Sum:** +14 + (-5) = +9 { mm}

Result & Clinical Interpretation
· **Measured Mean Electrical Axis:** ≈ +58^ (falling right inside the shaded normal zone on the diagram).
· **Clinical Conclusion: Normal Cardiac Axis** (no axis deviation, as +58 sits comfortably within the normal range of -30 **to** +90).

Plot Lead I (+13.5**):**
• Locate the horizontal Lead I axis (0 to 180).
• Move 13.5 **units** toward the positive pole (0) and draw a **perpendicular line** (90 vertical line) passing through that point.
2. **Plot Lead III (**+9**):**
• Locate the Lead III axis (+120 positive pole to -60 negative pole).
• Move 9 **units** along the positive pole toward +120 and draw a **perpendicular line** to the Lead III axis passing through that point.
3. **Find the Intersection (Resultant Vector):**
• Draw an arrow starting from the center origin (0,0) to the exact point where the two perpendicular lines intersect.

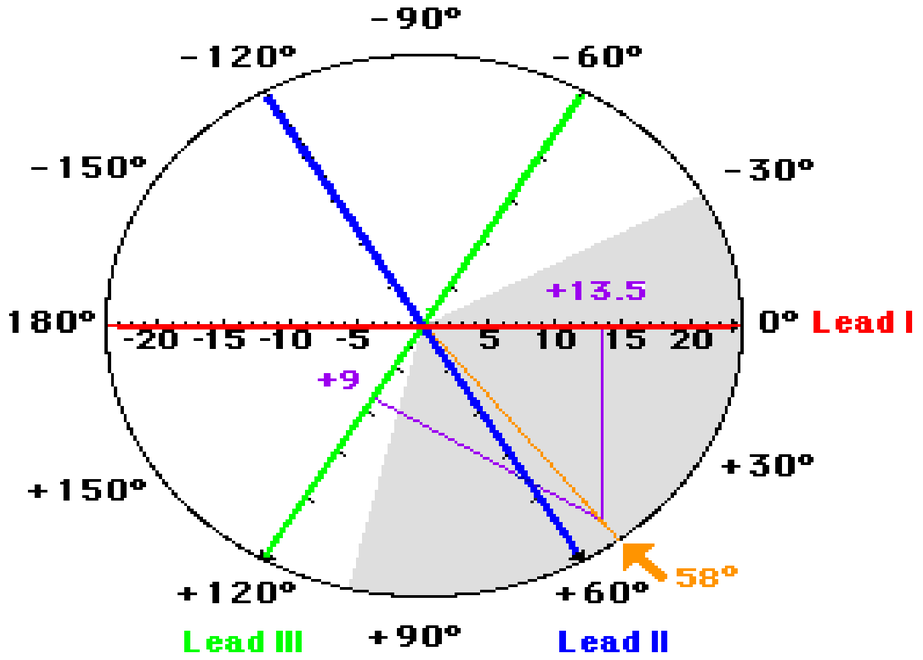

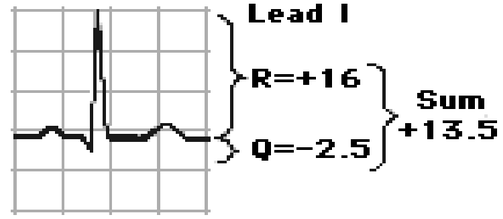

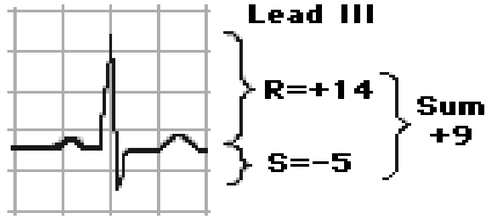

Uniplolar Leads

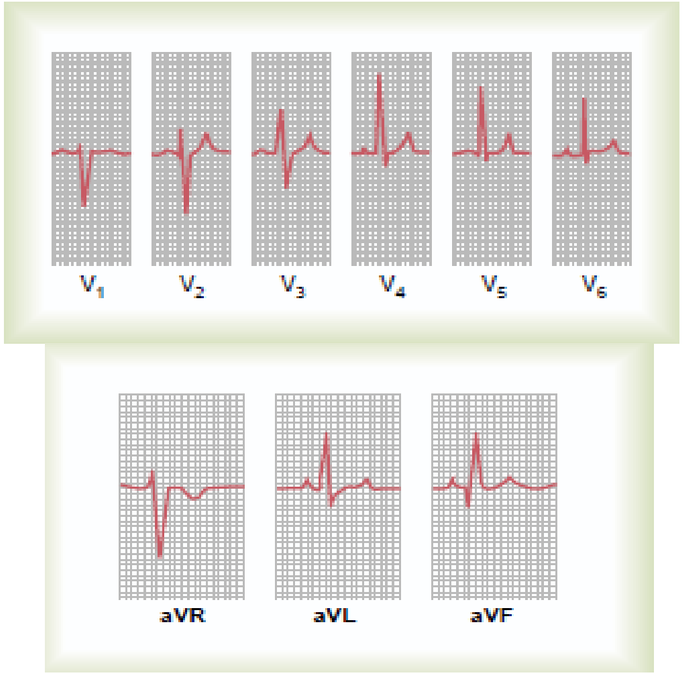

· **Lead aVR (-150 axis):** -11 { mm} *(predominantly negative/downward deflection)*
· **Lead aVL (-30 axis):** +9 { mm} *(predominantly positive/upward deflection)*
· **Lead aVF (+90 axis):** +6 { mm} *(predominantly positive/upward deflection)*

Plot Lead aVR (-11):
· Locate the Lead aVR axis (positive pole at -150, negative pole at +30).
· Because the value is **negative** (-11), move 11 **units away from** -150—directly toward the +30 pole—and draw a perpendicular line.
2. **Plot Lead aVL (+9) & Lead aVF (+6):**
· Move 9 **units** toward the positive pole of aVL (-30) and draw a perpendicular line.
· Move 6 **units** toward the positive pole of aVF (+90) and draw a perpendicular line.
3. **Resultant Vector:**
· All three perpendicular lines intersect along the +30 ray.

Clinical Interpretation
· **Calculated Mean Electrical Axis:** ≈ +30
· **Clinical Conclusion: Normal Cardiac Axis** (falls squarely inside the normal range of -30 **to** +90).

Quick Axis Inspection Rule
· **Lead aVR** has the largest magnitude (-11 { mm}), meaning the electrical depolarization wave is moving **directly away** from aVR (-150).
· The exact opposite direction to -150 is +30, confirming the mean electrical axis is right around +30.
(Note: Notice also that these augmented limb leads satisfy Goldberger's law: {aVR} + {aVL} + {aVF} = -11 + 9 + 6 ≈ 0, *allowing for minor visual rounding on the ECG grid.)*

When looking at the **6 limb leads (I, II, III, aVR, aVL, aVF)**, find the lead that has an **isoelectric (equiphasic) QRS complex** where the upward deflection equals the downward deflection (*R* ≈ *S*, so the **net QRS** ≈ 0).

· **Why *R* = *S* means perpendicular:** A lead records maximum amplitude when the mean electrical vector moves directly parallel to its axis, and records **zero net deflection** (*R* = *S*) when the vector is **perpendicular** (90) to that lead's axis.

· Therefore, the mean QRS axis lies along one of the **two directions perpendicular** (90 **away**) from that isoelectric lead.



Scan the 6 limb leads (I, II, III, aVR, aVL, aVF) to spot the lead where the positive (*R*) and negative (*S*) deflections are roughly equal (*R* ≈ *S*, net ≈ 0).

2. **Find the two axes perpendicular** (90) **to that lead:**

· Every limb lead axis has two perpendicular directions (+90 and –90 from its angle).

3. **Determine which of the two perpendicular directions is the true axis:**

· Look at the lead **parallel** to the desired direction (or check **Lead I** and **Lead aVF**):

· If the QRS in that direction's lead is **predominantly positive (+)**, the mean electrical axis points **toward** that positive pole.

· If it is **predominantly negative (–)**, the axis points **away** toward the opposite pole (180 away).

Applying It to the Provided ECG Strip:

In the 12-lead ECG shown (limb leads on the left: **I, II, III, aVR, aVL, aVF**; chest leads on the right: *V1–V6*):
· **Leads I and II** are clearly **positive** (*R* wave is much taller than *S*).
· **Lead aVF** is also **positive** (upward deflection exceeds downward).
· **Lead aVL** shows a relatively small/equilibrating deflection compared to the strong positive leads I, II, and aVF, placing the mean electrical vector in the **normal axis range** (0 **to** +90)—specifically around +30 **to** +60 (where Lead I and Lead II are strongly positive).



If the Isoelectric ($R \approx S$) Lead Is...	Its Angle	Perpendicular (90°) Directions Are...	Corresponding Leads on Those Perpendicular Axes
Lead I	0°	+90° or −90°	**aVF** (+90° is positive; −90° is negative aVF)
Lead II	+60°	−30° or +150°	**aVL** (−30° is positive; +150° is negative aVL)
Lead III	+120°	+30° or −150°	**aVR** (−150° is positive; +30° is negative aVR)
Lead aVR	−150°	−60° or +120°	**Lead III** (+120° is positive; −60° is negative Lead III)
Lead aVL	−30°	+60° or −120°	**Lead II** (+60° is positive; −120° is negative Lead II)
Lead aVF	+90°	0° or ±180°	**Lead I** (0° is positive; ±180° is negative Lead I)

Bipolar and Uniploar Limb Leads

First Case: Lead I (+5) and Lead aVF (+9), **Given Values:**

· **Lead I (0):** +5 { mm} (positive)

· **Lead aVF (+90):** +9 { mm} (positive)

· **Interpretation:**

· Both **Lead I** and **Lead aVF** are **positive (+)**, placing the mean electrical axis in the **normal quadrant (0 to +90)**.

· Since **aVF (+9)** is larger than **Lead I (+5)**, the vector points more steeply downward toward +90 (around +60), which is clearly **Normal Axis** (normal range: -30 **to** +90).

· *(Note: the picture shows bipolar and unipolar limb leads, **Leads I, II, and aVF** are positive while **aVR** is negative, matching a normal axis pattern.)*

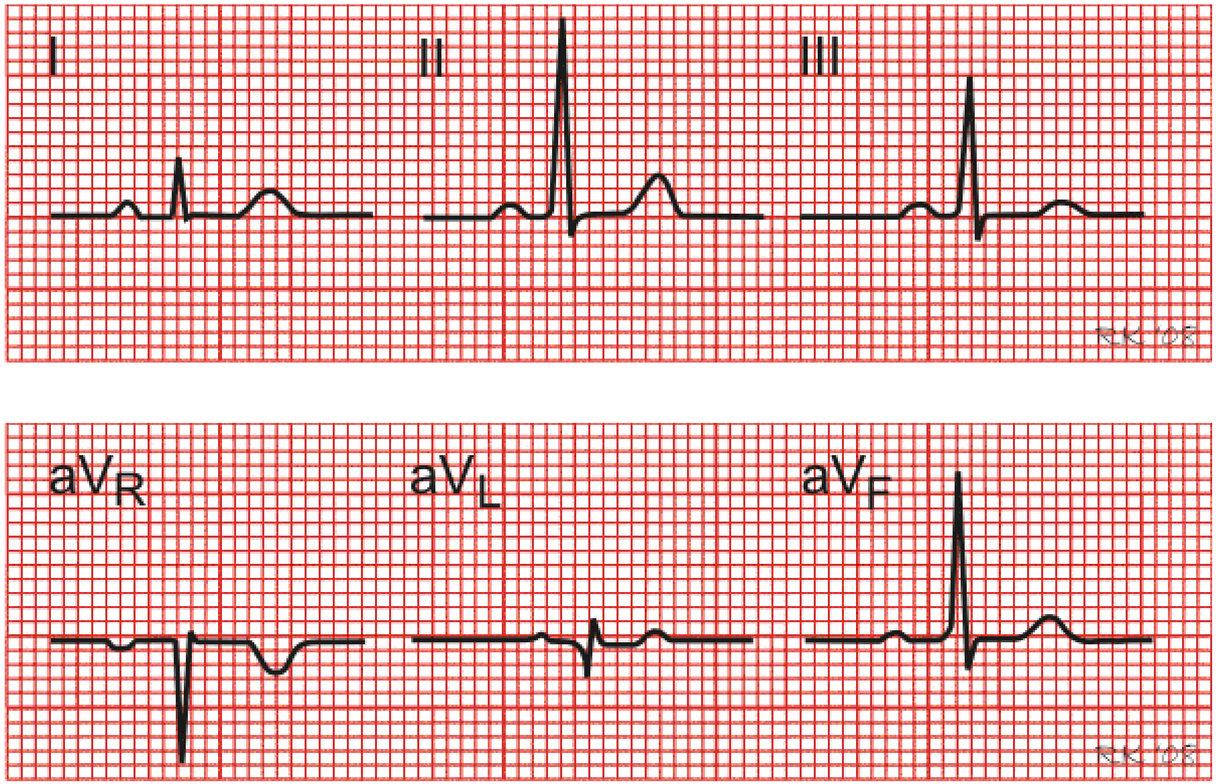

Second Case: Calculating Lead III Using Einthoven's Law

When given **Lead I** and **Lead II** and asked to find **Lead III**, use **Einthoven's Law**:

Lead II = Lead I + Lead III

Applying the Doctor's Example (Lead III ≈ +9)

· In the doctor's example, **Lead III comes out to approximately** +9 because **Lead II is roughly** 9 **units greater than Lead I** (Lead III = Lead II − Lead I ≈ +9).

Now we will discuss 4 things:

1. PQ (PR) Interval

2. QT Interval & Corrected QT (QT_c)

3. QRS Duration & Distinguishing Hypertrophy vs. Bundle Branch Block

4. ST Segment & Acute Coronary Syndromes (Myocardial Infarction)

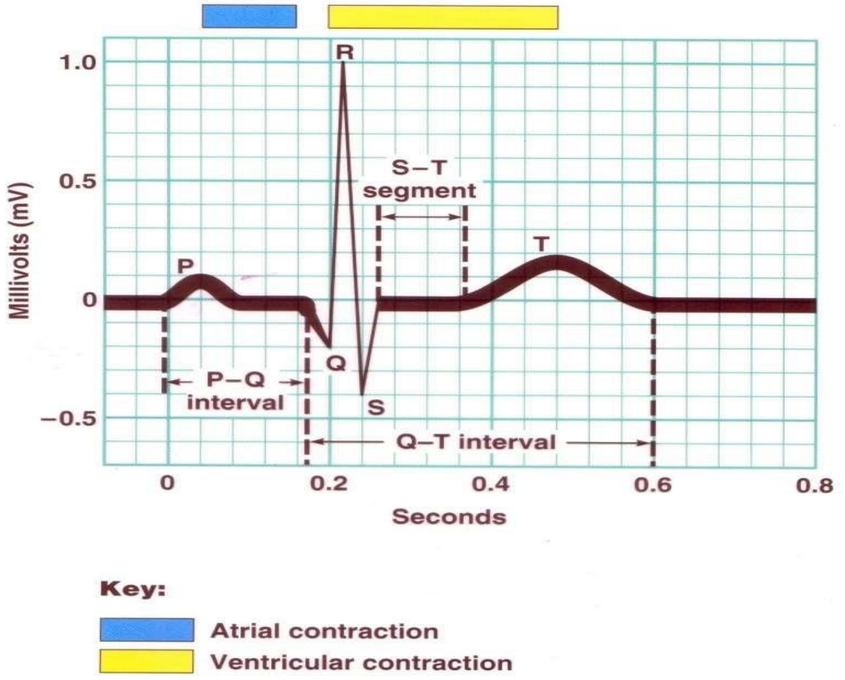

1. PQ (PR) Interval

- **Definition:** Represents the time from the **onset of atrial depolarization** (start of the P wave) until the **onset of ventricular depolarization** (start of the QRS complex), reflecting conduction delay through the AV node.

- **Normal Duration:**

· Typically around 0.16 seconds ≈ approx 4 small squares
· Normal range is up to 0.20 seconds ≈ 5 small squares or 1 large square; where each small square = 0.04 seconds at standard paper speed 25 mm/s

- **Prolonged PQ Interval** (> 0.20 s)

· Indicates delayed AV conduction (AV block) and can predispose to **serious ventricular arrhythmias**.

- **Drug Effect:** Medications such as **digoxin** can prolong the PQ interval. Digoxin is **positively inotropic** (increases contractility) and **negatively dromotropic** (slows conduction velocity through the AV node).

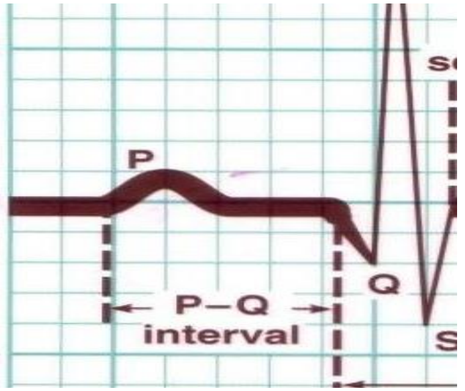

2. QT Interval & Corrected QT (*QTc*)

- **Definition:** Measures from the **beginning of the Q wave** (start of ventricular depolarization) to the **end of the T wave** (completion of ventricular repolarization)—encompassing total ventricular electrical systole.

- **Normal Duration:**

· Around 0.44 seconds≈ 11 small squares varying with heart rate.

- **Prolonged QT Interval & Arrhythmia Risk:**

· Prolongation increases the risk of delayed repolarization / early afterdepolarizations, allowing a **ventricular ectopic pacemaker** to fire and trigger **ventricular tachycardia (VT)**, which can degenerate into **ventricular fibrillation (VF)**—a life-threatening emergency.

- **Drug Effects:** Antiarrhythmics/cardiac drugs such as **amiodarone** (used in arrhythmias such as atrial fibrillation) can prolong the QT interval.

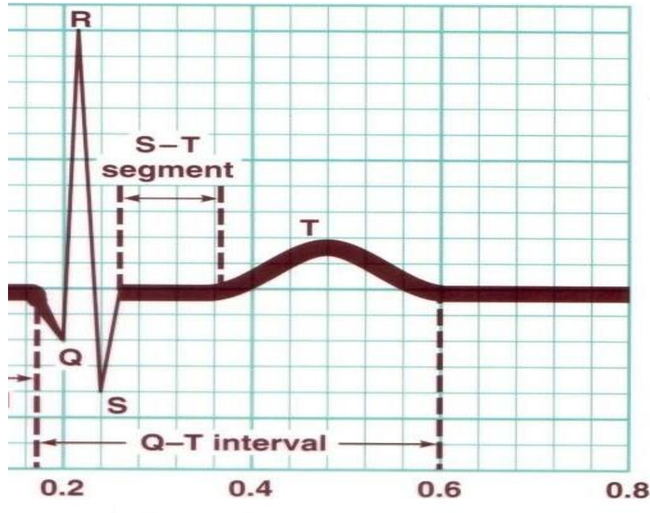

❑ Why Heart Rate Matters – Corrected QT (*QTc*):

· In **tachycardia** (fast heart rate), the **RR interval shortens**, making the raw QT interval appear shorter ("shrunk") and falsely normal on casual inspection.

· To adjust for heart rate, calculate the **corrected QT (*QTc*)** using Bazett's formula:

$$QT_c = \frac{QT}{\sqrt{RR}}$$

(where RR is in seconds; RR interval (s) = 60/HR

· **Calculations (with *QT = 0.44 s*):**

· HR = 75 bpm (RR = 60/75 = 0.80 s):

$$QT_c = \frac{0.44}{\sqrt{0.80}} \approx \frac{0.44}{0.894} \approx \mathbf{0.49\ s} \quad \text{(elevated / prolonged above 0.44 s)}$$

· HR = 60 bpm (RR = 1.0 s):

$$QT_c = \frac{0.44}{\sqrt{1.0}} = \mathbf{0.44\ s} \quad \text{(normal)}$$

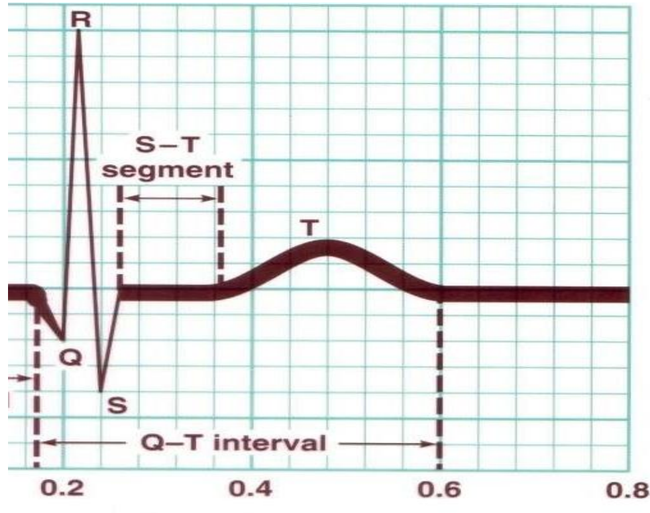

3. QRS Duration & Distinguishing Hypertrophy vs. Bundle Branch Block

➢ **Normal Duration:**

· Basic physiology references often cite ≈ 0.06 s, while clinical ECG readings generally accept up to 0.09 s (under 0.10 s).

➢ **Abnormal Prolongation:**

· 0.09 s **to** < 0.12 s: Suggests **ventricular hypertrophy** (increased myocardial mass/thickness).

· >= 0.12 (>=3 small squares**; note the doctor mentioned** > 4 small squares} **in class):** Indicates a **bundle branch block (BBB)** due to delayed/interrupted conduction through the right or left bundle branch.

➢ **How to Differentiate Ventricular Hypertrophy vs. Bundle Branch Block:**

· **Ventricular Hypertrophy ("Too much voltage"):** Thickened muscle generates higher electrical voltage. Measure total peak-to-peak amplitude (from top peak to bottom trough, adding magnitudes as positive values); **high QRS voltage** points toward **hypertrophy**.

· **Bundle Branch Block (Conduction delay without high voltage):** Prolongs QRS duration because the impulse takes a slower/detour pathway, **without** necessarily producing high QRS voltage from increased muscle mass.

4. ST Segment & Acute Coronary Syndromes (Myocardial Infarction)

✓ **Clinical Importance: Coronary artery disease (CAD)** is the **leading cause of death globally**, making the **ST segment** (and **T wave**) one of the most critical parts of the ECG to evaluate.

· **Typical Presentation:** A patient presenting with **chest pain**, often accompanied by **nausea and vomiting**, requires an immediate ECG.

➢ **ST-Segment Changes:**

○ **ST Elevation:** ST segment rises above the baseline (isoelectric line).

○ **ST Depression:** ST segment drops below the baseline (isoelectric line).

· Both changes can reflect **cardiac ischemia** (reduced blood flow/oxygen supply to the myocardium).

○ **STEMI (ST-Elevation Myocardial Infarction):**

· A critical medical emergency indicating acute transmural myocardial injury/infarction; **time is critical** for rapid reperfusion/intervention to save myocardium and life.

❖ **Role of Cardiac Troponin & Normal ECG Caveat:**

· **Cardiac troponin** is a biomarker of **myocardial cell death (necrosis)**. Elevated cardiac troponin indicates **myocardial infarction (MI)**.

- **Normal ECG does NOT rule out MI:** If a patient has a **normal ECG** and **initially negative troponin**, yet the **clinical history strongly suggests MI**, **do not discharge the patient**—keep them under observation in the emergency setting for serial ECGs and repeat troponin testing, as early MI can initially have a normal ECG or troponin levels that have not yet risen.

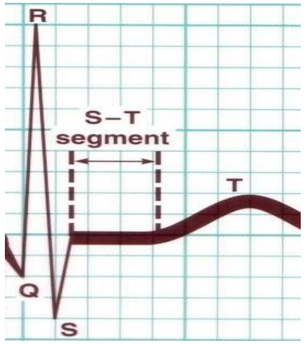

Segments vs. Intervals: *An **interval** includes waves plus segment(s) (e.g., **PQ/PR interval, QT interval**), whereas a **segment** is the baseline line **between waves and does not include any wave**—such as the **PR segment** and the **ST segment**.*

Electrocardiogram

- Record of electrical events in the myocardium that can be correlated with mechanical events
- **P wave**: depolarization of atrial myocardium.
  - Signals onset of atrial contraction
- **QRS complex**: ventricular depolarization
  - Signals onset of ventricular contraction..
- **T wave**: repolarization of ventricles
- **PR interval** or PQ interval: 0.16 sec
  - Extends from start of atrial depolarization to start of ventricular depolarization (QRS complex) contract and begin to relax
  - Can indicate damage to conducting pathway or AV node if greater than 0.20 sec (200 msec)
- **Q-T interval**: time required for ventricles to undergo a single cycle of depolarization and repolarization
  - Can be lengthened by electrolyte disturbances, conduction problems, coronary ischemia, myocardial damage

Core Rule: Excitation–Contraction Coupling (Electrical Precedes Mechanical)

On a cardiac cycle diagram (such as Wiggers' diagram), **electrical events (ECG waves) always happen BEFORE mechanical events (contraction, pressure rise, valve movements, and ejection)**:

· **Depolarization first** \rightarrow **Contraction & Pressure rise second.**

· There is a brief physiological delay between the electrical signal sweeping across the myocardium and the mechanical force/pressure building up inside the chambers.

Electrocardiogram

➢ Normal Measurements of the P Wave:

The **P wave** represents **atrial depolarization** (the electrical impulse spreading across the right and left atria).

· **Normal Duration (Width – horizontal axis):**

· Up to **3 small squares** maximum (0.12 seconds, since each small square = 0.04 s).

· **Normal Amplitude / Extent (Height – vertical axis):**

· Up to **1.5 to 2 small squares** maximum (0.15–0.20 mV, since each small square vertically = 0.1 mV).

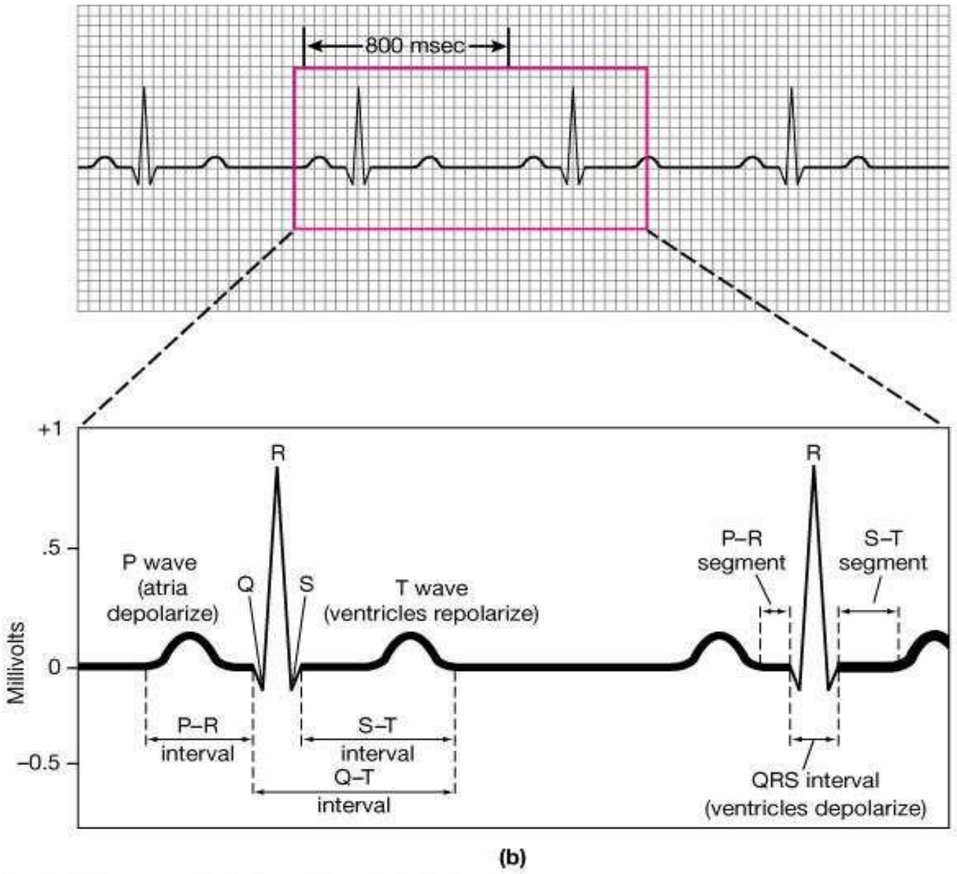

(b)

➢ Abnormal P-Wave Patterns & Clinical Correlations

· **Tall / Peaked P Wave ("Large" Amplitude – *P pulmonale*):**

· **Finding:** P wave exceeds the normal height limit (> 2 – 2.5 small squares} tall) with normal duration.

· **Underlying Cause: Right atrial enlargement / increased atrial mass or pressure**, classically associated with **pulmonary hypertension** (increased right-sided pressure/workload).

· **Classic Term: P pulmonale**.

· **Wide / Prolonged P Wave (Increased Duration – *P mitrale*):**

· **Finding:** P wave lasts longer than normal (> 3 small squares or > 0.12 s wide, often notched/m-shaped as depolarization takes longer across a dilated/enlarged left atrium).

· **Underlying Cause: Left atrial enlargement**, classically caused by **mitral stenosis** (obstructed flow from the left atrium to the left ventricle increasing left atrial pressure and size).

· **Classic Term: P mitrale.**

3. Quick Summary Table

Abnormal Feature	ECG Appearance	Classical Term	Typical Underlying Cause
Increased height (amplitude)	Tall / peaked P wave (> 2 small squares high)	**P pulmonale**	Right atrial enlargement / **pulmonary hypertension**
Increased duration (width)	Wide / prolonged P wave (> 3 small squares wide)	**P mitrale**	Left atrial enlargement / **mitral stenosis**

Flow of Electrical Currents in the Chest Around the Heart

Mean Vector Through the Partially Depolarized Heart



➢ Septal Depolarization (Left-to-Right) & Why Different Leads See Different Polarities:

6 PRECORDIAL (CHEST) LEADS

· **Starting Point:** Ventricular depolarization begins in the **interventricular septum**, spreading from **left to right**.
· **Why Polarity Differs Across Leads:** Whether a lead records a **positive (upward)** or **negative (downward)** deflection depends on the **direction of the wave relative to that lead's positive electrode**:
· A recording electrode on the **left side** (facing away from a left-to-right wave) sees a **negative (downward) deflection** (such as a small initial Q wave in left-facing leads).
· Another lead positioned so the wave moves **toward its positive pole** sees the exact same event as a **positive (upward) deflection**.
· **Key Takeaway:** Both deflections represent **ventricular depolarization**—the difference is simply the viewing angle of each lead.

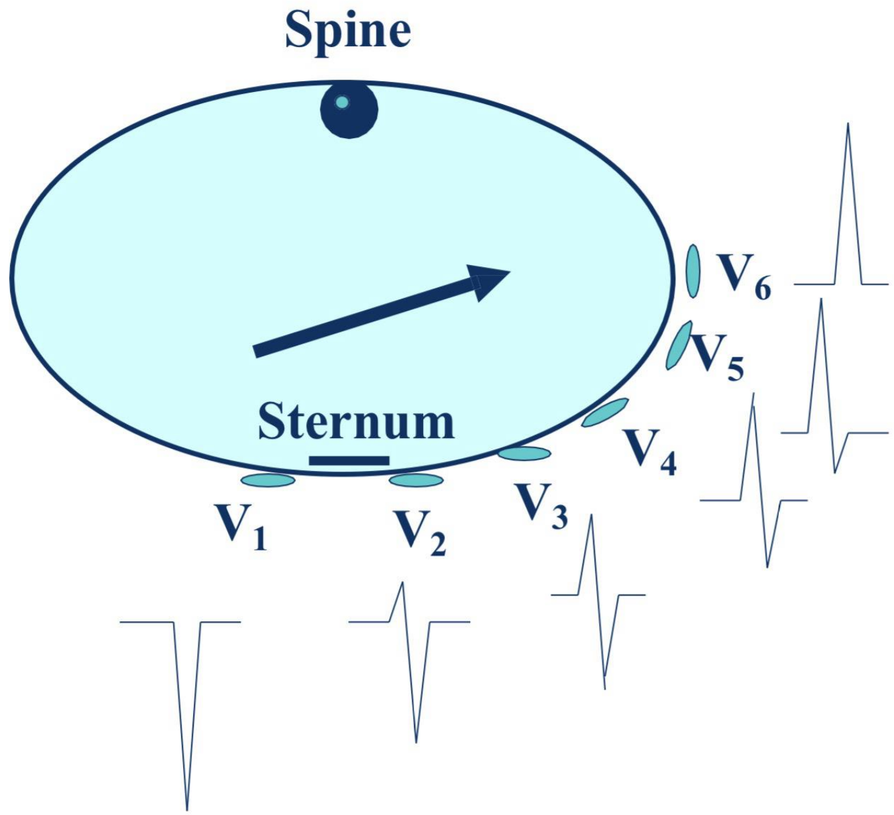

➢ Ventricular Depolarization vs. Repolarization Direction:

· **Depolarization (Inside** \rightarrow **Outside):**
· Once the septum activates, depolarization spreads through the ventricular walls from the **endocardium (inner layer)** toward the **epicardium (outer surface)**.
· **Repolarization (Outside** \rightarrow **Inside – Reverse of Depolarization):**
· Repolarization typically starts at the **last region to depolarize**—meaning from the **epicardium (outer layer) inward toward the endocardium**.

Vectorcardiogram

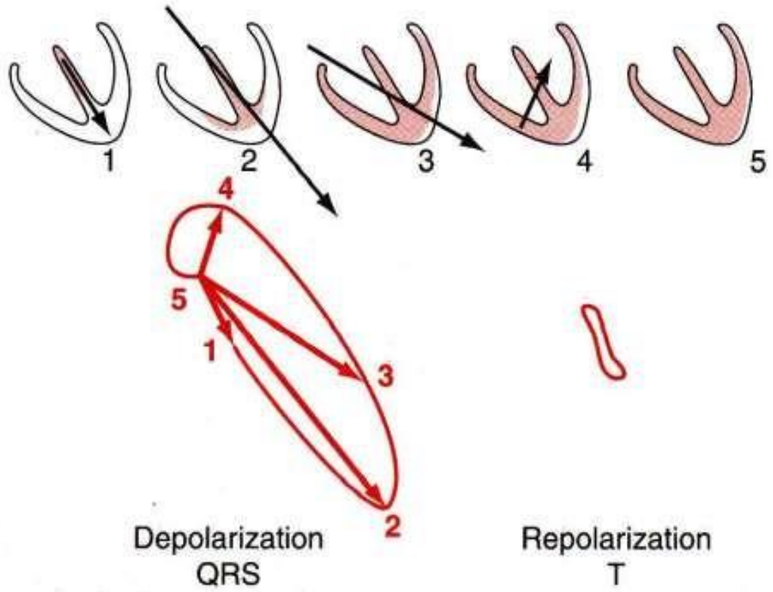

- This traces vectors throughout cardiac cycle.
- When half of the ventricle is depolarized, vector is largest.

- Note zero reference point, number 5, is point of full depolarization

❑ Why Repolarization Starts on the Outer Side (Epicardium)

· **Contraction & Endocardial Compression:** After depolarization triggers ventricular contraction, **intramyocardial pressure rises** and compresses the **endocardium** and the **blood vessels / microcirculation** running through the inner wall.

· **Effect on Blood Flow & Ion Movement:** Reduced perfusion and mechanical pressure/metabolic stress on the compressed endocardium **interfere with normal ion movement and repolarization** compared with the outer layer (**epicardium**), where conditions are more favorable—so repolarization begins at the epicardium first.

· *(Note: Because depolarization travels from inside to outside while repolarization travels from outside to inside—opposite directions—both waves have the **same polarity**, which is why the **T wave** is normally upright/positive like the main **R wave** of the QRS complex.)*

Chest leads (Unipolar)

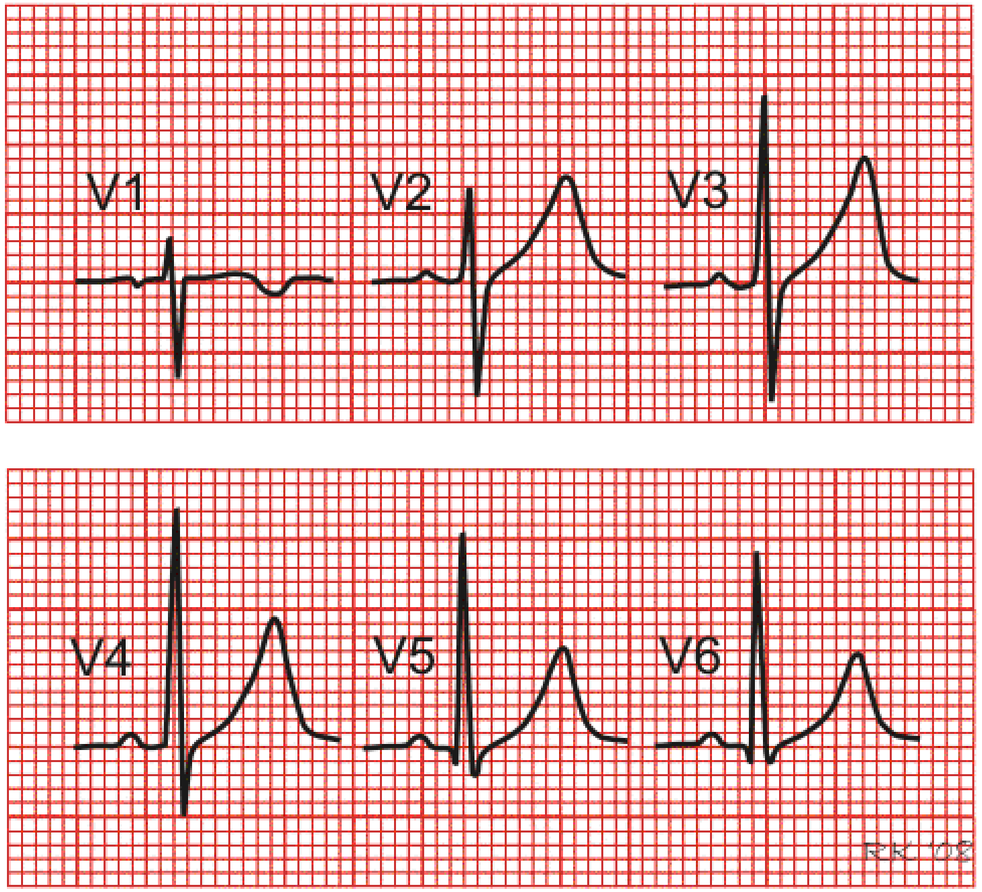

Thank You



رسالة من الفريق العلمي:



For any feedback, scan the code or click on it.

Corrections from previous versions:

Versions	Slide # and Place of Error	Before Correction	After Correction
V0 → V1			
V1 → V2			