Pathology of hematolymphoid system
Acute Leukemia
Histiocytic tumors

Professor Tariq Aladily
Department of Pathology
The University of Jordan
tnaladily@ju.edu.jo

School of Medicine

ACUTE MYELOID LEUKEMIA

- Occur at all age groups, but more common in elderly
- Heterogenous, diagnosis is made by morphologic, immunophenotypic and karyotype studies
- Prognosis depends most importantly on type of mutations (molecular and cytogenetic studies
- Symptoms are accelerated, become significant within few weeks
- Symptoms are related to anemia, thrombocytopenia and neutropenia
- Involvement of LN, spleen and solid organs is rare. When occurs, it is called myeloid sarcoma (acute monoblastic leukemia)

PATHOGENESIS

- Mutations in genes of transcription factors required for maturation and differentiation of myeloblasts
- Additional mutations in tyrosine kinase pathways (RAS)
- Epigenetic mutation is common (20%); mutation is isocitrate dehydrogenase (IDH) produces an oncometabolite that blocks enzyme of epigenome and interferes with myeloblast differentiation

WHO-CLASSIFICATION

- Therapy related AML: occurs after treatment with chemo or radiotherapy
- AML with recurrent cytogenetic mutation
- AML with myelodysplasia: occurs de novo or complicates MDS
- AML-Not otherwise specified

- Diagnosis of AML: 20% blasts in peripheral blood or bone marrow (of nucleated cells)

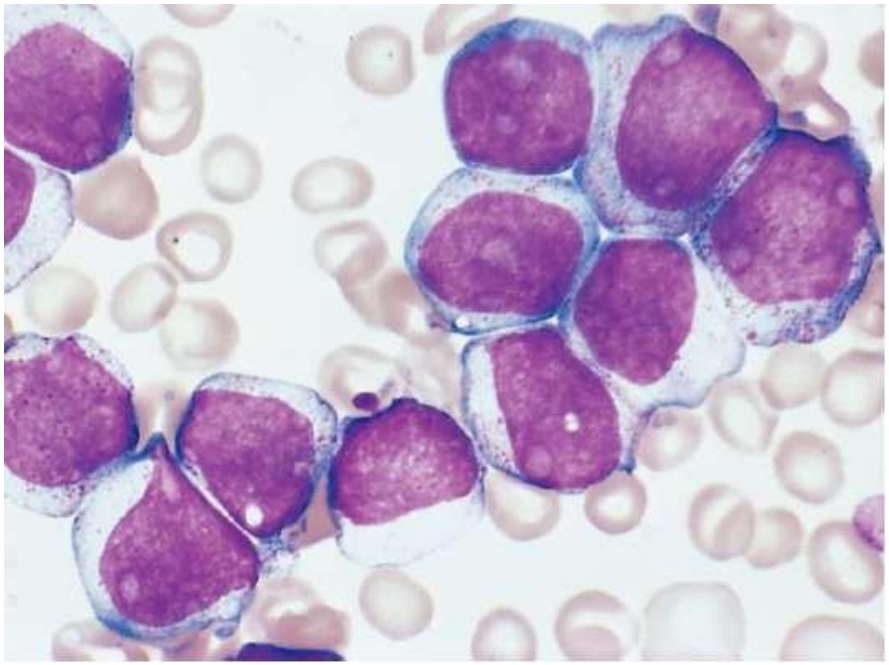

- Morphology: large cells, high N/C ration, fine granules in cytoplasm, fine chromatin, prominent nucleoli
- Auer rods: small pink rods present in cytoplasm, represent peroxidase enzyme
- Myeloblasts express CD34, myeloperoxidase (MPO), CD13, CD33
- Sometimes: monoblast, erythroblast, megakaryoblast

OUTCOME

- Generally poor, <30% responds to chemotherapy
- Worse than ALL
- P53 mutation: worse outcome
- IDH inhibitors are new promising drugs

ACUTE PROMYELOCYTIC LEUKEMIA

- Also called AML-M3
- Maturation is arrested at promyelocyte stage
- Leukemic cells appear similar to promyelocytes (heavy cytoplasmic granules, numerous Auer rods, negative for CD34)
- Carry recurrent mutation: t(15;17) fusion between PML gene (chrom 15) with alpha retinoic acid receptor (RARA) on chrom 17. Chimeric fusion gene produces a protein that blocks promyelocyte maturation by inhibiting the action of retinoic acid.
- All trans-retinoic acid (ATRA), a vitamin A analogue, overcomes this block. Effect is synergistic with arsenic trioxide (degrades oncoprotein)
- Malignant promyelocyte secrete tissue factor, causing DIC

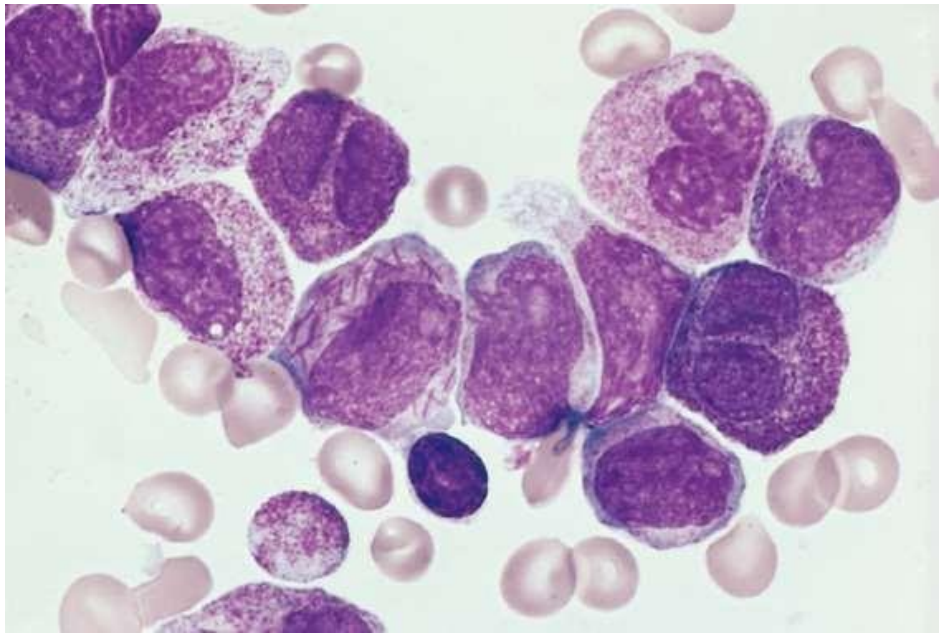

- APL: malignant promyelocytes show numerous cytoplasmic granules and Auer rods. The nuclei are commonly cleaved.

PRECURSOR B AND T CELL NEOPLASMS

- Lymphoblastic lymphoma when occurs in solid tissue (T>B)
- Acute lymphoblastic leukemia when circulates peripheral blood and involve bone marrow (B>T)
- B-ALL is the most common childhood malignancy
- Neoplastic cells are lymphoblasts, the most immature lymphoid cell. Aggressive neoplasms, express CD34 and TDT
- T-ALL is less common, presents in adolescents, involving thymus, more common in boys
- B-ALL tends to disseminate to solid organs (brain, testis, spleen)

PATHOGENESIS

- Mutations in transcription factors for genes responsible for maturation of blasts
- In B-LL, mutation in PAX5 gene
- Mutations in RAS signaling and tyrosine kinase proteins promoting cell survival
- Most childhood B-ALL have hyperdiploidy (>50 chromosomes) and t(12;21), involving ETV6 and TUNX1 genes, creating new transcription factor
- Adult B-ALL exhibits t(9;22) between ABL and BCR genes, similar to chronic myeloid leukemia, creating a new tyrosine kinase protein (imatinib)
- T-ALL shows mutation in NOTCH1 gene (70% of cases), PTEN gene (tumor suppressor) and CDKN2A (promotes cell cycle)

MORPHOLOGY OF ALL

- Blasts are large, high N/C ration
- Chromatin is open (pale)
- Nucleolus sometimes present
- Cytoplasm is not granular

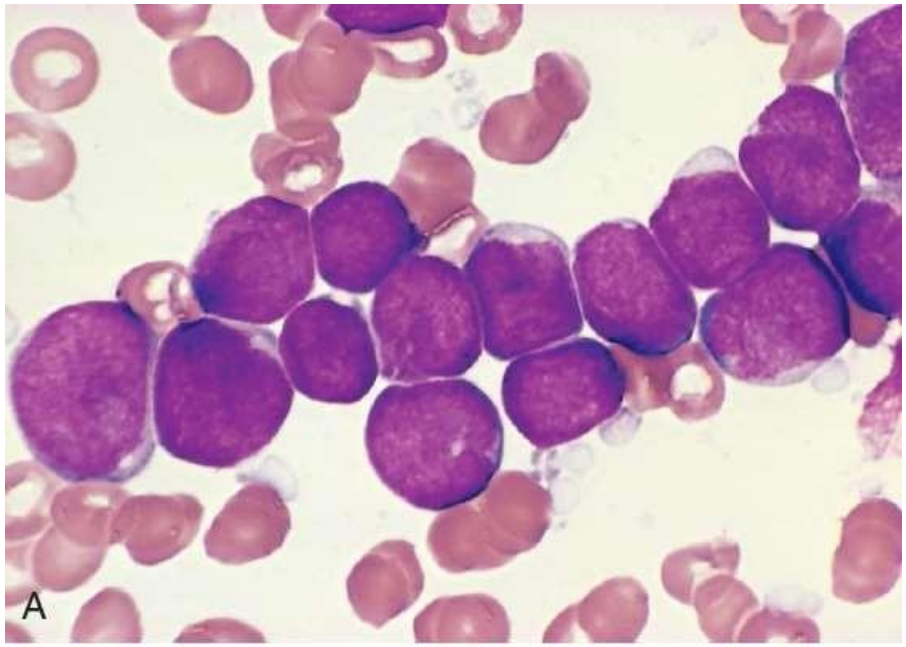

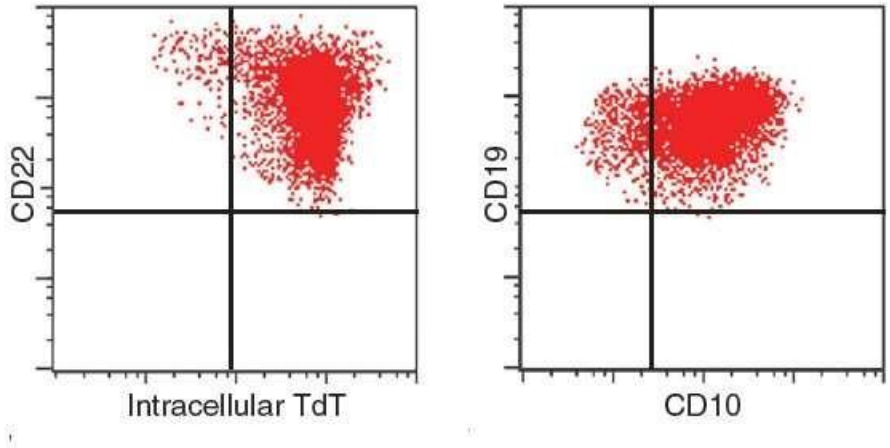

CLINICAL FEATURES

- Anemia, thrombocytopenia
- Bone pain
- Lymphadenopathy and hepatosplenomegaly
- Testicular enlargement
- Mediastinal mass (T-ALL)
- CNS involvement
- Damage to solid organs secondary to leukemic infiltration
- Favorable prognostic factors in B-ALL: hyperdiploidy, low WBC count, age between 2-10 years
- Poor prognostic factors in B-ALL: age < 2 years, age in adolescents or adults, WBC count >100k

LANGERHANS CELL HISTIOCYTOSIS

- Neoplasm of dendritic cells
- Langerhans cells express CD1a and Langerin
- Langerin is a transmembrane protein, attached to Birbeck granules (tennis ricket shape under electron microscope)
- Proliferating Langerhans cells appear large and vacuolated, similar to macrophages
- Pathogenesis: acquired mutation in serin/threonine kinase BRAF, leads to hyperactivity of this kinase

MULTISYSTEMIC LCH

- Occurs mostly in children less than 2 years
- Multiple cutaneous lesion, composed of LCs
- Hepatosplenomegaly and lymphadenopathy
- Pulmonary lesions
- Osteolytic lesions
- Extensive bone marrow infiltration leads to pancytopenia
- Treated with chemotherapy

UNISYSTEM LCH

- AKA eosinophilic granuloma
- Affects a single organ, most commonly bone, then skin, lung, stomach
- Can be unifocal or multifocal
- Unifocal is commonly asymptomatic, can cause pain
- Mulfocal unisystem disease presents in children, commonly affects calvaria bone, extends to pituitary gland causing diabetes insipidus, exophthalmous (Hand- Schuller-Christian triad).
- Proliferating LCs are admixed with numerous eosinophils, lymphocytes, plasma cells and neutrophils
- Treatment: unifocal: surgical excision, multifocal: chemotherapy, sometimes spontaneous regression