

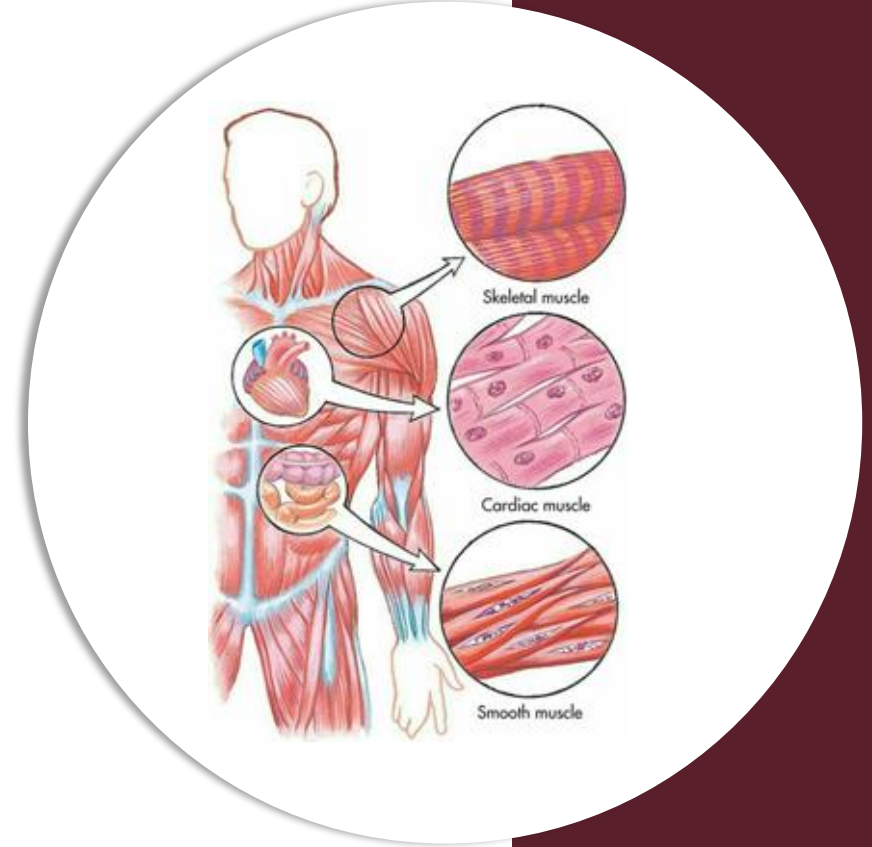
بِسْمِ اللّٰهِ الرَّحْمٰنِ الرَّحِیْمِ
(وَفَوْقَ كُلِّ ذِي عِلْمٍ عَلِيمٌ)



دکتور

Histology | Mid GI

Past Papers



Written by : DST

Reviewed by : Bushra Masalha
Maria Baroudi

Q1

All of the following are lined by simple columnar with goblet EXCEPT:

- A. ileum.
- B. gall bladder.
- C. Small intestine.
- D. jejunum.
- E. colon.

Ans: B

Q2

The Striated ducts characterized by all of the following EXCEPT:

- A. It has elongated mitochondria.
- B. It is interlobular duct.
- C. Secretes lysozyme and IgA.
- D. It has radial striation.
- E. Lined by tall cuboidal cells.

Ans: B

Q3

Histology of the stomach: all the following statement are correct EXCEPT:

- A. Chief cells are basophilic and predominant in the base of tubular gastric gland.
- B. The gastric pits in the body are long and narrow.
- C. The predominant cells in the pyloric region are the mucous cells.
- D. Parietal cells show intracellular canaliculi during activity.
- E. The parietal cells are located in the neck aspect of the fundic gland

Ans: B

Q4

Concerning the histology of the glands of the digestive system, all the followings are correct EXCEPT:

- A. The parotid gland has acini capped by serous demilunes and delivers the secretions into intercalated ducts.
- B. The pancreatic acini are serous glands containing centroacinar cells and their cells are characterized by polarity.
- C. The submandibular gland is a compound tubuloalveolar gland, it has a complicated duct system.
- D. The Von Ebner glands deliver their serous secretion into the groove of the circumvallate papillae.
- E. The Brunner glands in the submucosa of the duodenum secretes mucus and gastrine.

Q5

Section in the parotid gland, one of the following structures is not present in the section.

- A. Serous acinus.
- B. Striated duct.
- C. Intercalated duct.
- D. Serous Demilune.
- E. Interlobular duct.

Ans: D

Q6

Choose the correct statement with respect to salivary glands:

- A. The submandibular gland is exclusively composed of serous cells.
- B. The labial, palatal and sublingual glands are non-encapsulated.
- C. The parotid gland is described histologically as a branched tubuloacinar gland.
- D. Salivary secretions are devoid of lysozyme.
- E. The main duct of the submandibular gland is lined by non-keratinized stratified squamous epithelium before it empties into the oral cavity.

Ans: E

Q7

Which of the following is incorrect about pylorus histology :

- A. Long tubular pits
- B. Lined by squamous columnar epithelium with goblet cells
- C. The sphincter is thickening of innermost circular layer.

Ans:b

Q8

Which of the following is NOT true:

Answer: Taste buds are medial to the circumvallate papillae

Q9

Which of the following is not predominant in the pylorus:

Answer: Basophilic chief cells

Q10

Which sentence is Wrong:

Answer: active chief cell contains canaliculi.

Q11

Concerning the histology of the stomach, all are correct except:

Answer: in the pyloric region the chief cells are abundant and located in the....aspect of pyloric gland

Q12

Concerning the histology of digestive glands, all are true except:

Answer: the parotid acini are capped by serous demilunes & deliver their secretion into intercalated ducts.

Q13

Which of the following is not located on villi?

A. paneth cells

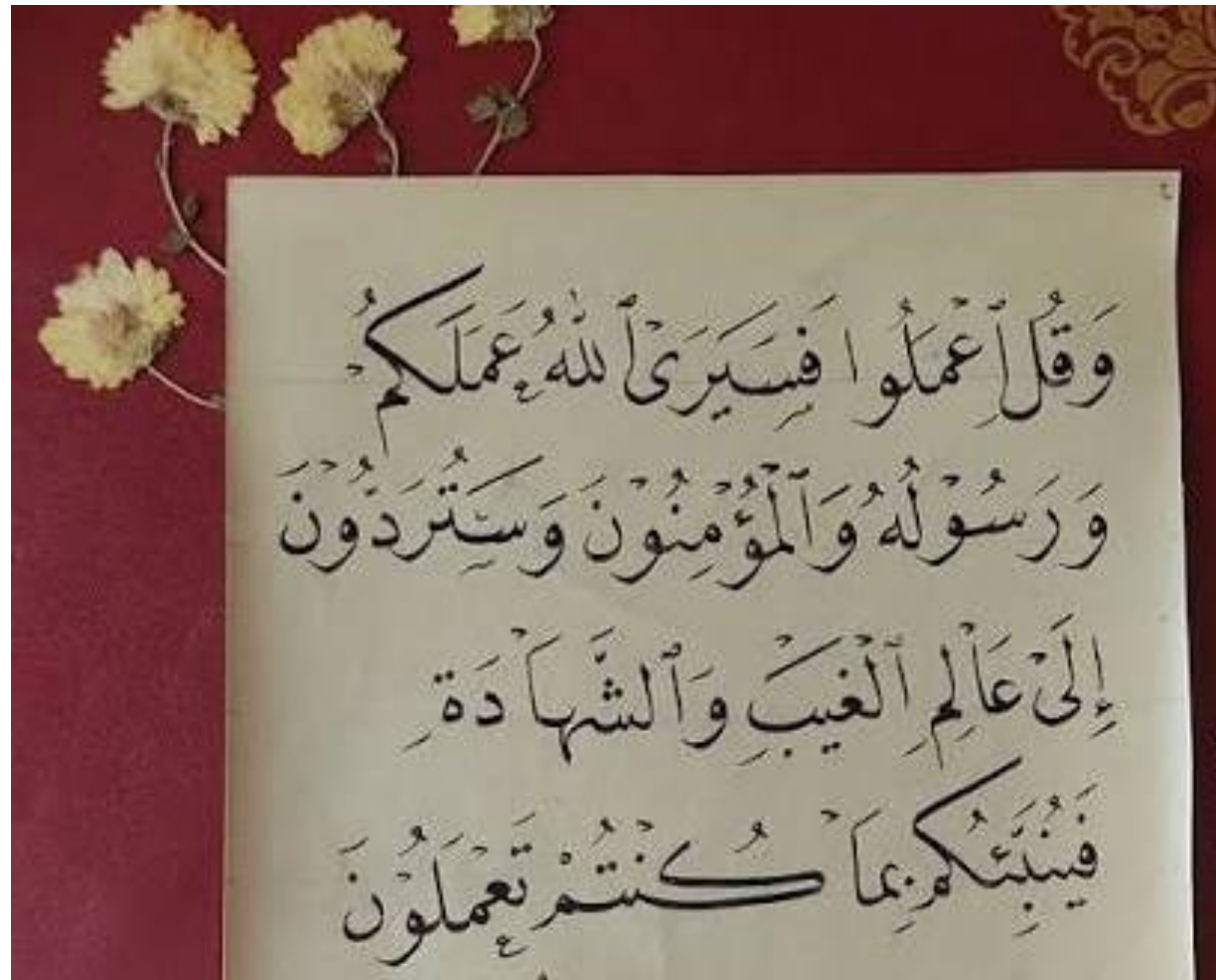B. goblet cells

C. brush boarder enzymes

Ans: A

رسالة من الفريق العلمي:

قال تعالى :



وَقُلْ أَعْمَلُوا بِمَا أَمَرَ اللَّهُ بِكُمْ
وَرَسُولُهُ وَالْمُؤْمِنُونَ وَسَتُرَدُّونَ
إِلَىٰ عَالَمِ الْغَيْبِ وَالشَّهَادَةِ
فَإِنَّكُمْ بِمَا كُنْتُمْ تَعْمَلُونَ

For any feedback, scan the code or click on it.



- Corrections from previous versions:

Versions	Slide # and Place of Error	Before Correction	After Correction
V0 → V1			
V1 → V2			