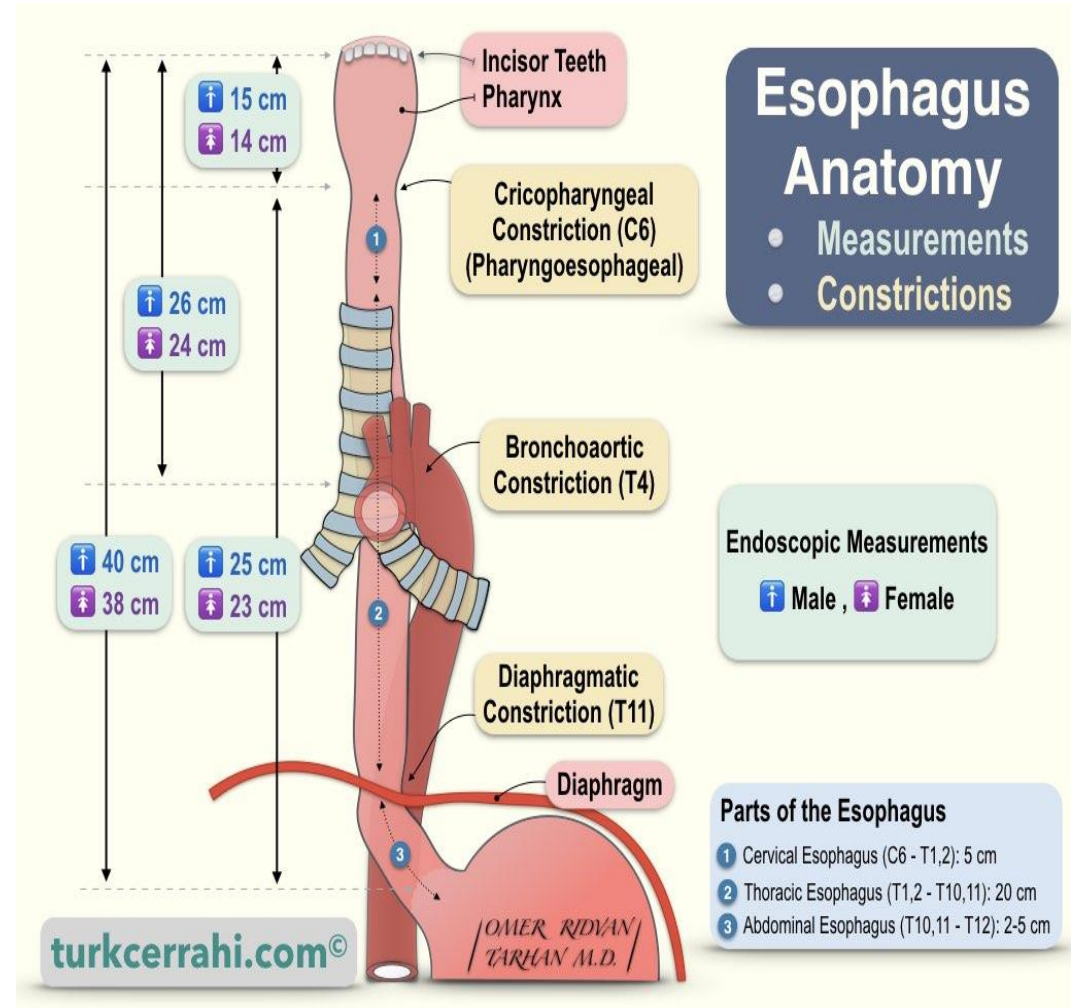


# Week 2 Practical

Esophagus, stomach, Small intestine large intestine (cecum, appendix and colon)

# Esophagus:

- The esophagus is a tubular structure about 10 in. (25 cm) long that joins the pharynx to the stomach.
- Enter the abdomen through esophageal opening (level of T10) in the right crus of diaphragm.
- has cervical, thoracic part and abdominal part



# Esophagus: relations

- Relations of thoracic part:

Anteriorly: trachea, left recurrent laryngeal n., left bronchus, pericardium

Posteriorly: thoracic vertebra, thoracic duct, azygous vein, Rt posterior intercostal arteries, descending thoracic aorta

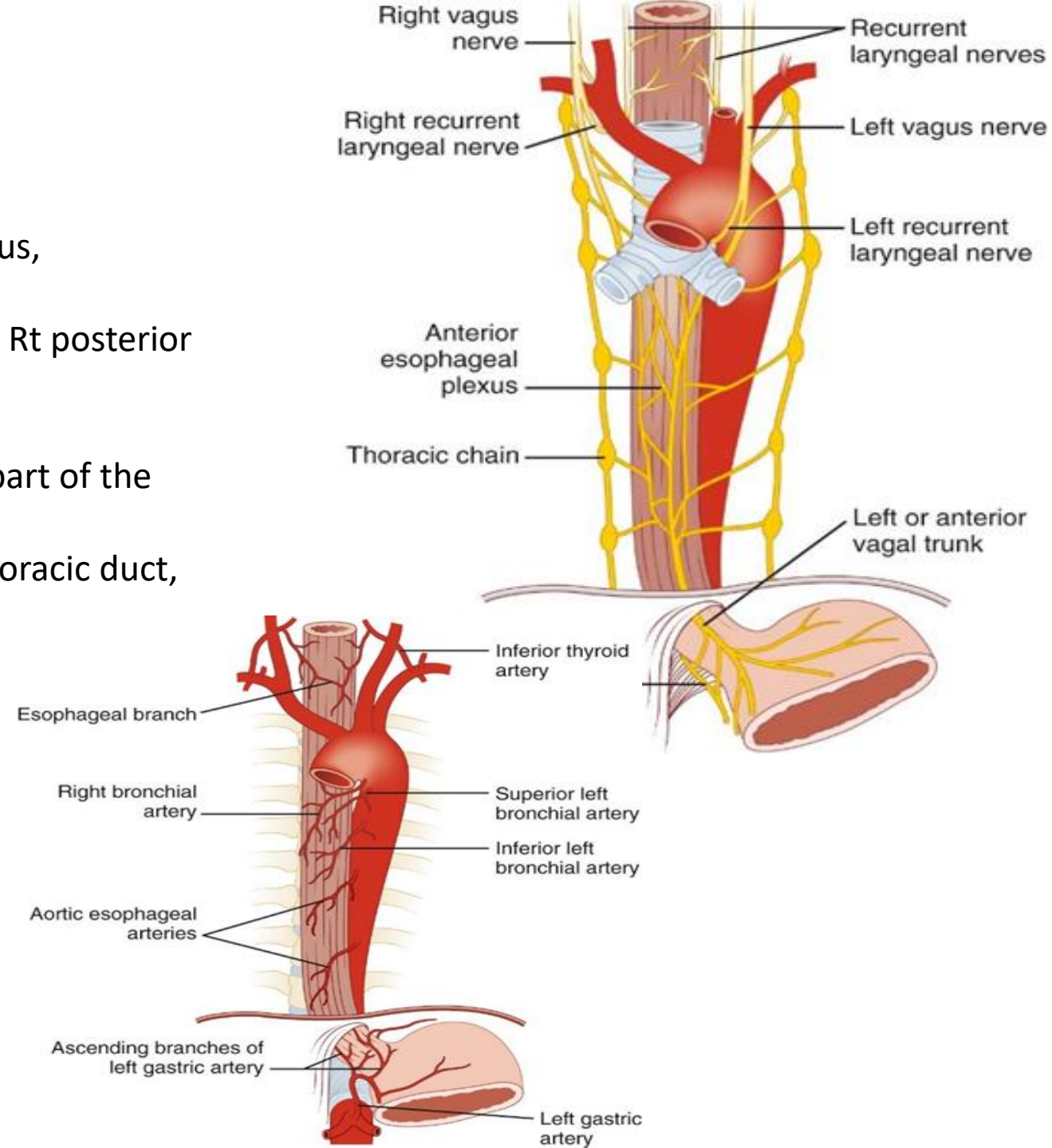
Right side: The right mediastinal pleura and the terminal part of the azygos vein

Left side: The left subclavian artery, the aortic arch, the thoracic duct, and the left mediastinal pleura and lung.

Relations of abdominal part:

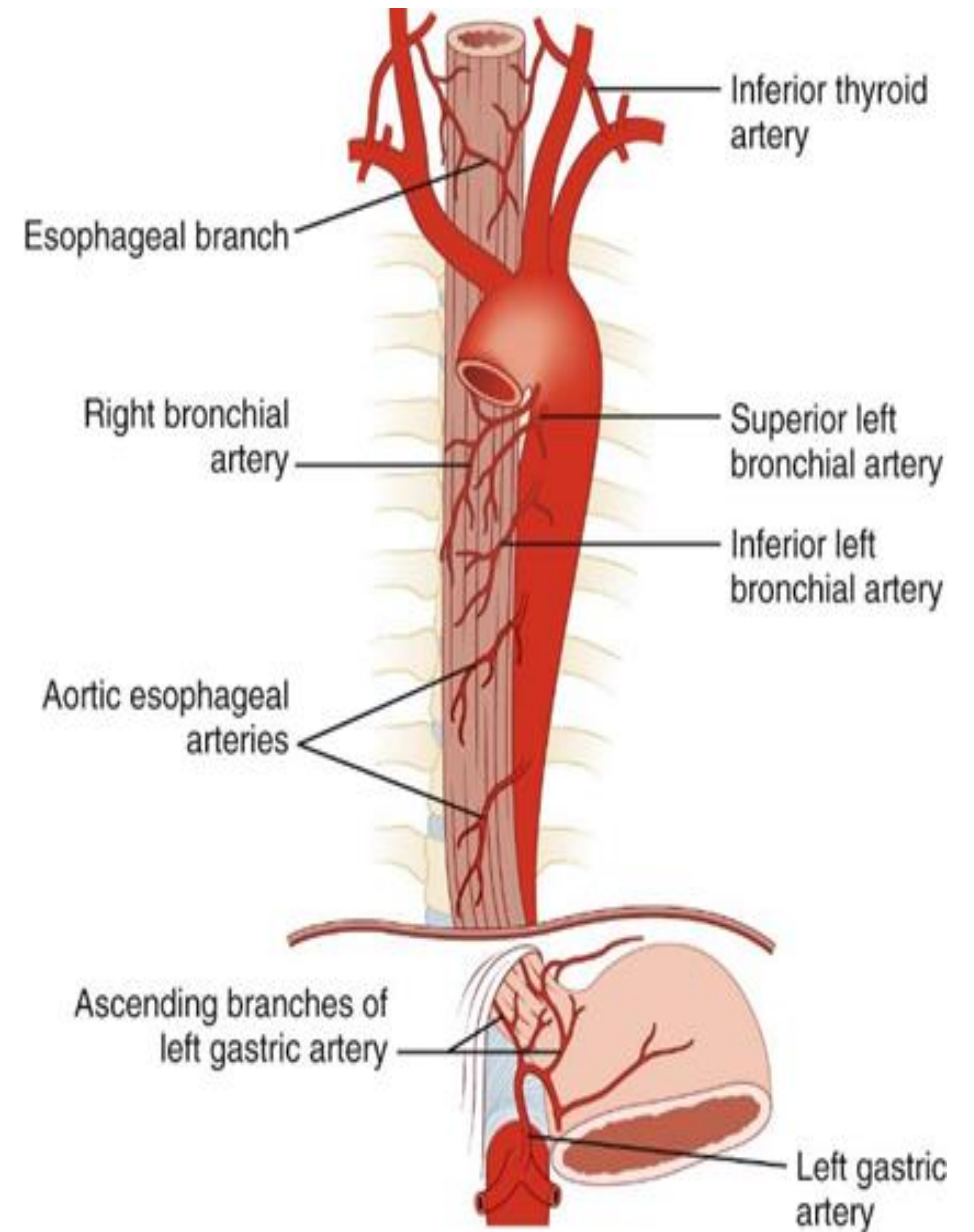
1-Anteriorly: left lobe of the liver & left vagus nerve

2-Posteriorly: left crus of the diaphragm & right vagus nerve



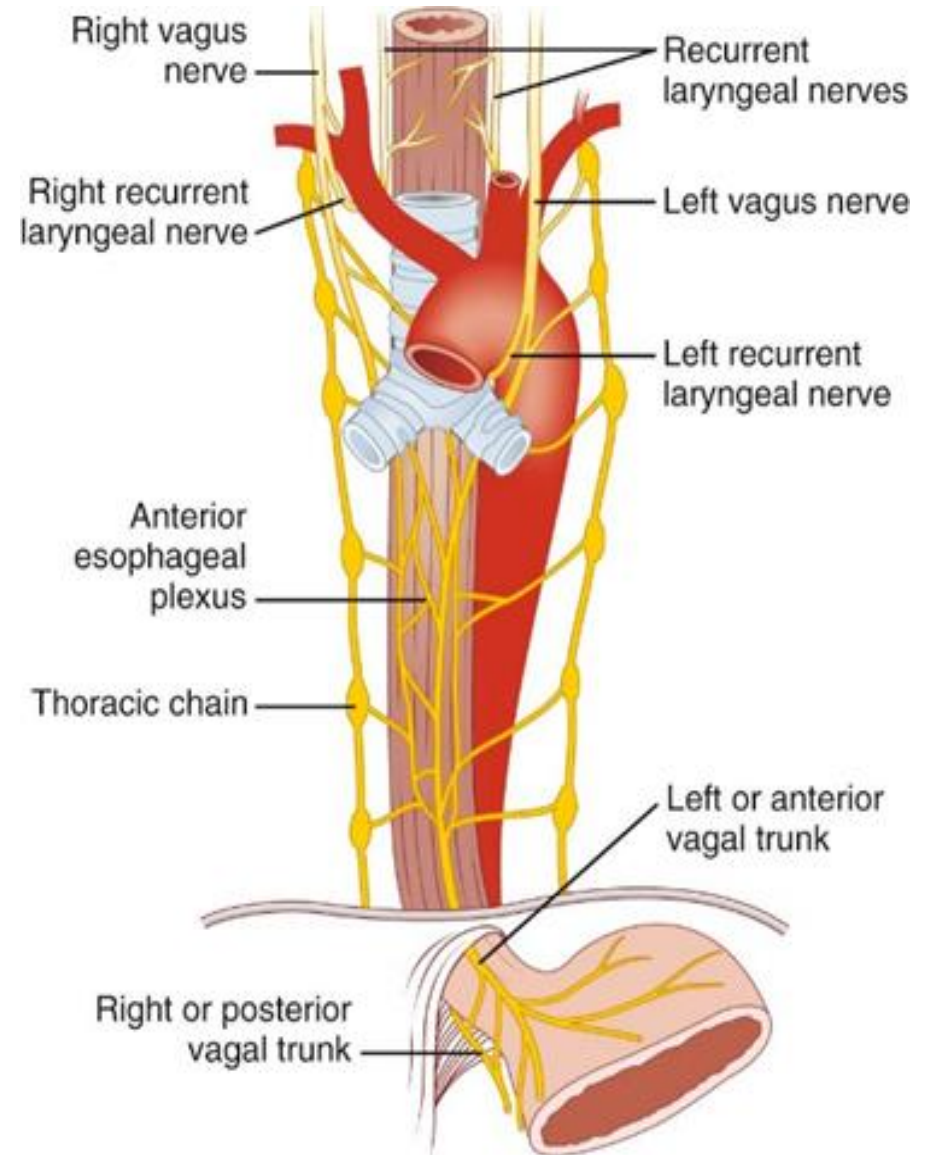
## blood supply of esophagus:

SECTION	Artery	Vein	Lymph Nodes
Upper third	Inferior thyroid artery	Drain into the inferior thyroid veins	Drain into the deep cervical nodes
Middle third	Descending thoracic aorta	Drain into the azygos veins	Drain into the superior and posterior mediastinal nodes
Lower third	Branches from the left gastric artery	Drain into the left gastric vein, a tributary of the portal vein	Drain into nodes along the left gastric blood vessels and the celiac nodes



## Innervation of esophagus:

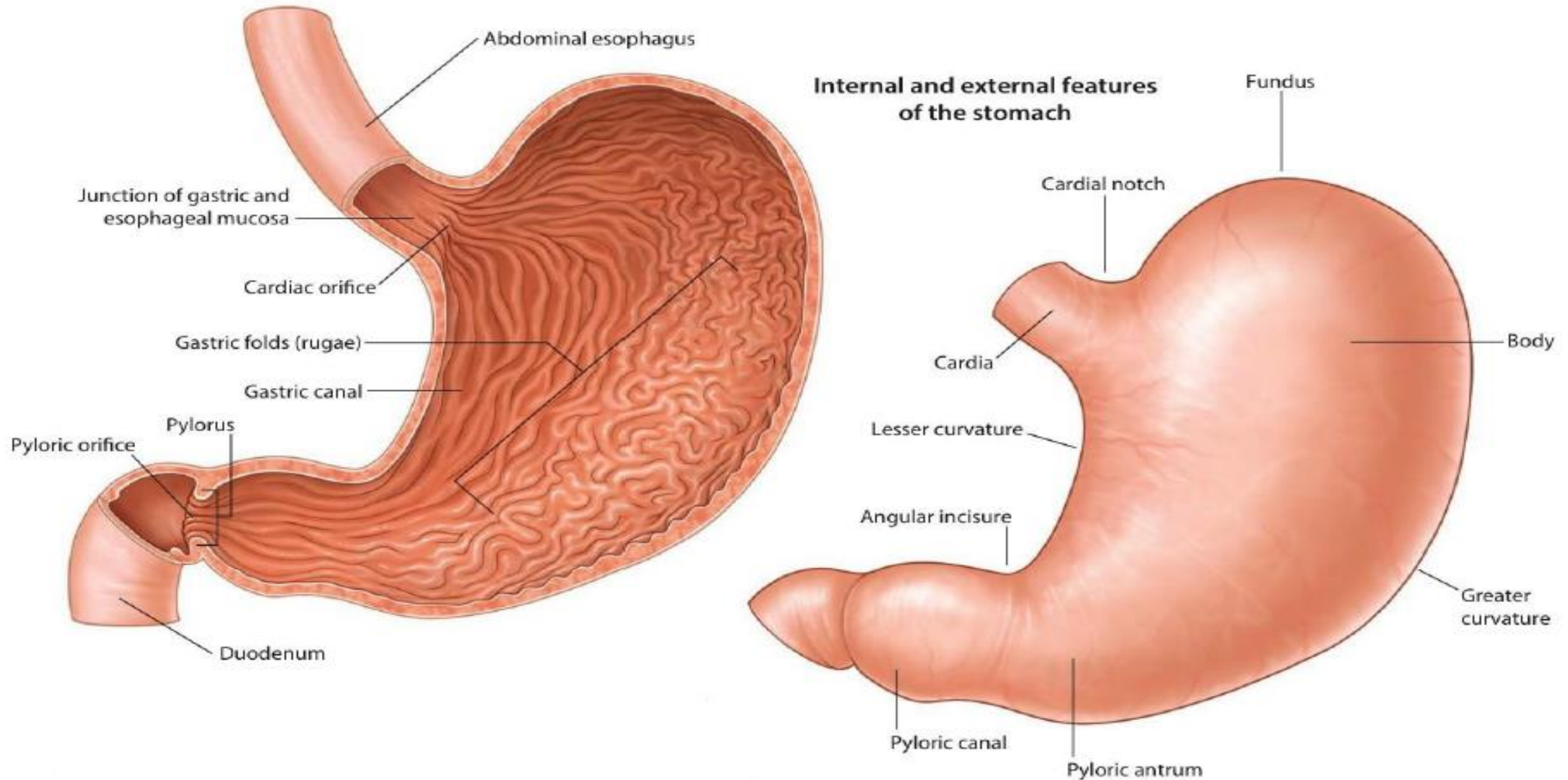
- >The esophagus is supplied by parasympathetic and sympathetic efferent and afferent fibers via the vagi and sympathetic trunks.
- Notice the gastroesophageal sphincter and the esophageal constrictions



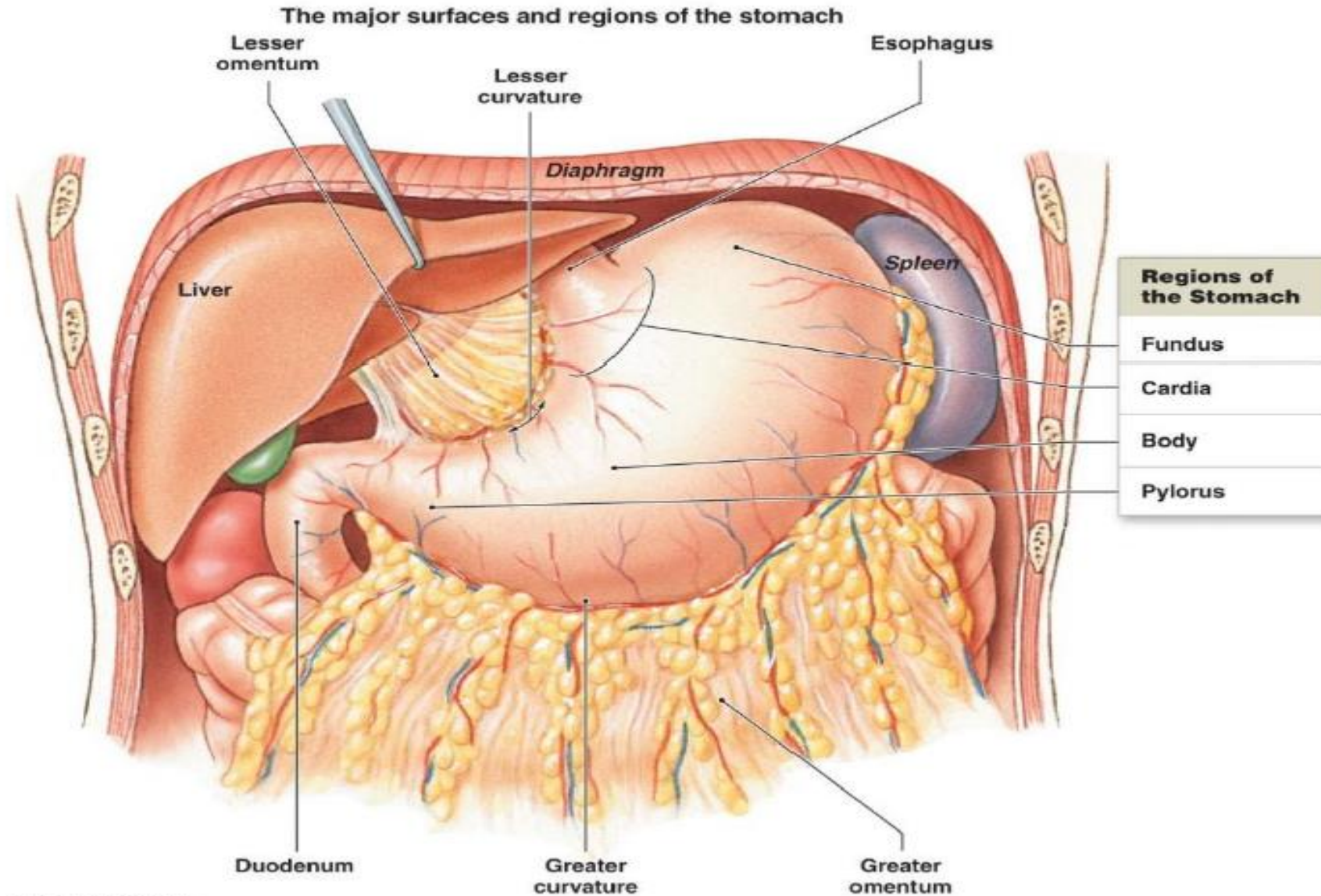
## ✱ Stomach.

- The students should know and identify :
  1. Parts, Surfaces, curvature and Orifices.  
of the stomach
  2. Omenta of the stomach
  3. Relations of the stomach
  4. Blood supply of the stomach
  5. Venous and lymphatic drainage of the stomach
  6. Nerve supply of the stomach

# 1. Parts, Surfaces, curvature and Orifices of the stomach

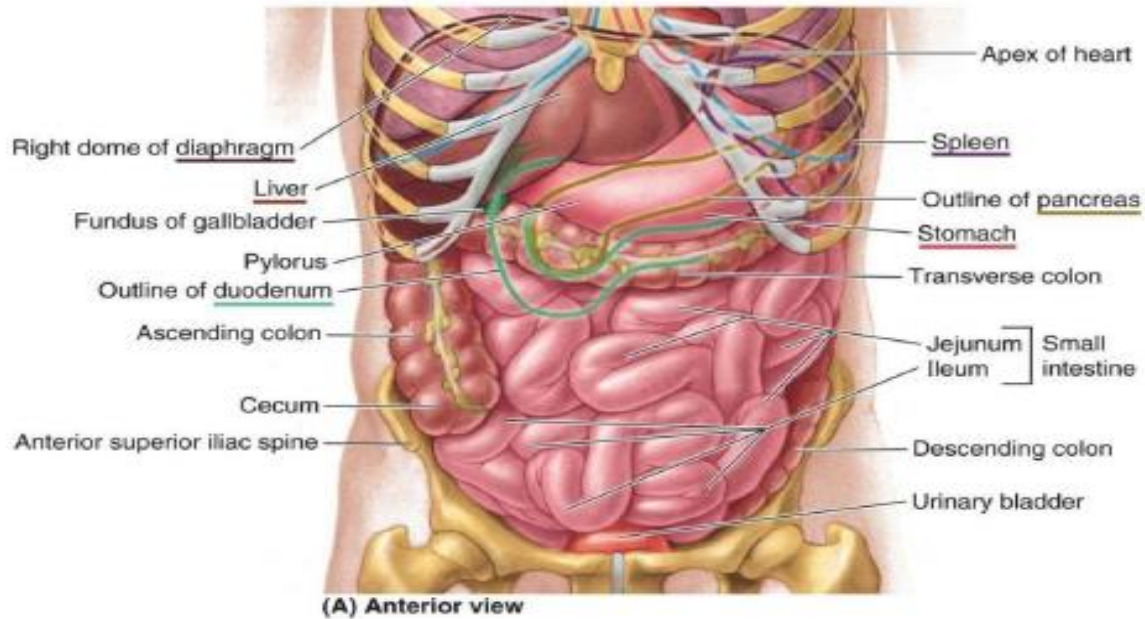


## 2. Omenta of the stomach

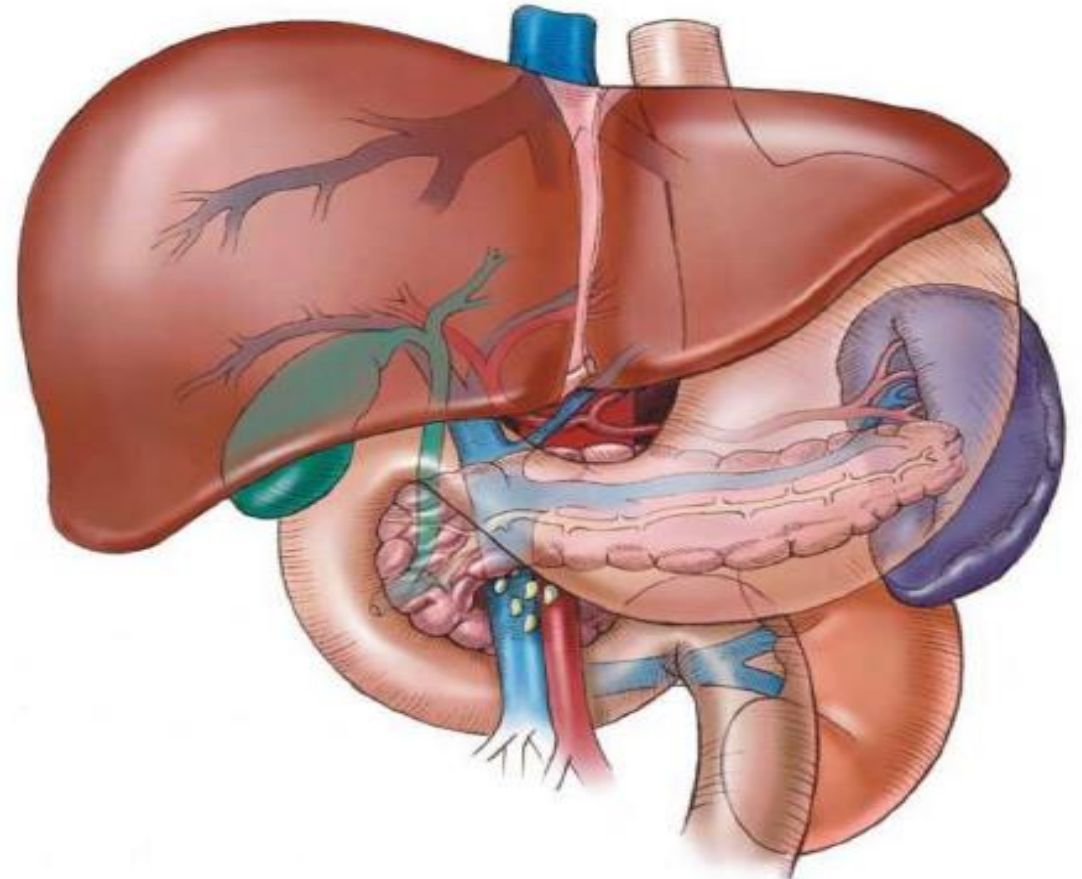


# 3. Relations of the stomach

- Anterior- superior

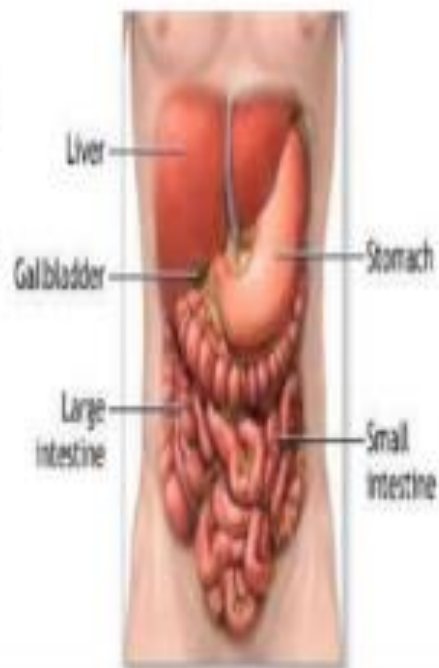

- Posteriorly = stomach bed



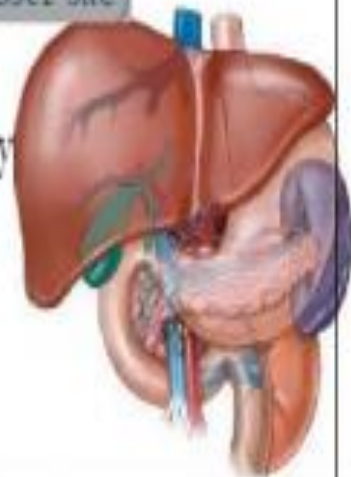
## ANTERIOR- SUPERIOR

- The anterior abdominal wall
- the left costal margin
- the left pleura and lung
- the diaphragm
- the left lobe of the liver

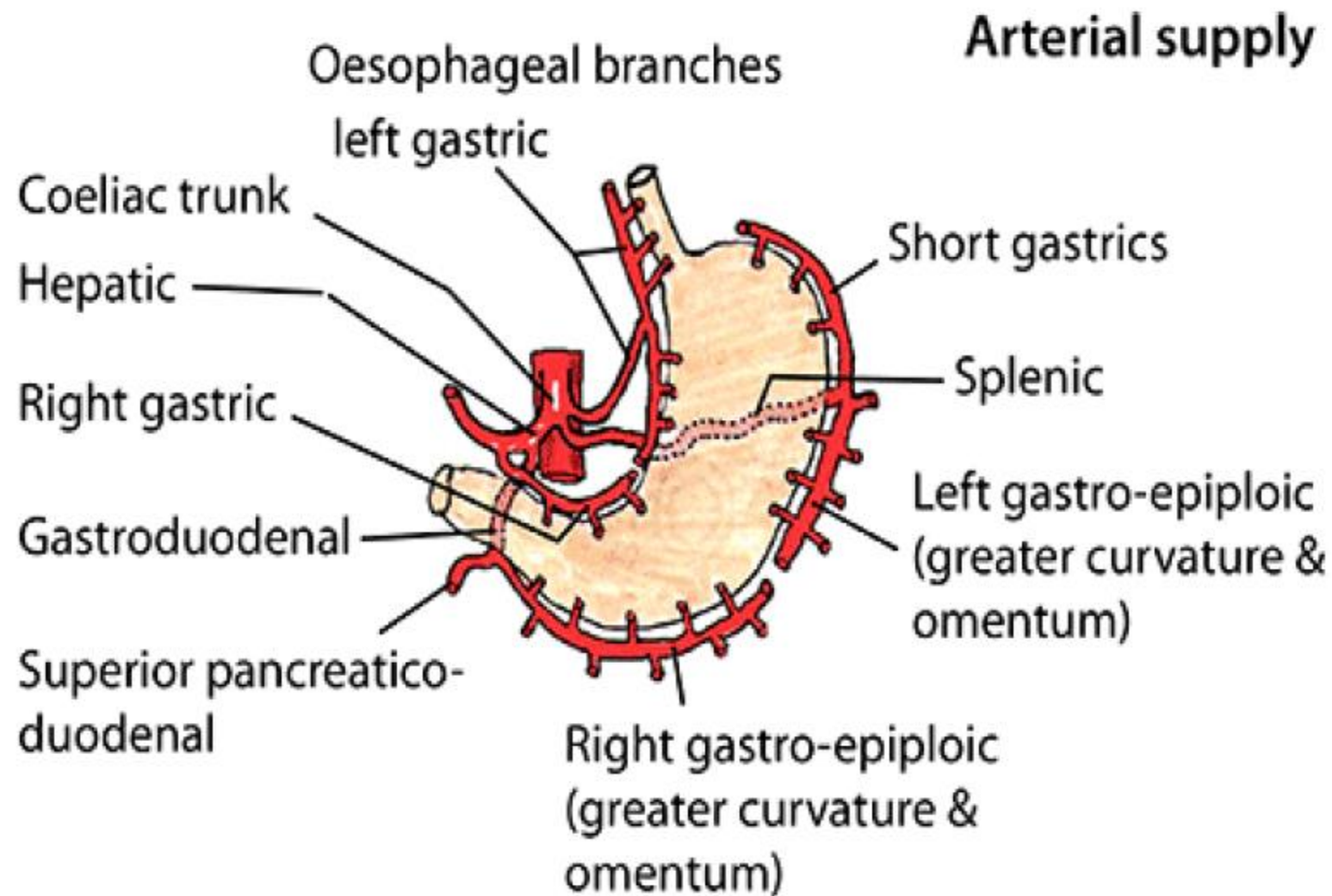


## POSTERIORLY = STOMACH BED

- The lesser sac
- the left crus of diaphragm
- the spleen (as angle, part ant. and part post. and form the left boundary of the lesser sac)
- the left suprarenal gland
- the upper part of the left kidney
- the splenic artery
- the body of pancreas
- the transverse mesocolon
- the transverse colon

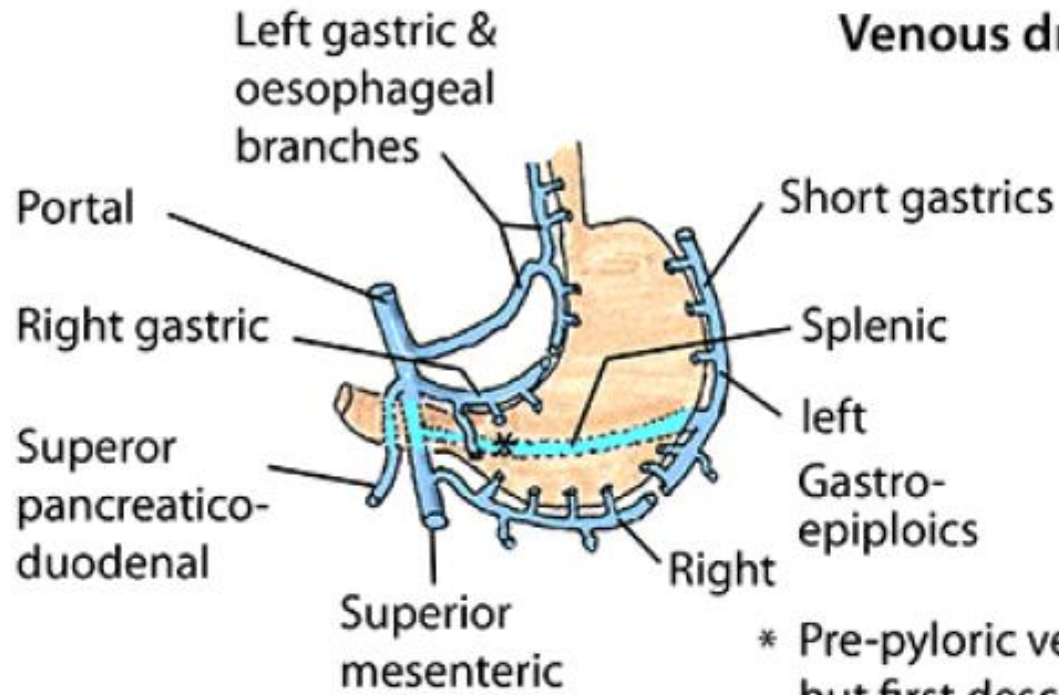


## 4. Blood supply of the stomach

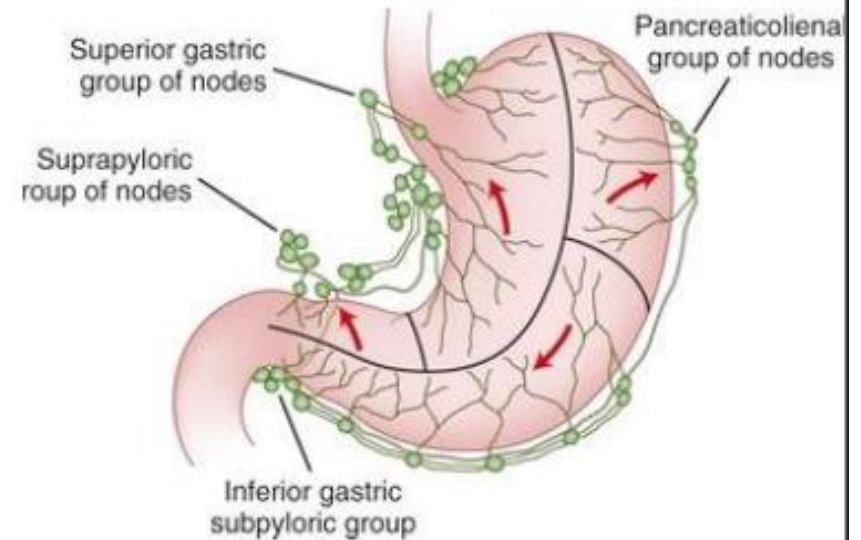


# 5. Venous and lymphatic drainage of the stomach

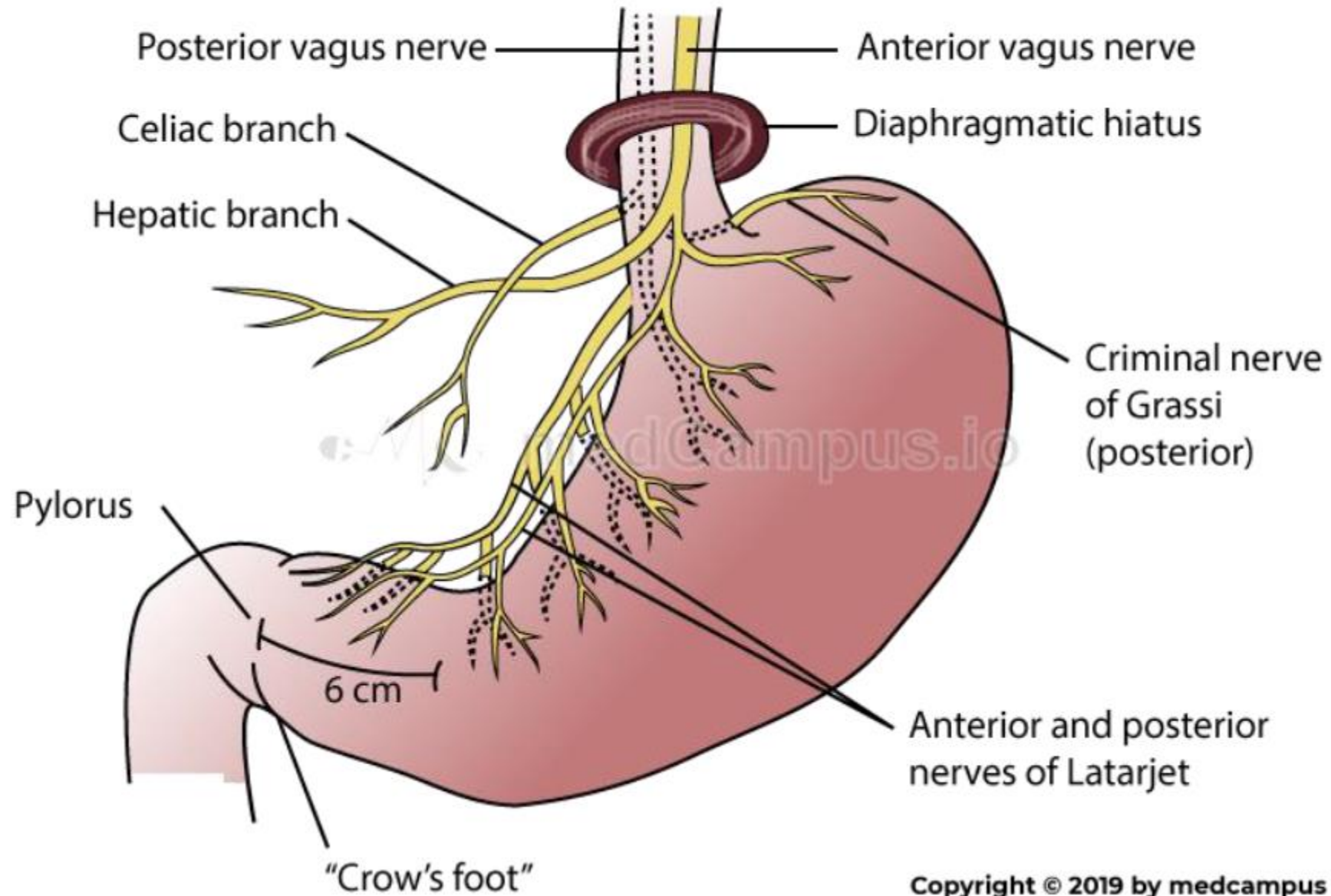
## Venous drainage



\* Pre-pyloric vein of Mayo but first described by Laterjet



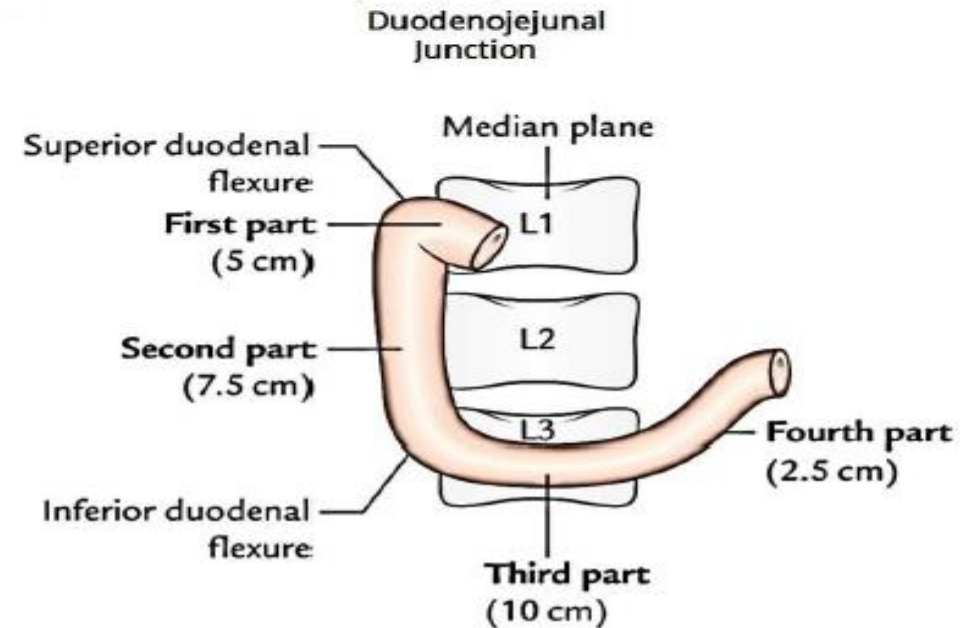
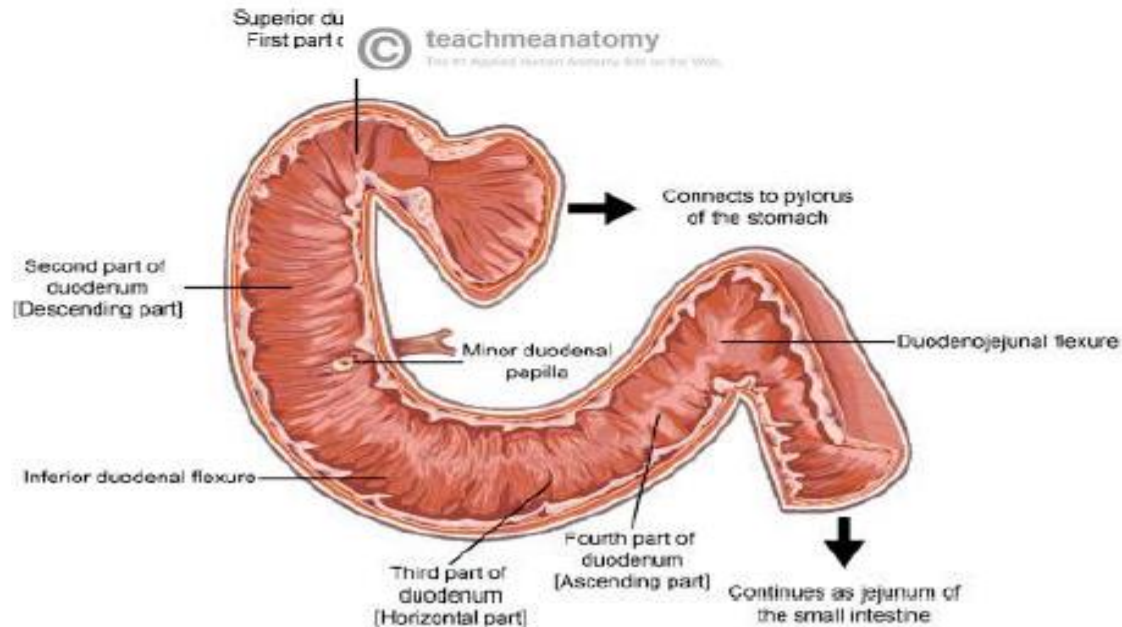
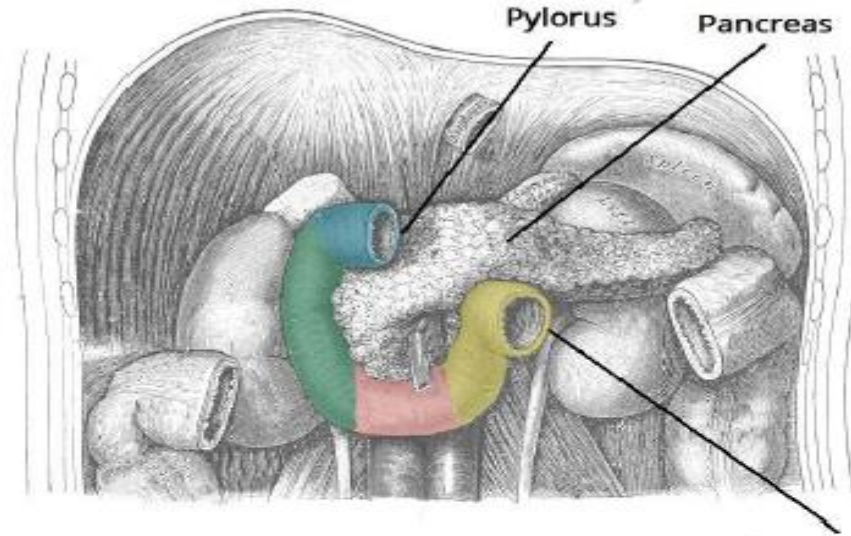
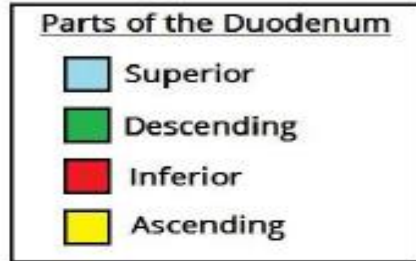
## 6. Nerve supply of the stomach



## ✦ Duodenum.

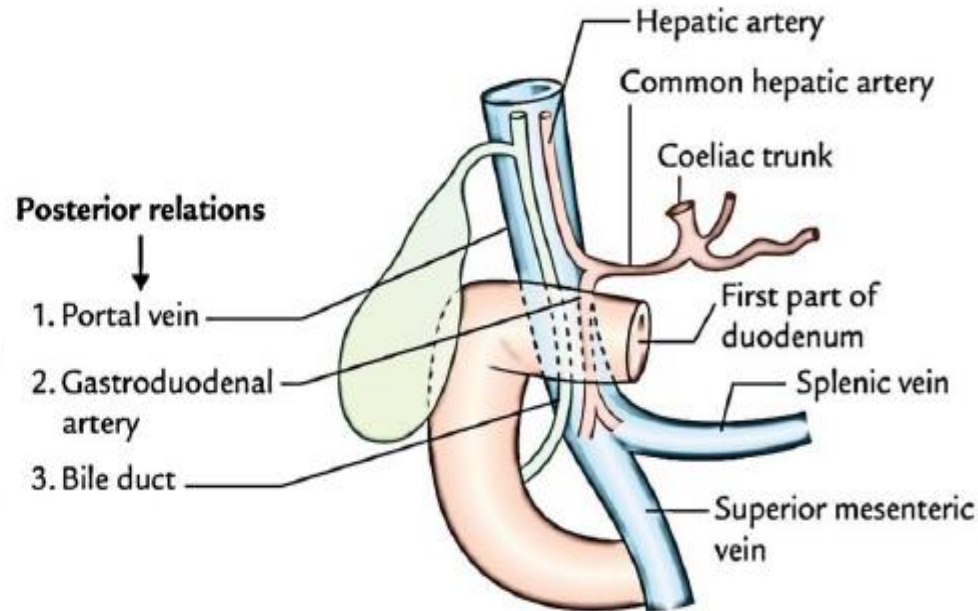
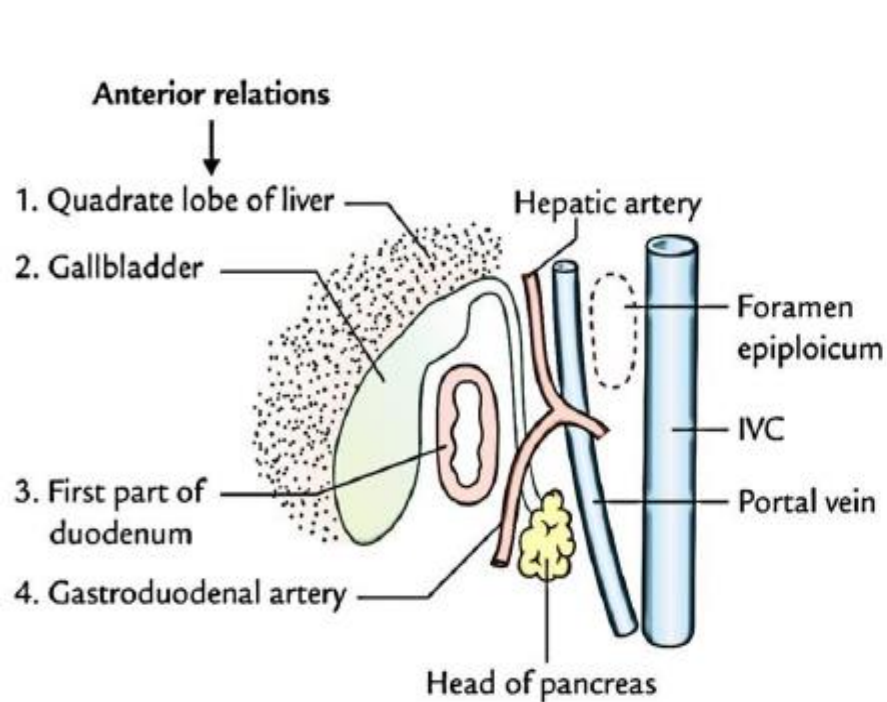
- The students should know and identify :
  1. Parts, Site and length of the duodenum
  2. Relations of the duodenum
  3. Blood supply of the duodenum
  4. Venous and lymphatic drainage of the duodenum

# 1. Parts, Site and length of the duodenum



## 2. Relations of the duodenum

### • Relations of the First Part of the Duodenum

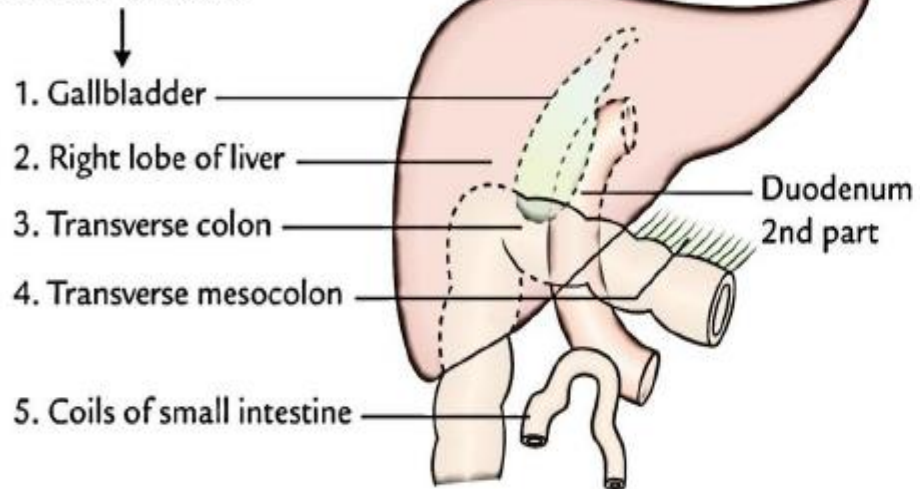


- >The first part begins from the pyloduodenal junction. At the level of the transpyloric line.
  - >Runs upward and backward at the level of the 1st lumbar vertebra 1 inch to the right.
- Relations of the first part:
- Anteriorly: The liver (quadratus lobe), The gall bladder
  - Superiorly: The epiploic foramen
  - Posteriorly: The lesser sac, the bile duct, the portal vein, Inferior vena cava, gastroduodenal Artery (if there is a peptic ulcer on the posterior wall of the 1st inch perforation and infiltration may occur along with bleeding from this artery)
  - Inferiorly: The head of the pancreas

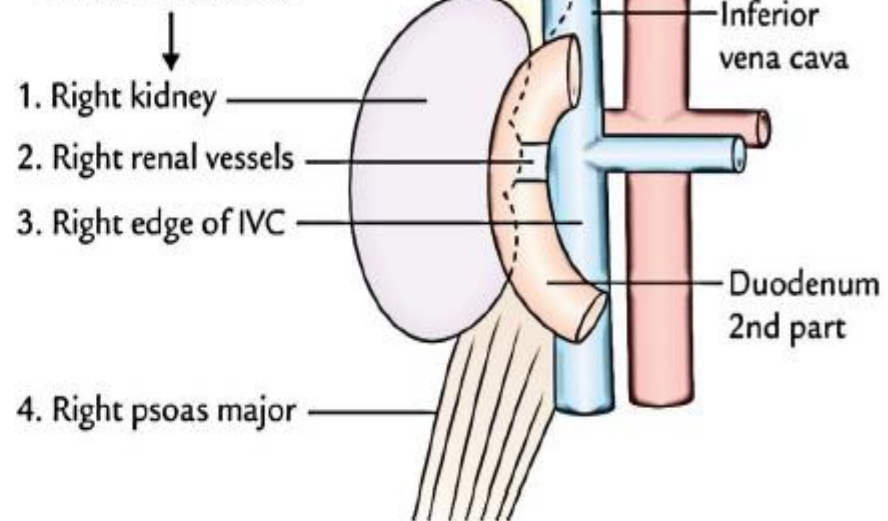
## 2. Relations of the duodenum

### • Relations of the Second Part of the Duodenum

#### Anterior relations



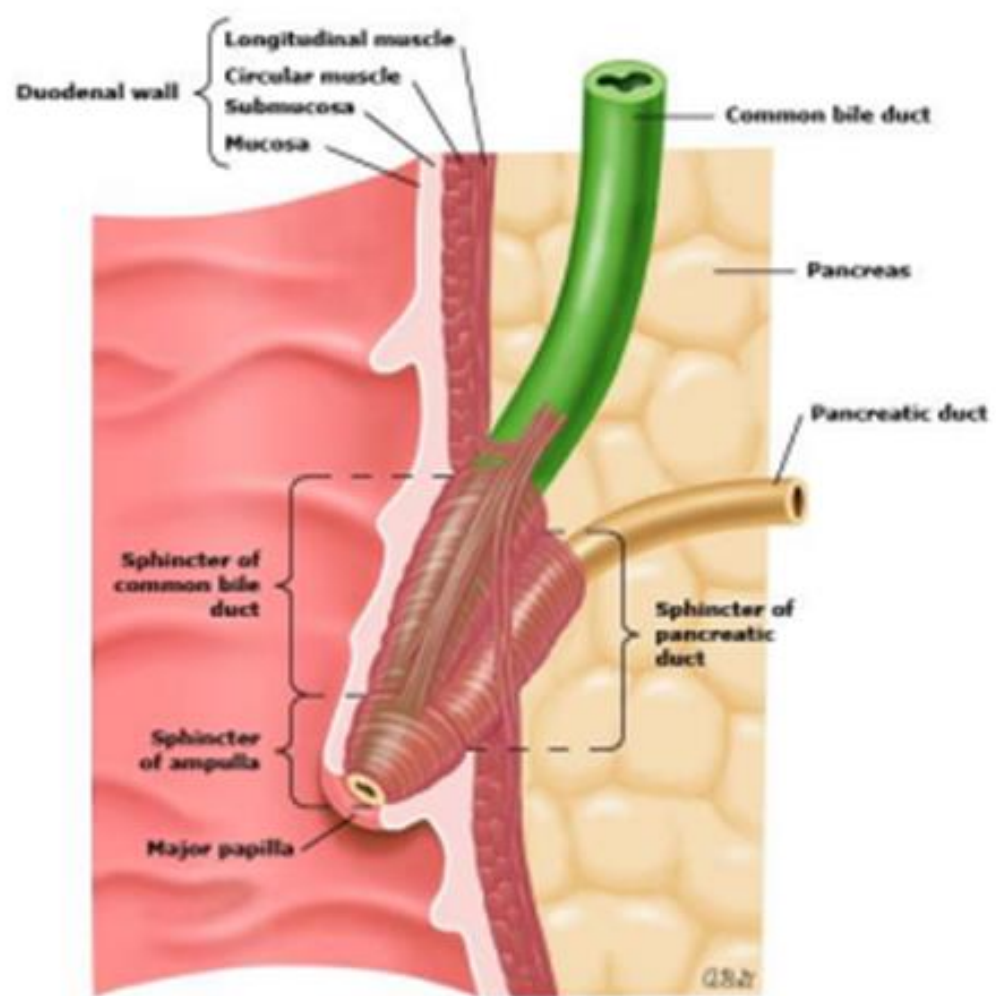
#### Posterior relations



Importance of the 2nd part: it receives the common bile and pancreatic ducts.

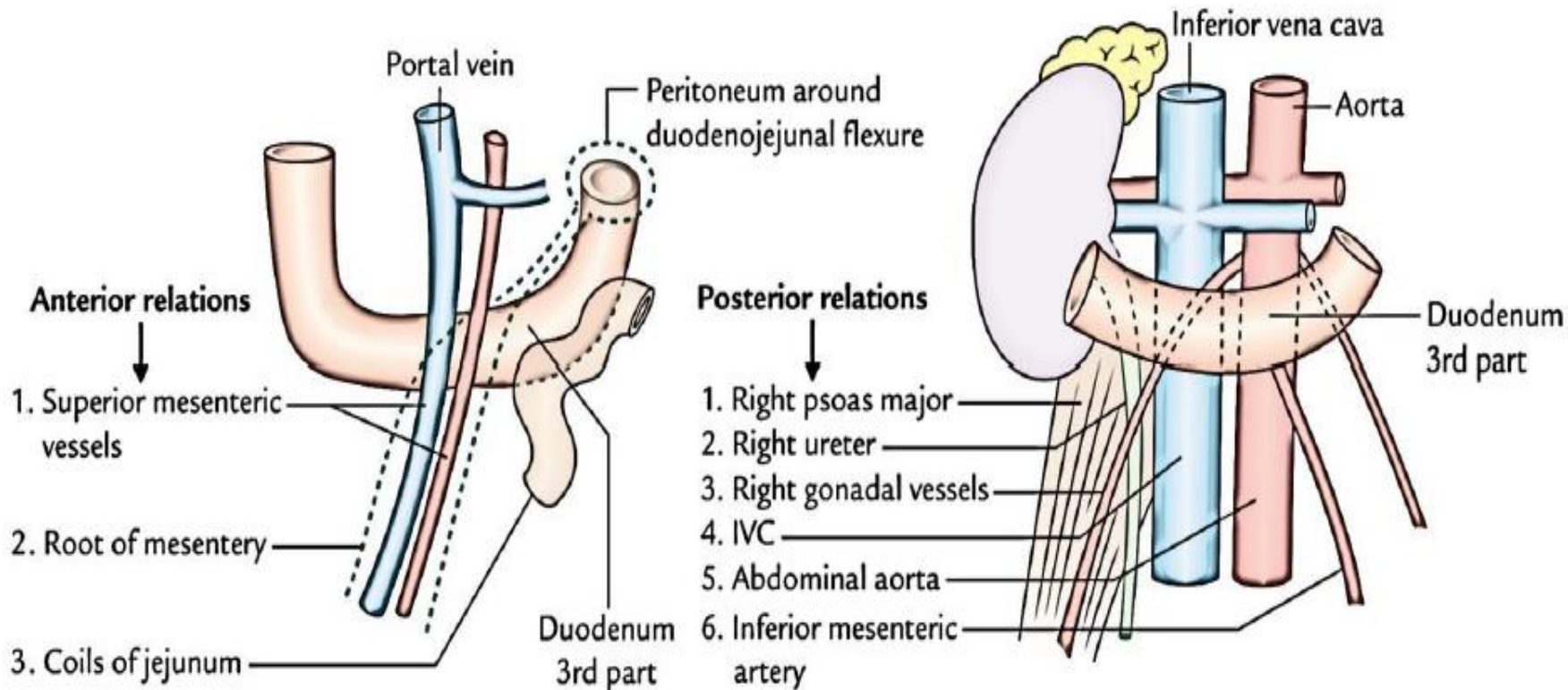
Relations of the second part:

- Anteriorly: The gallbladder (fundus), the right lobe of the liver, the transverse colon, the coils of small intestine
- Posteriorly: Hilum of the right kidney, the right ureter
- Laterally: Right colic flexure, ascending colon, right lobe of the liver
- Medially: Head of the pancreas, Bile and pancreatic ducts



## 2. Relations of the duodenum

### • Relations of the Third Part of the Duodenum

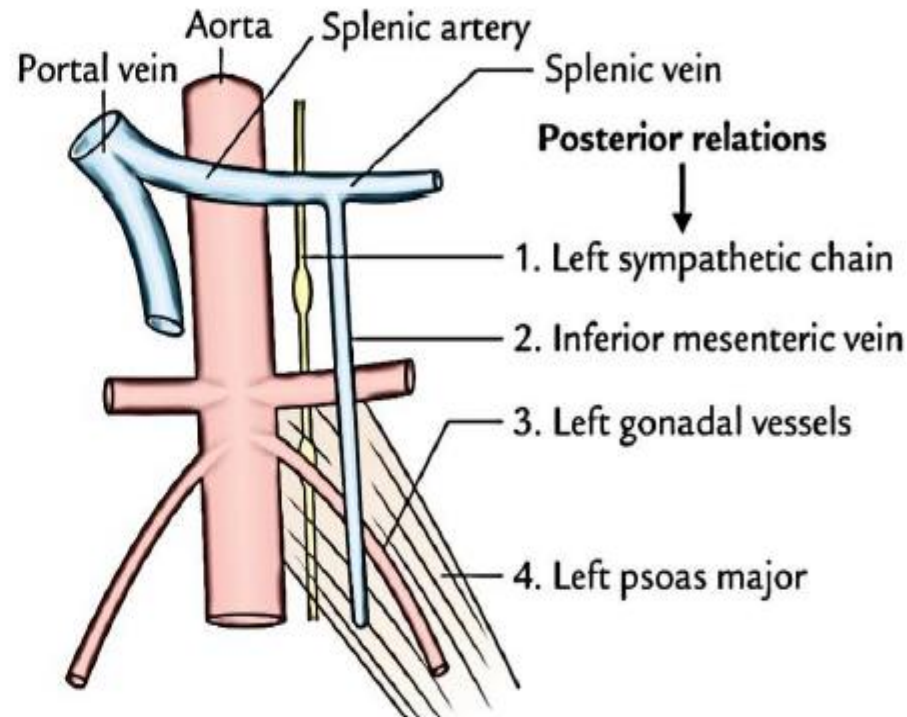
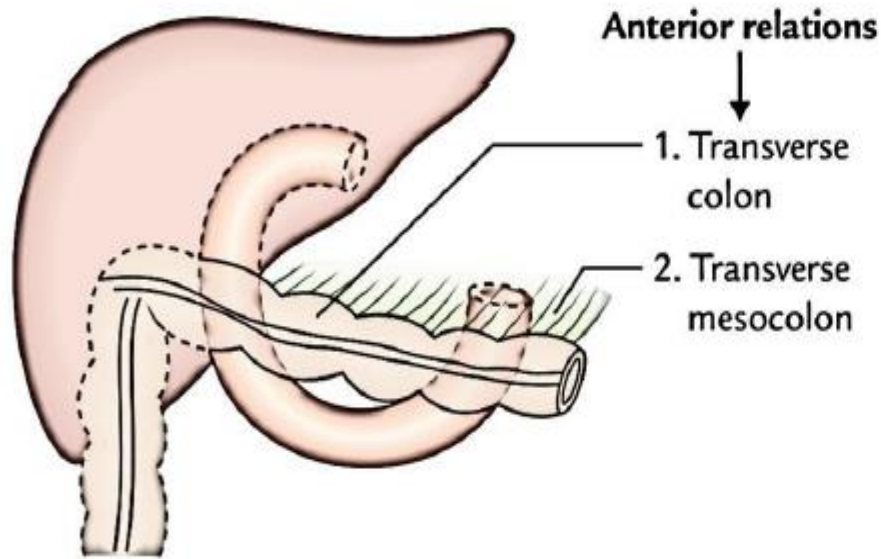


- Relations of the third part:
- Anteriorly: The root of the mesentery of the small intestine, the superior mesenteric vessels contained within the mesentery coils of the jejunum
  - Posteriorly: The right ureter, the right psoas muscle, the inferior vena cava, the aorta
  - Superiorly: The head of pancreas
  - Inferiorly: Coils of jejunum
- Part of the Duodenum (1inch)
- >Runs upward to the left
  - >Ends in the duodenojejunal junction at the level of the 2nd lumbar vertebrae 1 inch to the left.
  - >The junction (flexure) is held in position by the ligament of Treitz, which is attached to the right crus of the diaphragm (duodenal recess).

## 2. Relations of the duodenum

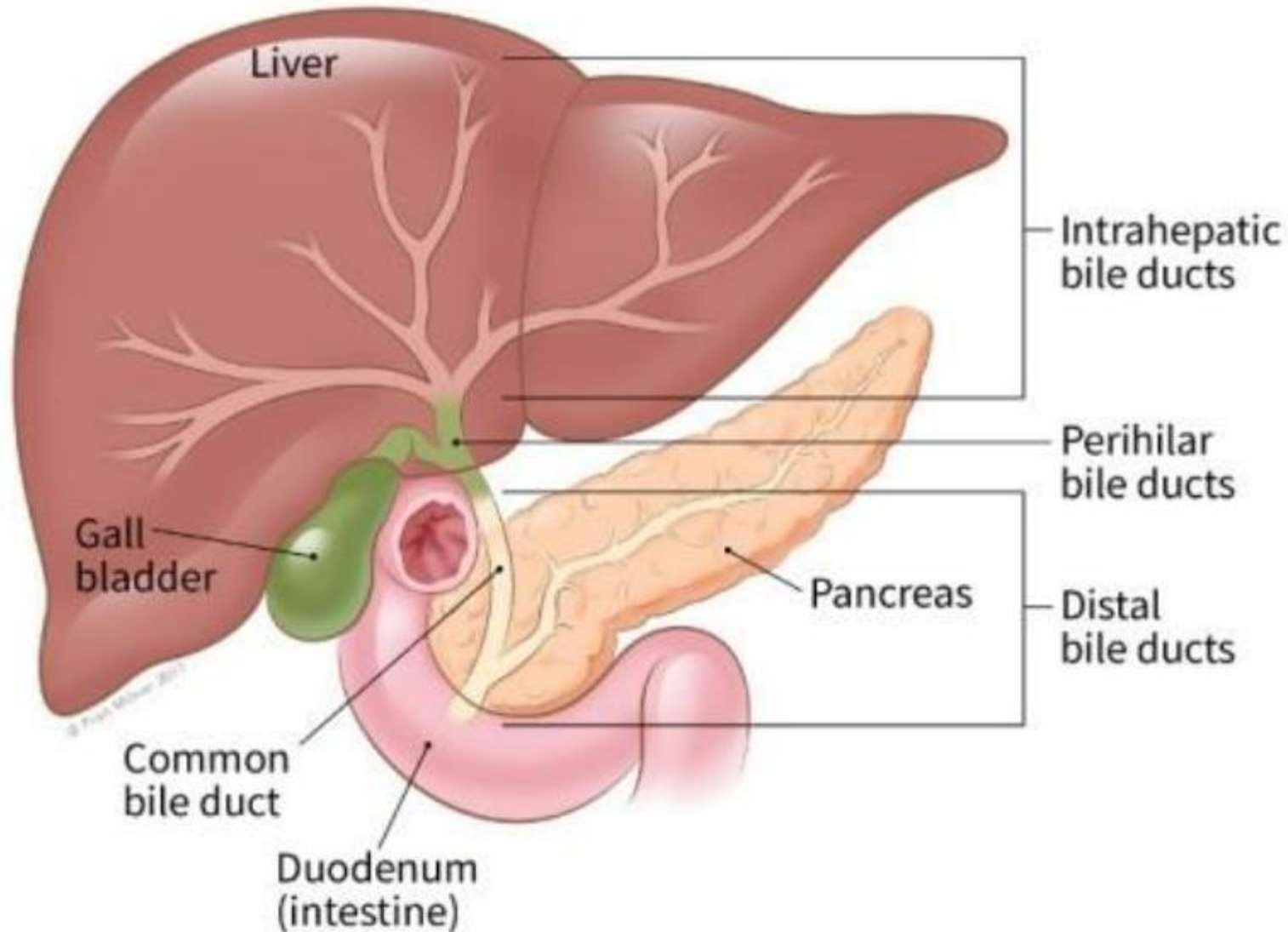
### • Relations of the Fourth Part of the Duodenum

- Relations of the fourth part:
- Anteriorly: The beginning of the root of the mesentery, Coils of the jejunum
  - Posteriorly: Left psoas major muscle, The sympathetic chain on the left margin of the aorta
  - Superiorly: Uncinate process of the pancreas

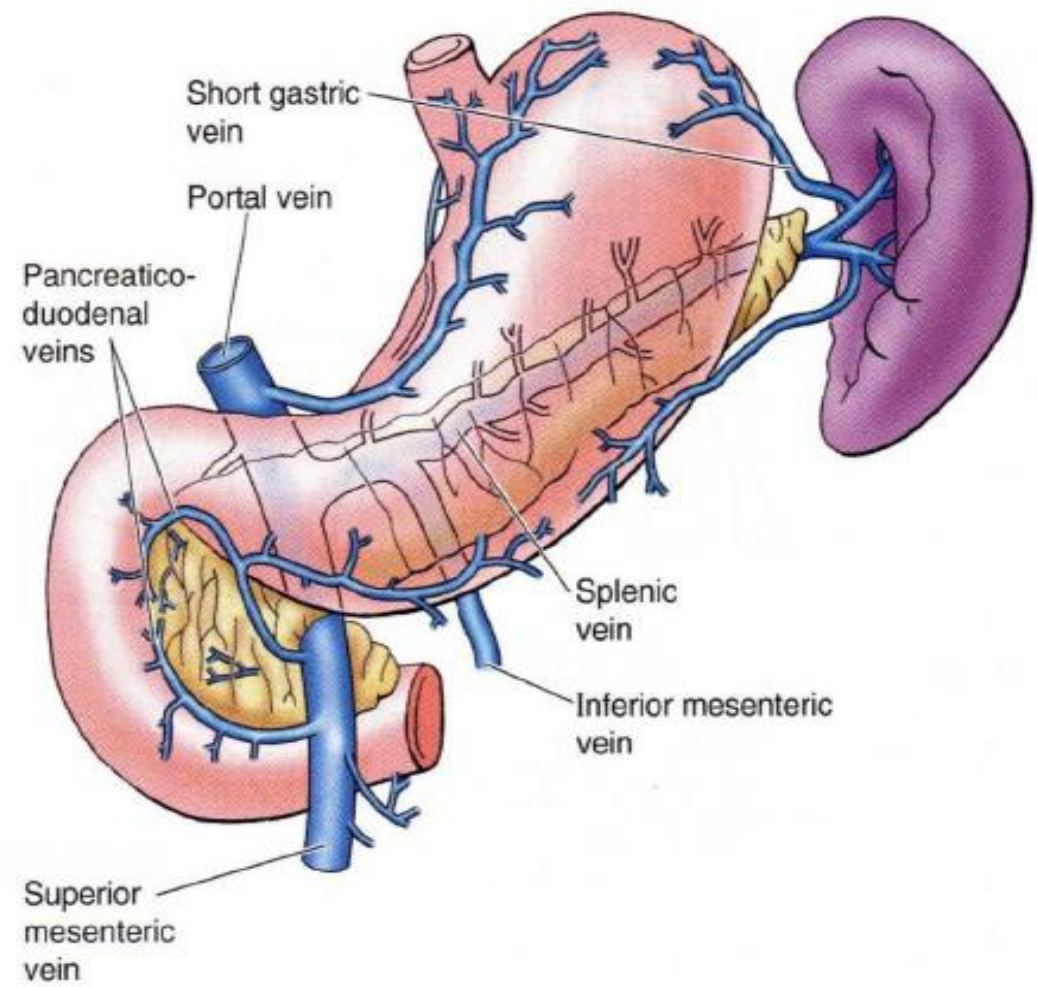
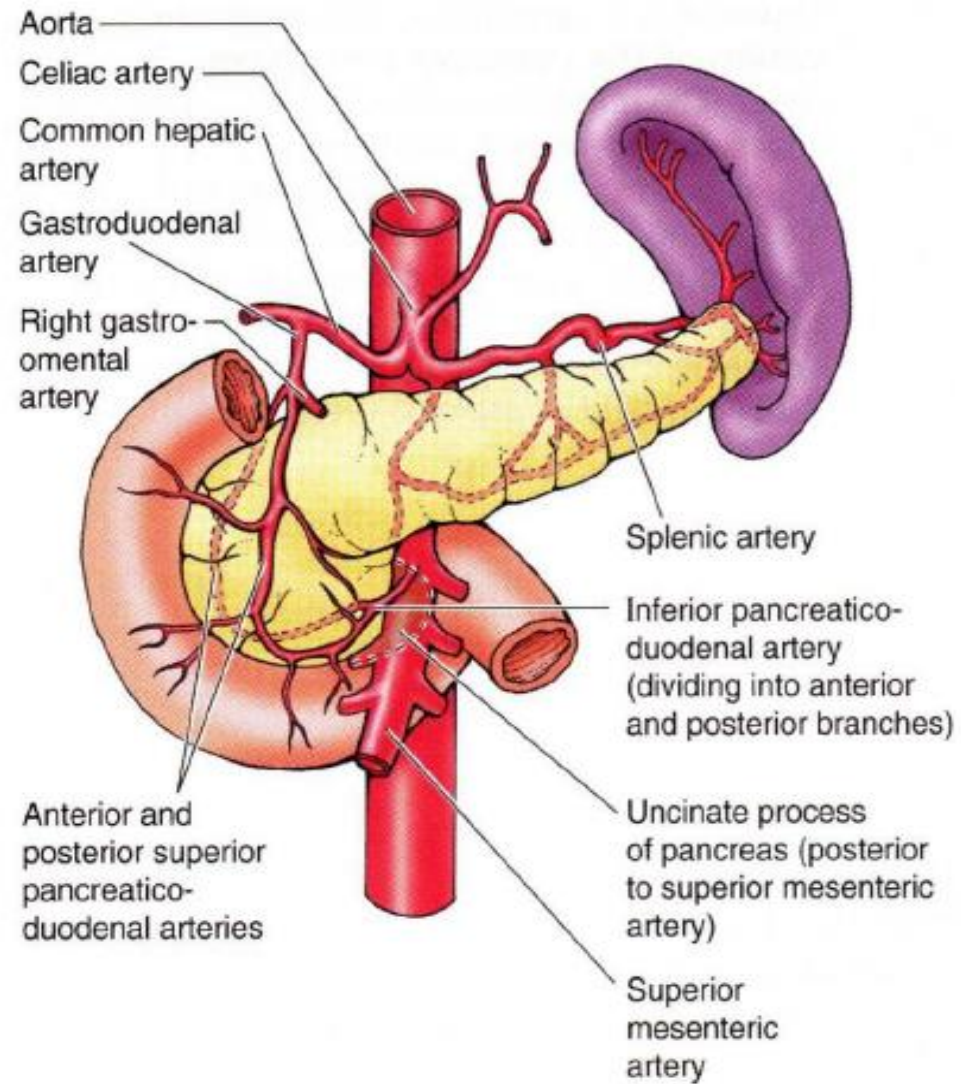


## 2. Relations of the duodenum

- Relations of pancreas and bile ducts to the Duodenum



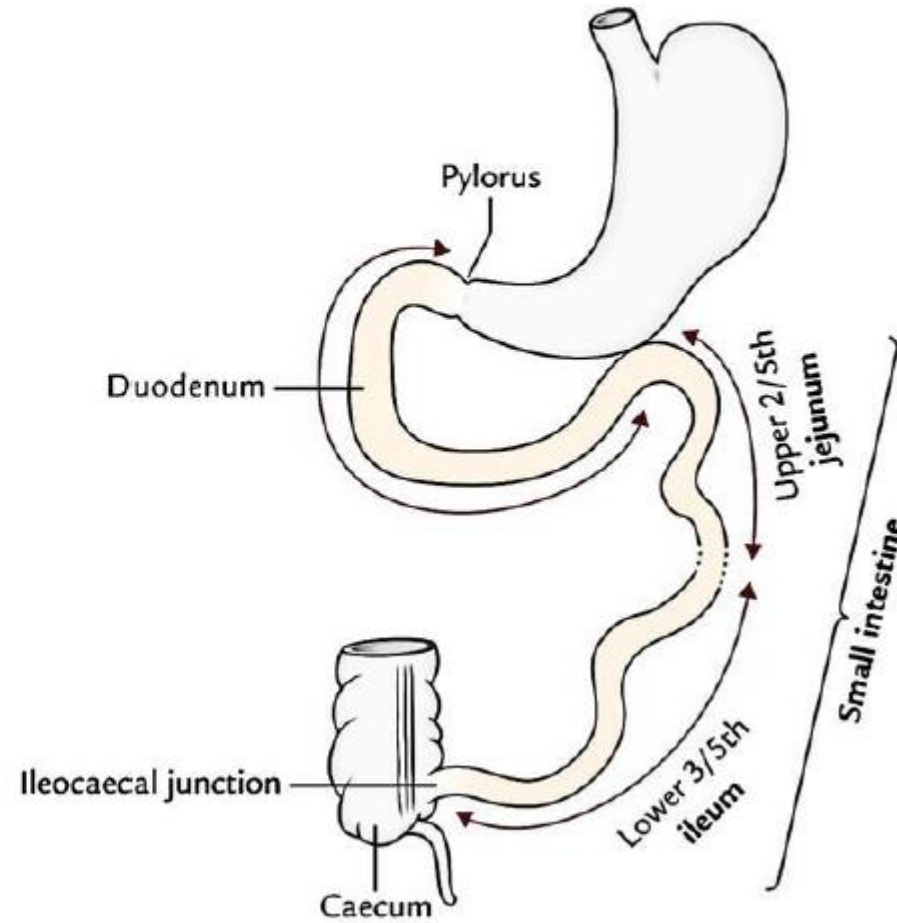
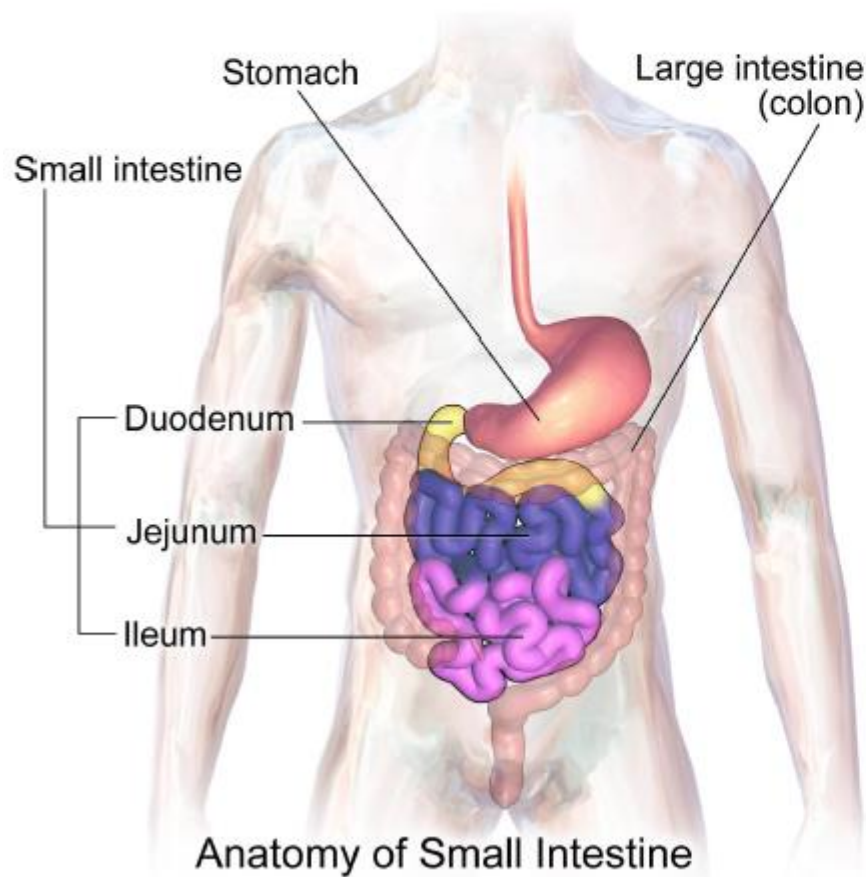
# 3. Blood supply and Venous drainage of the duodenum



## ✱ Jejunum and Ileum.

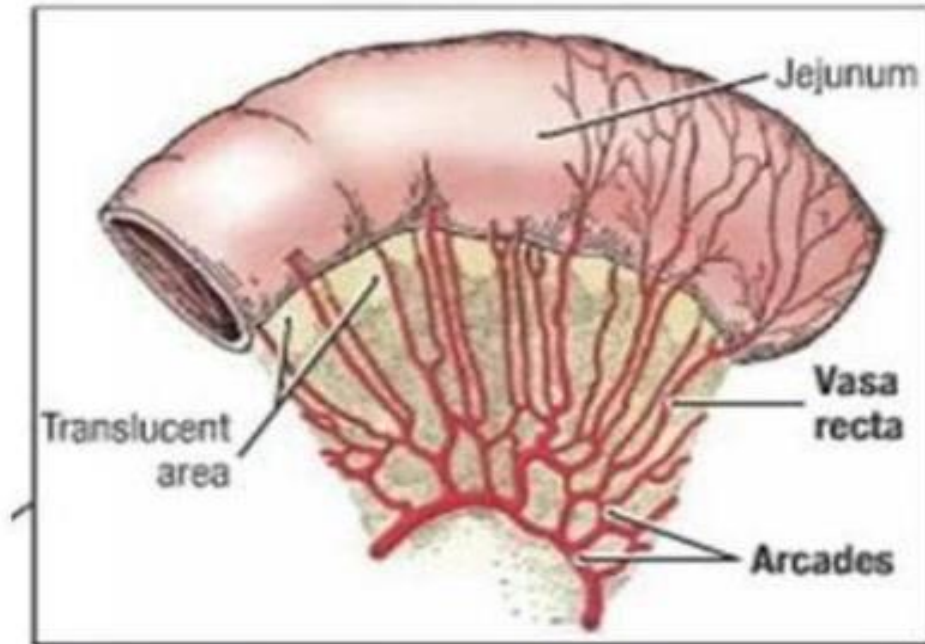
- The students should know and identify :
  1. Site and length of the Jejunum and Ileum.
  2. Differences between the Jejunum and Ileum.
  3. Blood supply of the Jejunum and Ileum.
  4. Venous and lymphatic drainage of Jejunum and Ileum.

# 1. Site and length of the Jejunum and Ileum



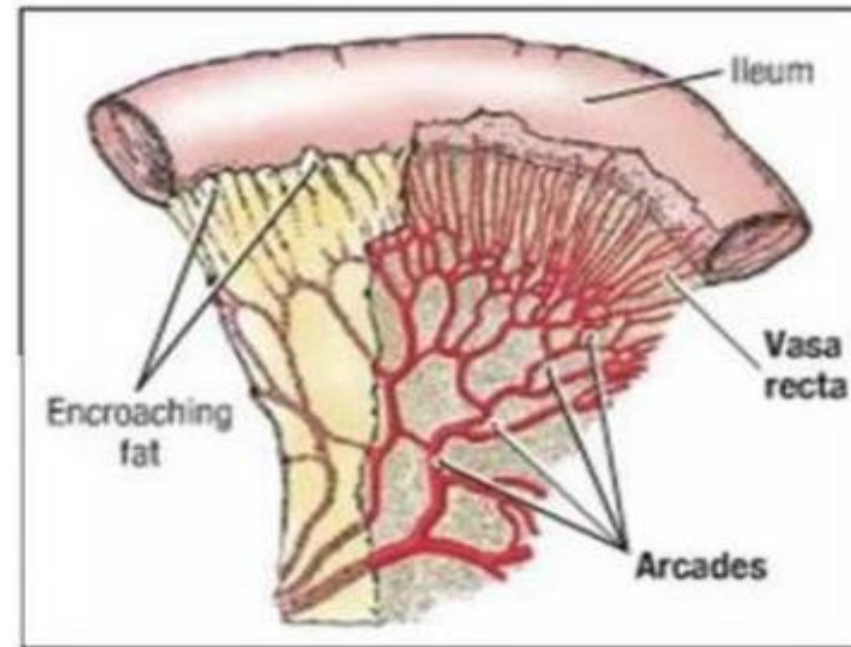
## 2. Differences between the Jejunum and Ileum

### Jejunum



- Less complex arterial arcades
- Longer Vasa Recta
- More plicae circulares, thicker, more highly folded
- No fat in mesentery

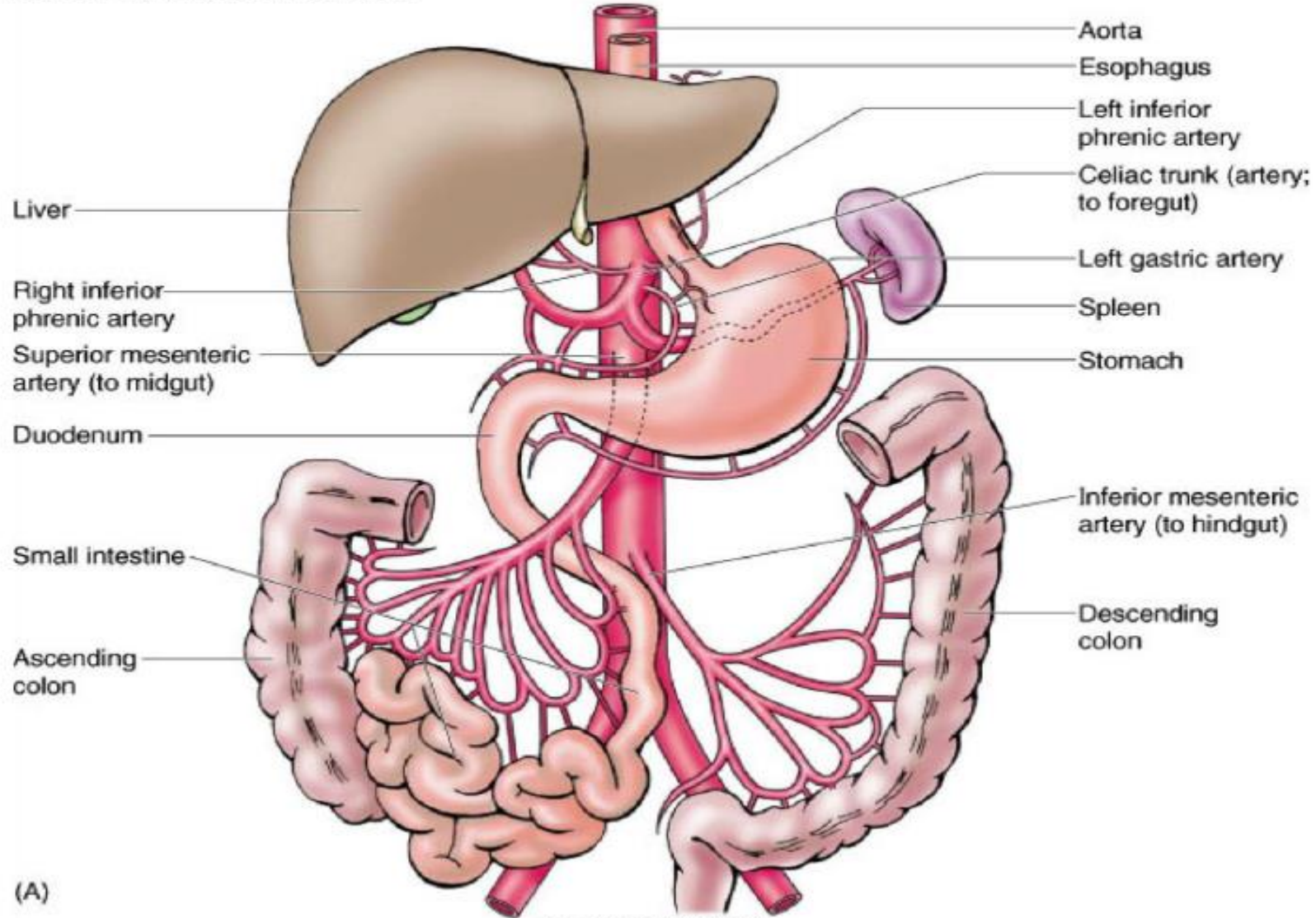
### Ileum



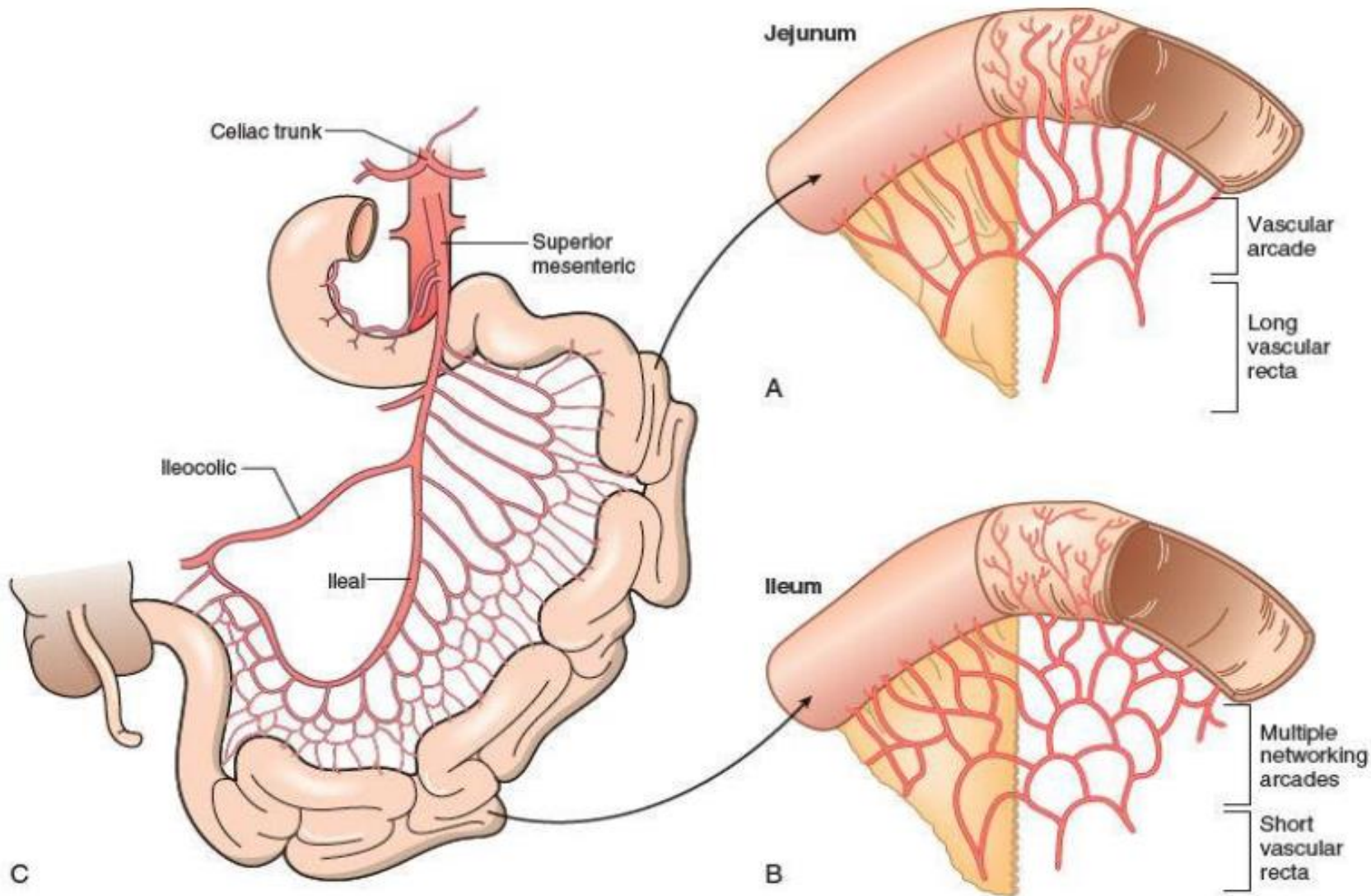
- More complex arterial arcades
- Shorter Vasa Recta
- Less plicae circulares, thinner less folded
- Fat present in mesentery

# 3. Blood supply of the Jejunum and Ileum

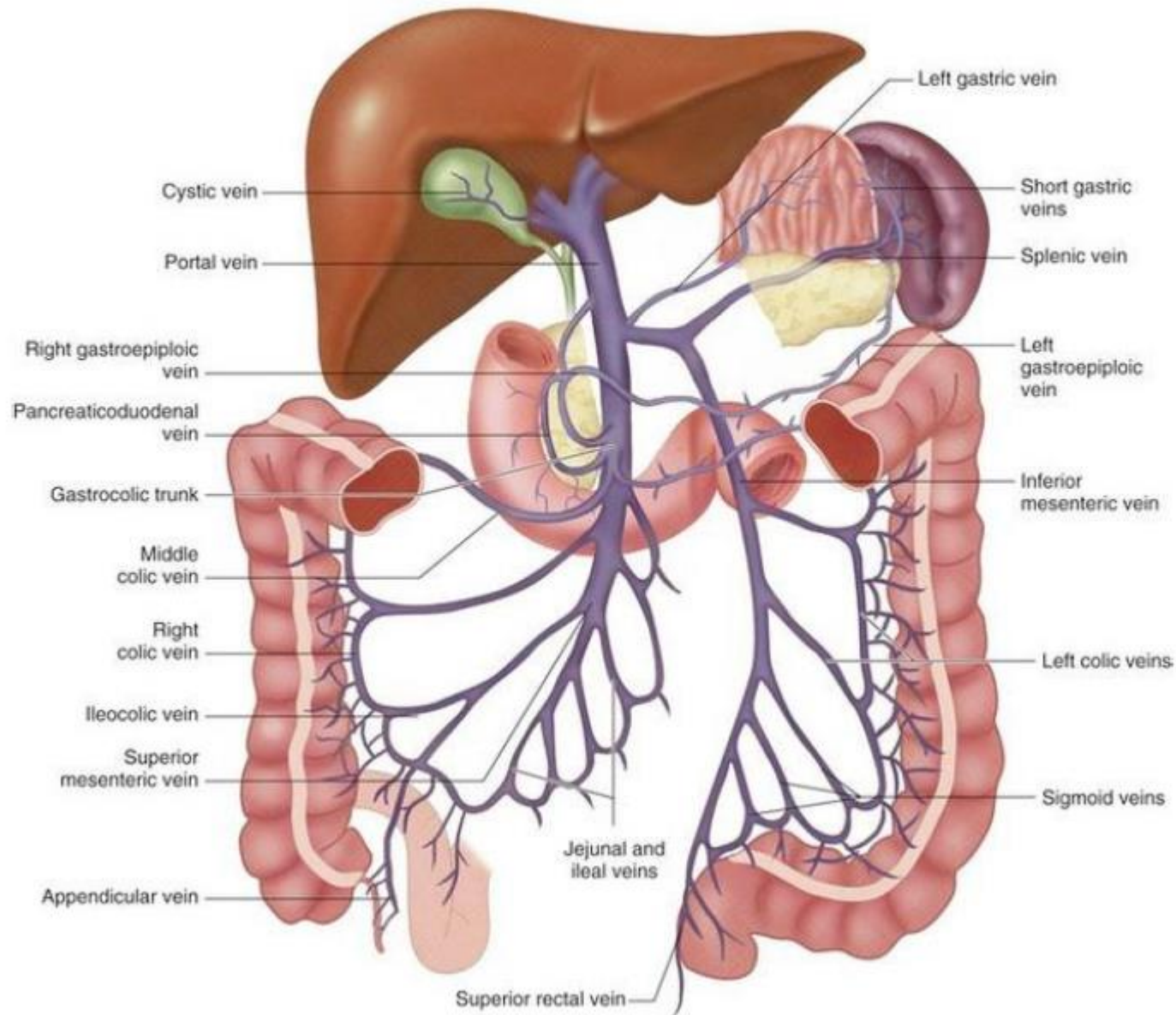
2.28. Arterial supply of the GI tract.



# 3. Blood supply of the Jejunum and Ileum



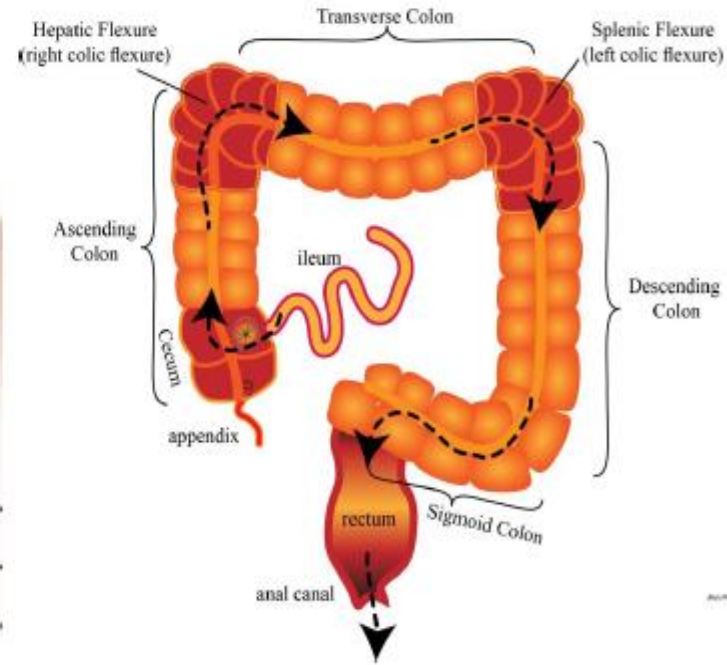
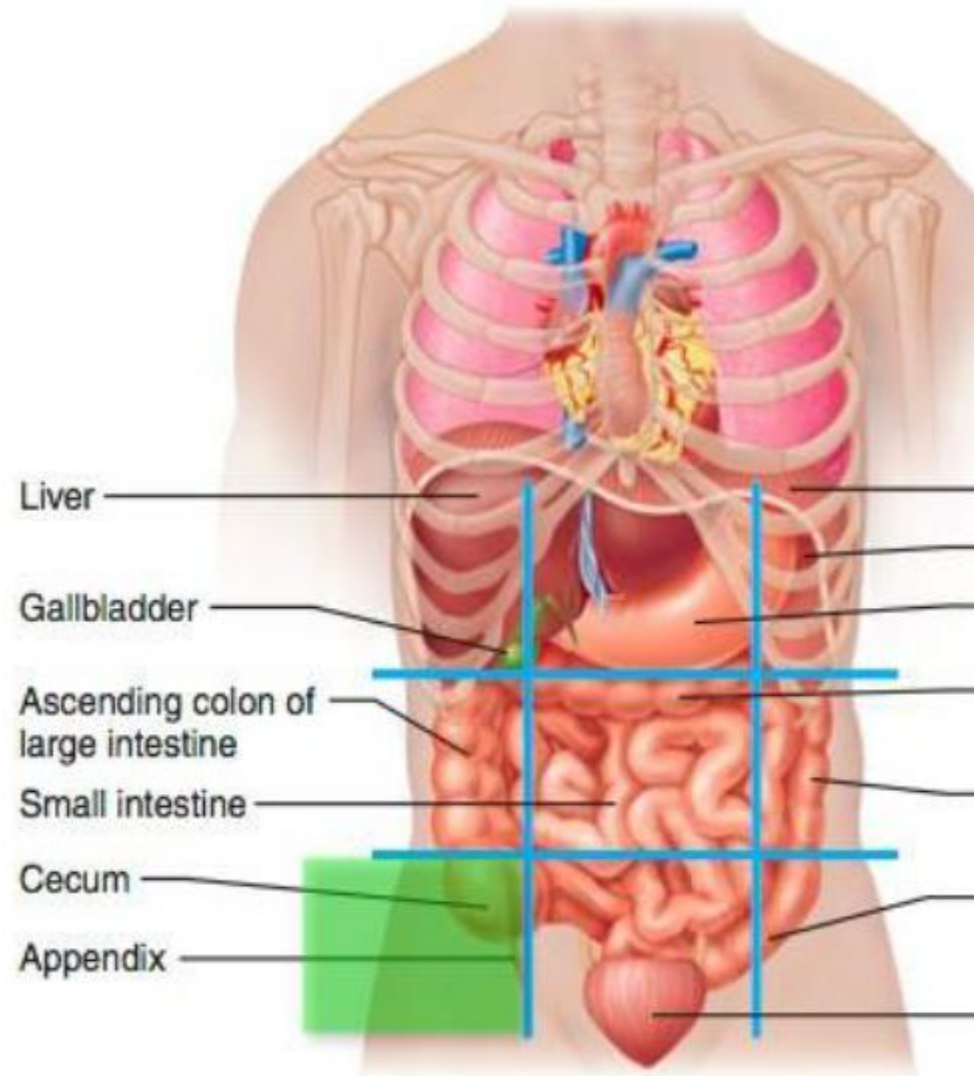
# 4. Venous drainage of the Jejunum and Ileum



## ✦ Cecum

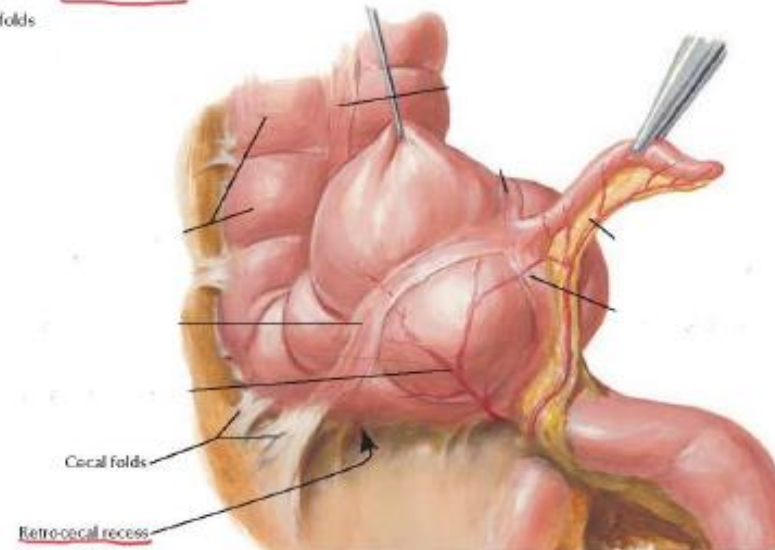
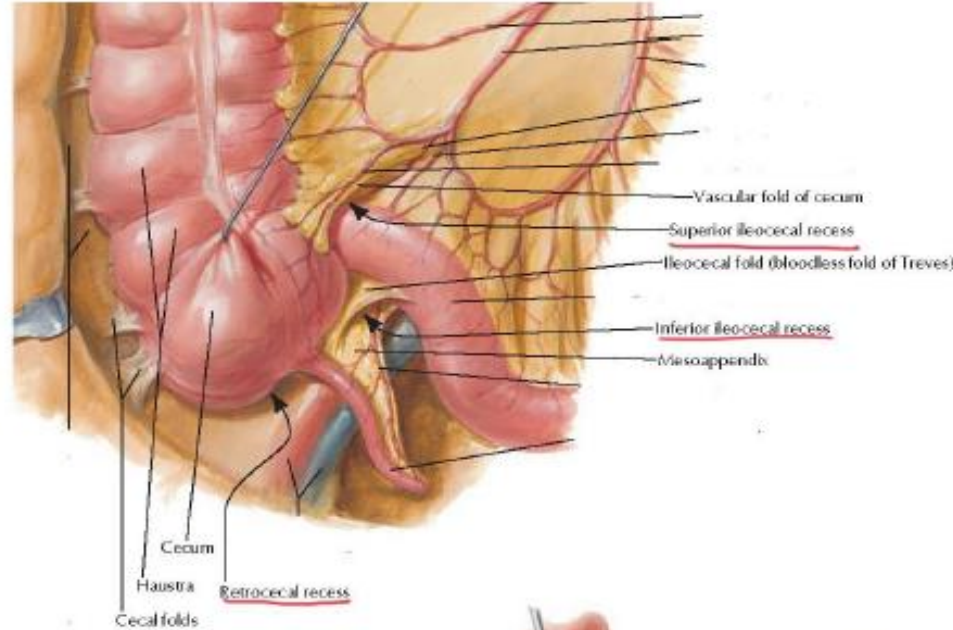
- The students should know and identify the :
  1. Site and Position
  2. Peritoneal Relations
  3. Features
  4. Relations
  5. Blood supply

# • Site and Position of the cecum

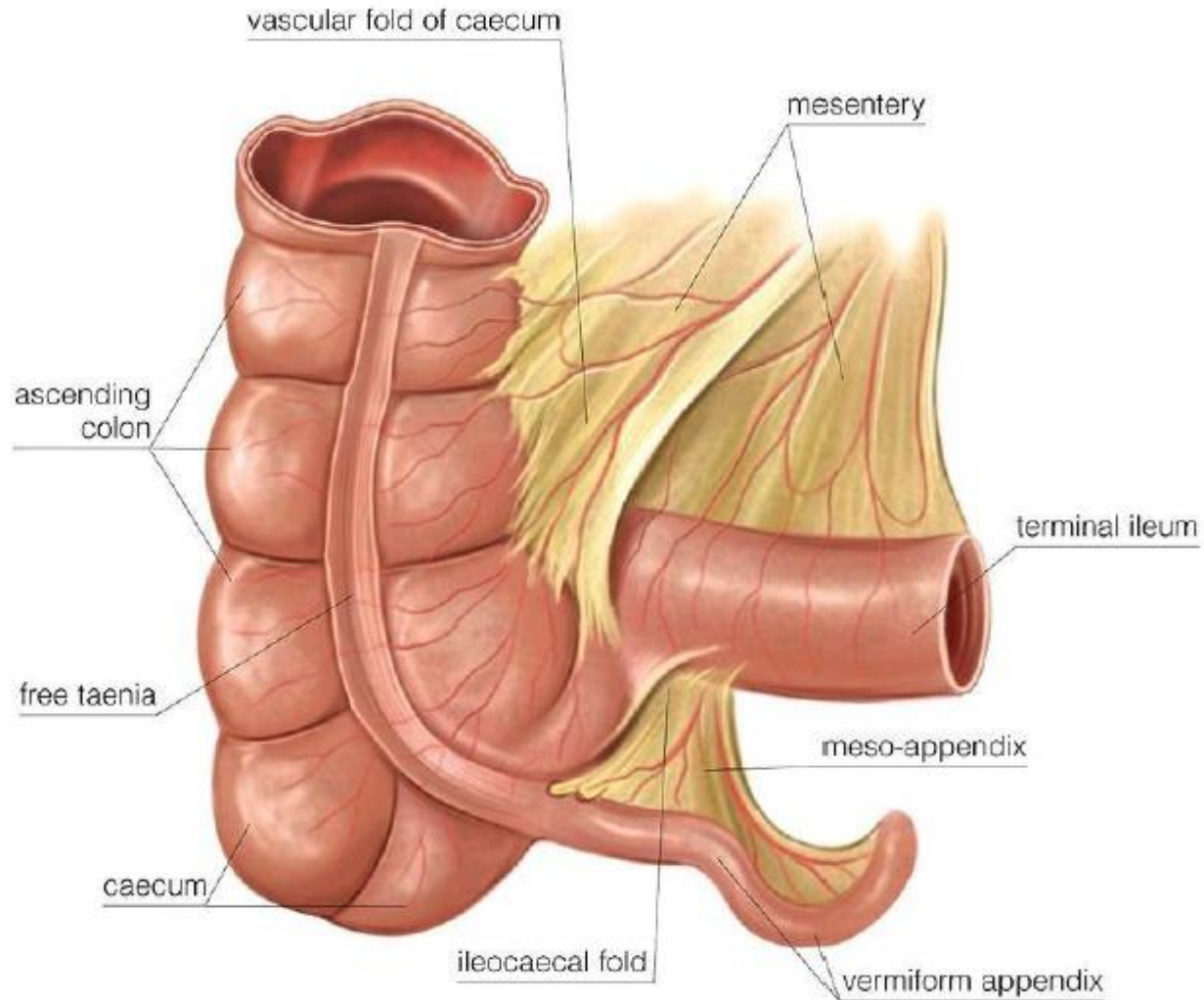


- Folds of peritoneum close to the cecum

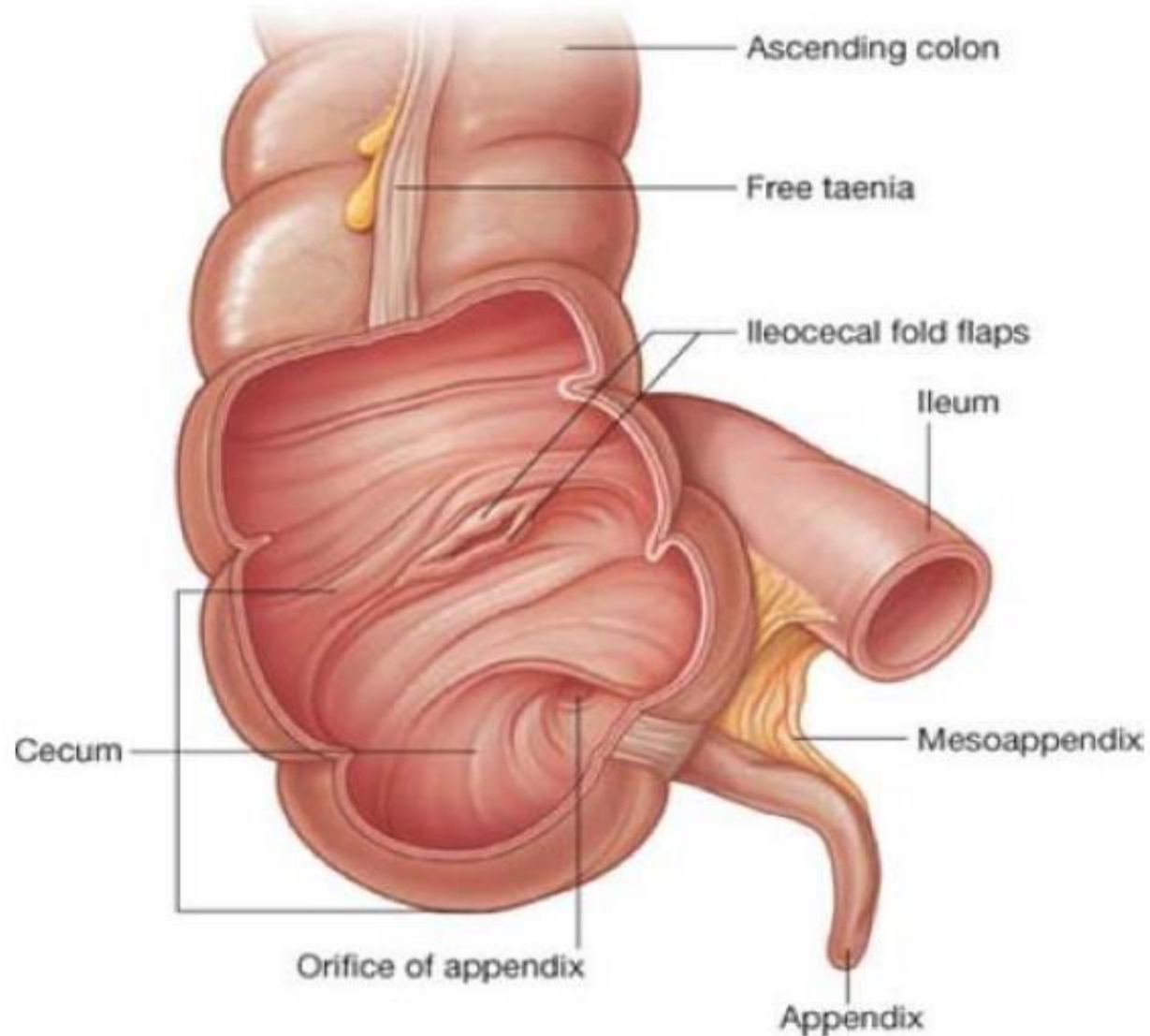
- The students should identify :
  1. superior ileocecal recesses
  2. inferior ileocecal recesses
  3. retrocecal recesses



- Taenia coli



- Ileocecal Valve



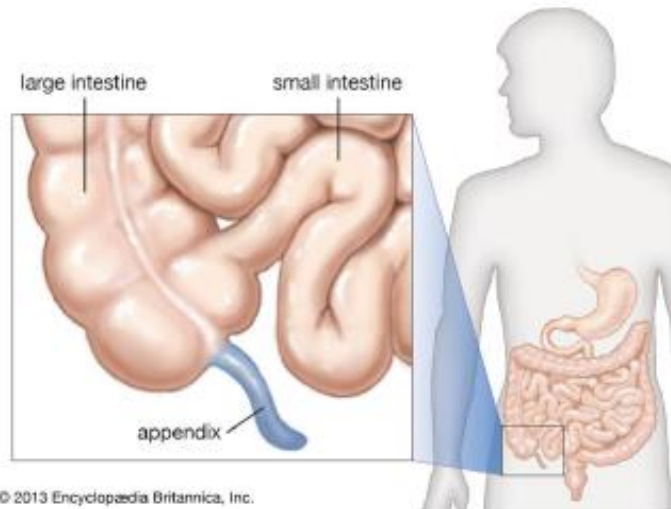
# • Relations of the cecum

- Anterior relations :

1. Coils of the small intestine.
2. Greater omentum.
3. Anterior abdominal wall (in the right iliac region)

- Medially:

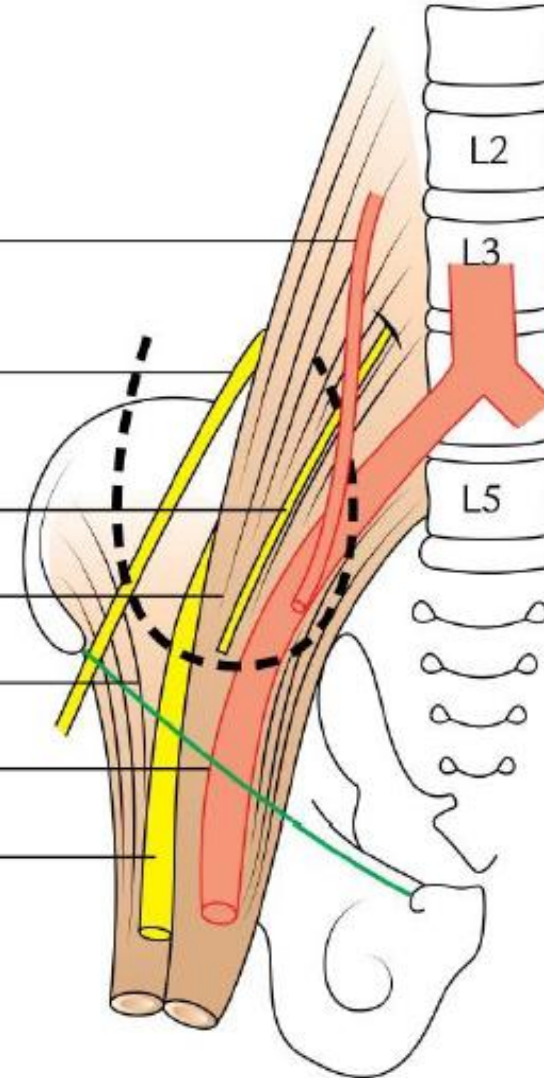
1. The appendix arises from the cecum on its medial side



© 2013 Encyclopædia Britannica, Inc.

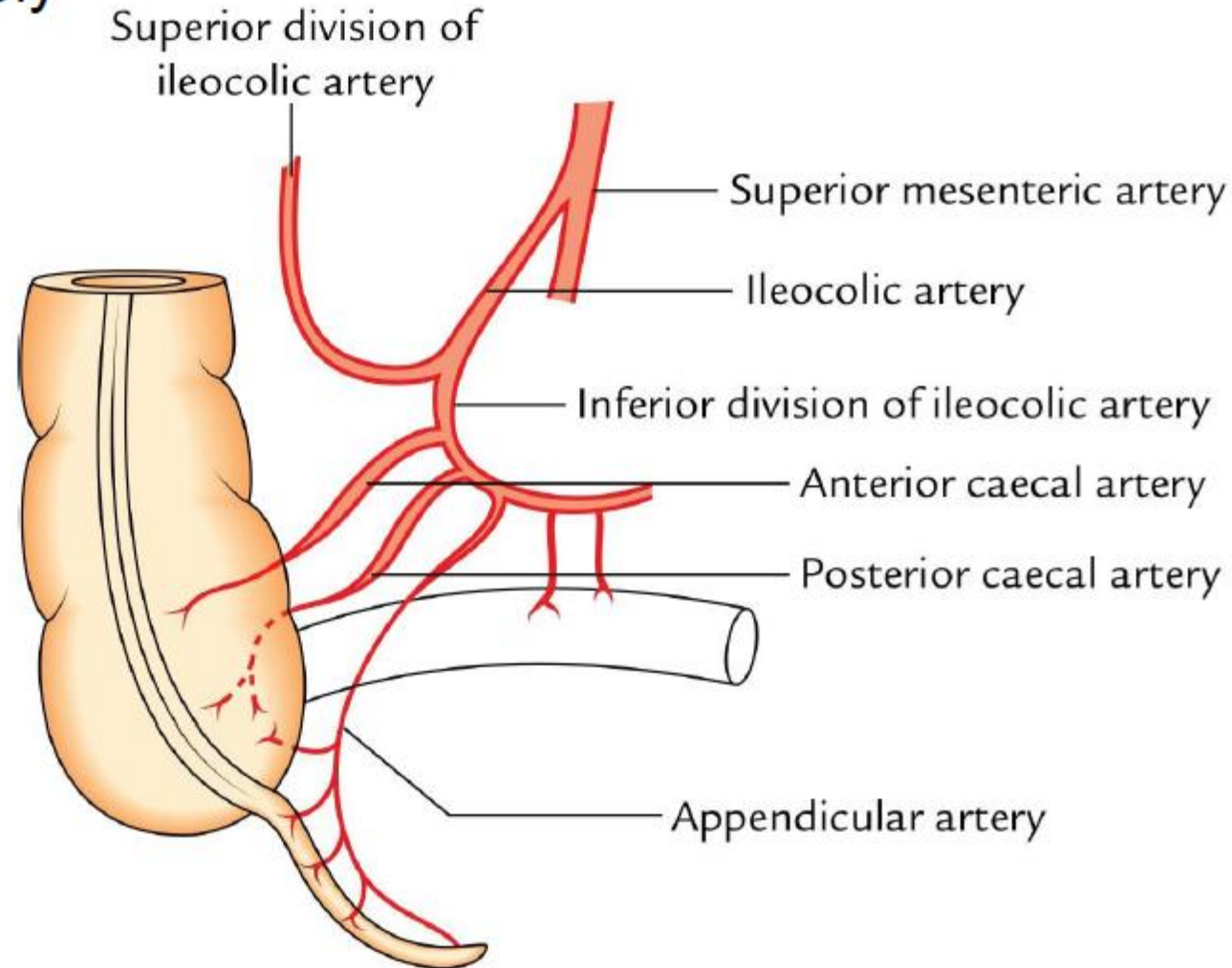
## Posterior relations

- ↓
1. Right gonadal vessels
  2. Lateral cutaneous nerve of thigh
  3. Genitofemoral nerve
  4. Psoas major
  5. Iliacus
  6. External iliac artery
  7. Femoral nerve



# • Blood supply of the cecum

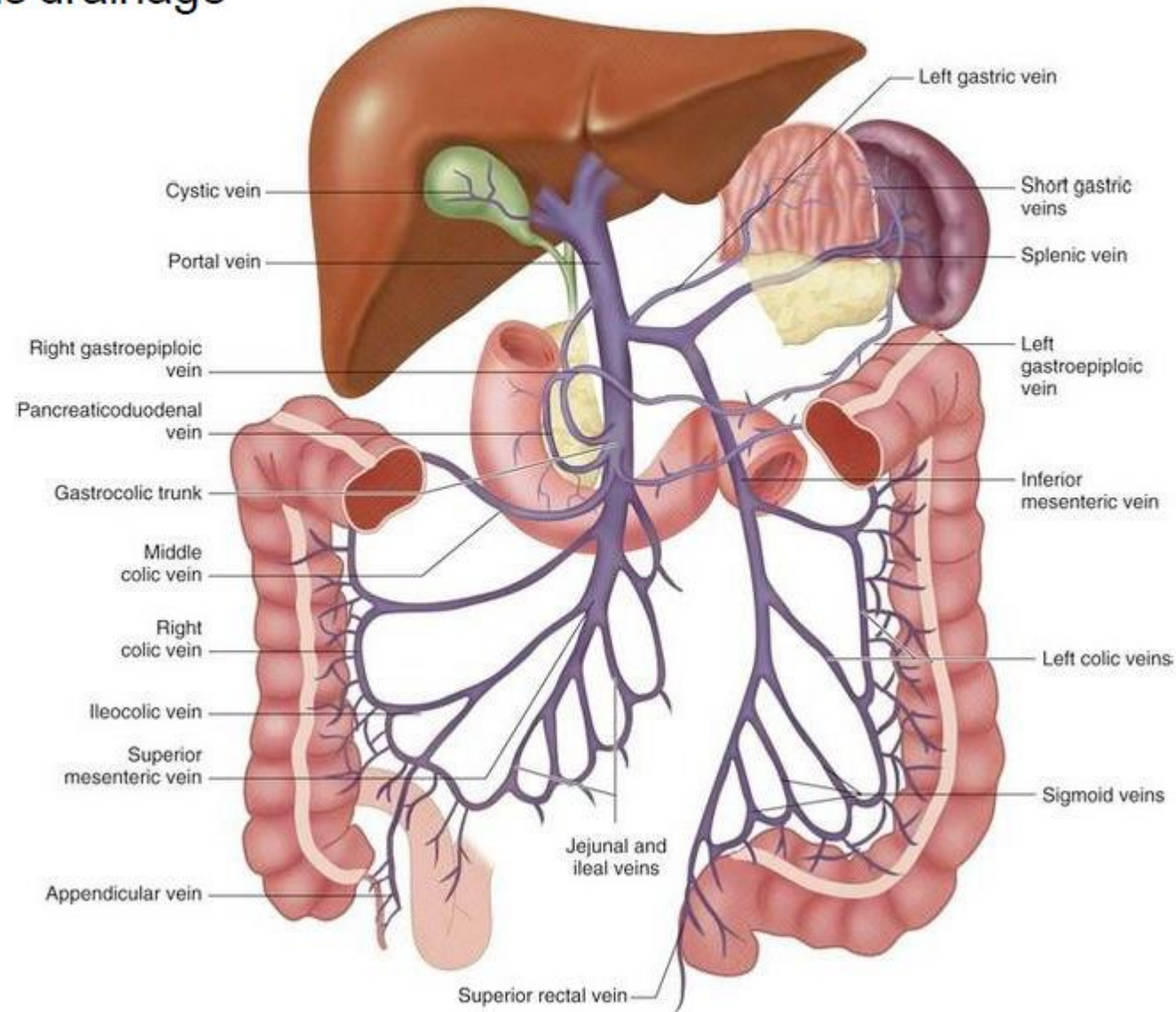
## • Arterial supply



Arterial supply of the caecum and appendix.

# • Blood supply of the cecum

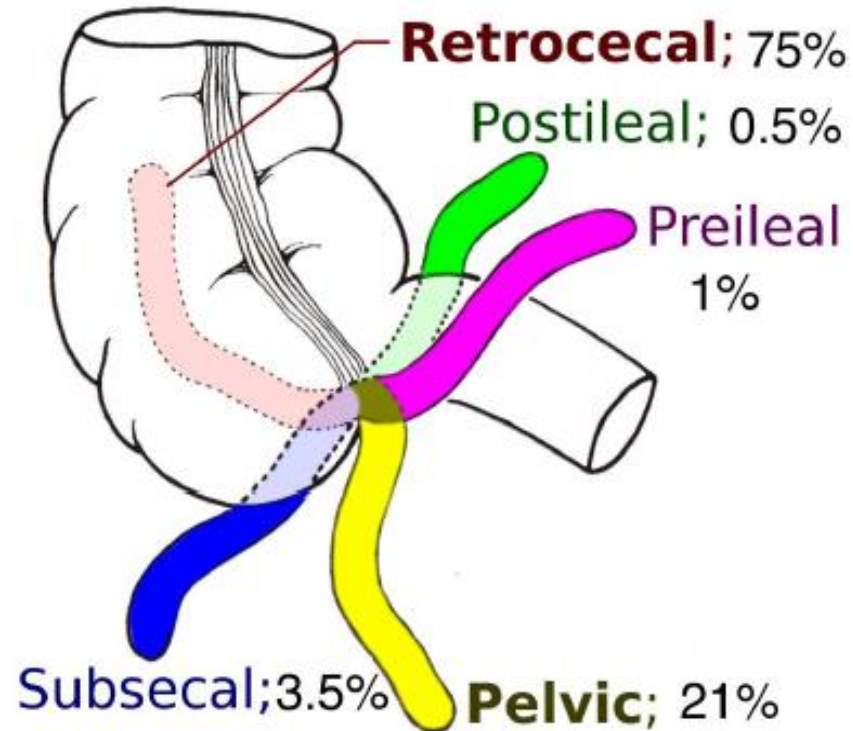
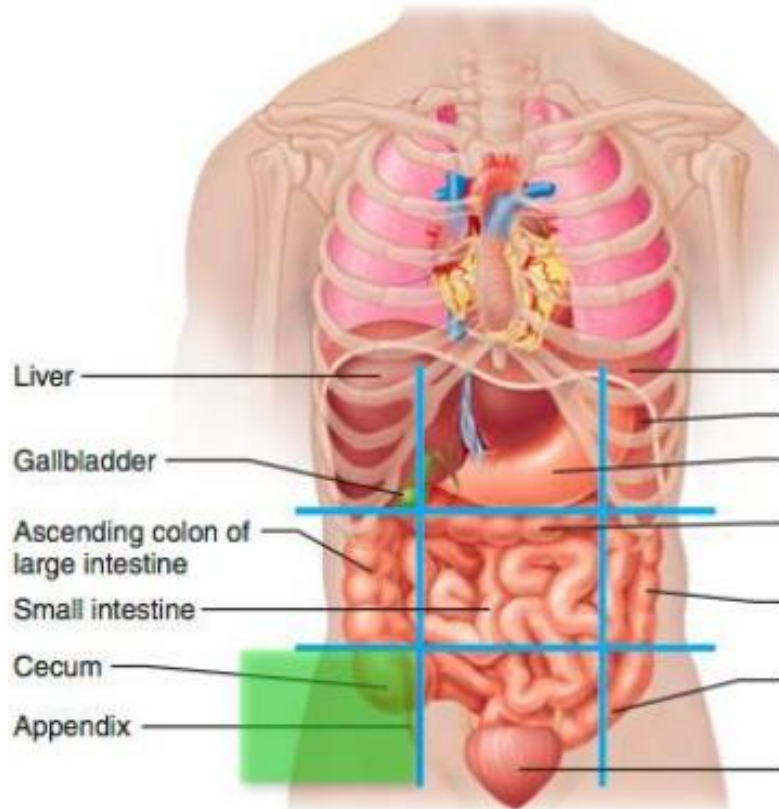
## • Venous drainage



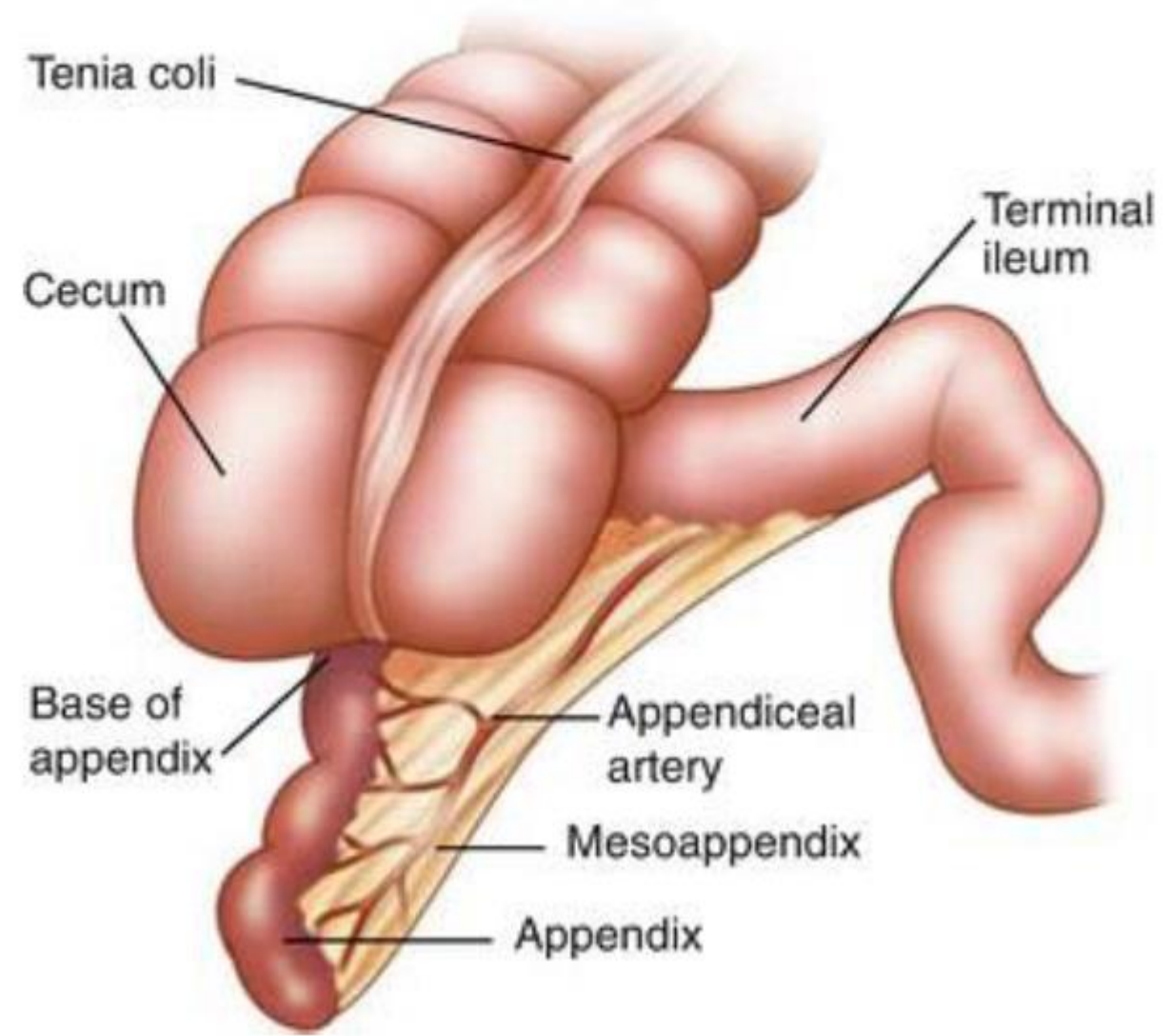
## ✦ Appendix

- The students should know and identify the :
  1. Site and Position
  2. Peritoneal Relations
  3. Features
  4. Relations
  5. Blood supply

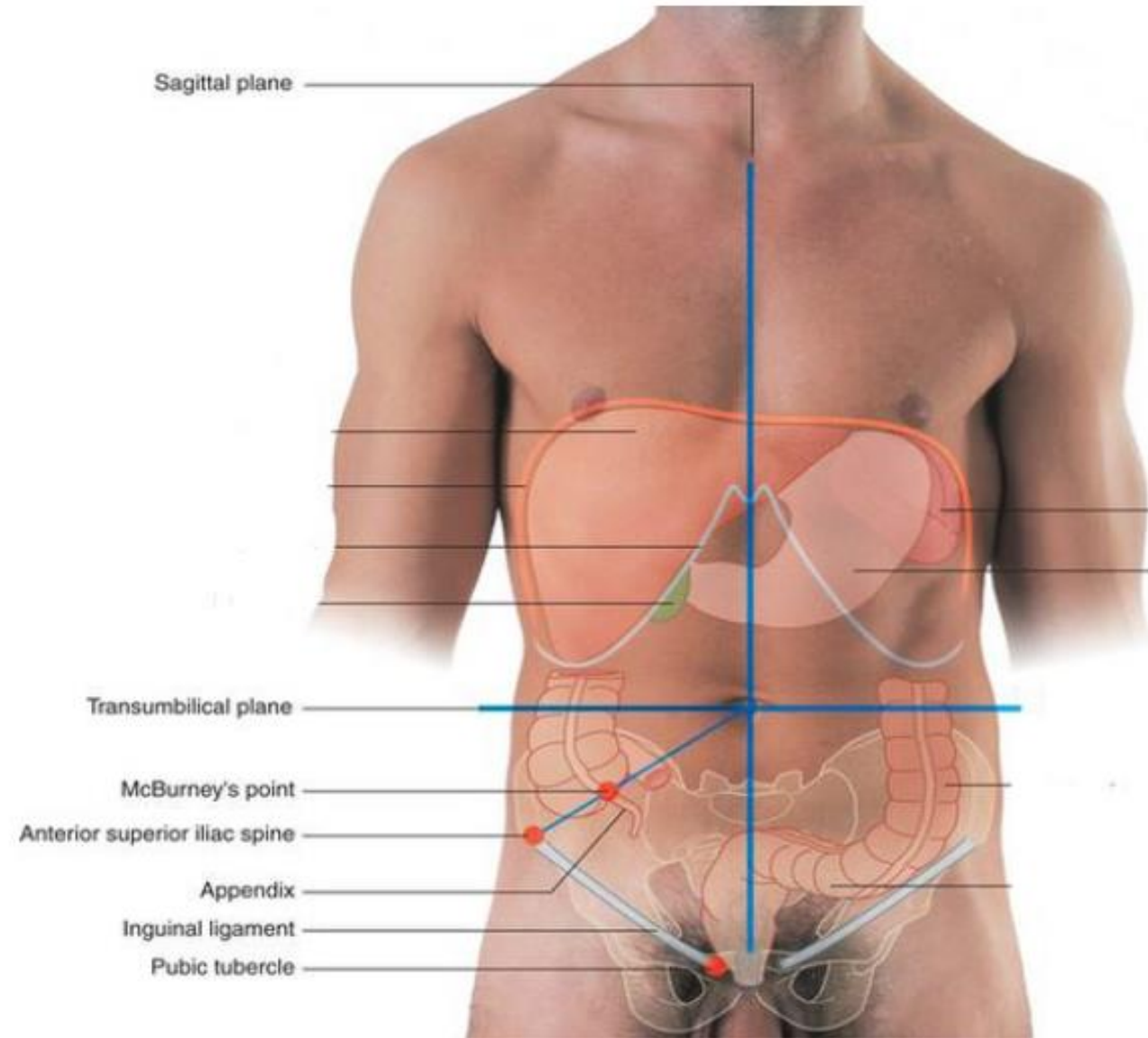
# • Site and Position of the Appendix



- Peritoneal Relations ( mesoappendix)

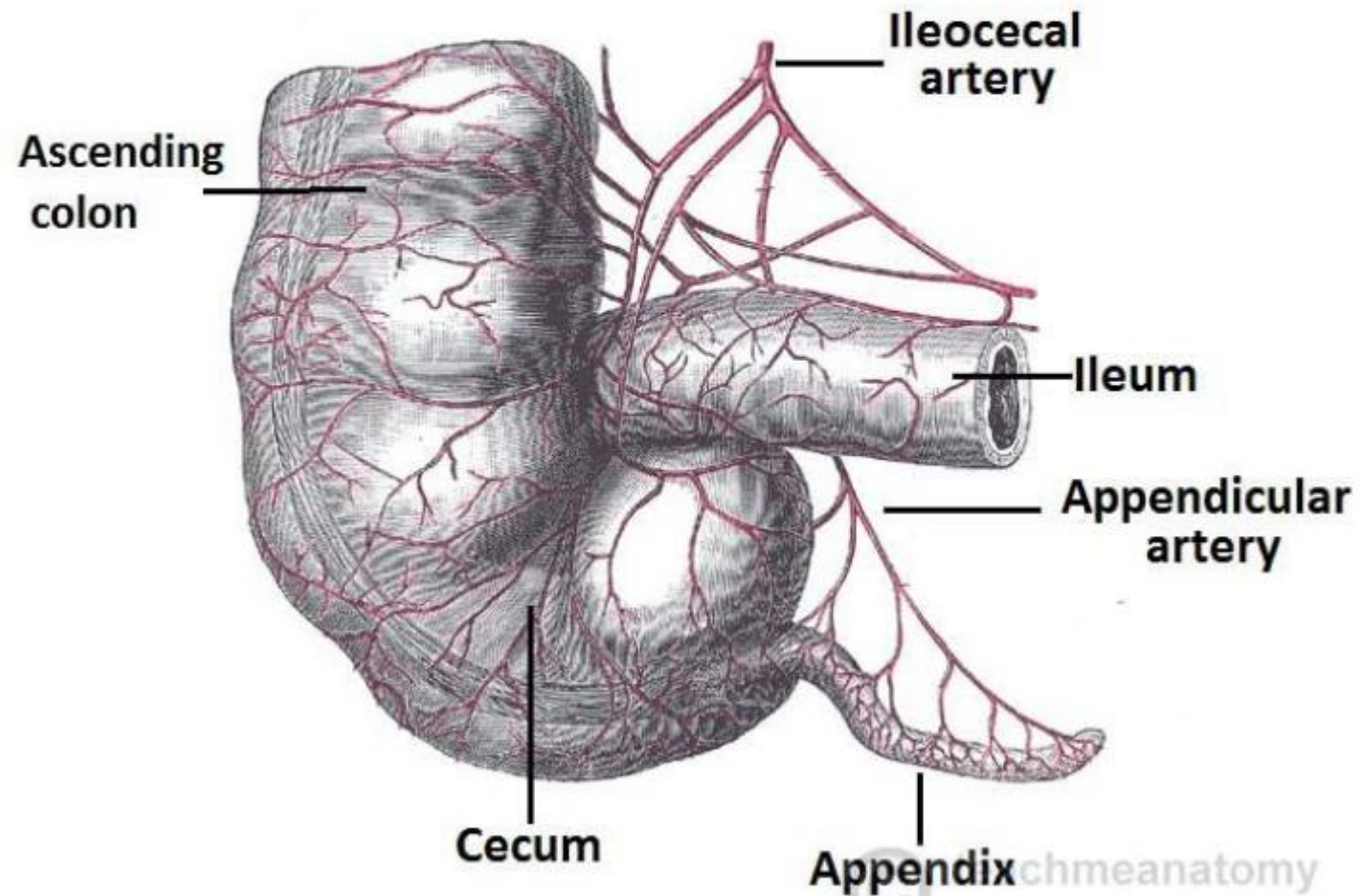


- **McBurney's point**



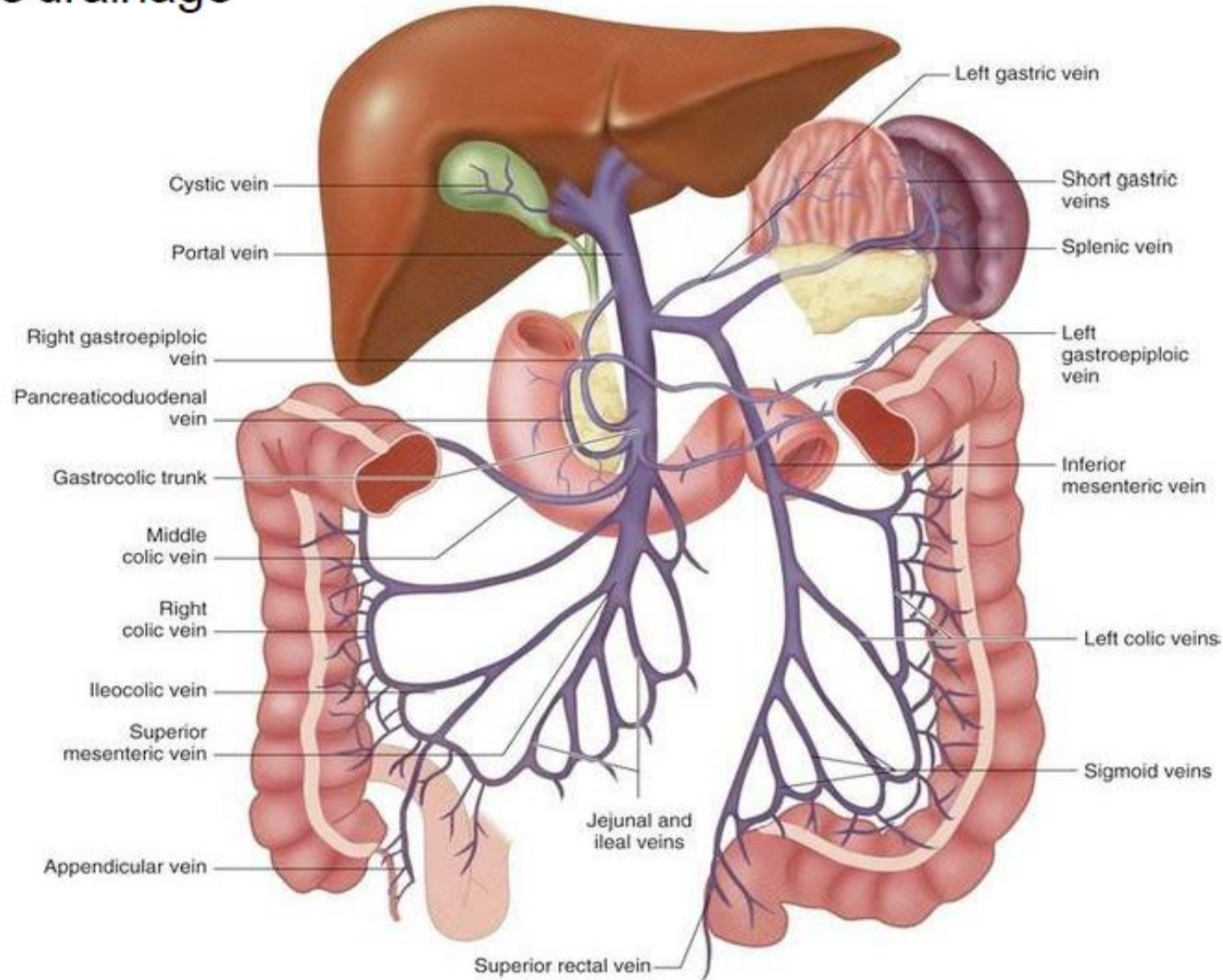
# • Blood supply of the Appendix

- Arterial supply



# • Blood supply of the Appendix

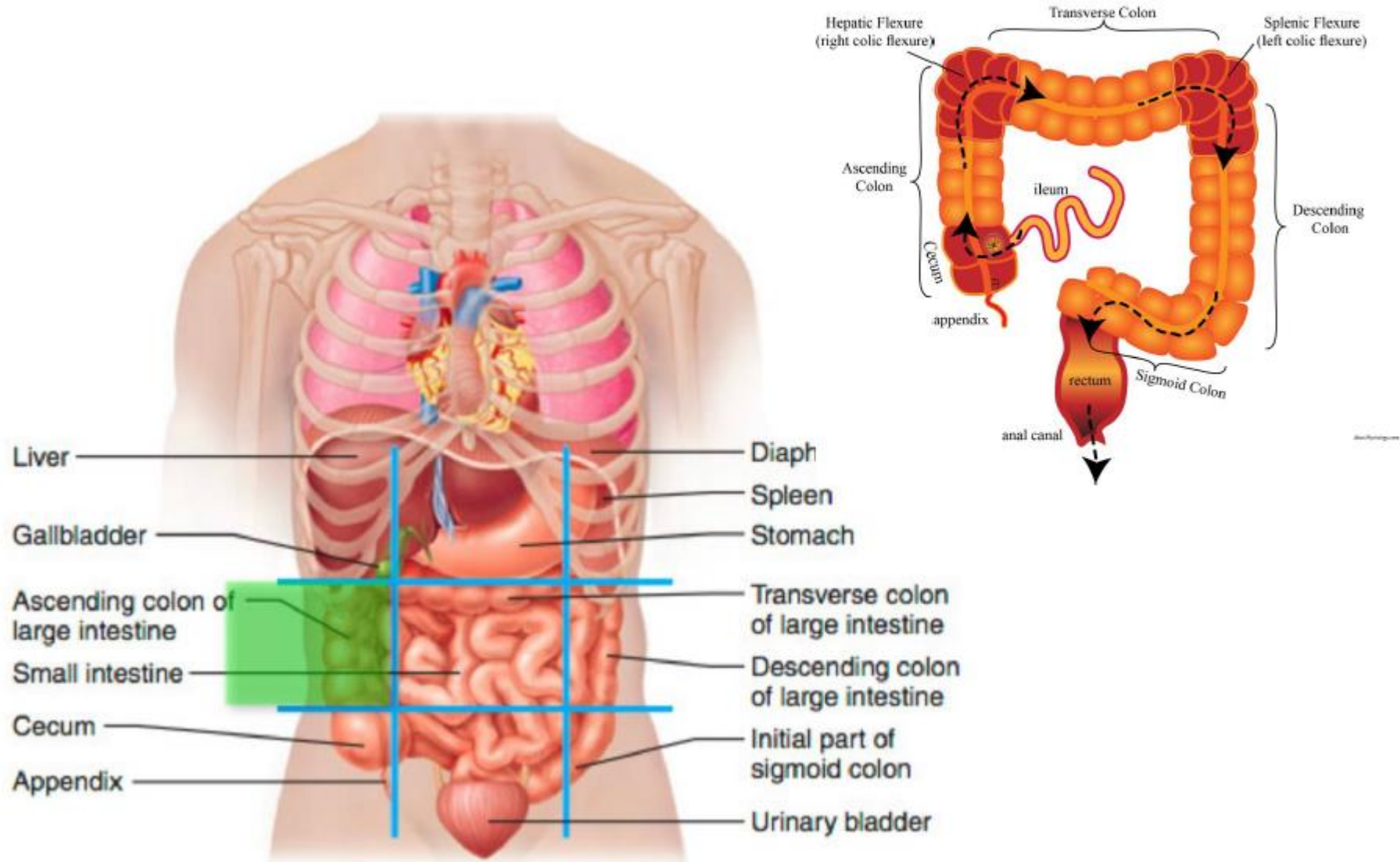
## • Venous drainage



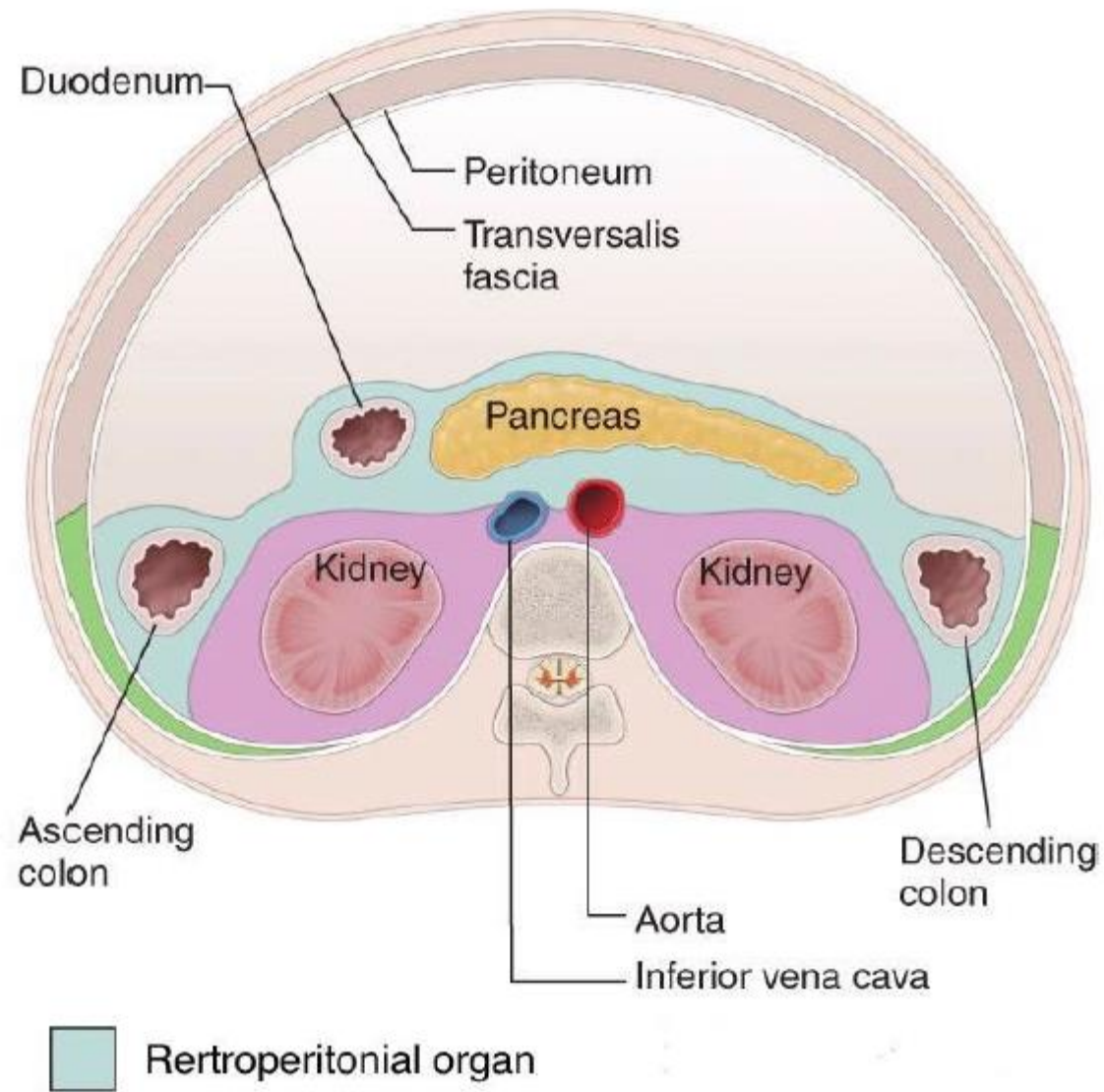
## ✦ Ascending Colon

- The students should know and identify the :
  1. Site and Position
  2. Peritoneal Relations
  3. Features
  4. Relations
  5. Blood supply

# • Site and Position of the Ascending Colon



# • Peritoneal Relations



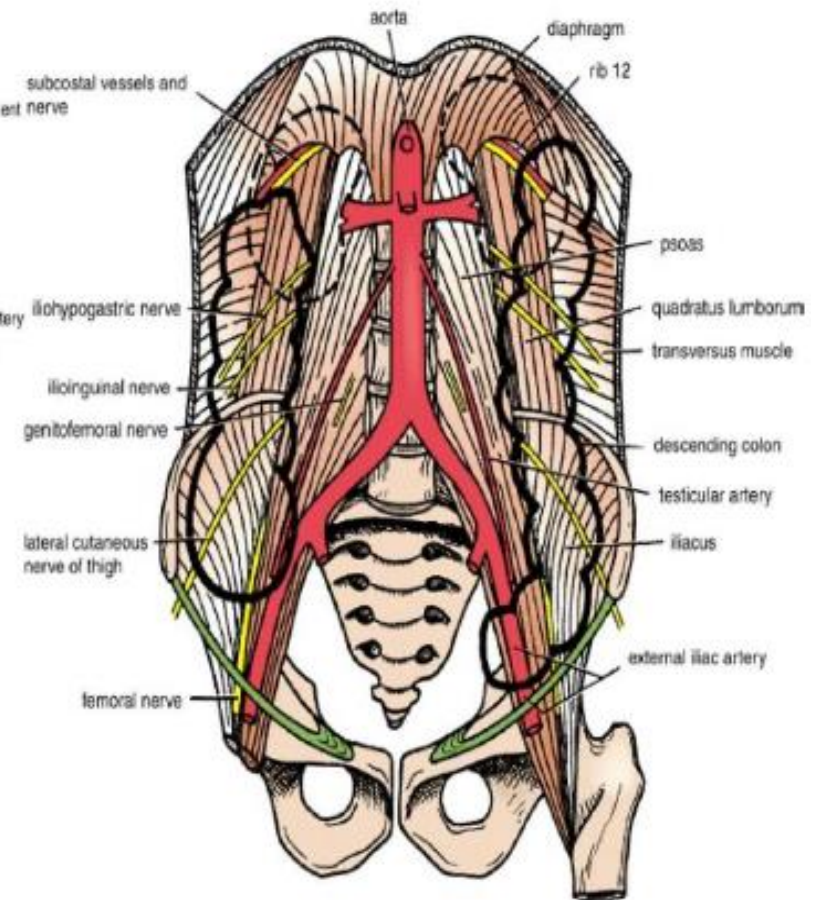
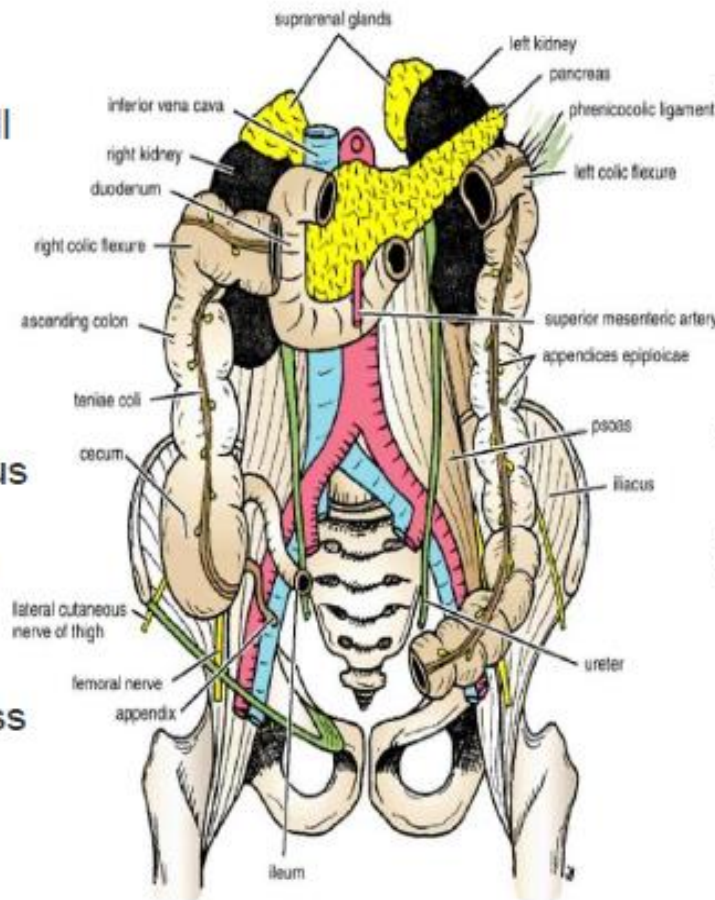
# • Relations of ascending colon

## • Anterior relations :

1. Coils of small intestine
2. The greater omentum
3. The anterior abdominal wall

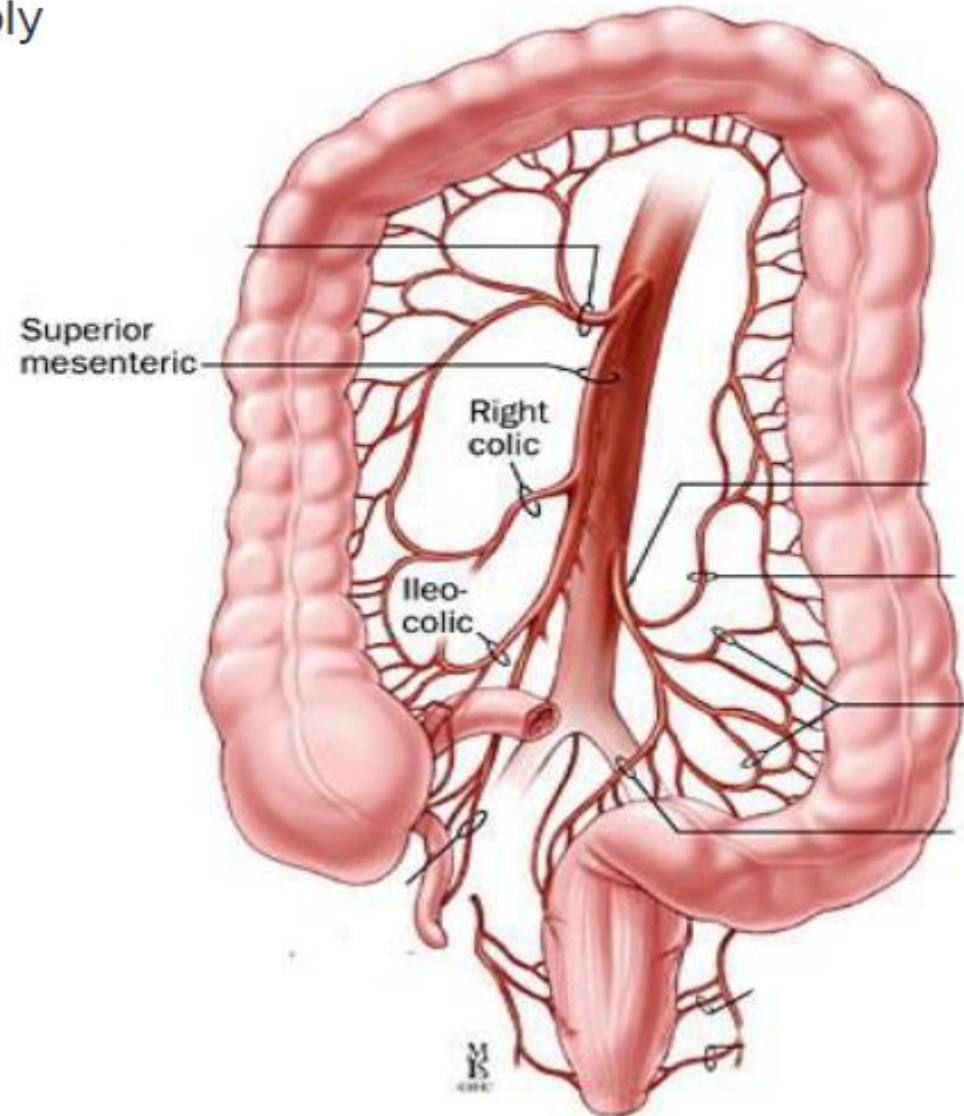
## • Posteriorly:

1. The iliacus
2. The iliac crest
3. The quadratus lumborum
4. The origin of the transversus abdominis muscle,
5. The lower pole of the right kidney.
6. The iliohypogastric .n
7. The ilioinguinal nerves cross behind it .



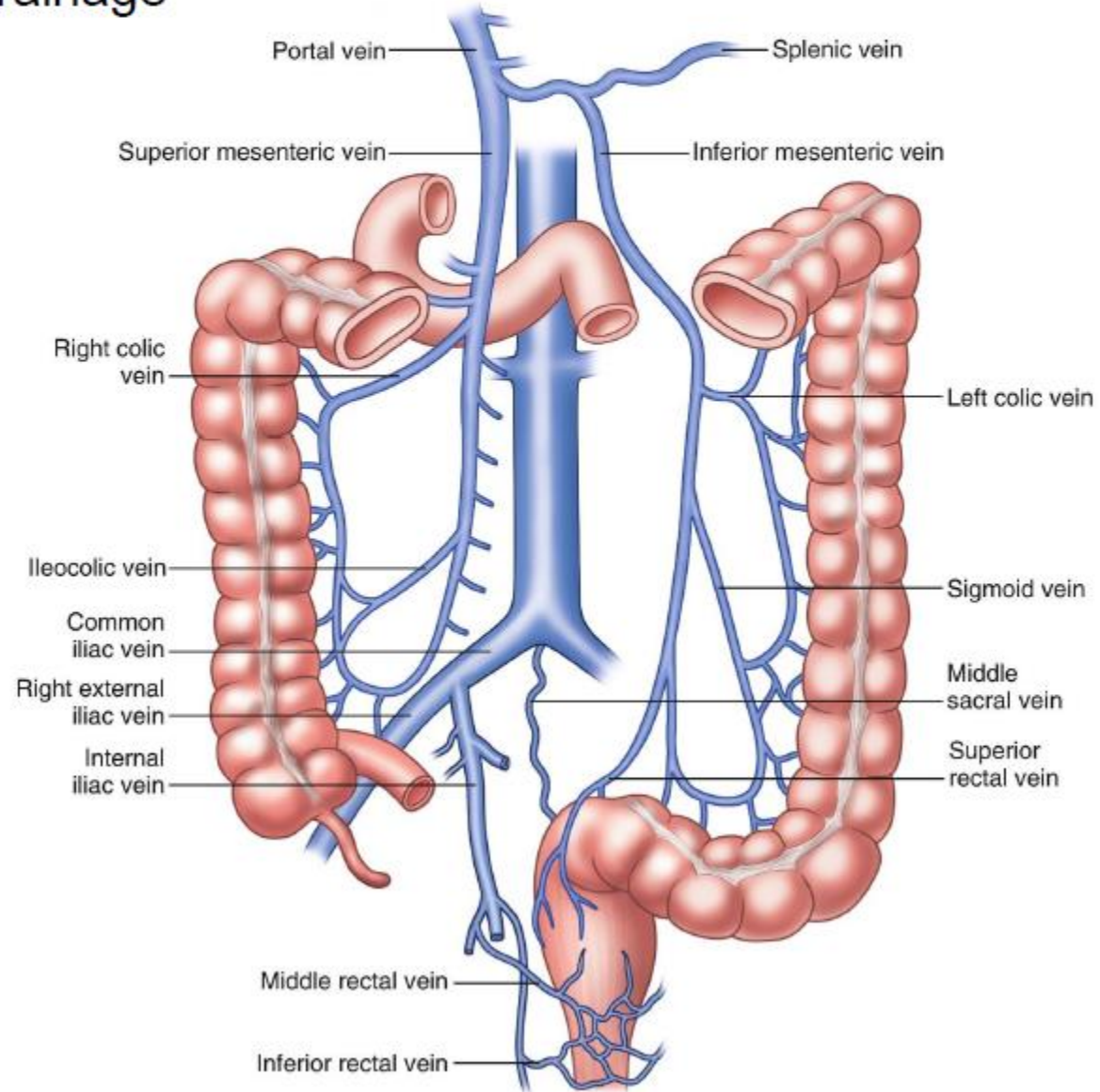
# • Blood supply of the ascending colon

- Arterial supply



# • Blood supply of the ascending colon

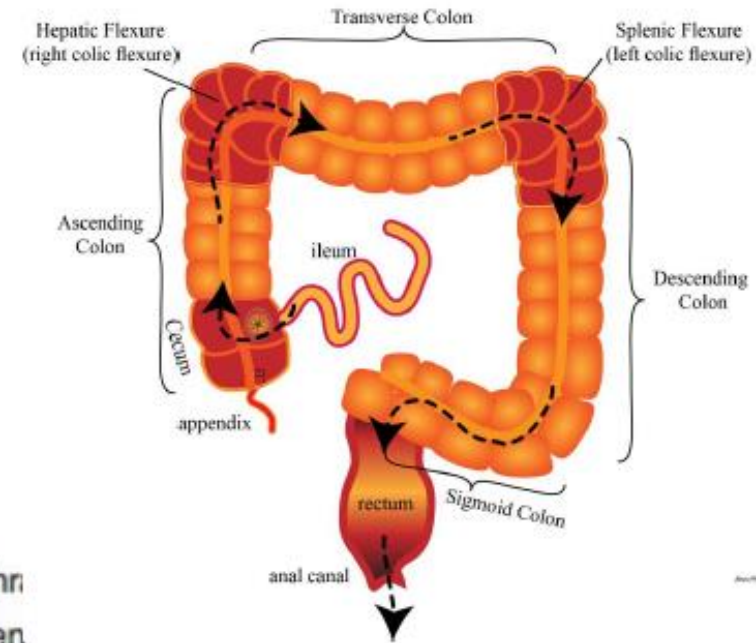
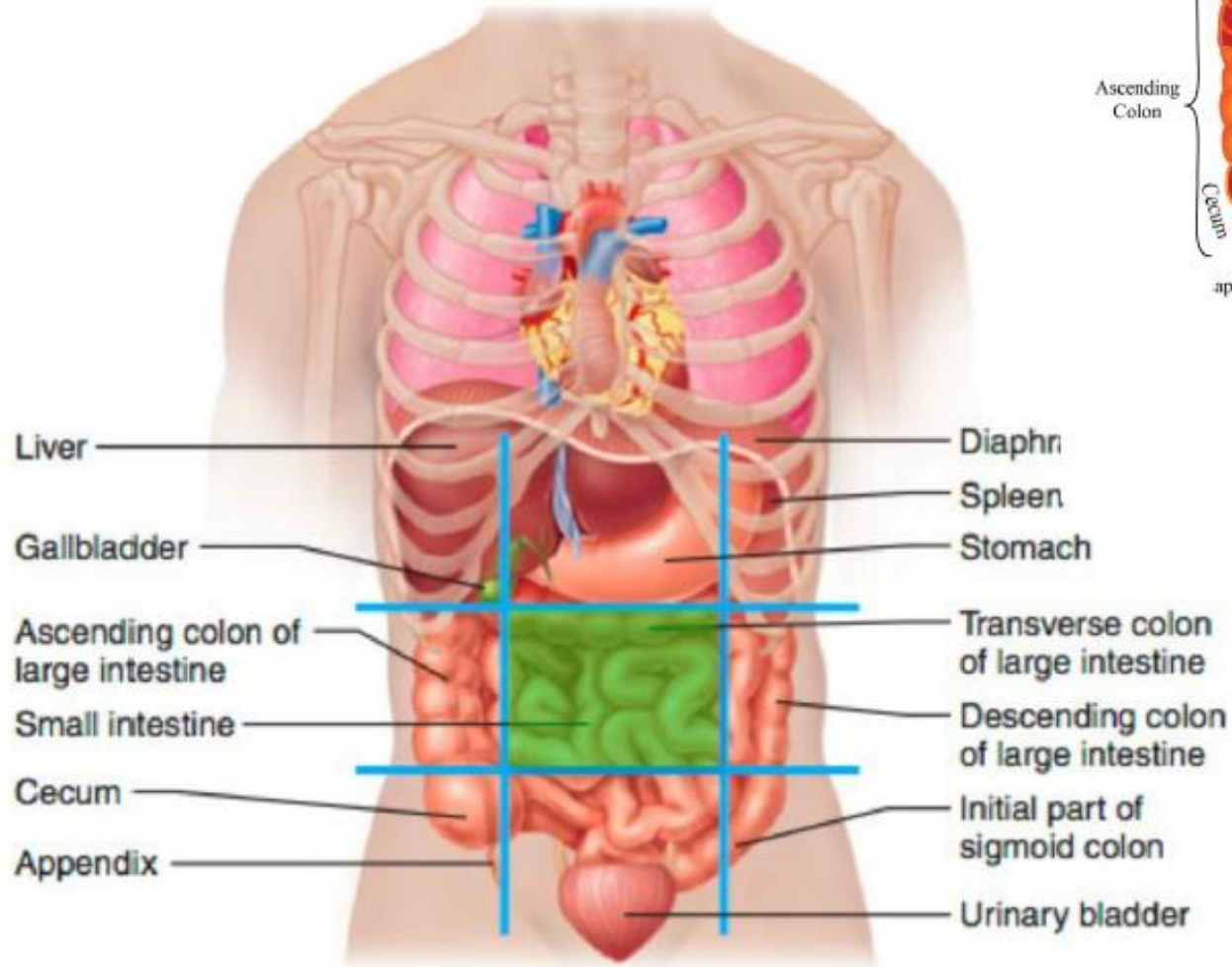
## • Venous drainage



## ✱ Transverse colon

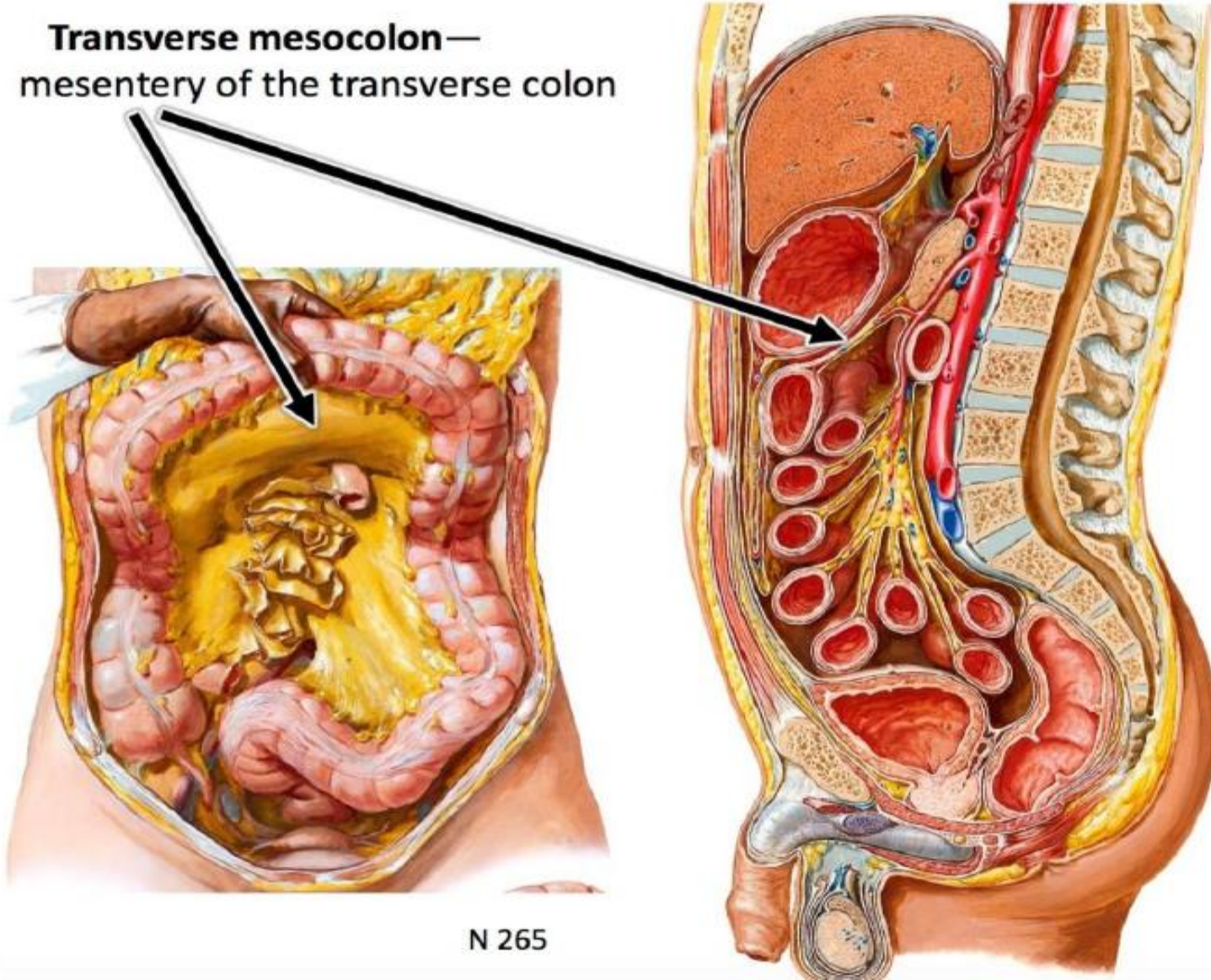
- The students should know and identify the :
  1. Site and Position
  2. Peritoneal Relations
  3. Features
  4. Relations
  5. Blood supply

# • Site and Position of the Transverse Colon

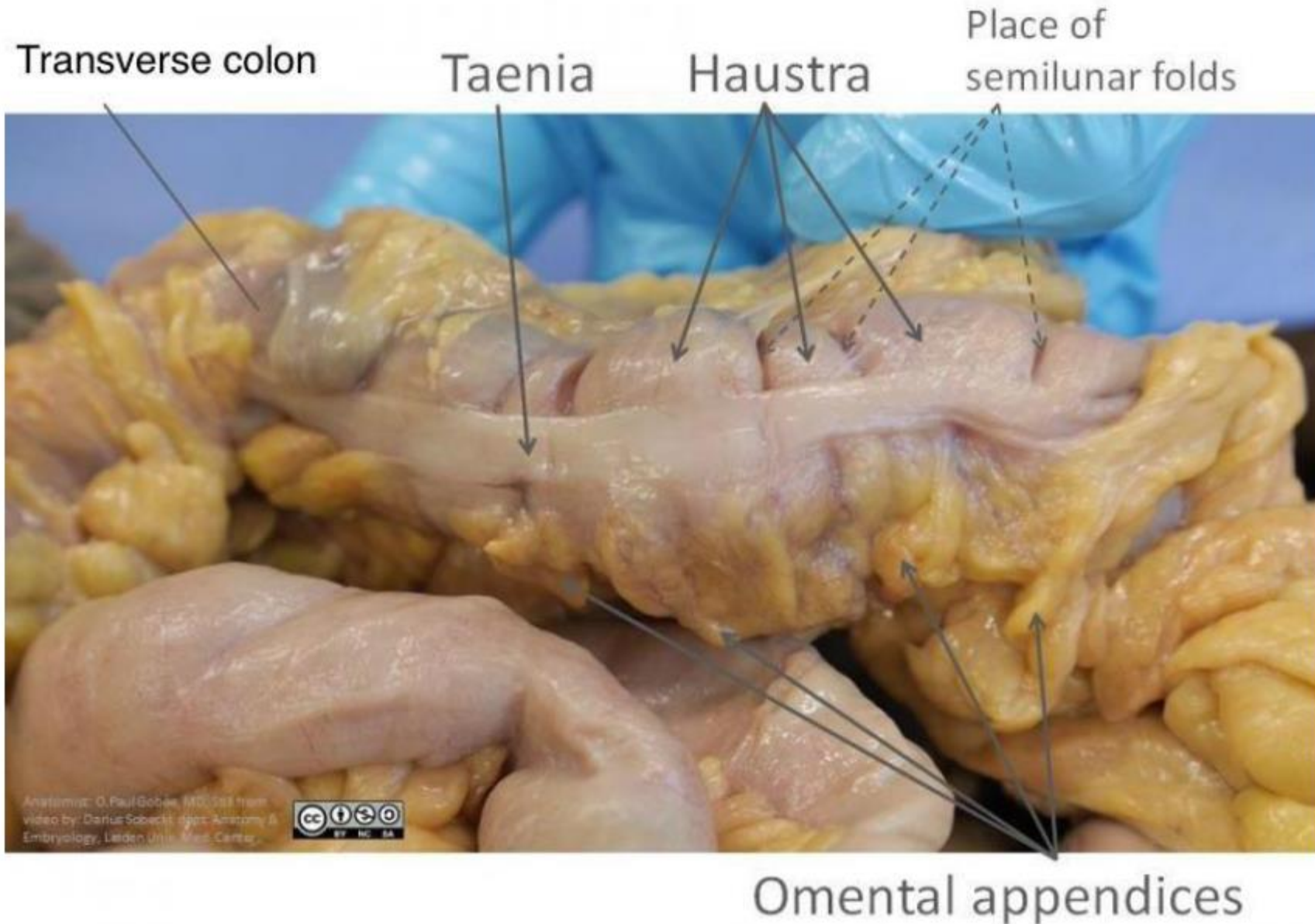


- Peritoneal Relations ( transverse mesocolon)

**Transverse mesocolon—  
mesentery of the transverse colon**

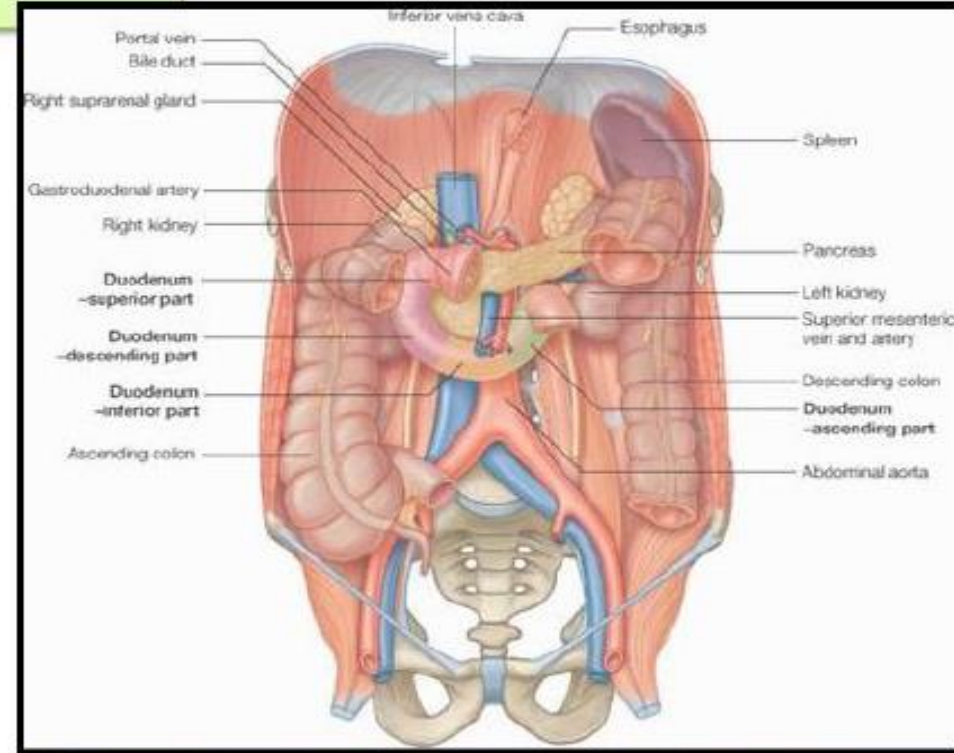
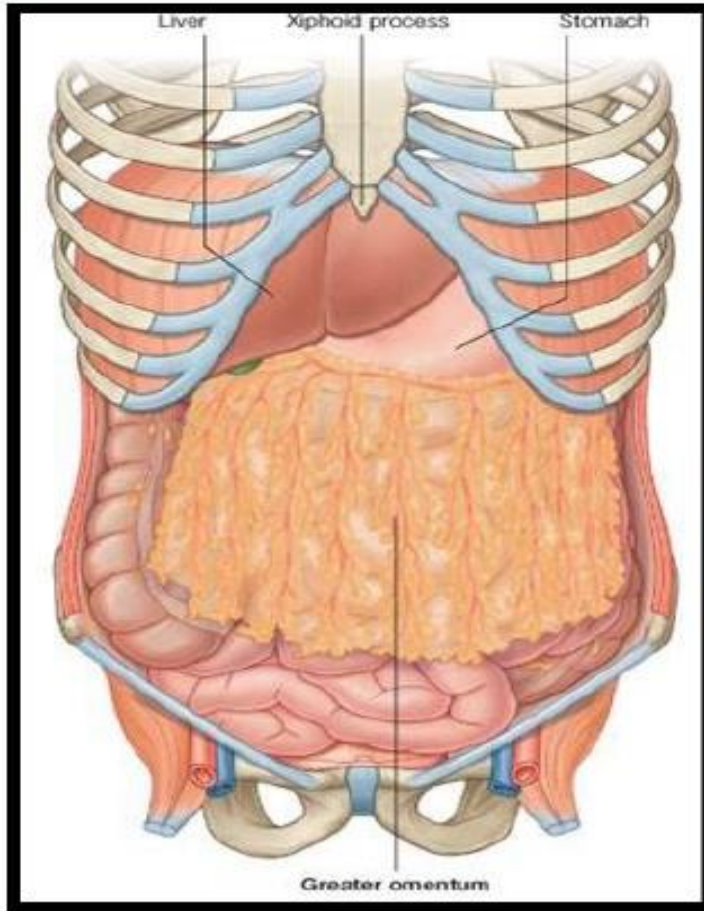


- Taenia coli



# • Relations of Transverse colon

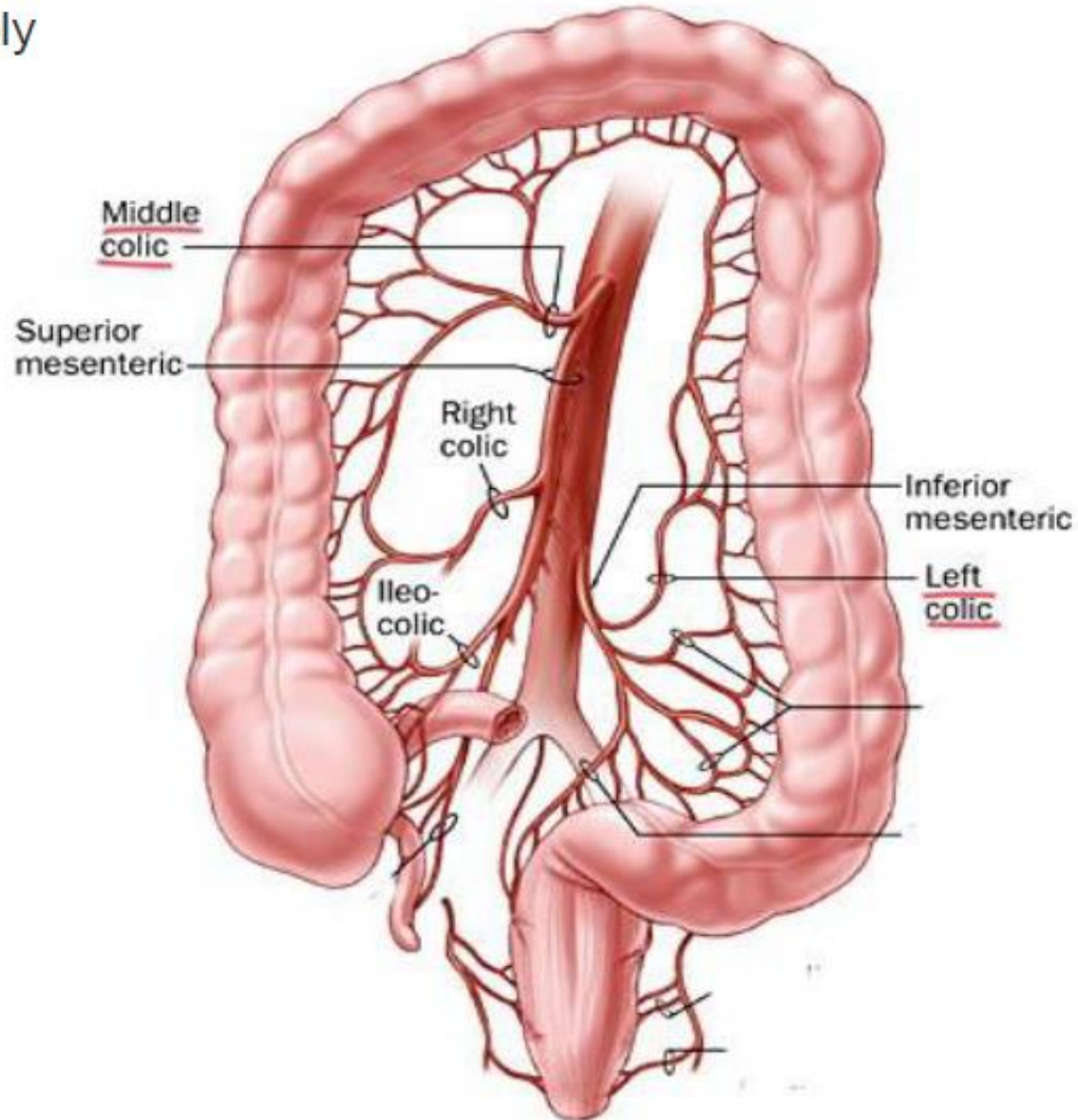
**Anterior:** greater omentum, anterior abdominal wall



**Posterior:** 2<sup>nd</sup> part of duodenum, pancreas & superior mesenteric vessels.

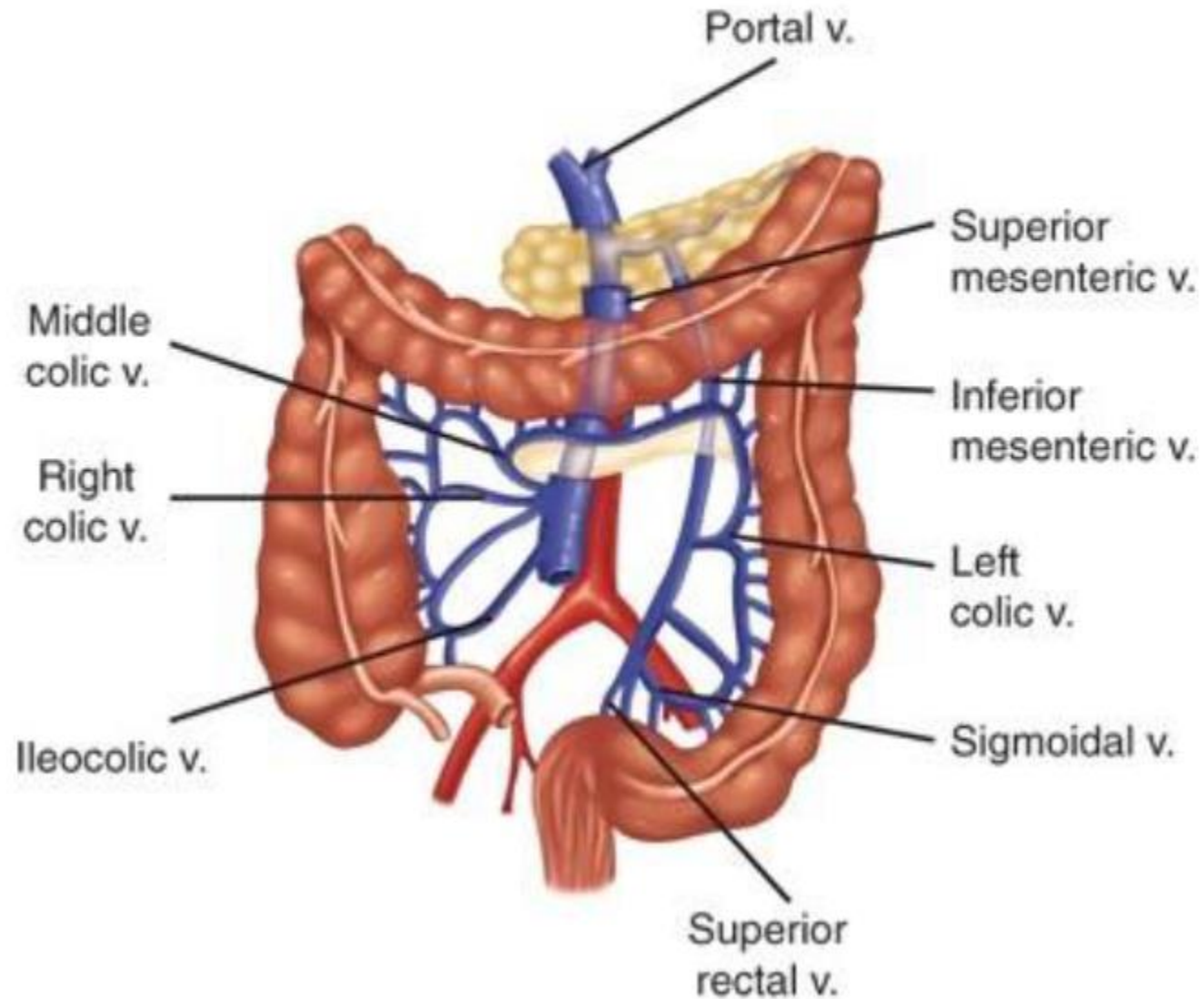
# • Blood supply of the Transverse colon

- Arterial supply



# • Blood supply of the Transverse colon

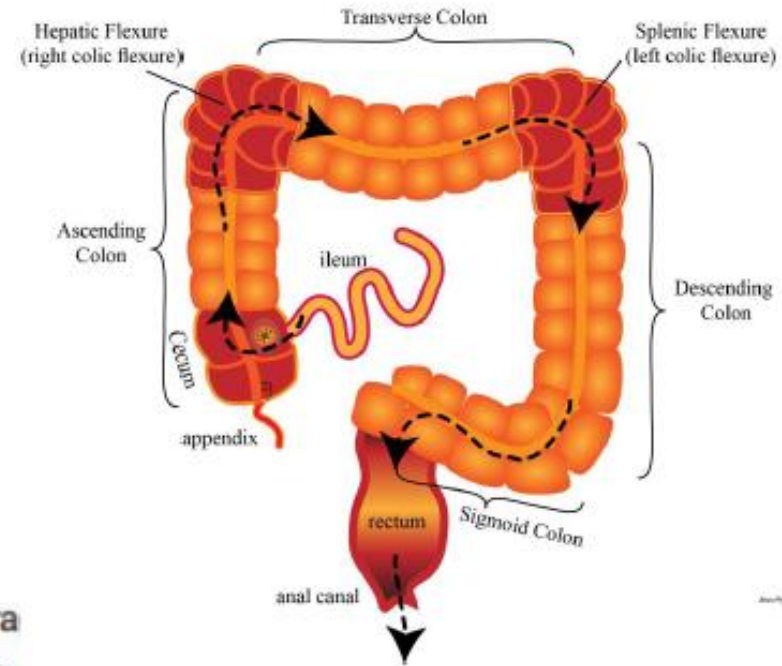
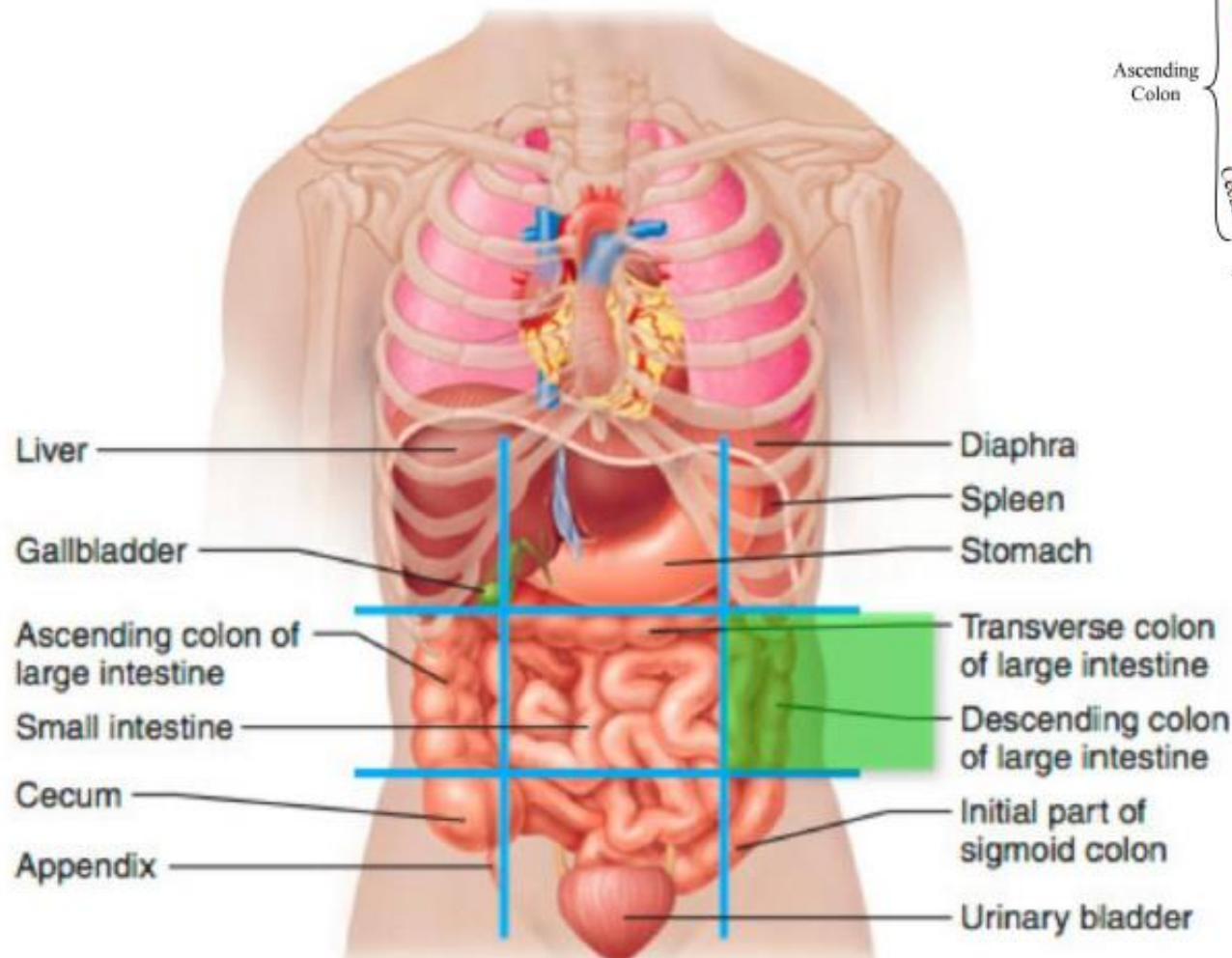
- Venous drainage



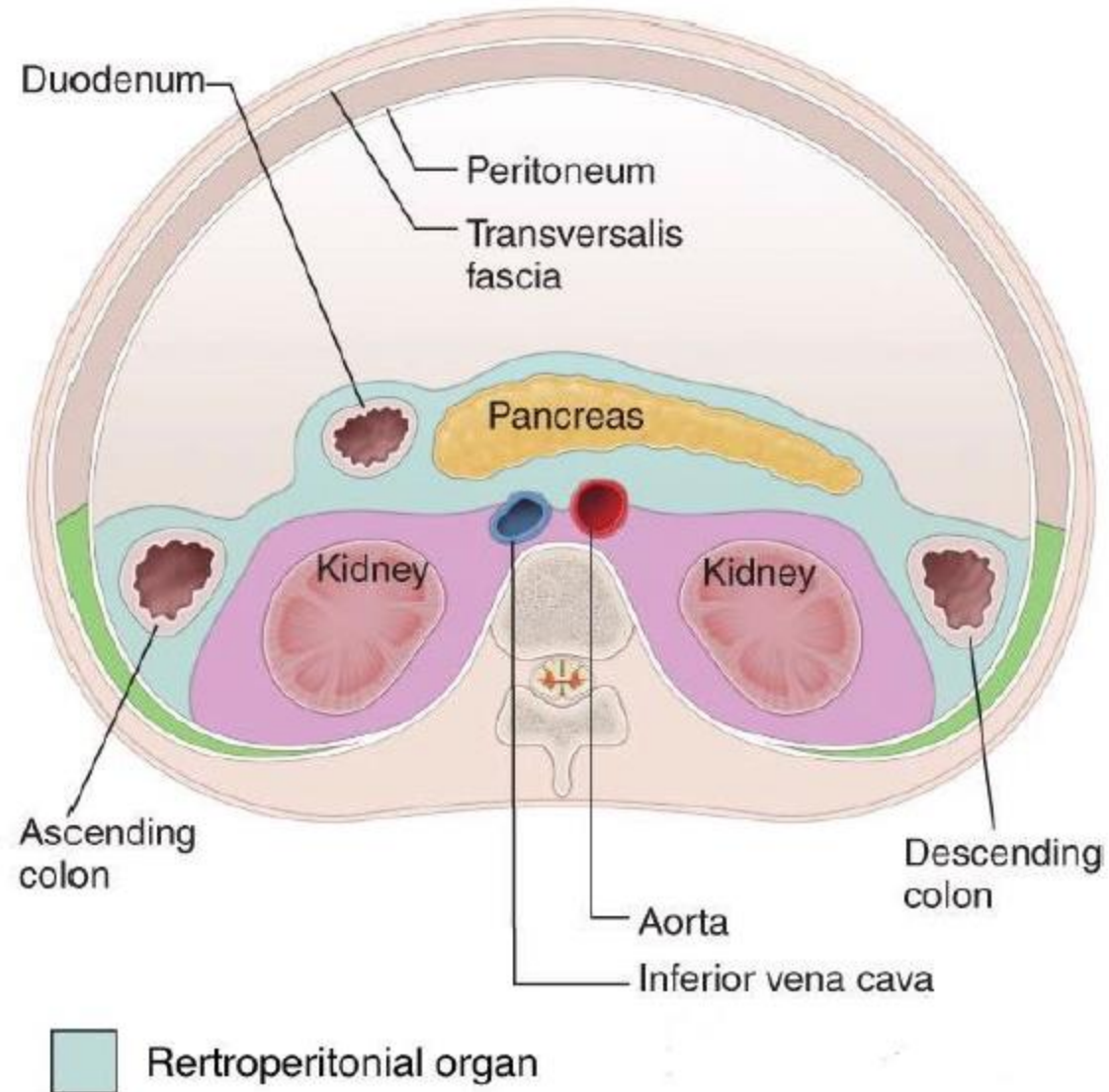
## ✦ Descending Colon

- The students should know and identify the :
  1. Site and Position
  2. Peritoneal Relations
  3. Features
  4. Relations
  5. Blood supply

# • Site and Position of the Descending Colon



# • Peritoneal Relations



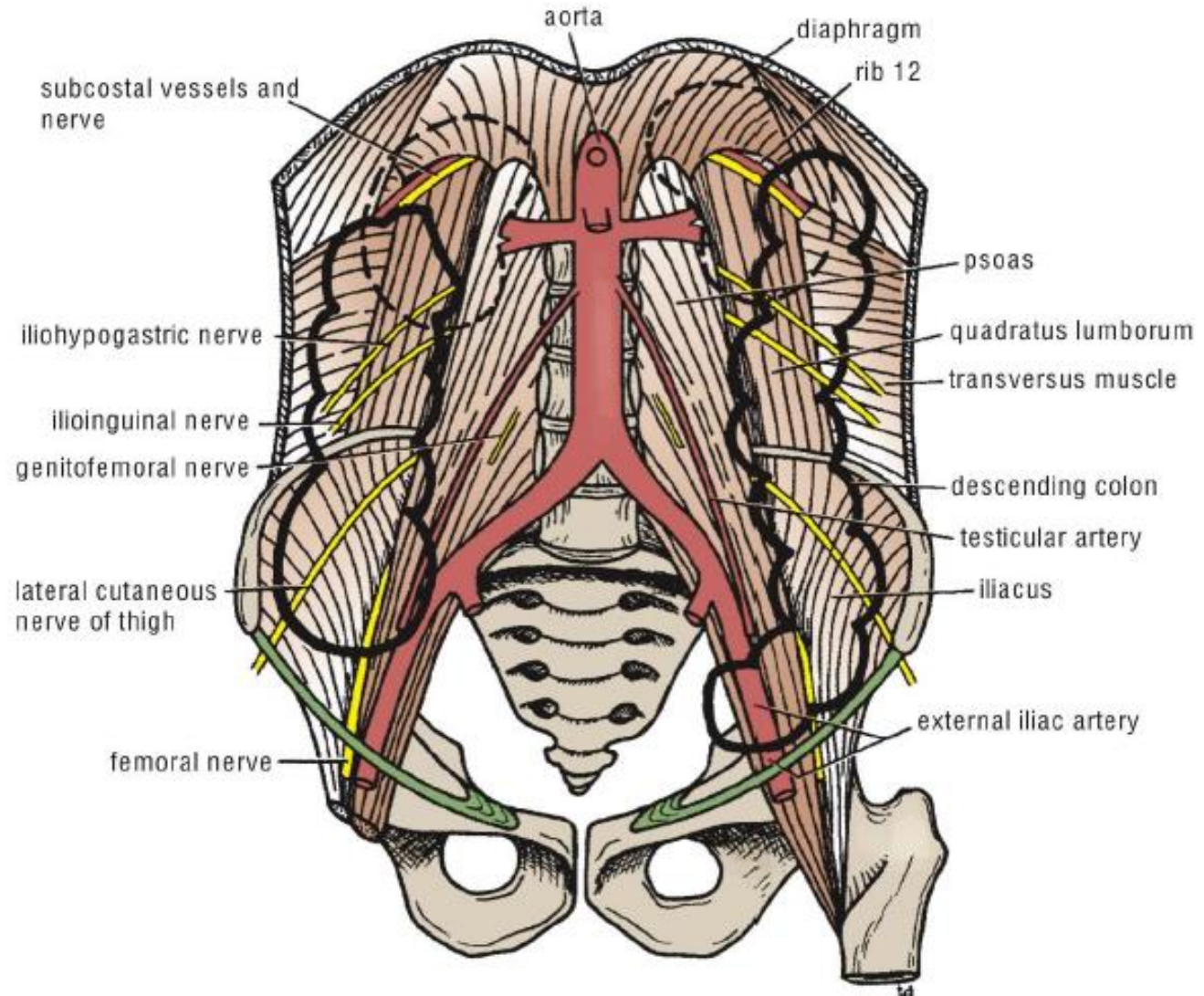
# • Relations of Descending colon

## • Anterior relations :

1. Coils of small intestine
2. The greater omentum
3. The anterior abdominal wall

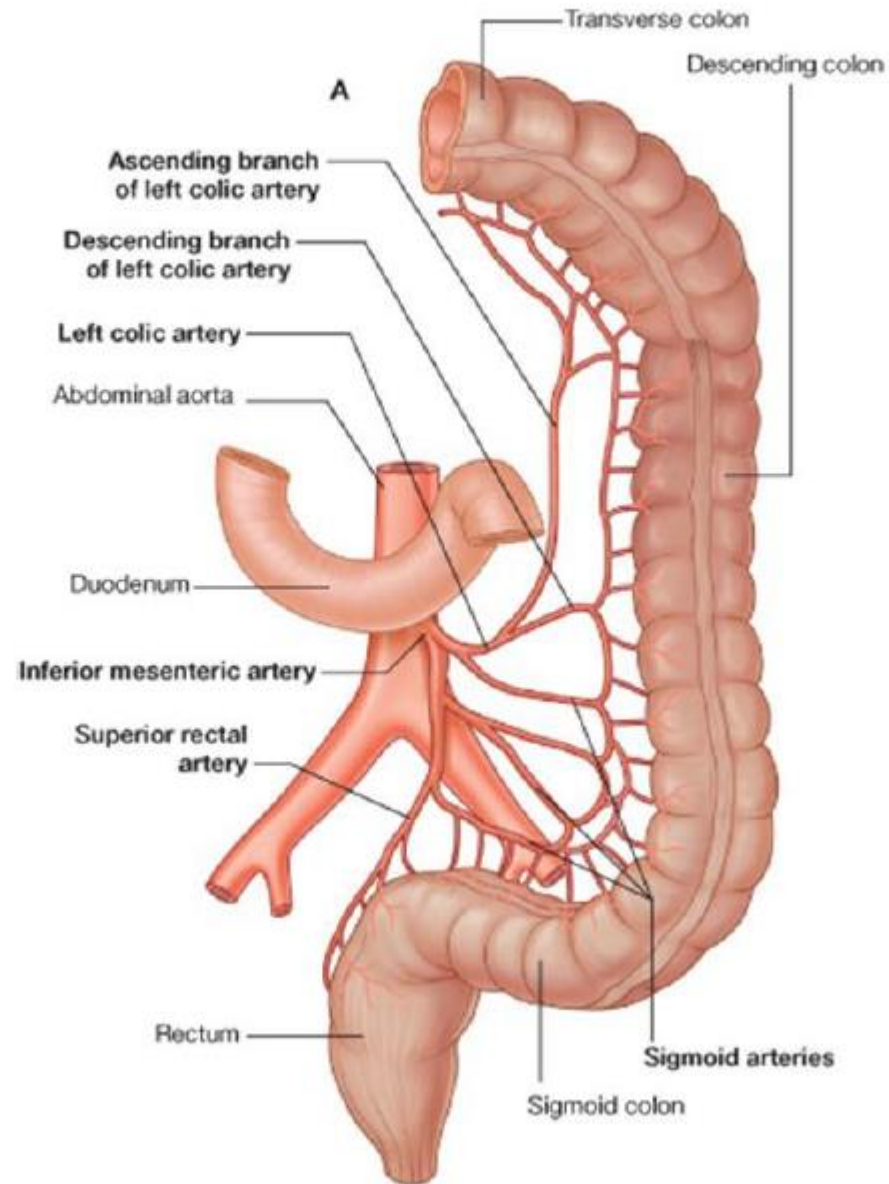
## • Posteriorly:

4. The lateral border of the left kidney
5. the origin of the transversus abdominis muscle
6. the quadratus lumborum the iliac crest
7. the iliacus
8. the left psoas
9. The iliohypogastric and the ilioinguinal nerves
10. the lateral cutaneous nerve of the thigh
11. the femoral nerve



# • Blood supply of the Descending colon

- Arterial supply



# • Blood supply of the Descending colon

- Venous drainage

