

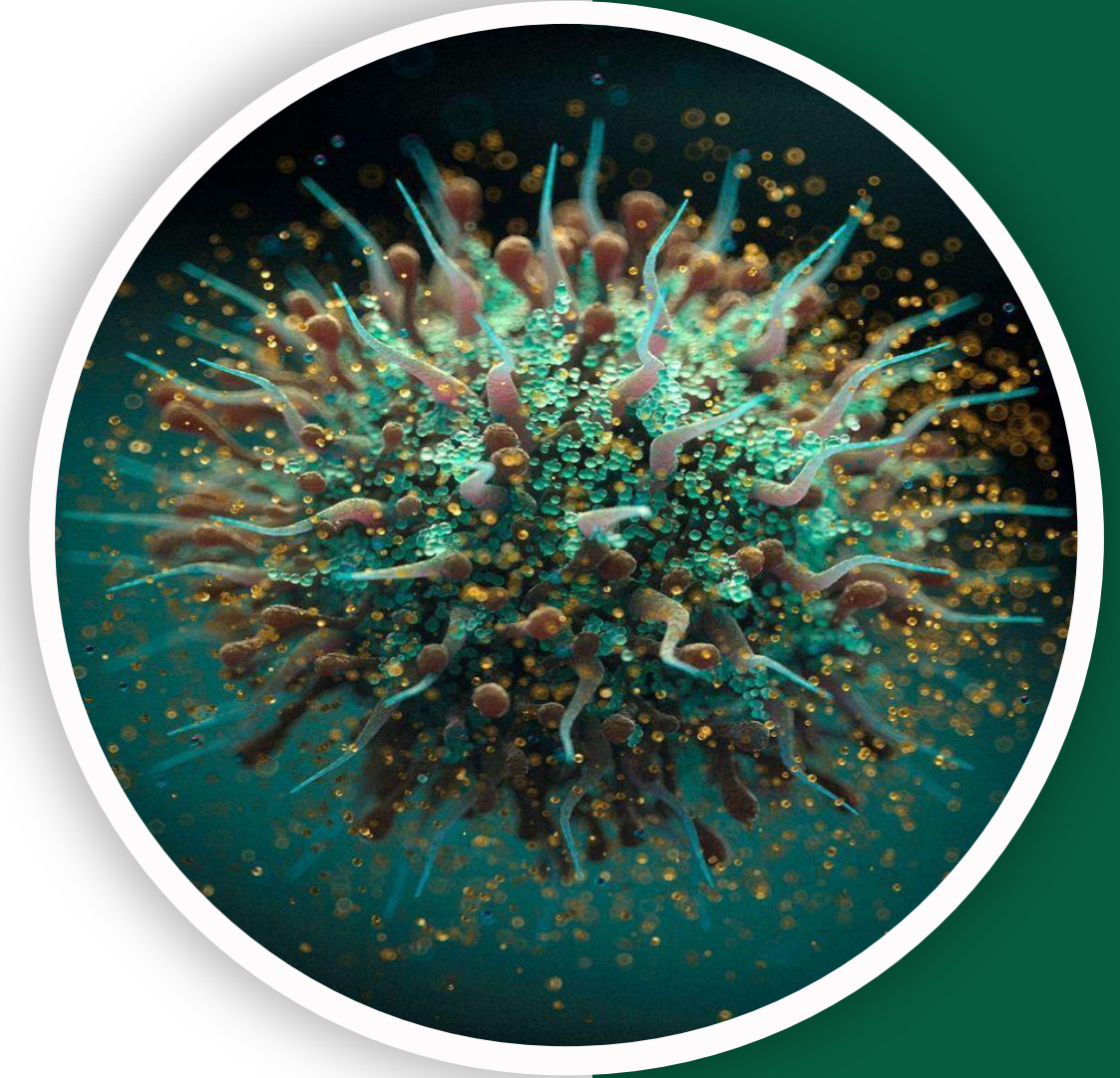
بِسْمِ اللّٰهِ الرَّحْمٰنِ الرَّحِیْمِ  
(وَفَوْقَ كُلِّ ذِي عِلْمٍ عَلِيمٌ)



جربان


GIS Pathology | MID

# Past Papers



Written by : DST  
NST

Reviewed by : Layan Bassam  
Abdallah Alabdallat



# *Past Papers*



# Esophageal Diseases

Q1: All of the following are risk factors for esophageal squamous cell carcinoma, EXCEPT:

- A) Caustic esophageal injury.
- B) Achalasia.
- C) Plummer-Vinson syndrome.
- D) previous radiation therapy.
- E) Barrett's esophagus.

Answer: E

Q2: One of the following best describes CMV esophagitis:

- A) Nuclear viral inclusions usually seen at the ulcer edge.
- B) Viral inclusions usually seen in endothelial and stromal cells.
- C) Upper endoscopy typically shows punched-out ulcers.
- D) Upper endoscopy typically shows pseudomembranes.
- E) Histology: inflammation, basal cell hyperplasia, and papillomatosis

Answer: B

Q3: A 60 year old female patient, known case of cancer on her 8th cycle of chemotherapy, presented with mild dysphagia. Endoscopy revealed patches of adherence, gray white pseudomembranous. The most likely diagnosis is:

- A) GERD
- B) early squamous cell carcinoma
- C) Infectious esophagitis by candidiasis
- D) Infectious esophagitis by HSV
- E) Infectious esophagitis by CMV

Answer: C

Q4: A 60-year-old man with long standing portal hypertension, developed severe Hematemesis, followed by severe hypotension and shock then admitted to intensive Care unit (ICU), the most likely cause of his bleeding is:

- A) Gastric ulcer.
- B) Viral esophagitis.
- C) Gastroesophageal reflux disease.
- D) Achalasia.
- E) Esophageal varices.

Answer: E

Q5: The best management plan for Mallory Weiss tear of the esophagus is:

- A) Endoscopy with cautery.
- B) Will heal spontaneously with no intervention.
- C) Surgical correction.
- D) Proton pump inhibitors.
- E) Antibiotic treatment.

Answer: B

Q6: A healthy lady gives birth to an infant. Upon start of feeding the baby developed frequent regurgitation with bouts of suffocation and cyanosis. After investigations, this baby's most likely diagnosis will be:

- A) Esophageal stenosis.
- B) Hirschsprung disease.
- C) Intussusception.
- D) Achalasia.
- E) Esophageal atresia and tracheoesophageal fistula.

Answer: E

Q7: One of the following is TRUE regarding gastroesophageal reflux disease (GERD) and reflux esophagitis:

- A) Cannot be seen in infants.
- B) Rings in the esophagus wall are characteristic.
- C) Elevated lower esophageal sphincter tone is the basic mechanism.
- D) Alcohol, smoking and obesity are considered risk factors.
- E) Neutrophilic infiltration of squamous epithelium is the earliest histologic finding.

Answer: D

Q8: A 60-year-old man, who is debilitated, HIV positive and bed ridden, complained of dysphagia and odynophagia. Upon endoscopy whitish adherent membranes are seen all over the esophagus, the most likely diagnosis:

- A) Esophageal reflux disease.
- B) Barrett esophagus.
- C) Candida esophagitis.
- D) Cytomegalovirus esophagitis.
- E) Herpes simplex esophagitis.

Answer: C

Q9: A 22-year-old woman has had multiple episodes of aspiration of food associated with Difficulty swallowing during the past year. A barium swallow shows marked esophageal Dilation above the level of the lower esophageal sphincter. A biopsy specimen from the Lower esophagus shows an absence of the myenteric ganglia. What is the most likely diagnosis?

- A) Achalasia
- B) Barrett esophagus
- C) Plummer-Vinson syndrome
- D) Pyloric stenosis
- E) Esophageal varices.

Answer: A

Q10: All of the following statements regarding the esophageal diseases is true except:

- A) stenosis is more commonly acquired.
- B) Atresia occurs most frequently at or near the tracheal bifurcation
- C) Esophageal stenosis is caused by fibrous thickening of the mucosa
- D) Achalasia-like disease is most commonly caused by Diabetic autonomic neuropathy
- E) esophageal varices can be caused due to parasitic infection in the liver and it represents a fatal condition

Answer: C

Q11: A patient has had pain for 1 week when he swallows food. Upper gastrointestinal endoscopy shows punched out ulcers in the region of the mid to lower esophagus. The ulcers are round and sharply demarcated, and have an erythematous base, a biopsy is taken and shows multinucleated giant cells. Which of the following is most likely to produce these findings?

- A) Reflex esophagitis
- B) esophageal candidiasis
- C) CMV esophagitis
- D) Herpes simplex esophagitis
- E) All of the following can cause these features.

Answer: D

## Q12: Which of the following statements is true?

- A) squamous cell carcinoma has a very high association with alcohol and smoking, and it commonly occurs in the lower third of esophagus.
- B) Adenocarcinoma doesn't Arise from a background of Barrett.
- C) The most important management of Barrett esophagus is to do Periodic endoscopy with biopsy to screen for dysplasia.
- D) CMV infects the squamous cells of esophagus.
- E) patients with eosinophilic esophagitis don't respond to steroids therapy.

Answer: C

Q13: Eosinophilic esophagitis is related to:

- A) Pre malignant condition
- B) Viral infection
- C) Allergy to certain food
- D) Congenital disease
- E) Chronic reflux disease

Answer: C

Q14: Esophageal atresia is commonly associated with a fistula between esophagus and:

- A) Stomach
- B) Diaphragm
- C) Bronchus
- D) Spleen
- E) Lung

Answer: C

Q15: The presence of goblet cells in the esophagus is seen in:

- A) Barret esophagus
- B) Squamous cell carcinoma
- C) Candida esophagitis
- D) Early reflux esophagitis
- E) Caustic injury

Answer: A

Q16: Which of the following typically describes Barrett esophagus:

- A) Esophageal ulceration as a result of reflux esophagitis
- B) Squamous dysplasia
- C) Marked eosinophilic infiltrate of the esophageal mucosa
- D) Intestinal metaplasia as a result of long-standing reflux esophagitis
- E) Esophageal adenocarcinoma as a result of reflux esophagitis

Answer: D

Q17: A 60-year-old patient with liver cirrhosis and portal hypertension who developed sudden massive hematemesis and hypovolemic shock. what is the most likely cause of this bleeding based on this scenario:

- A) Esophagitis
- B) Esophageal varices
- C) Esophageal cancer
- D) Gastric ulcer
- E) Gastric cancer

Answer: B

Q18: A 30-year-old HIV positive man, presented with dysphagia and odynophagia. Upper endoscopy showed adherent whitish thick membranes in the esophagus .

Biopsy showed matted hyphae. Which of the following he is most likely to have:

- A) Helicobacter pylori infection
- B) Eosinophilic esophagitis
- C) Herpes simplex virus esophagitis
- D) Candida esophagitis
- E) Chemical esophagitis

Answer: D

Q19: A patient suffers from prolonged vomiting and then is presented with hematemesis:

Answer: Esophageal lacerations

Q20: Which of the following best explains the development of congenital esophageal atresia near the tracheal bifurcation?

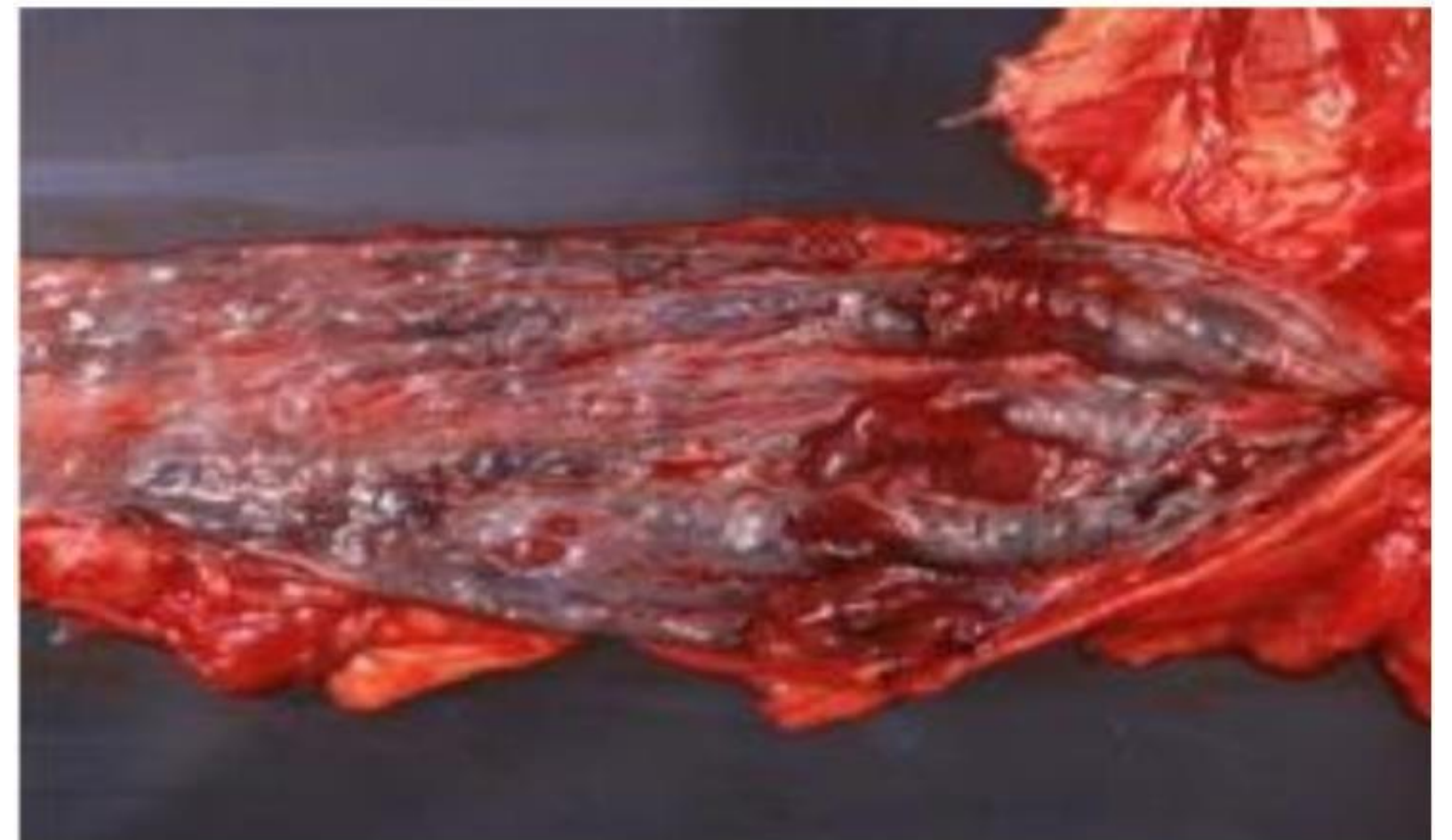- A) Failure of tracheoesophageal ridges to fuse
- B) Incomplete recanalization of the upper esophagus
- C) Congenital muscular atrophy of the esophageal wall
- D) External vascular compression during development

Answer: A

\* Note: I phrased the question based on the given answer due to absence of original wording.

Q21: This is a section from the esophagus from a 60-year-old patient with liver cirrhosis who developed massive hematemesis, what is the most likely cause of this bleeding based on the picture:

- A) Esophagitis
- B) Gastric ulcer
- C) Gastric cancer
- D) Esophageal cancer
- E) Esophageal varices



Answer: E

# Gastric diseases

Q1: Which mutation is mostly associated with hereditary diffuse gastric cancer?

- A) BRCA2.
- B) CDH1.
- C) NF1.
- D) SMARCA4.
- E) P53.

Answer: B

Q2: What is the classic distribution of the inflammatory pattern typically seen in autoimmune gastritis?

- A) Oxyntic predominant gastritis with atrophic changes and intestinal metaplasia.
- B) Antral predominant gastritis with mildly inflamed oxyntic mucosa.
- C) Cardiac lymphoid aggregates and normal antral/oxyntic mucosa.
- D) Diffuse antral and oxyntic gastritis with intestinal metaplasia of antral mucosa.
- E) Cardiac predominant gastritis with atrophic changes and intestinal metaplasia.

Answer: A

Q3: A 52-year-old man has several gastric polyps. Histology shows cystically dilated, irregular glands lined by parietal and chief cells. Which is TRUE about this polyp?

- A) If dysplasia is present, it usually transforms to malignancy.
- B) Associated with Lynch syndrome.
- C) Associated with *H. pylori* infection.
- D) Associated with PPI use.
- E) Most common type of gastric polyps.

Answer: A

Q4: All of the following are true regarding peptic ulcer disease (PUD), EXCEPT:

- A) Duodenal ulcers are less associated with *H. pylori* than gastric ulcers.
- B) NSAIDs can cause peptic ulcer disease.
- C) Upper endoscopy should be done in suspected bleeding PUD.
- D) PPIs are part of treatment.
- E) Stress gastric ulcers can occur after extensive burns.

Answer: A

Q5: Regarding chronic gastritis, which of the following statements is TRUE:

- A) *H. pylori* gastritis affects predominantly the gastric body.
- B) Autoimmune gastritis causes marked hypergastrinemia.
- C) *H. pylori* gastritis can cause pernicious anemia.
- D) Autoimmune gastritis is the most common cause.
- E) *H. pylori* causes decrease in acid production.

Answer: B

Q6: A 72-year-old man takes large amounts of NSAIDs and develops hematemesis. Gastric biopsy will most likely show:

- A) Gastric Adenoma.
- B) Acute gastritis.
- C) Epithelial dysplasia.
- D) Adenocarcinoma.
- E) Helicobacter pylori infection.

Answer: B

Q7: All of the following about chronic gastritis are true, EXCEPT:

- A) *H. pylori* is the most common cause.
- B) Carcinoid tumor could occur secondary to autoimmune gastritis.
- C) *H. pylori* gastritis increases risk of MALToma.
- D) Autoimmune gastritis is mediated by type 4 hypersensitivity and associated with autoimmune diseases.
- E) There is high acid production in *H. pylori* associated pangastritis.

Answer: E

I don't believe this was mentioned ; we've put it just in case

Q8: Autoimmune gastritis is associated with:

- A) Male predominance.
- B) NSAID intake.
- C) Pan-gastritis.
- D) Low gastrin level.
- E) Vitamin B12 deficiency.

Answer: E

Q9: Gastritis is commonly associated with all of the following EXCEPT:

- A) NSAIDs.
- B) Chemotherapy.
- C) Steroid.
- D) Alcohol.
- E) Iron.

Answer: E

Q10: The most common tumor in the stomach is:

- A) MALToma.
- B) Adenocarcinoma.
- C) Carcinoid tumor.
- D) T-cell lymphoma.
- E) Gastrointestinal Stromal Tumor.

Answer: B

Q11: A 67-year-old woman has experienced severe nausea, vomiting, early satiety, and a 9-kg weight loss over the past 4 months. Upper gastrointestinal endoscopy shows that the entire gastric mucosa is eroded and the wall of the stomach is rigid and thickened. Under microscopic examination the cells are discohesive. Which of the following is most likely to be found on histologic examination of a gastric biopsy specimen?

- A) Chronic atrophic gastritis.
- B) Primary gastric lymphoma.
- C) Intestinal-type adenocarcinoma.
- D) Granulomatous inflammation.
- E) Signet ring cell adenocarcinoma.

Q12: Autoimmune gastritis is typically associated with which of the following?

- A) Decreased gastrin levels
- B) Hyperchlorhydria
- C) Pernicious anemia
- D) Mucosa associated lymphoid tissue (MALT) lymphoma
- E) Spares the body of the stomach

Answer: C


Q13: Presence of which of the following risk factors is strongly associated with the development of gastric adenocarcinoma, intestinal type?

- A) Inherited APC gene mutation
- B) Vitamin B12 deficiency
- C) Helicobacter pylori infection
- D) Chronic alcohol abuse
- E) Use of non-steroidal anti-inflammatory drugs

Answer: C

Q14: A 50-year-old man in the intensive care unit (ICU) after a major surgery, and suddenly developed hematemesis, based upon the picture given above from the stomach, the most likely diagnosis is:

- A) Gastric carcinoma
- B) Autoimmune gastritis
- C) Viral gastritis
- D) Stress ulcers
- E) Chronic H pylori gastritis



Answer: D

# Intestinal Diseases

Q1: Which of the following conditions results in steatorrhea?

- A) Deficiency of vitamin B12
- B) Malabsorption of proteins.
- C) Lactase deficiency.
- D) Maldigestion of lipids.
- E) Decreased secretion of intrinsic factor.

Answer: D

Q2: Which of the following conditions that cause intestinal obstruction has been incorrectly described?

- A) Volvulus is a congenital disease that can be complicated by infarction to the bowel.
- B) Intussusception Is the most common cause of intestinal obstruction in children younger than 2 years and is characterized by a currant jelly stool.
- C) The presence of intussusception in adults is highly suggestive of intraluminal mass or tumor.
- D) Hirschsprung Disease is a defect in colonic innervation. It tends to be more severe in males and more common in females.
- E) Hernia is a protrusion of bowel segment and its mesentery through a defect in abdominal wall.

Answer: D

Q3: A 34-year-old woman is bothered by a low-volume, mostly watery diarrhea associated with flatulence. She has experienced a 4-kg weight loss. She has no fever, nausea, vomiting, or abdominal pain. A stool sample is negative for occult blood, ova, and parasites, and a stool culture yields no pathogens. An upper gastrointestinal endoscopy is performed and a biopsy specimen from the upper part of the small bowel shows severe diffuse blunting of villi and a chronic inflammatory infiltrate in the lamina propria. Which of the following statements correctly describes this disease?

- A) Anti-endomysial antibody is the most sensitive serological test.
- B) The biopsy should be obtained from the proximal duodenum
- C) The main treatment of choice is corticosteroids
- D) 50% of patients will develop skin lesions called dermatitis herpetiformis
- E) people with HLA-DQ2 and HLA-DQ8 have more genetic predisposition

Answer: E

Q4: All of the following are features of celiac disease except:

- A) Associated with HLA-DQ2
- B) Gluten hypersensitivity
- C) Increased risk for small bowel cancer
- D) Onset in children or adult
- E) Microscopically shows increased intraepithelial neutrophils and villous atrophy

Answer: E

Q5: The most common site for Hirschprung disease is:

A) Right colon

B) Anus

C) Left colon

D) Sigmoid

E) Rectum

Answer: E

Q6: A 25-year-old man presented complaining of steatorrhea and found to have iron deficiency anemia. Serology showed elevated levels of anti TTG and anti-endomysial antibodies. What would you expect to see upon microscopic examination of a biopsy from the duodenum for this patient ?

- A) Marked neutrophils infiltration
- B) Increased intraepithelial lymphocytes and villous atrophy
- C) Dilated lymphatic spaces
- D) Pseudopolyps
- E) Lipid accumulation in the cytoplasm of epithelial cells

Answer: B

**Q7: Which of the following is associated with celiac disease:**

**Answer: Dermatitis herpetiformis**

Q8: A 32-year-old lady with ulcerative colitis, she is at greatest risk for development of which of the following conditions:

- A) Appendicitis.
- B) Acute pancreatitis.
- C) Perianal fistulas.
- D) Colonic fissures.
- E) Sclerosing cholangitis.

Answer: E

Q9: Which of the following is a feature of both UC and Crohn disease?

- A) The presence of non-caseating granuloma in 35% of cases
- B) stenosis and narrowing of the lumen due to fibrosis in the bowel wall
- C) There is a recurrence after surgery
- D) They have a risk of a perianal fissure development
- E) In colonic involvement, they carry a risk for malignant transformation

Answer: E

Q10: All of the following are features of diverticulitis except:

- A) Flask shape outpouches
- B) Associated with low-fiber diet
- C) Irregular distribution
- D) Predispose to fibrosis and segment stenosis

Answer: C

Q11: All of the following favor the diagnosis of ulcerative colitis over Crohn disease except:

- A) Presence of non-caseating granulomas
- B) Continuous inflammation
- C) Superficial mucosal inflammation
- D) Toxic megacolon
- E) Absence of fistula

Answer: A

Q12: A 32-year-old patient diagnosed with chronic inflammatory bowel disease, CROHN type, which of the following is most likely a typical feature:

- A) Non caseating granulomas on microscopic examination
- B) Almost always involves the rectum
- C) The small intestine is typically spared
- D) Inflammation limited to mucosa and submucosa
- E) Colectomy cures the disease

Answer: A

Q13: Which of the following strongly favors Crohn disease over ulcerative colitis:

- A) Absence of skip lesions
- B) inflammation limited to the colon
- C) Inflammation limited to mucosa and submucosa
- D) Development of colonic tubular adenomas
- E) Presence of granulomas

Answer: E

Q14: A clinical case; a patient with focal points limited to the mucosa  
from the rectum to the transverse colon

Answer: risk for primary sclerosing cholangitis is higher

Q15: The most important risk for malignancy in large bowel adenoma is:

- A) Duration of the lesion
- B) Architecture
- C) Size
- D) Anatomic location
- E) Number of polyps

Answer: C

Q16: Which of the following colonic polyposis syndromes is typically associated with central nervous system tumors:

- A) Turcot syndrome
- B) Peutz-Jeghers syndrome
- C) Gardner syndrome
- D) Juvenile polyposis syndrome
- E) Lynch syndrome

Answer: A

Q17: Which of the following is true about familial adenomatous polyposis syndrome (FAP):

- A) Germline mutation in DNA mismatch repair genes
- B) Germline mutation in E-cadherin gene
- C) Colorectal carcinoma of the right-side colon predominates
- D) 100% of patients will develop colon carcinoma by the age of 30
- E) Mucocutaneous hyperpigmentation

Answer: D  
( if untreated )

Q18: Which of the following colonic polyps show dysplasia on microscopic examination and are considered a precursor of colonic adenocarcinoma:

- A) Inflammatory polyp
- B) Hyperplastic polyp
- C) Juvenile polyps
- D) Peutz-Jeghers polyps
- E) Colonic adenoma

Answer: E

Q19: Which of the following is associated with thyroid tumor :

- A) Turcot syndrome
- B) Peutz-Jeghers syndrome
- C) Gardner syndrome
- D) Lynch syndrome
- E) Juvenile polyposis syndrome

Answer: C

Q20: A 32-year-old lady with ulcerative colitis, she is at greatest risk for development of which of the following conditions:

- A) Appendicitis
- B) Acute pancreatitis
- C) Perianal fistulas
- D) Colonic fissures
- E) Sclerosing cholangitis

Answer: E

Q21: The most common tumor of the appendix:

- A) Appendiceal adenocarcinoma
- B) Tubular adenoma
- C) Carcinoid tumor
- D) Signet ring carcinoma
- E) Lymphoma

Answer: C

**Q22: The most important feature for prognosis in colon cancer is:**

**Ans : Depth and nodal metastasis**

Q23: The most common cause of acute appendicitis is:

- A) Worms
- B) Crohn disease
- C) Mucocele
- D) Carcinoid
- E) Fecolith impaction

Answer: E

Q24: A 35-year-old patient presents with mucosal inflammation extending continuously from the rectum to the transverse colon. Which of the following conditions is most strongly associated with this disease?

- A) Crohn disease
- B) Dermatitis herpetiformis
- C) Primary sclerosing cholangitis
- D) Peutz-Jeghers syndrome
- E) Whipple disease

Answer: C

# Disorders of the Gallbladder

- **There were no past exam questions available for this lecture; the following questions are all Test bank**

Q1. Which of the following statements about cholesterol stones is TRUE?

- A) They are found throughout the biliary tree
- B) Most are radiopaque
- C) They are exclusively found in the gallbladder
- D) Pure cholesterol stones are black in color

سبحان الله وبحمده  
سبحان الله العظيم

Answer:C

Q2. What is a possible intestinal complication of untreated cholelithiasis?

- A) Toxic megacolon
- B) Gallstone ileus
- C) Volvulus
- D) Intussusception

سبحان الله ، الحمد لله  
لا إله إلا الله، الله أكبر

Answer:B

Q3. Cholecystitis is almost always associated with which of the following?

- A) Viral hepatitis
- B) Biliary atresia
- C) Gallstones
- D) Pancreatic cysts

اللهم صلِّ وسلم وبارك على سيدنا  
محمد وعلى آله وصحبه أجمعين

Q4. Which statement is TRUE about the prognosis of gallbladder carcinoma?

- A) Prognosis is good with chemotherapy alone
- B) Early diagnosis is common
- C) It has a poor prognosis with only 1% 5-year survival
- D) It does not metastasize outside the biliary system

أستغفر الله العظيم وأتوب إليه

Q5. What is the best initial diagnostic tool for suspected cholecystitis?

A) Ultrasonography

B) CT scan

C) Colonoscopy

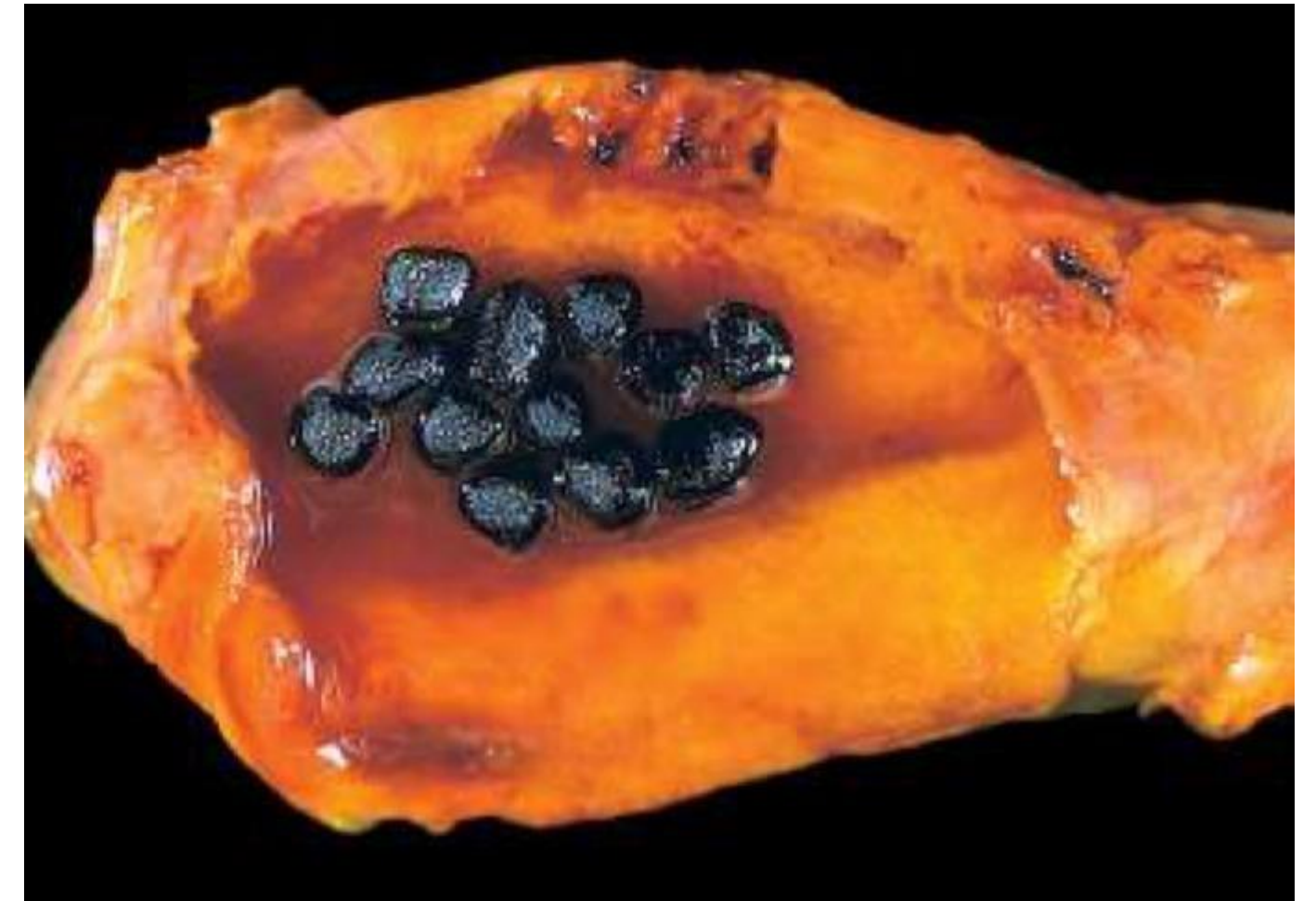D) MRI

لا حول ولا قوة إلا بالله العلي العظيم

Answer:A

Q6. A 45-year-old man with a history of chronic hemolytic anemia presents with intermittent right upper quadrant pain. Imaging reveals multiple small, black radiopaque gallstones. Which of the following is the most likely composition of these stones?

- A) Cholesterol monohydrate
- B) Calcium carbonate
- C) Mixed bile salts
- D) Calcium bilirubinate



Answer:D

رسالة من الفريق العلمي:

وَلَبِّ فِئْتِ اللَّهِ

ظن لا يخيب

# For any feedback, scan the code or click on it.



Corrections from previous versions:

Versions	Slide # and Place of Error	Before Correction	After Correction
V0 → V1			
V1 → V2			