

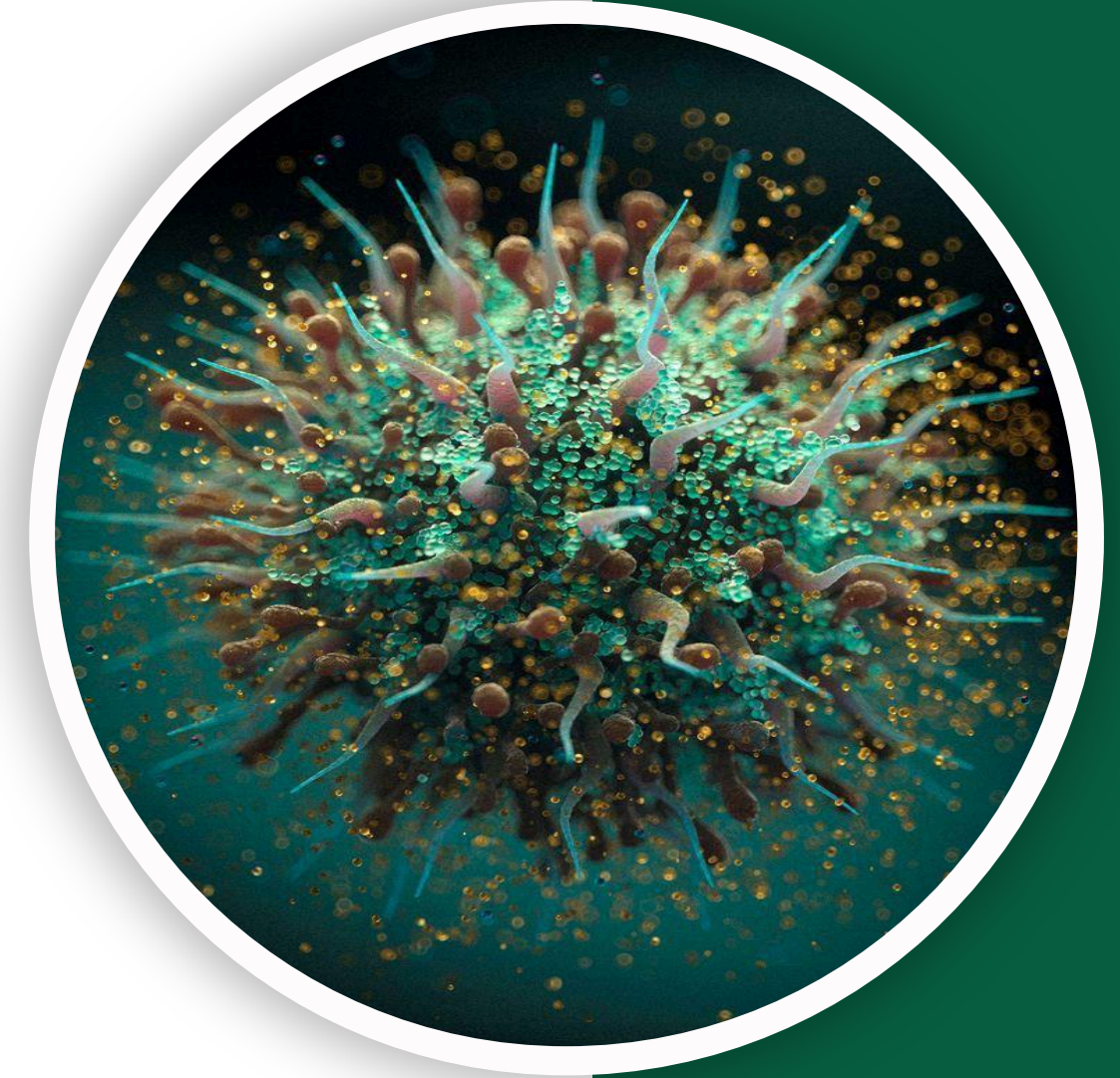
بِسْمِ اللّٰهِ الرَّحْمٰنِ الرَّحِیْمِ
(وَفَوْقَ كُلِّ ذِي عِلْمٍ عَلِيمٌ)



جِلْدَان

GIS Pathology | MID 7

Intestinal Diseases Pt.3



Written by : DST

Reviewed by : Layan Bassam
Rawan Okour

Intestinal pathology, part 3

Manar Hajeer, MD, FRCPath
University of Jordan, School of medicine



Diseases of the intestines

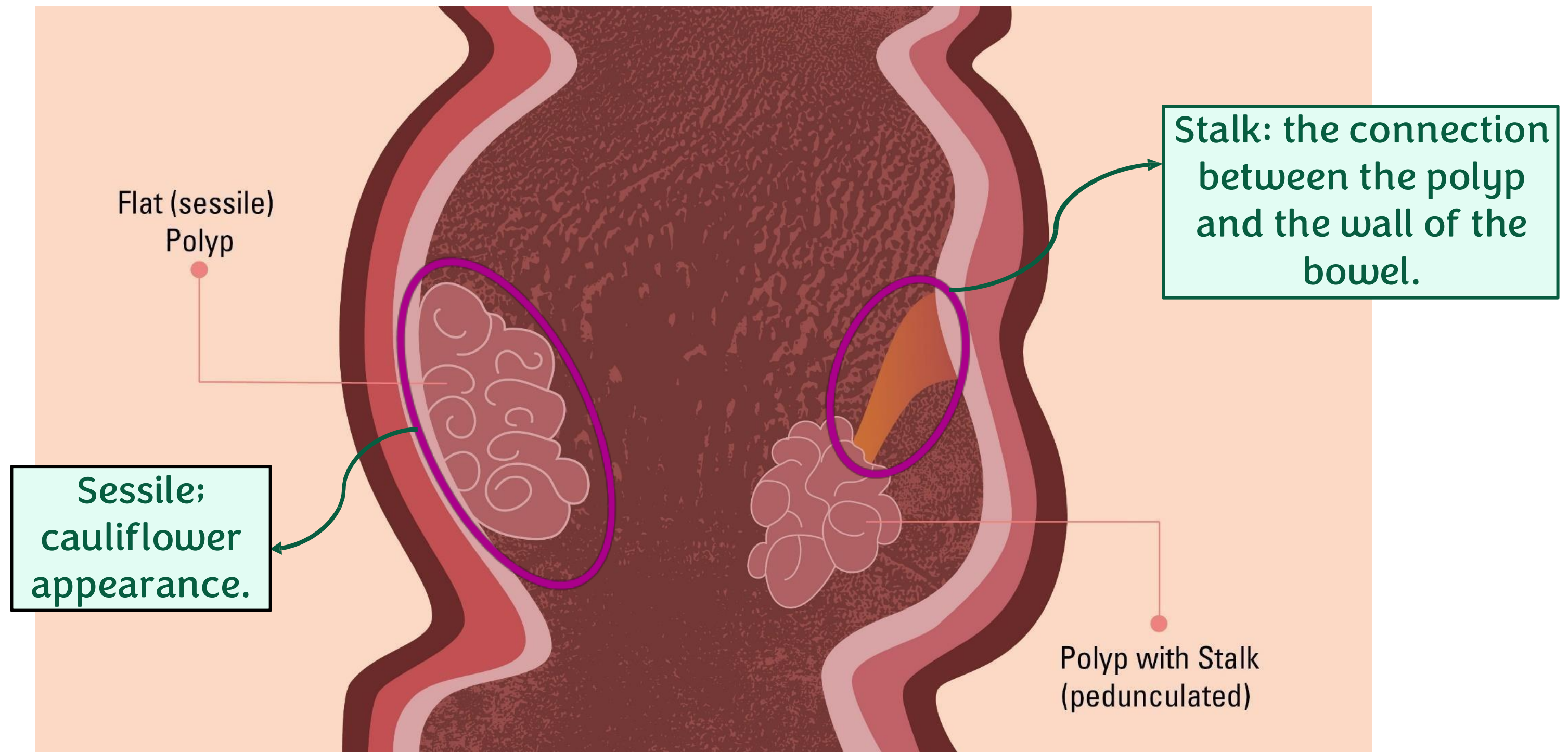
Are divided into :

- ▶ Intestinal obstruction
- ▶ Vascular disorders
- ▶ Malabsorptive diseases and infections
- ▶ Inflammatory intestinal diseases.
- ▶ **Polyps and neoplastic diseases** We will be discussing polyps in this lecture

COLONIC POLYPS AND NEOPLASTIC DISEASE

- We can divide polyps according to their architecture seen during endoscopy into : sessile or pedunculated.
- They are also divided into: neoplastic & non neoplastic
 - ▶ Colon is most common site for polyps
 - ▶ *Sessile polyp*: no stalk
 - ▶ *Pedunculated polyp* are attached to the wall of the bowel or the intestine by a : *stalk*(a narrow fibrovascular core that connects the polyp to the mucosal surface of the bowel wall)
 - ▶ *Neoplastic polyps: adenomas*, in which there is dysplasia and considered precursors of malignancy.
 - ▶ *Non neoplastic polyps* encompass a group of polyps that are : inflammatory, hamartomatous, or hyperplastic.

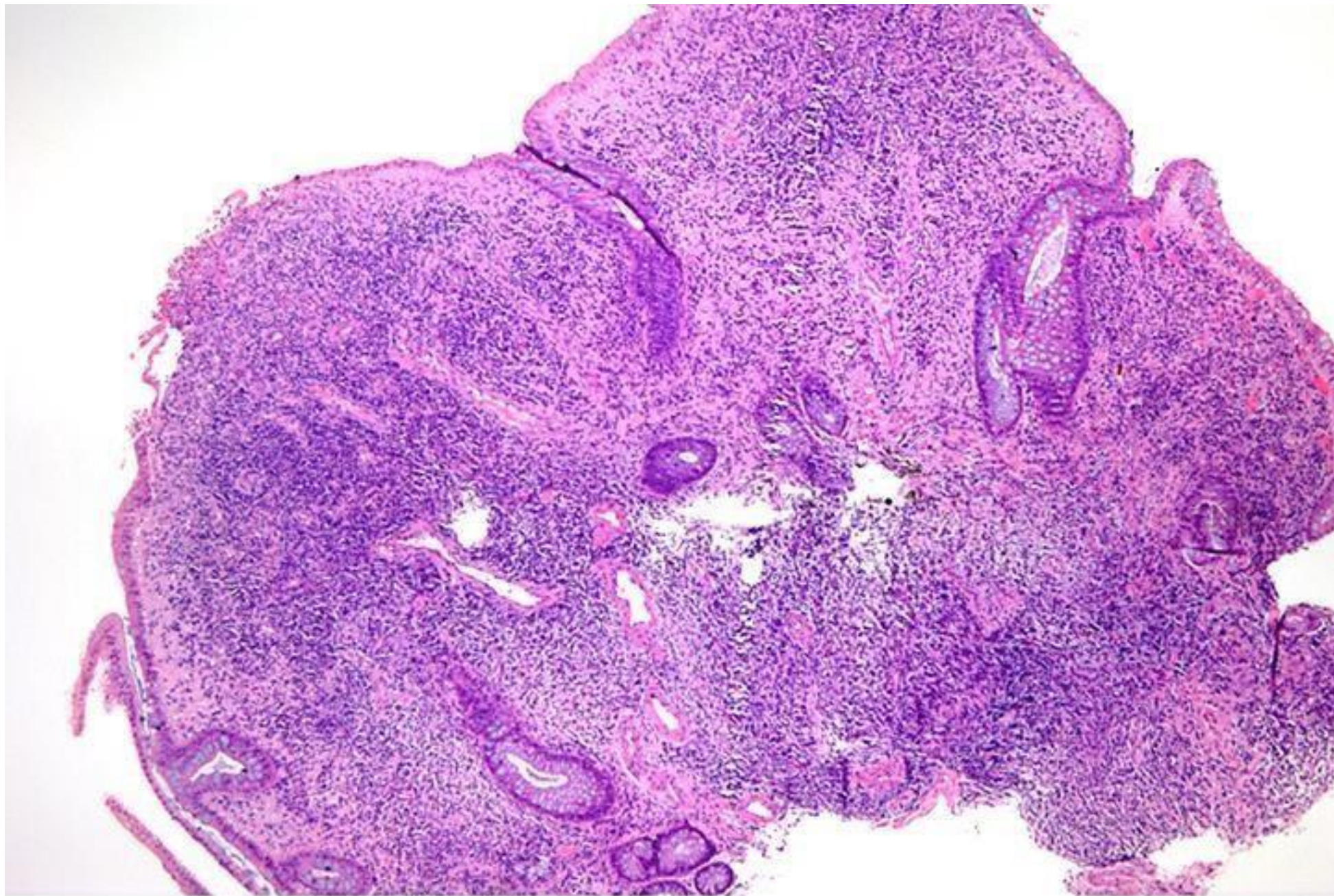
As a conclusion the polyp is any overgrowth above the level of mucosa



Inflammatory Polyps

- ▶ Solitary rectal ulcer syndrome, **it is the typical type of inflammatory polyps, it is due to:**
 - ▶ Impaired relaxation of anorectal sphinctor.
 - ▶ Recurrent abrasion and ulceration of the overlying rectal mucosa.
 - ▶ Chronic (**repeated**) cycles of injury and healing give a polypoid mass of inflamed and reactive mucosal tissue.
- ▶ **Patient presents with:**
 - ▶ Rectal bleeding, mucus discharge and polyp.

Inflammatory polyps



4x: low power, dense inflammation in lamina propria

Histopathologic examination reveals:

1 Inflammatory mass filled with inflammatory cells

- The bluish foci are inflammatory cells including:
Neutrophils , lymphocytes & plasma cells

2 the surface of the polyp is ulcerated & eroded

3 Glands are scant ,only few glands are left; due to destruction by inflammation

4 glands are benign looking

- Note: inflammatory polyps can also be seen in the context of inflammatory bowel diseases

Hamartomatous Polyps

- ▶ Sporadic or syndromic, **under the microscope they look the same**
- ▶ Hamartomatous polyposis syndromes (**syndromic type**)
- ▶ Disorganized, tumor-like growth composed of mature cell types normally present at that site.

So if you are in the colon and you find disorganized mass or tumor, composed of: glands, smooth muscle cells, nerves & blood vessels. All of these structures are related to the colon (can be found normally there).

➤ **Hamartomatous polyps can be :**

- ▶ Juvenile Polyps

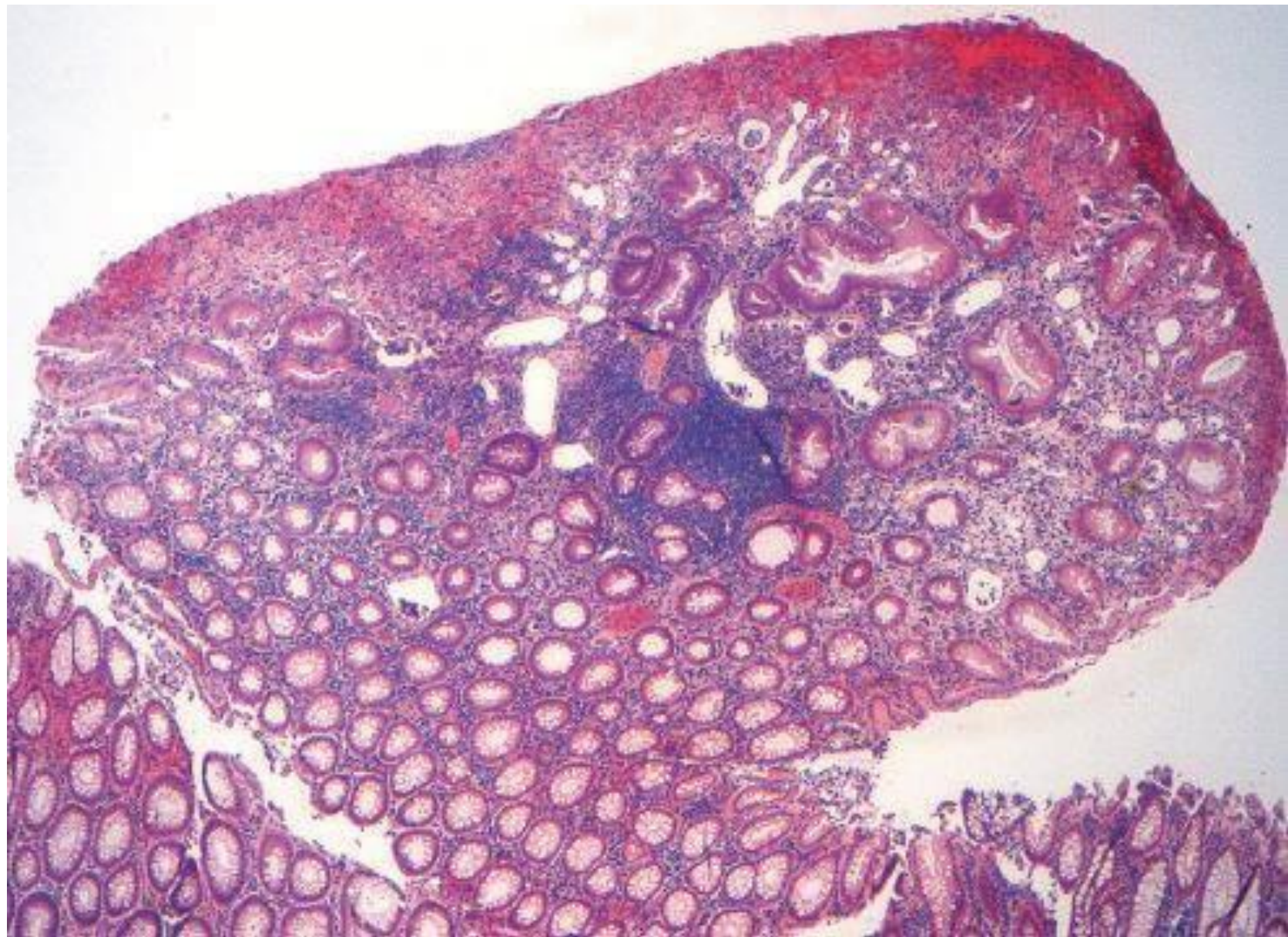
or

- ▶ Peutz-Jeghers Syndrome

Juvenile Polyps

- ▶ Most common hamartomatous polyp
They can be sporadic or syndromic :
- ▶ **Sporadic**
- ▶ Solitary. <5 years of age (usually only one polyp is found in a child under 5yrs old)- this is the typical presentation
- ▶ usually they are seen in the Rectum,& present with rectal bleeding.
- ▶ **Syndromic (juvenile polyposis) .**
- ▶ Dozens. < 5 years , **not single**
- ▶ Autosomal dominant **inherited syndrome**
- ▶ **Mutation in** Transforming growth factor- β (TGF- β **gene**) signaling pathway
- ▶ germline mutation (SMAD4 **gene**) is seen here because it is an **inherited syndrome**
- ▶ Increased risk for colonic adenocarcinoma and others.

Juvenile Polyps



- ▶ usually Pedunculated present with stalk
- ▶ Reddish lesions due to the presence of surface ulcerations, granulation tissue & new blood vessel formation
- ▶ Cystic spaces on cut Sections correspond to the:
 - ▶ Dilated glands filled with mucin and inflammatory debris.
 - ▶ Granulation tissue on surface.
- These polyps are devoid of dysplasia (there is no dysplasia)
- Benign polyps, but if they are part of the syndrome then there is an increased risk of malignancy

Peutz-Jeghers Syndrome

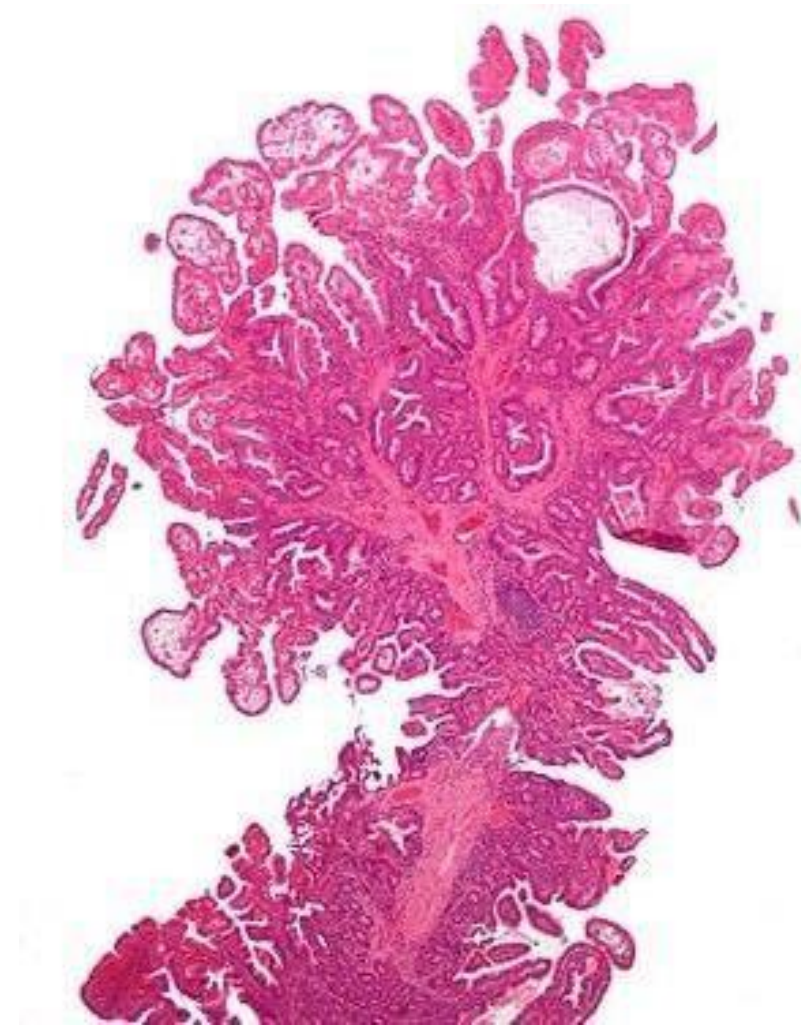
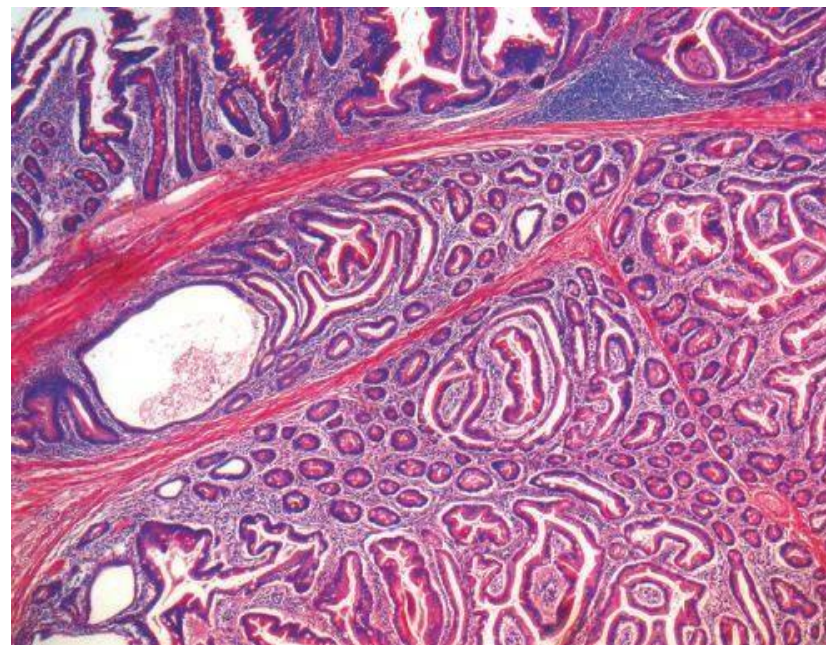
*Mostly present as a syndrome

- ▶ Autosomal dominant inherited syndrome , rare it presents with a **triad** of manifestations:
- ▶ Multiple gastrointestinal hamartomatous polyps (not only one polyp)
- ▶ Mucocutaneous hyperpigmentation (increased melanin pigment in the skin & mucous membrane of the mouth)
- ▶ Increased risk for several malignancies: colon (colorectal), pancreas, breast, lung, ovaries, uterus, and testes

These patients carry this germ-line mutation:

- ▶ *LKB1/STK11* germline mutation (tumor suppressor protein).

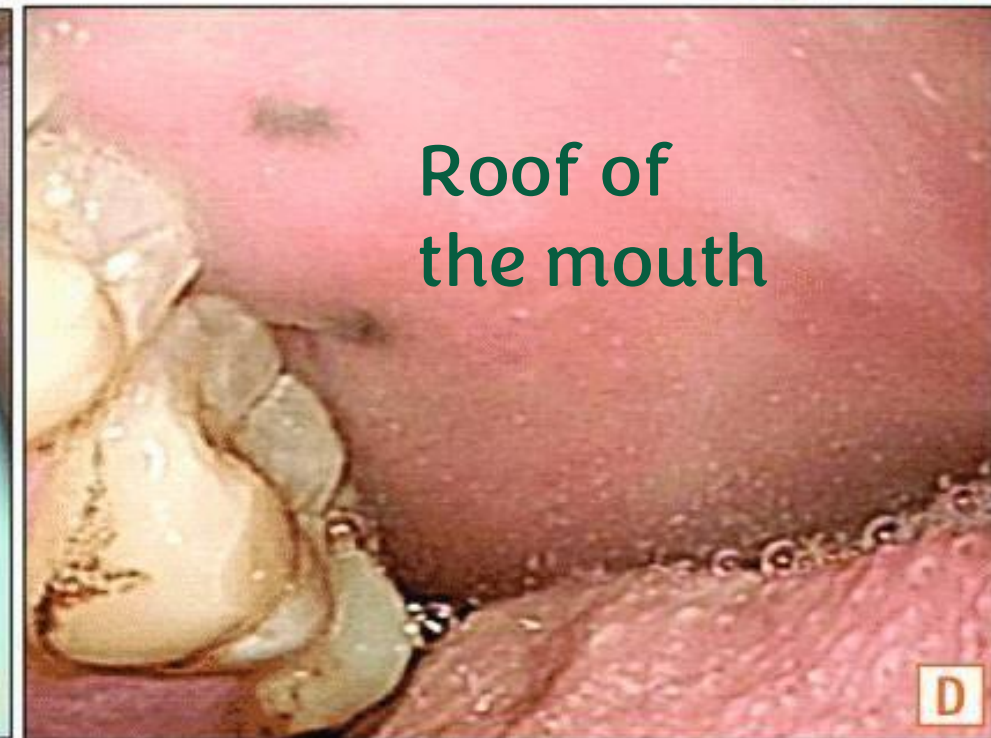
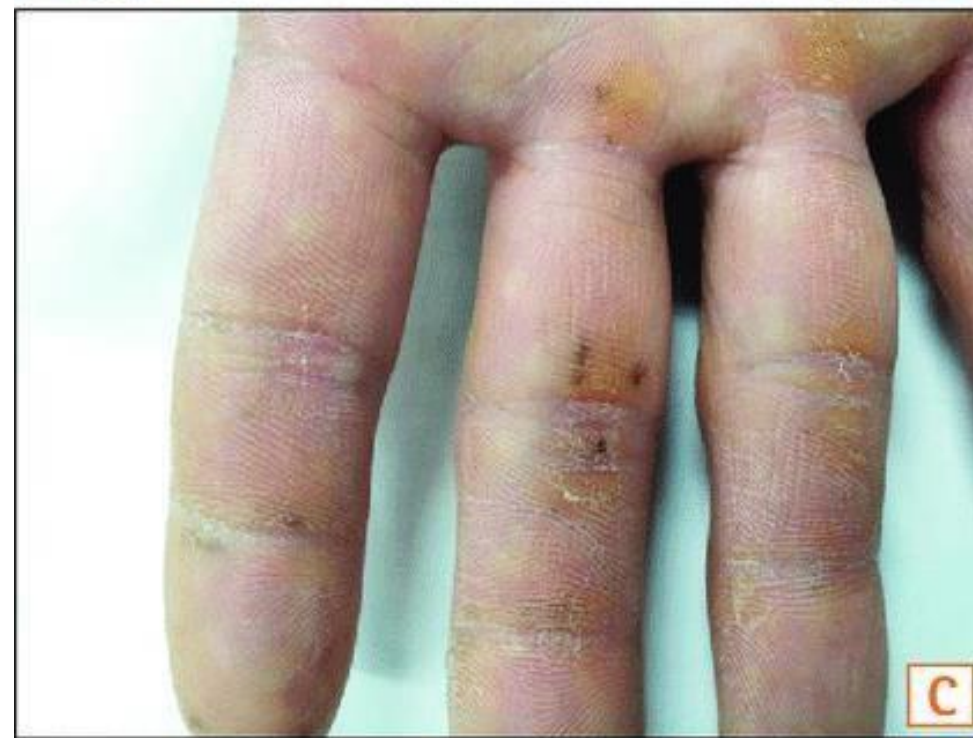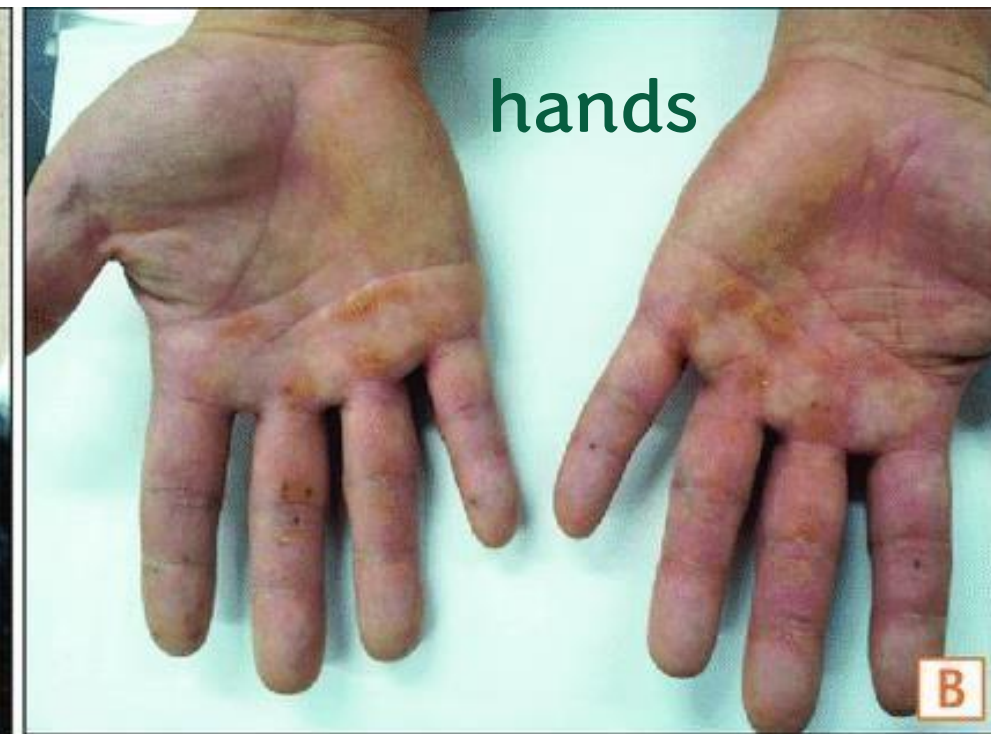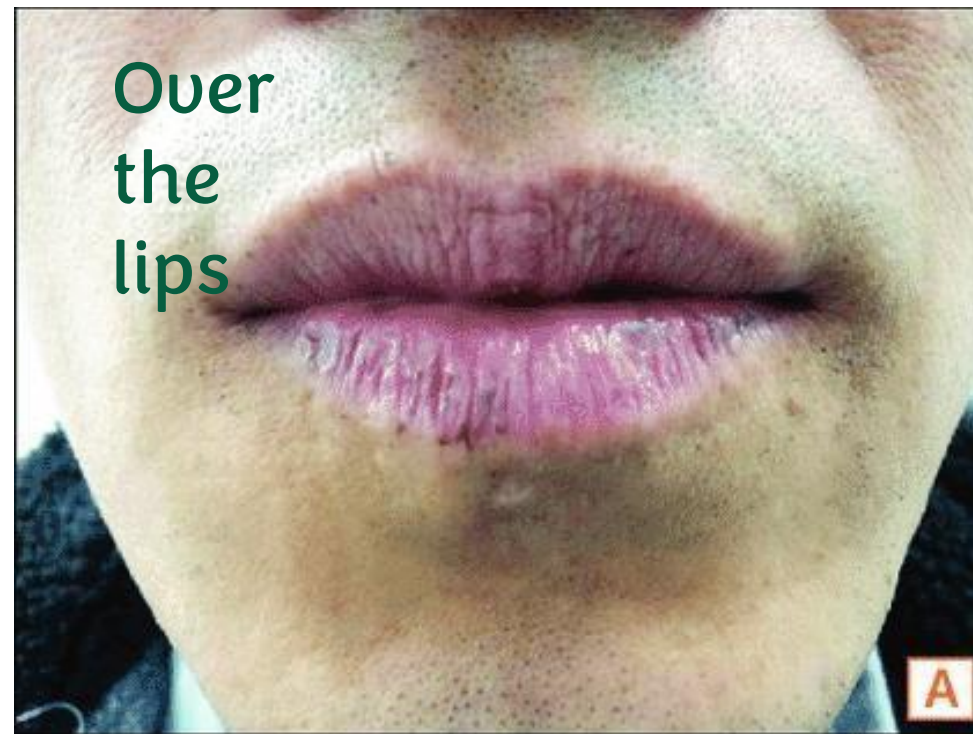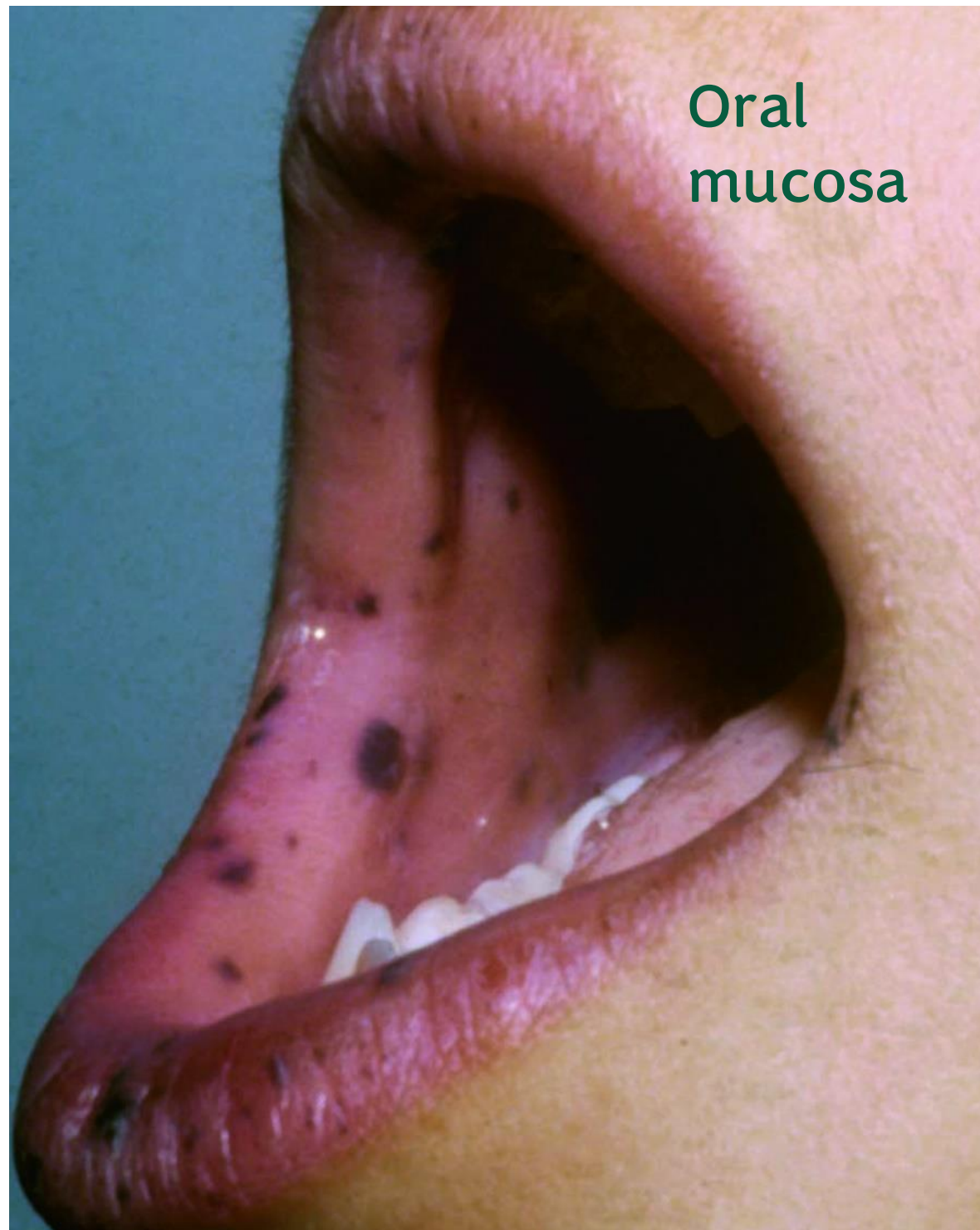Peutz-Jeghers polyp



- ▶ Mostly in small intestine –other types of polyps are usually seen in the colon.
- ▶ Large, pedunculated (with stalk), lobulated.
- ▶ Arborizing network of connective tissue, smooth muscle, lamina propria and glands (normal lining epithelium)
- ▶ Normal-appearing intestinal epithelium
- ▶ These polyps have a distinctive appearance under the microscope :Christmas tree pattern.
- ▶ No dysplasia, but an increased risk of malignancy as part of the syndrome

Mucocutaneous pigmentation Peutz-Jeghers syndrome:

hyperpigmentation



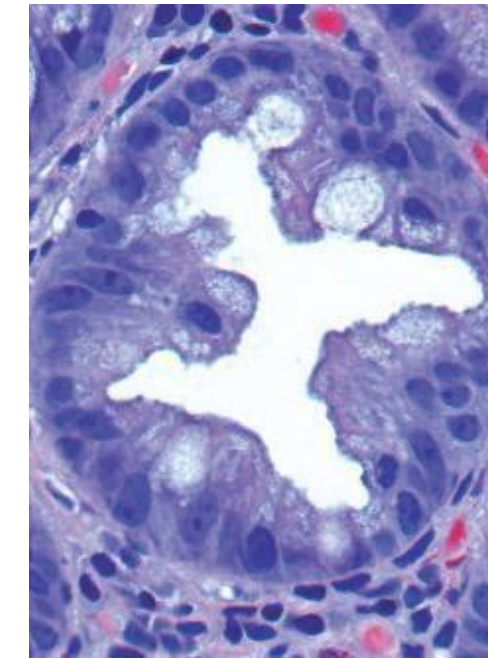
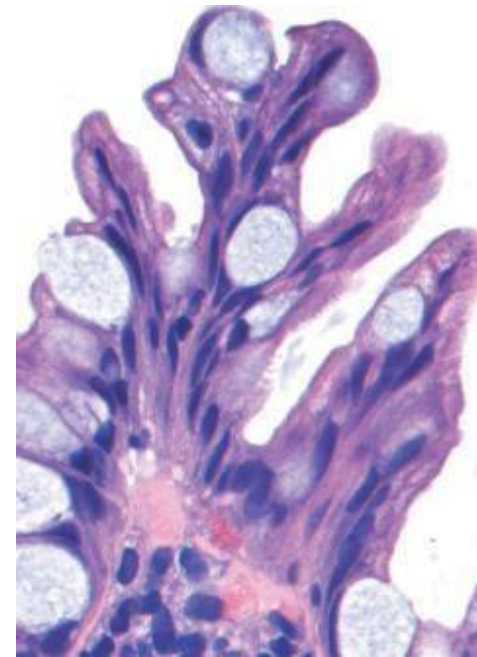
Hyperplastic Polyps

- ▶ Common
- ▶ 6-7th decades. They occur with advancing in age
- ▶ Pathogenesis includes: Decreased epithelial turnover and delayed shedding of surface epithelium
 - >>> pileup of goblet cells & epithelial overcrowding
 - So cell will not die, they will accumulate & pile up in the polyp
- ▶ **No malignant potential**
- ▶ **Biopsy is important**, to differentiate them from other types of polyps.
 - During colonoscopy all polyps look the same so the gold standard to **differentiate** between them is the **histopathology** and the **presence or absence of dysplasia**.

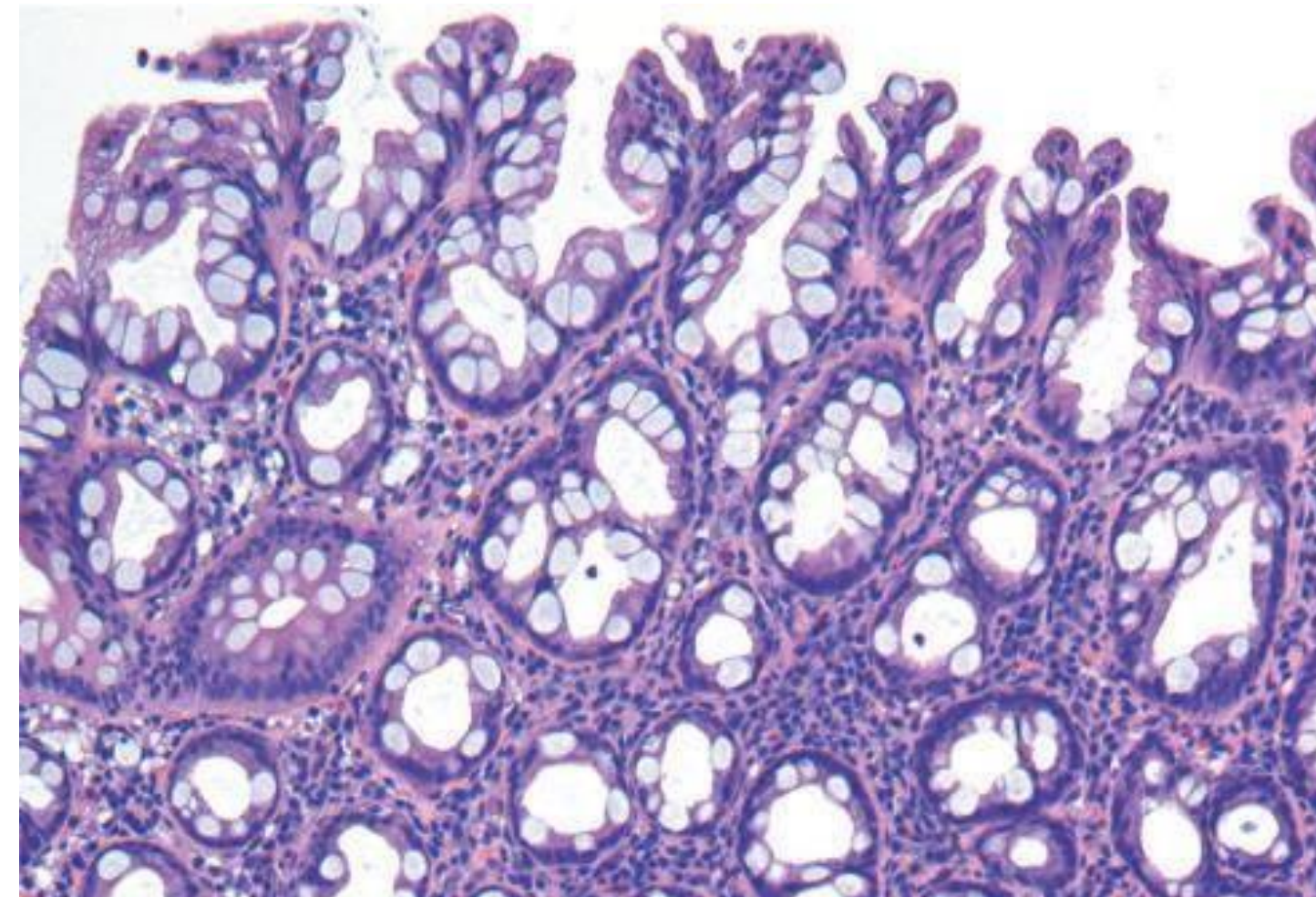
Hyperplastic polyp

- ▶ Mostly seen in Left colon
- ▶ especially in Recto-sigmoid. Small < 5 mm
- ▶ Often multiple
- ▶ Crowding of goblet & absorptive cells.
- ▶ Serrated surface.
- ▶ Serrated appearance is only seen at the surface of the polyp (مثل أسنان المشط)


A lot of goblet cells and absorptive intestinal epithelial cells



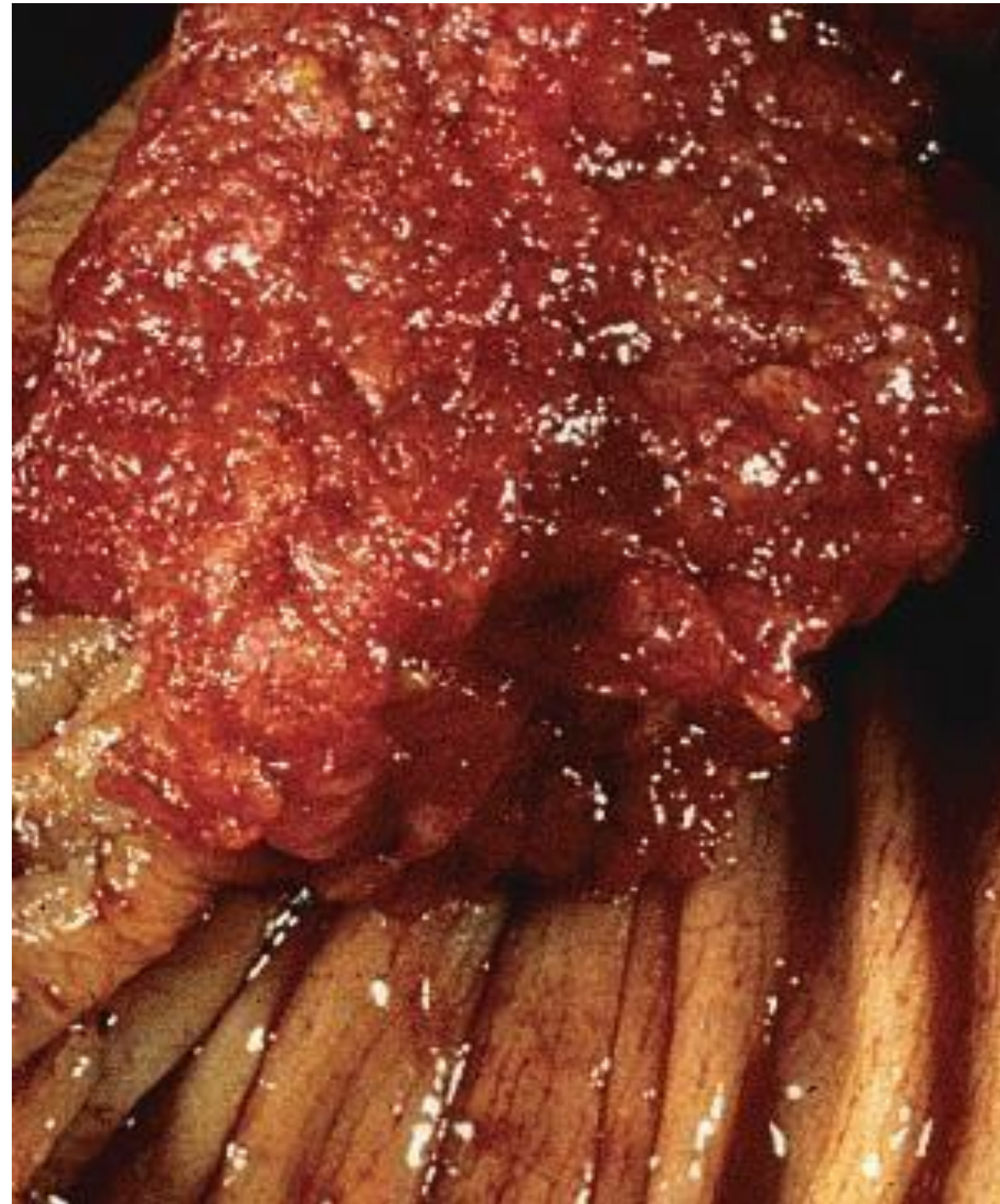
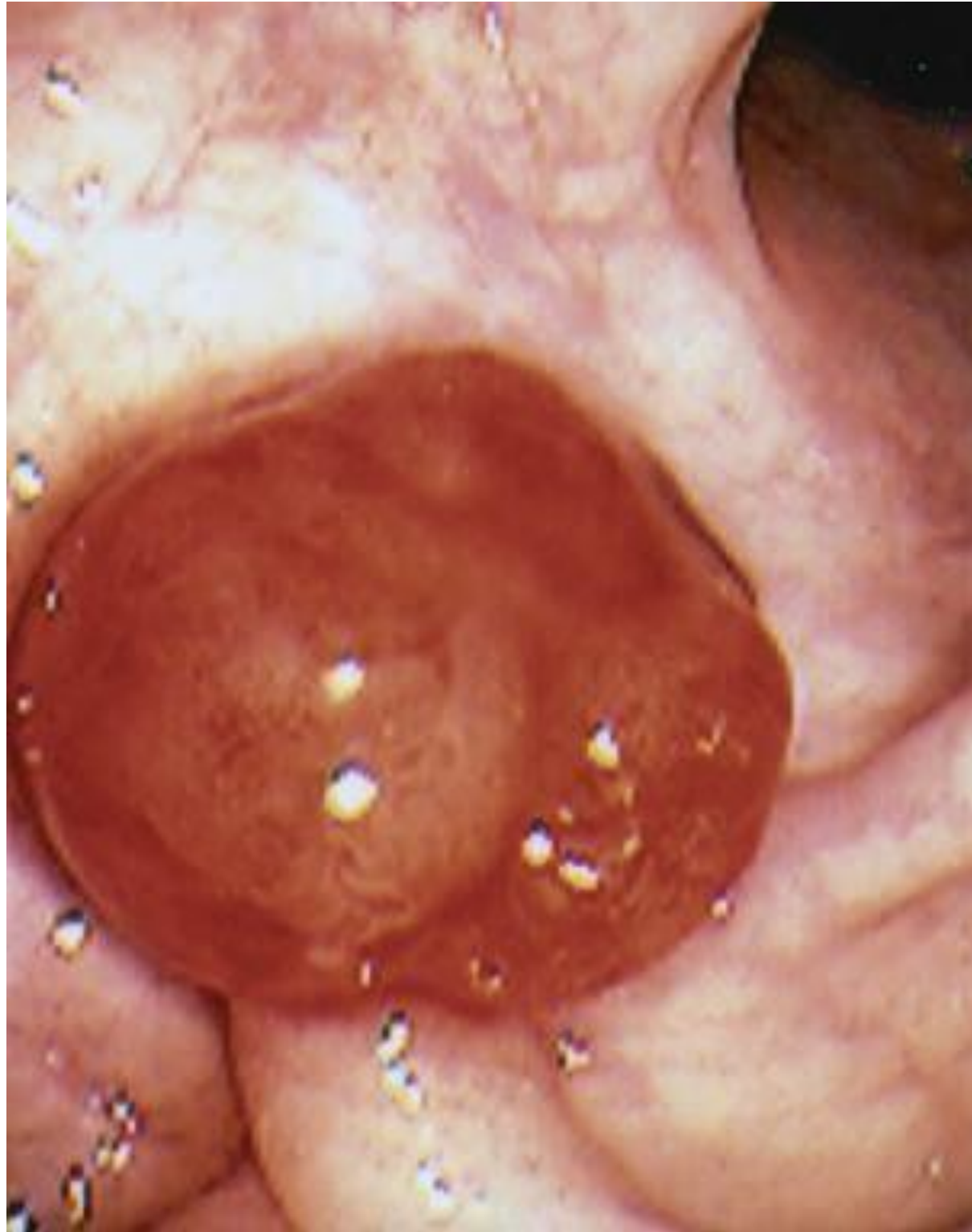On a cut section the crypts will have a STAR appearance



Adenomas

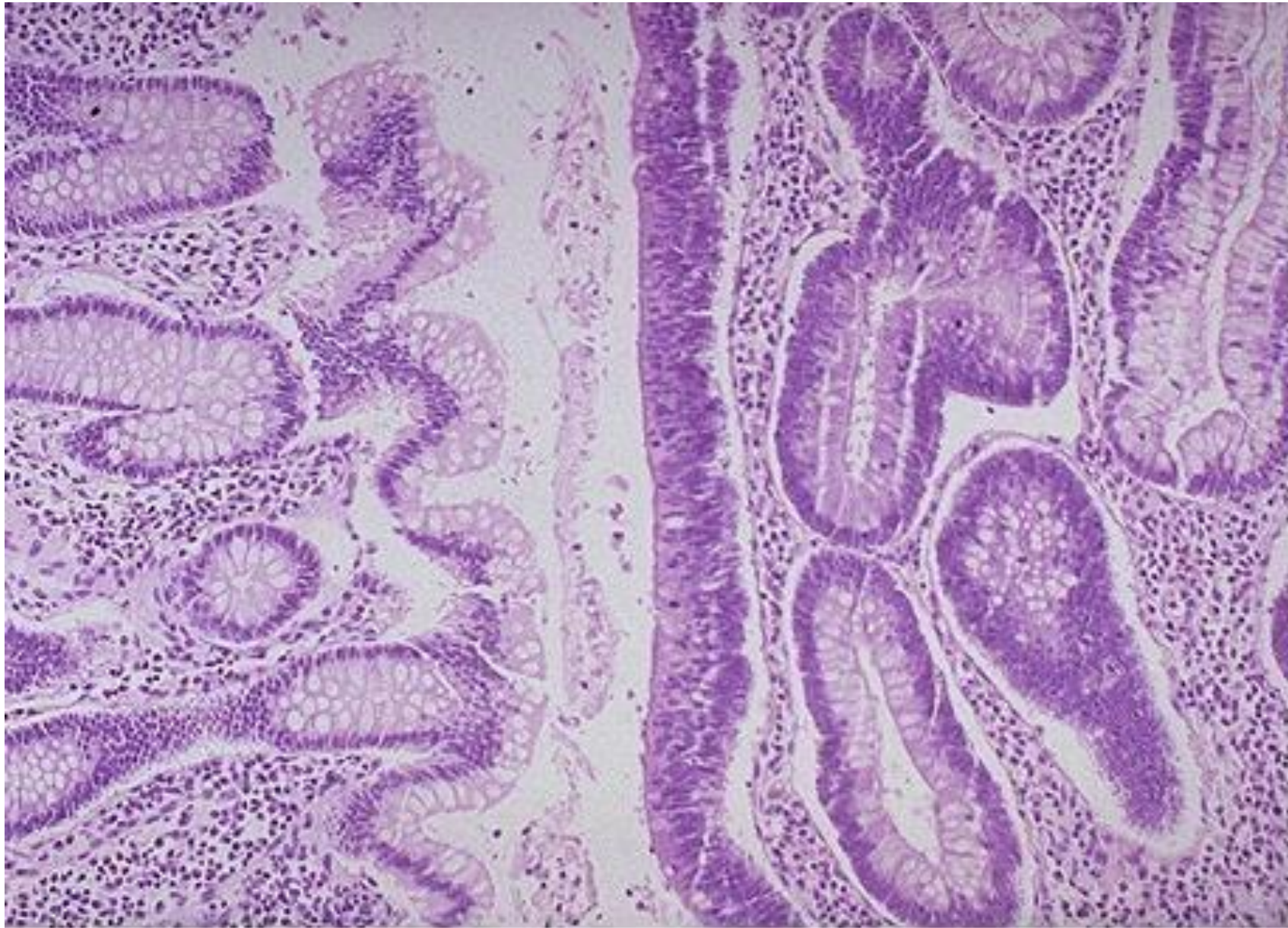
- ▶ Most common and clinically important **because they are considered**
 - ▶ 50% of adults > 50 years. (western world)
 - ▶ **Precursors for majority of colorectal adenocarcinomas**
 - ▶ USA: screening colonoscopy starts at 45 yrs **to detect it at early age**
 - ▶ Earlier screening with family history (screening should start **before 10 years from the youngest age at which the cancer is diagnosed in the family**)
So if adenomas were diagnosed at the age of 40, screening starts at the age of 30
 - ▶ **Western diets (availability of red meat & low fiber diet) and lifestyles increase risk.**
- 

Pedunculated or sessile



- The Gold standard way to differentiate between the polyps is the histopathologic examination, because all of them will look the same upon colonoscopy.

Colon adenoma

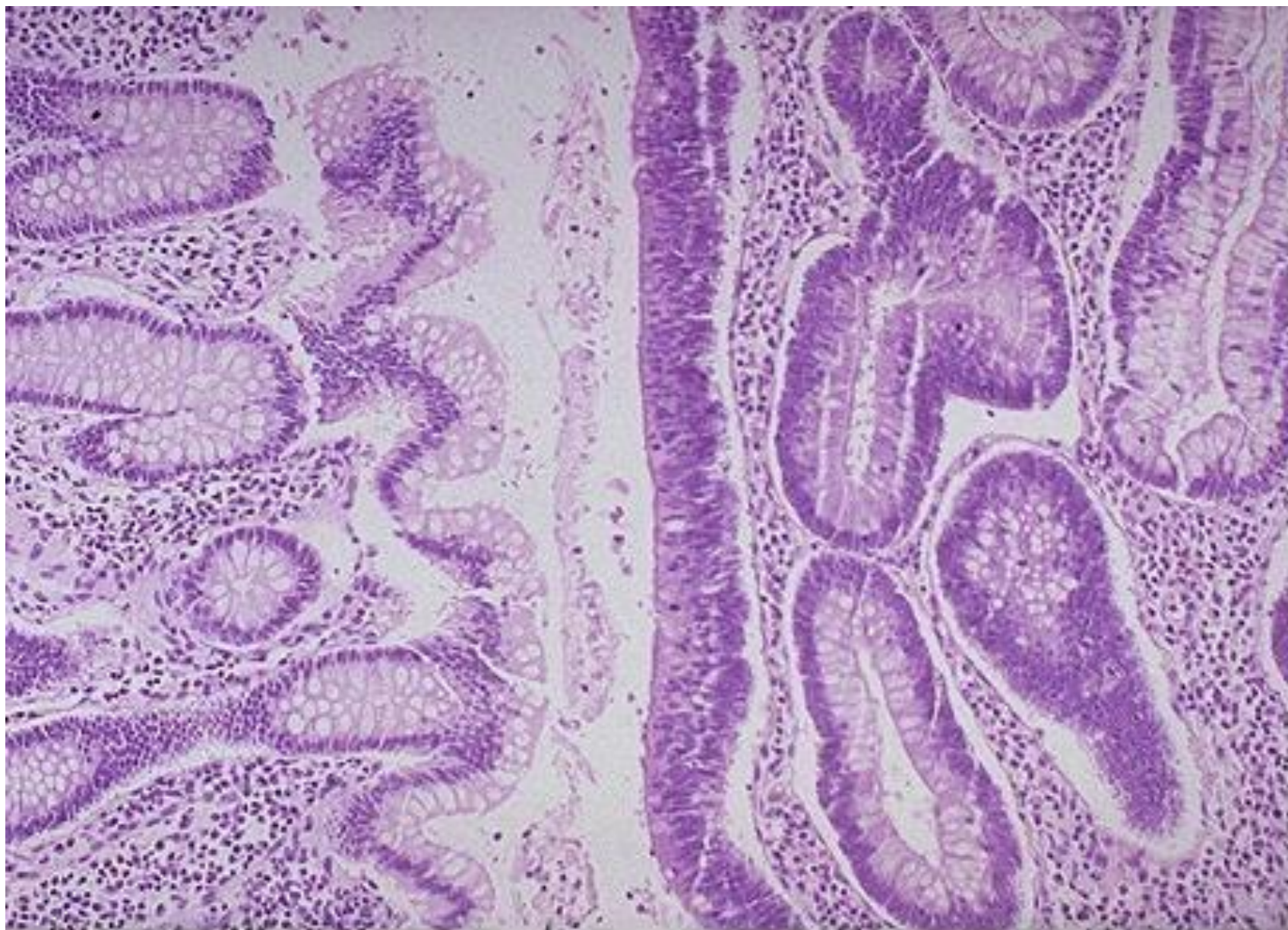


Check the next slide

- ▶ Hallmark: epithelial dysplasia
 - ▶ **Dysplasia is defined as** : Nuclear hyperchromasia, elongation, stratification **of the nuclei (over each other) , high N/C ratio.**
 - ▶ Size is most important correlate with risk for malignancy. **(40% if > 4cm) (if the adenoma's size is >4cm , 40% of them will have an invasive focus)**
 - ▶ **The second most important factor is the presence High-grade dysplasia is a second factor**
- The higher the grade the higher the risk of developing carcinoma .**
- ▶ **Architecture: Tubular, villous, tubulovillous. (They are divided according to their architecture NOT according to the risk of malignancy)**

Histopathology of Colon Adenoma

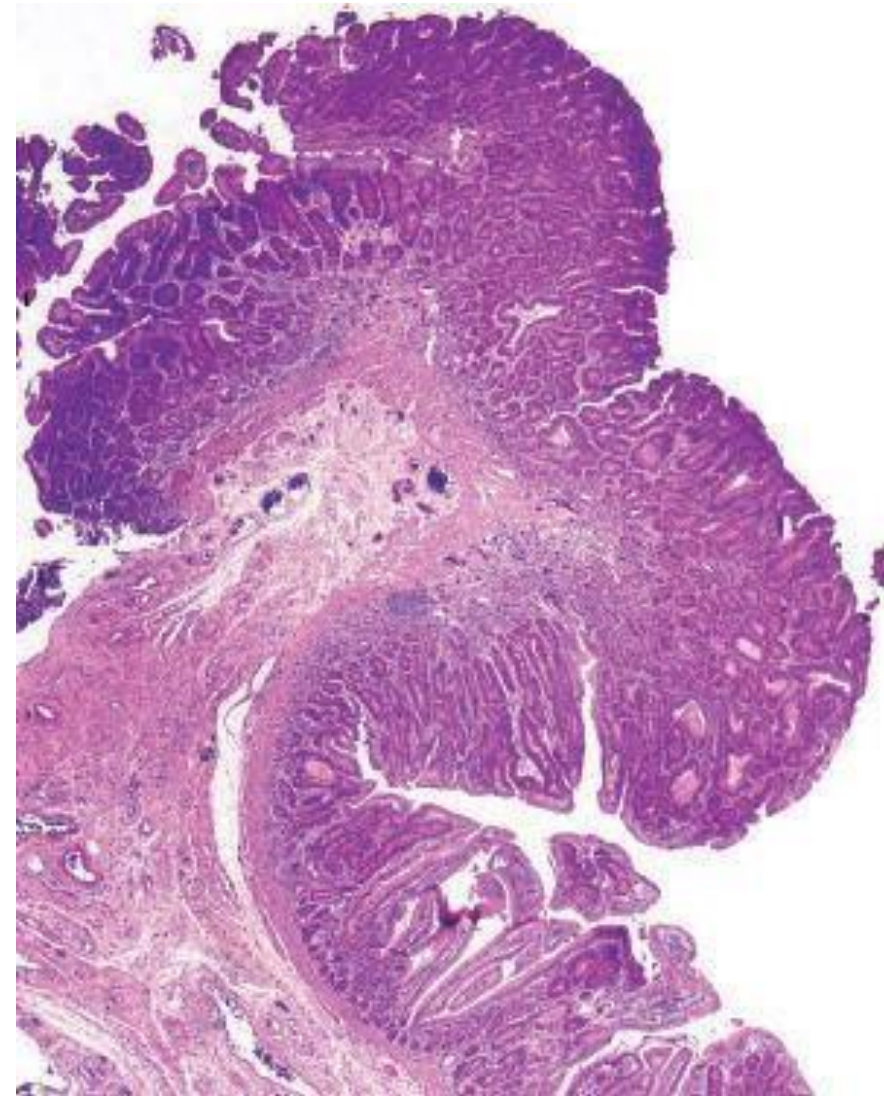
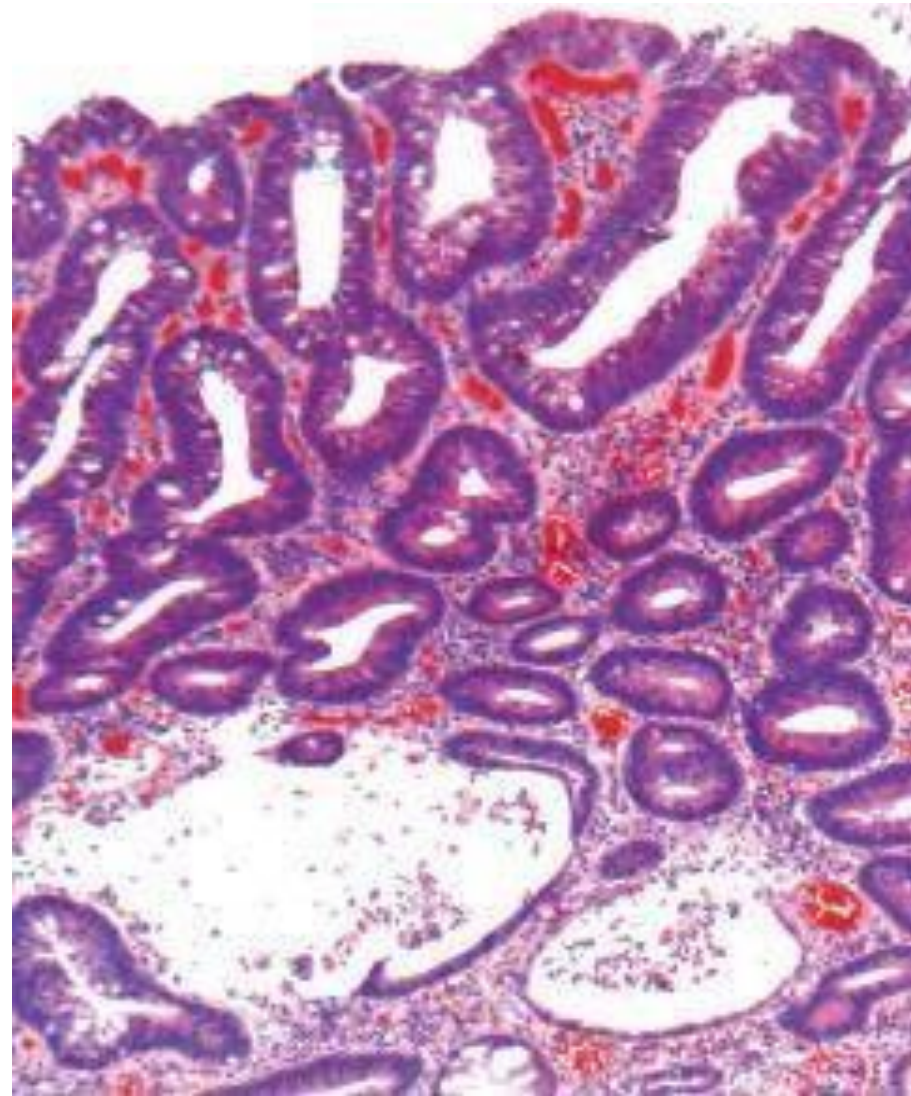
Normal mucosa Dysplastic mucosa



- In the **left side** of the picture we can see the **normal intestinal mucosa**, in which the **nuclei** are **basally** located and **small** in size.
- On the **right side**, the **nuclei** of Crypts and surface are **hyperchromatic** and **stratified**, their color is **deeply blue** seen in H&E stain with **high** nuclear to cytoplasmic ratio (N/C ratio).

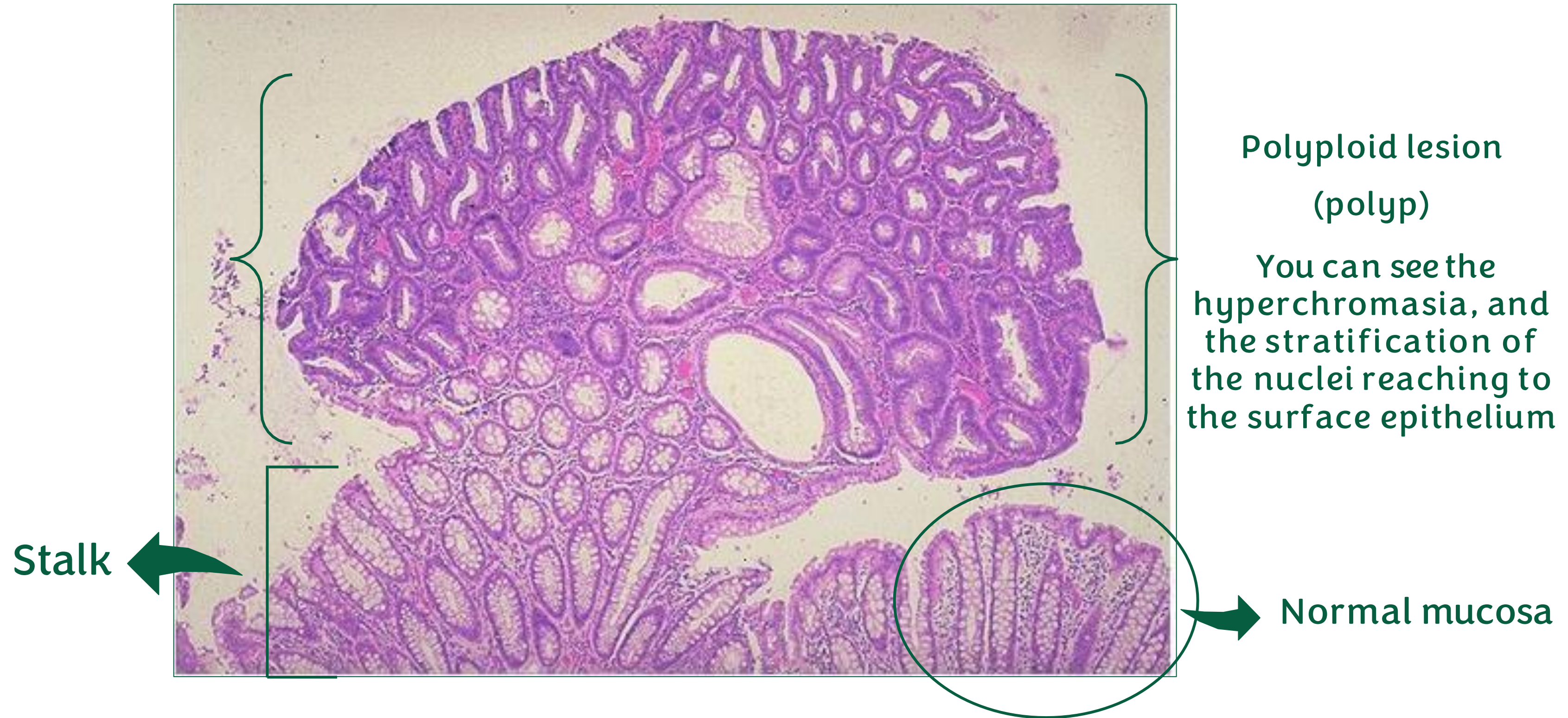Tubular adenoma:

They're named so because of the presence of small tubular glands on the surface

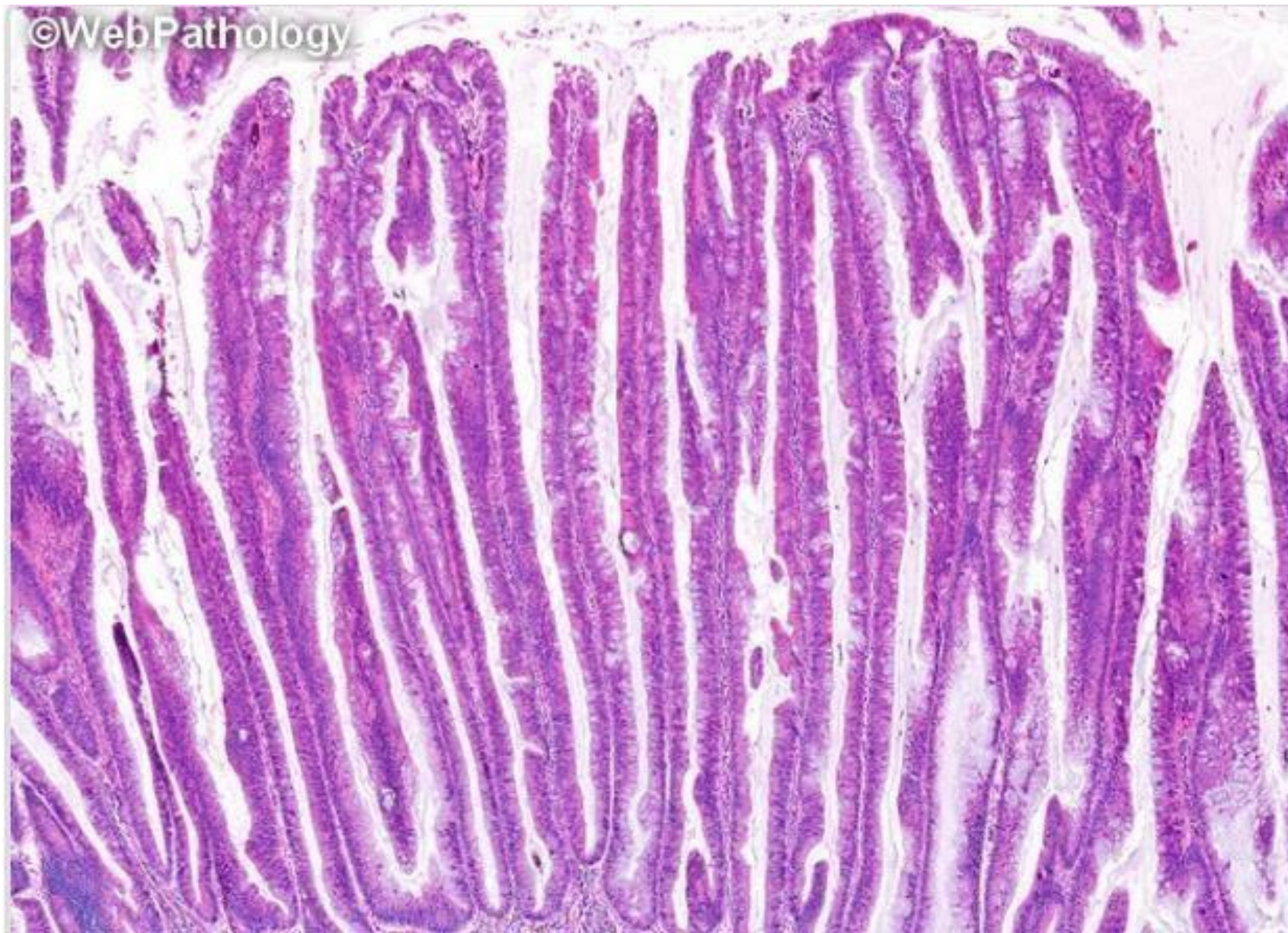

- ▶ Pedunculated
- ▶ small tubular glands

This is a colonic tubular adenoma

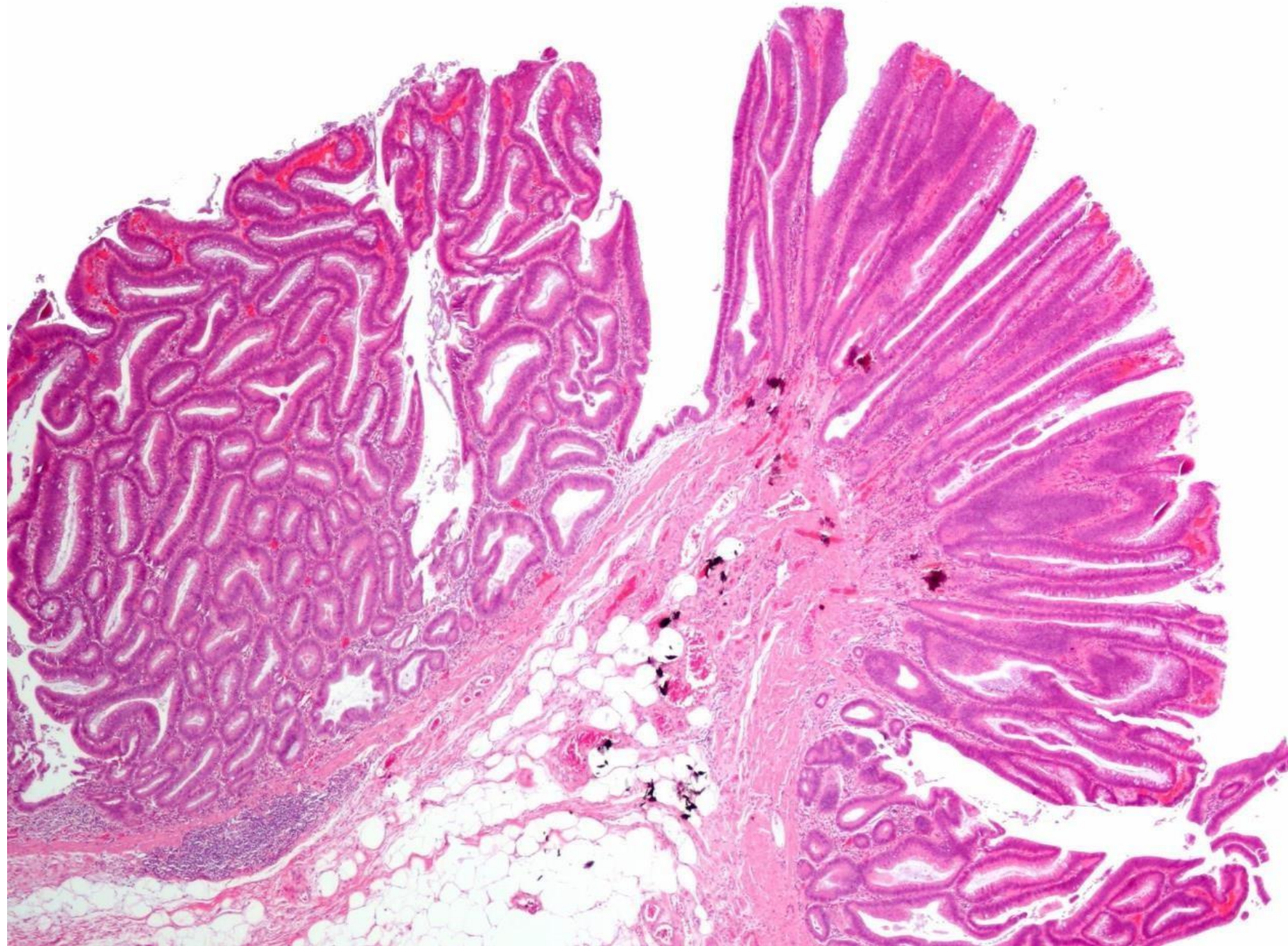


Villous adenoma.



- ▶ Long slender villi (finger like projections, like the villi of the small bowel).
 - ▶ Large and sessile.
 - ▶ More frequent invasive foci
- Note : the risk of invasive carcinoma is not related to the architecture , but to the size of these adenomas.

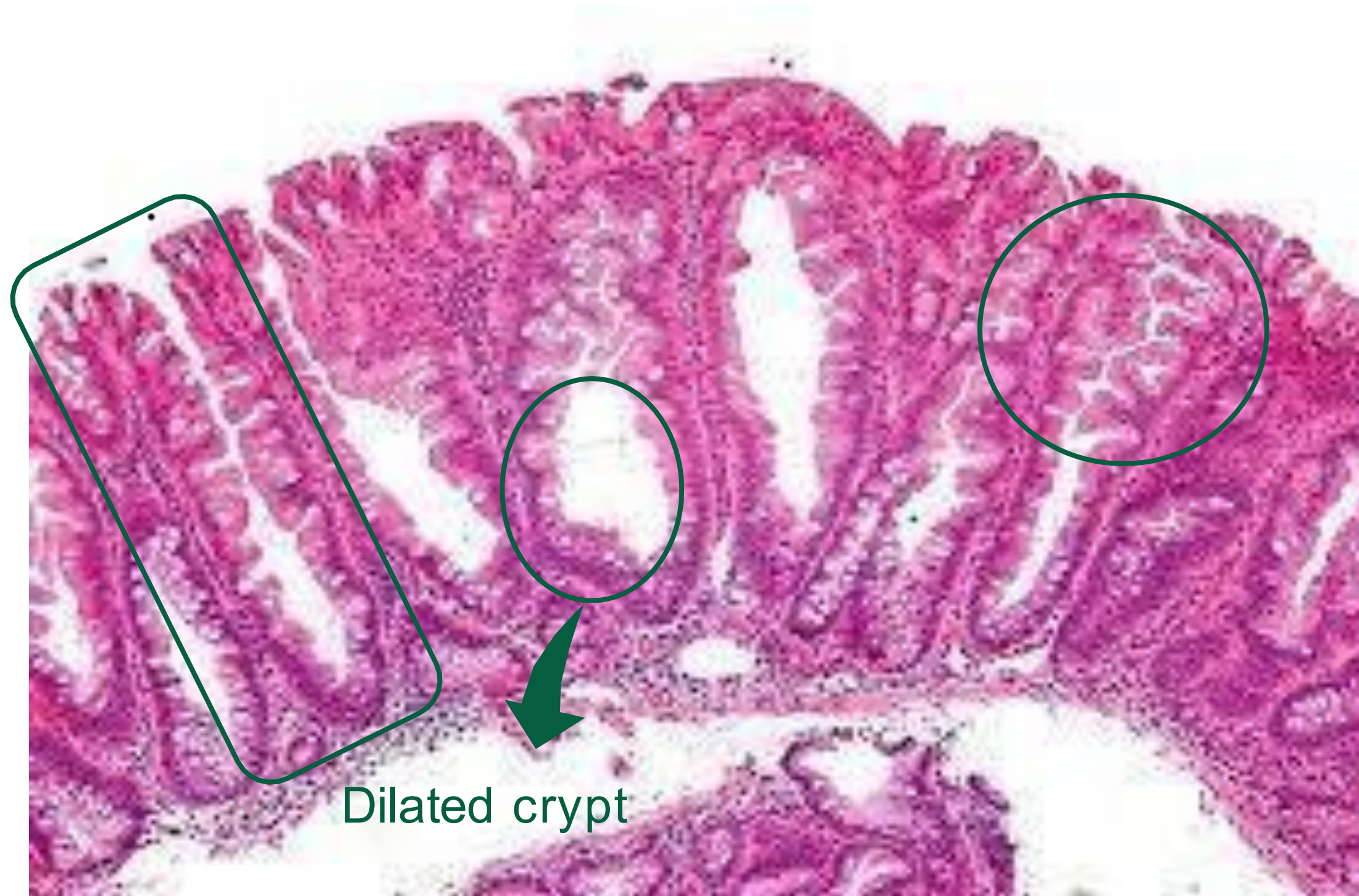
Tubulovillous adenoma



- It harbors both architectural features of tubular component and villous component

Sessile serrated adenoma

- ▶ Overlap with hyperplastic polyps.
- ▶ Lack dysplasia .(unlike other adenomas)
- ▶ Malignant potential similar to conventional adenomas. (although they lack dysplasia).
- ▶ Serrated architecture throughout full length of glands.(not only on the surface like the hyperplastic polyps).
- ▶ Basal crypts dilated.+ sometimes laterally branching



The typical appearance of sessile serrated adenoma . You can notice that the serrations (See TOOTH appearance) reach the full area of the crypts not only the surfaces .

Familial Syndromes

- ▶ Syndromes associated with colonic polyps and increased rates of colon cancer
- ▶ **These syndromes have Genetic basis.**
- **The most important syndromes are :**
 - 1 **Familial Adenomatous Polyposis (FAP)**
 - 2 **Hereditary Nonpolyposis Colorectal Cancer (HNPCC) sometimes called: Lynch syndrome**

Familial adenomatous polyposis FAP

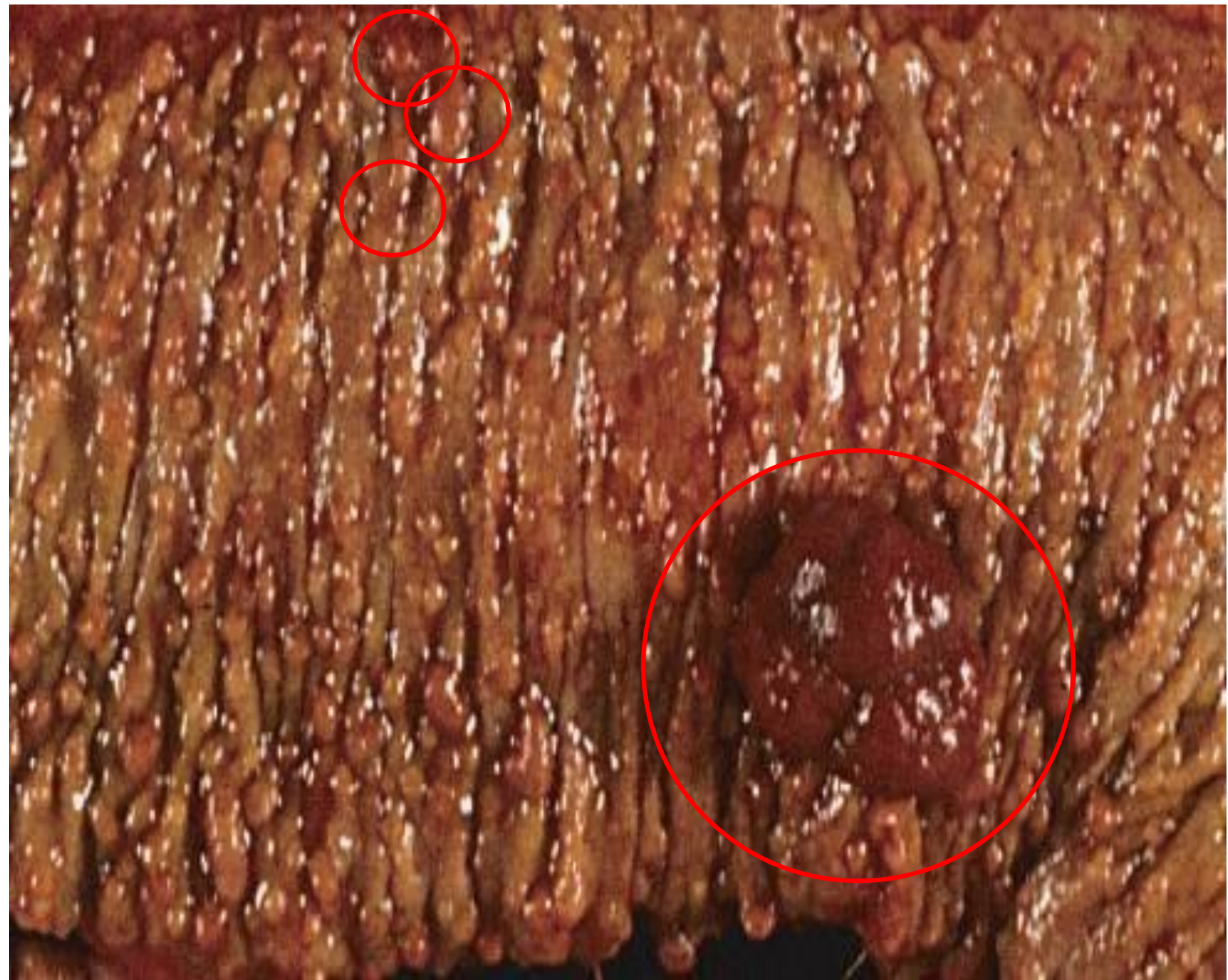
- ▶ Autosomal dominant. (when there's a member of the family affected by FAP we should screen all the family members, because it's inherited)
- ▶ Numerous colorectal adenomas: teenage years.
- ▶ Mutation in APC (adenomatous polyposis coli) gene.
- ▶ At least 100 polyps are necessary for a diagnosis of classic FAP.
- ▶ Morphologically similar to sporadic adenomas (they are adenomas and they both harbor dysplasia whether low grade or high grade).
- ▶ 100% of patients develop colorectal carcinoma, IF UNTREATED, often before age of 30.
- ▶ Standard therapy: prophylactic colectomy.
- ▶ Risk for extraintestinal manifestations, sometimes extra intestinal tumors (in addition to the risk of colorectal carcinoma)

Variants of FAP:

- ▶ **Classified according to Specific APC mutations.**
- ▶ **Gardner syndrome:** intestinal polyps + osteomas (**benign**) (mandible, skull, and long bones); epidermal cysts (**skin related cyst**); desmoid (**fibromatosis**) and thyroid tumors; and dental abnormalities.
- ▶ **Turcot syndrome:** intestinal adenomas and CNS tumors (medulloblastomas >>**1/3 of the cases it could be glioblastomas**)

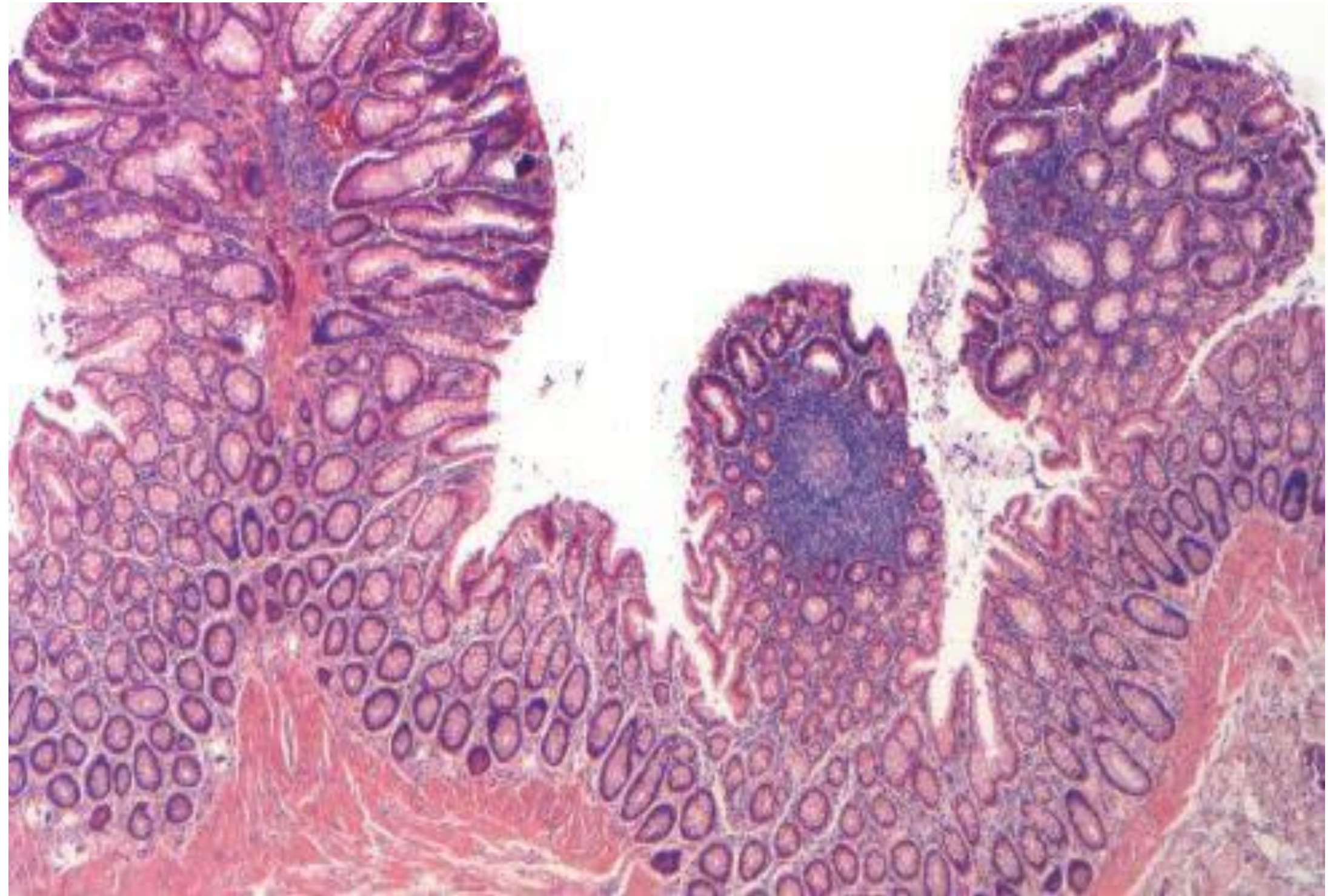
We need at least 100 polyp to diagnose the classic FAP . However, most of the time patients have 1000 or more polyps with variable sizes (Like a carpet of polyps)

Many small polyps



One large polyp

Similar to classical/conventional sporadic adenomas under the microscope, we can see 3 polyps here in the same picture



Hereditary Nonpolyposis Colorectal Cancer: HNPCC, Lynch syndrome

It's called " nonpolyposis" because we don't see as many polyps as we see in FAP. However, there is definitely a polyp precursor lesion for the development of colorectal cancer .

- ▶ Autosomal dominant. Inherited germ-line mutations in DNA mismatch repair genes **which are important in** (detection, resection and repair of errors in DNA replication).
- ▶ Increased risk of: Colorectum, endometrium, stomach, ovary, ureters, brain, small bowel, hepatobiliary tract, and skin cancers.
- ▶ Colon cancer at younger age than sporadic cancers (**before 50 yrs**)
- ▶ Right colon, abundant mucin.
- ▶ Only few adenomatous precursors (typically sessile serrated adenomas).

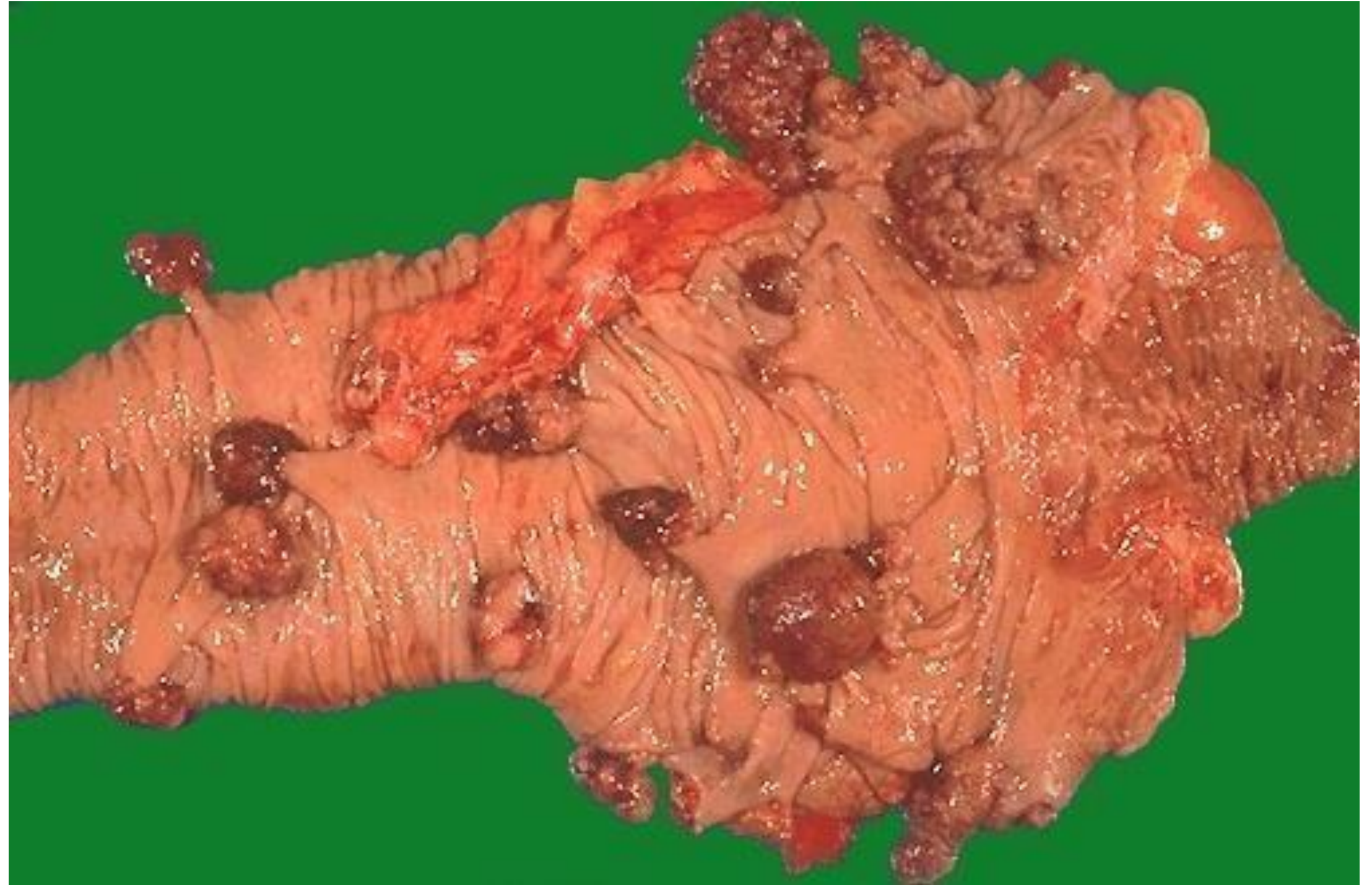
HNPC, cont

- ▶ Accumulation of mutations at 1000x higher rates in microsatellite DNA (short repeating sequences) **where most of the mutations occur**
- ▶ Resulting in microsatellite instability, **which will lead to high incidence of cancers including the colorectal.**
- ▶ 5 genes identified but Majority of cases involve either MSH2 or MLH1.

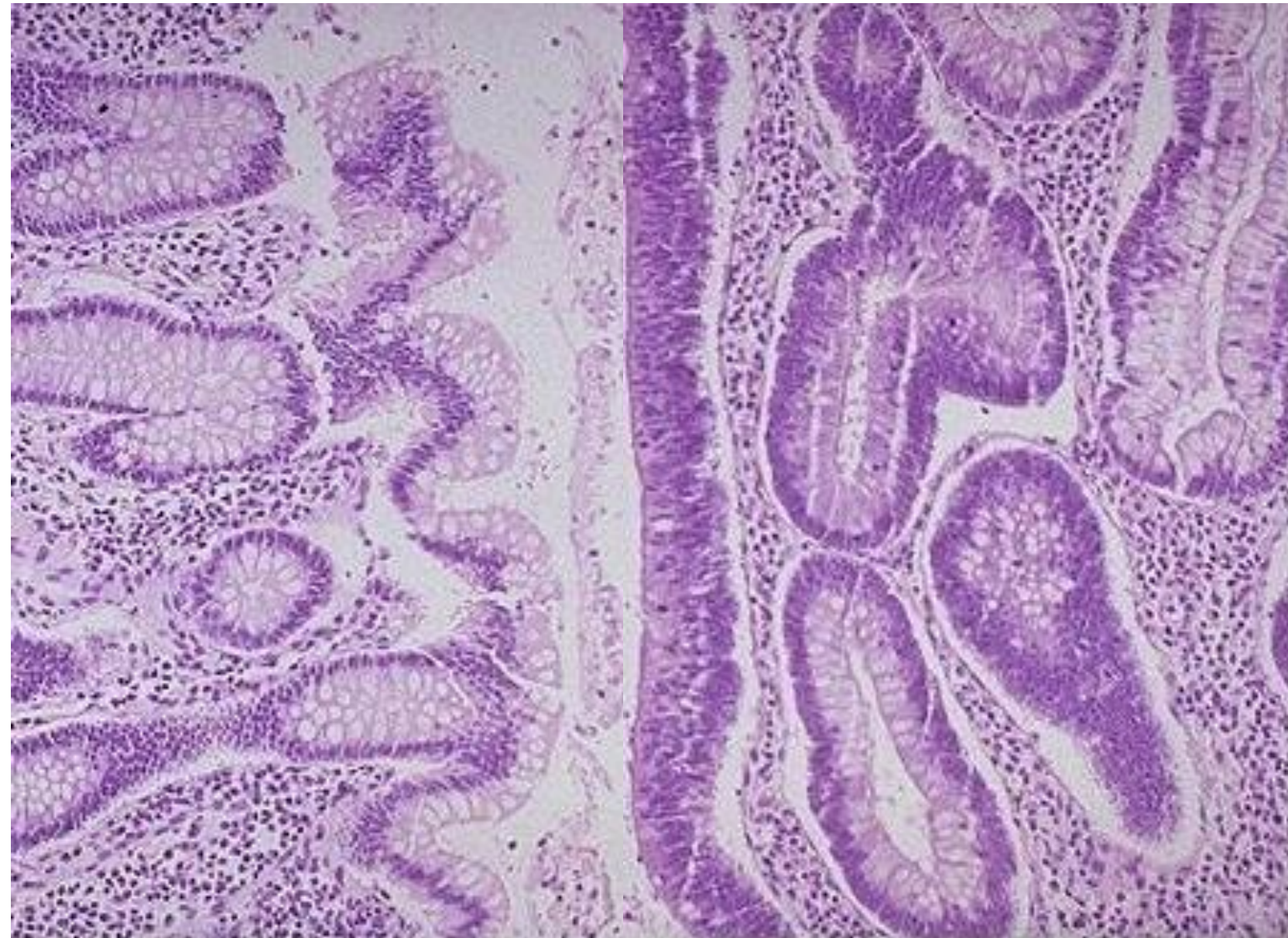
Mutations in the DNA mismatch repair genes >>micro satellite instability

Cecal polyps in HNPCC.

- This is the right side of the colon, the **cecum**, which is known for its broad diameter.
- we can see here many polyps but still less in number than those in FAP (most of these are of the sessile adenoma subtype) & they have high risk of progression colorectal carcinoma which



Click on the normal mucosa for a quiz on this lecture



Additional Resources:

Reference Used:

(numbered in order as cited in the text)

1. First reference
2. Second reference
3. ...

Extra References for the Reader to Use:

1. Video
2. Webpage
3. ...

رسالة من الفريق العلمي:

توصيات

مقولة مرعبة لابن القيم - رحمه الله - يقول فيها
"إذا لم تُخْلِص فلا تَتَعَب!"

اجعلها تذكير لك في عملك وسعيك وأين ما
كُنْتَ، واسأل وألح على الله أن يرزقك الإخلاص
والقبول، وأكثر من دعاء عمر بن الخطاب رضي
الله عنه: "اللهم اجعل عملي كله صالحا،
واجعله لوجهك -خالصا-، ولا تجعل لأحد فيه
شيئا"

For any feedback, scan the code or click on it.



Corrections from previous versions:

Versions	Slide # and Place of Error	Before Correction	After Correction
V0 → V1			
V1 → V2			