

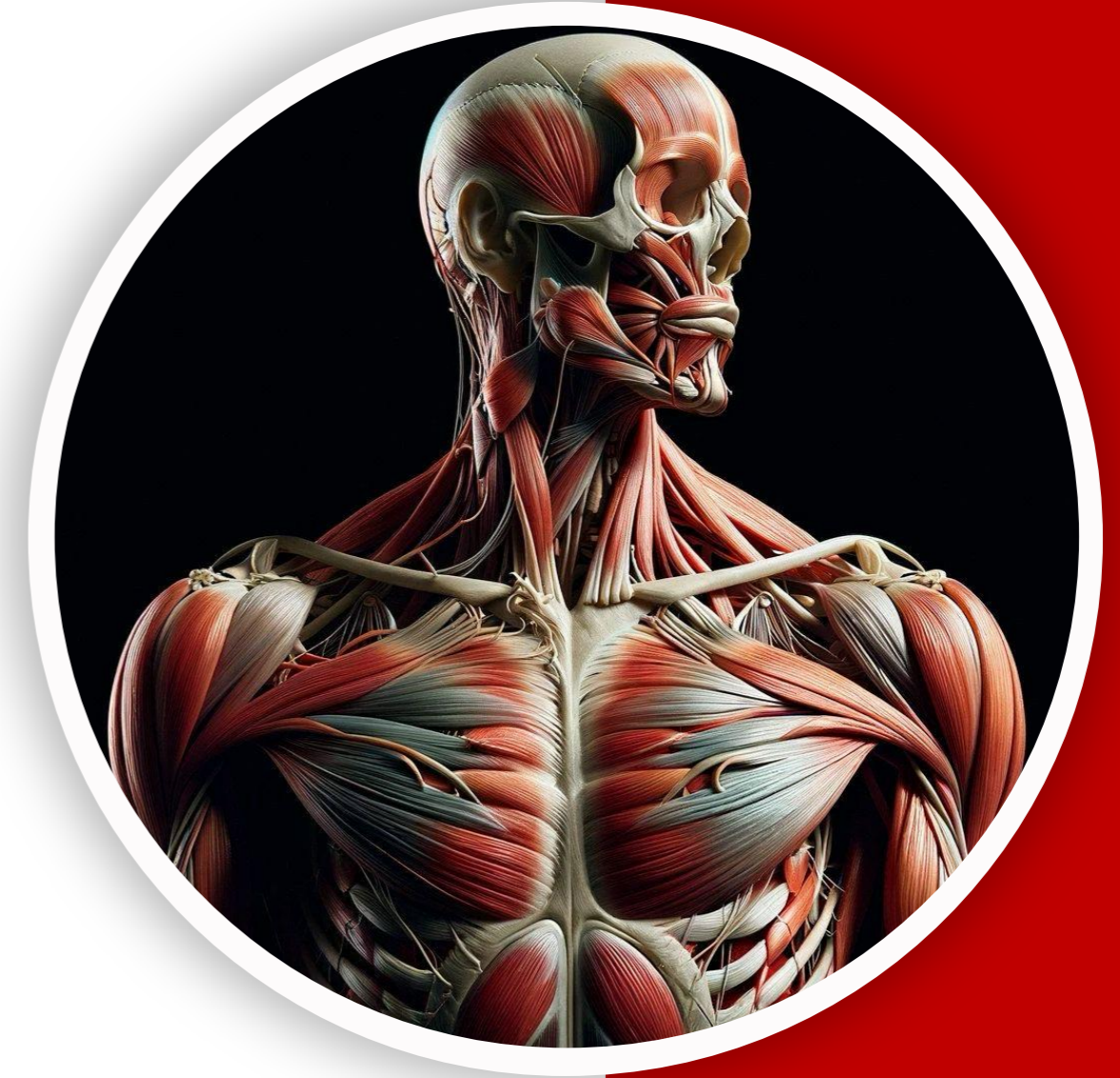بِسْمِ اللّٰهِ الرَّحْمٰنِ الرَّحِیْمِ  
(وَفَوْقَ كُلِّ ذِي عِلْمٍ عَلِيمٌ)



جراحین

MSS Anatomy | FINAL

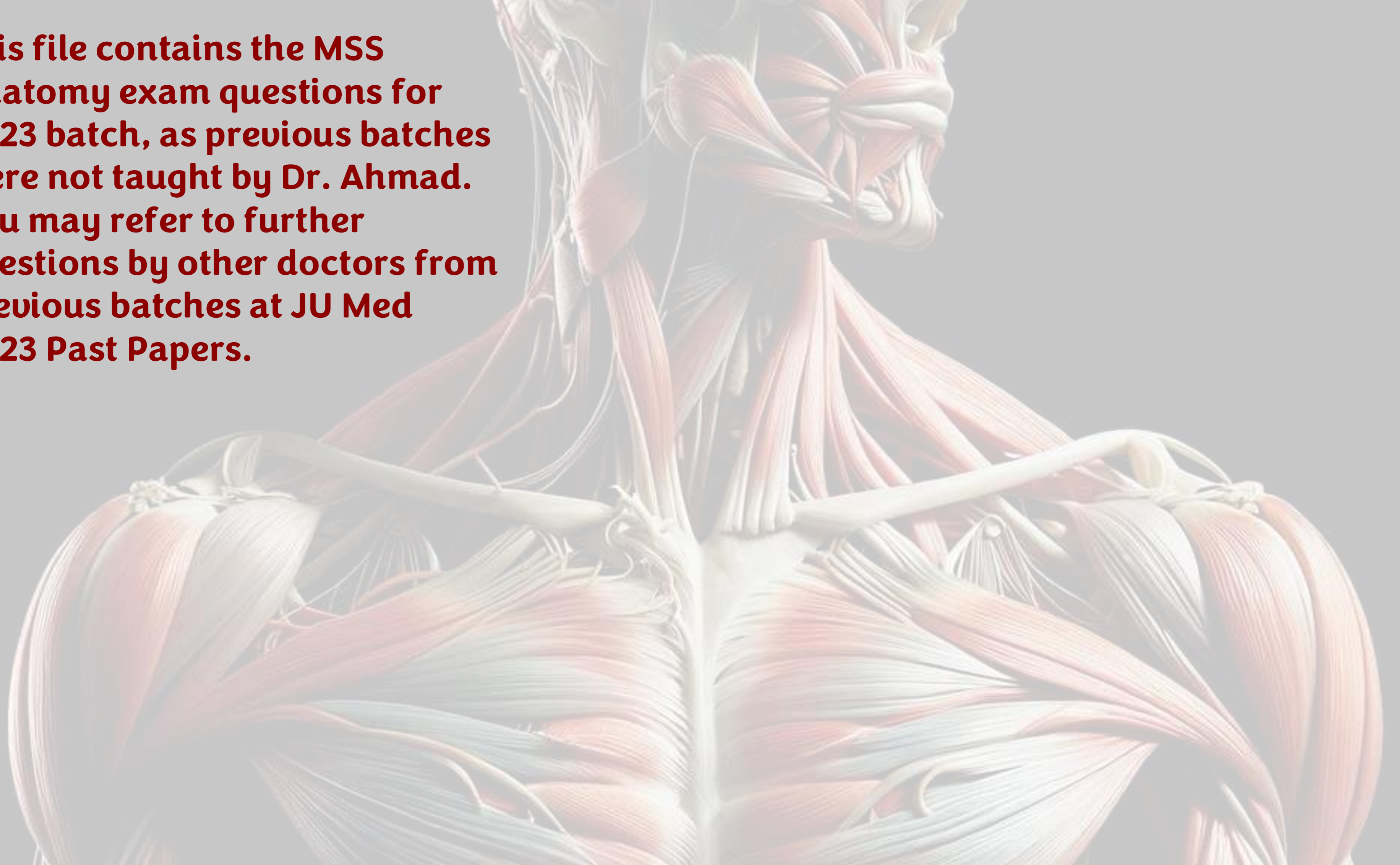
# 2023 Past Papers



Written by : Sarah Albakkar

Reviewed by : Leen Jarah

**This file contains the MSS  
Anatomy exam questions for  
2023 batch, as previous batches  
were not taught by Dr. Ahmad.  
You may refer to further  
questions by other doctors from  
previous batches at JU Med  
2023 Past Papers.**



# Question

**Q1: Which of the following statements about the mandibular nerve is INCORRECT?**

- A. It is the third division of the trigeminal nerve**
- B. It carries both sensory and motor fibers**
- C. Buccal branch supplies the buccinator muscle**
- D. It innervates muscles of mastication**

**Answer: C**

# Question

Q2: Injury to the anterior division of the mandibular nerve will paralyze which muscle?

A. Medial pterygoid

B. Masseter

C. Digastric

D. Mylohyoid

**Answer: B**

# Question

**Q3: Which of the following is a content of the carotid triangle?**

- A. External jugular vein**
- B. Ansa cervicalis**
- C. Subclavian artery**
- D. Thoracic duct**

**Answer: B**

# Question

**Q4: The cavernous sinus drains into the transverse sinus via which sinus?**

- A. Inferior petrosal sinus**
- B. Sigmoid sinus**
- C. Superior petrosal sinus**
- D. Straight sinus**

**Answer: C**

# Question

**Q5: A muscle is shown inserting into the angle of the mouth . Which of the following is the most likely muscle?**

**A. Medial pterygoid**

**B. Buccinator**

**C. Temporalis**

**D. Lateral pterygoid**

**Answer: B**

# Question

**Q6: Which muscle is responsible for depressing the larynx?**

**A. Thyrohyoid**

**B. Sternothyroid**

**C. Omohyoid**

**D. Sternohyoid**

**Answer: B**

# Question

**Q7. Which of the following is a branch of the first part of the subclavian artery?**

- A. Thyrocervical trunk**
- B. Vertebral artery**
- C. Internal thoracic artery**
- D. All of the above**

**Answer: D**

# Question

**Q8. The central retinal artery is a branch of which artery?**

**A. Internal carotid artery**

**B. Ophthalmic artery**

**C. External carotid artery**

**D. Maxillary artery**

**Answer: B**

# Question

Q9. A person had a head injury and developed periorbital ecchymosis the next day . Which layer allows the gravitation of blood to the eye ?

- A. Skin
- B. Dense connective tissue
- C. Aponeurosis
- D. Loose areolar tissue

**Answer: D**

# Question

Q10. Which artery is related to the pterion?

- A. Superficial temporal artery
- B. Maxillary artery
- C. Anterior branch of middle meningeal artery
- D. Occipital artery

**Answer: C**

# Question

**Q11. Which type of hemorrhage is characterized by a lucid interval?**

- A. Subdural hemorrhage**
- B. Subarachnoid hemorrhage**
- C. Epidural hemorrhage**
- D. Intracerebral hemorrhage**

**Answer: C**

# Question

**Q12. A tumor at the angle of the mouth will most likely spread to which lymph nodes?**

- A. Submental lymph nodes**
- B. Submandibular lymph nodes**
- C. Deep cervical lymph nodes**
- D. Parotid lymph nodes**

**Answer: B**

# Question

**Q13. Which structure prevents posterior dislocation of the TMJ?**

- A. Sphenomandibular ligament**
- B. Stylomandibular ligament**
- C. Lateral temporomandibular ligament**
- D. Articular disc**

**Answer: C**

# Question

**Q14. The oval window is related to which structure?**

**A. Malleus**

**B. Incus**

**C. Stapes**

**D. Tympanic membrane**

**Answer: C**

# Question

Q15. A patient can not open his left eye ,has loss of forehead wrinkles, and drooping of the mouth on the same side. What is the lesion :

- A. Upper motor neuron lesion (right side)
- B. Lower motor neuron lesion of left facial nerve
- C. Trigeminal nerve lesion
- D. Oculomotor nerve lesion

**Answer: B**

# Question

Q16. The sensation of cold when eating ice cream is transmitted mainly by which nerve?

- A. Inferior alveolar nerve
- B. Lingual nerve
- C. Buccal nerve
- D. Glossopharyngeal nerve

**Answer: B**

# Question

**Q17. Which muscle elevates, abducts, and externally rotates the eyeball?**

- A. Superior rectus**
- B. Inferior rectus**
- C. Superior oblique**
- D. Inferior oblique**

**Answer: D**

# Question

Q18. Which of the following statements is INCORRECT?

- A. In hypoglossal nerve palsy, the tongue deviates to the normal side
- B. Recurrent laryngeal nerve is a branch of the vagus nerve
- C. Glossopharyngeal nerve provides sensory innervation to the pharynx
- D. Spinal accessory nerve supplies sternocleidomastoid muscle
- E. Sympathetic fibers from inferior ganglion travel with cervical nerves

**Answer: A**

# Question

**Q19. The vein formed by the union of the anterior facial vein and anterior division of retromandibular vein drains into?**

- A. External jugular vein**
- B. Internal jugular vein**
- C. Subclavian vein**
- D. Brachiocephalic vein**

**Answer: B**

# Question

**Q20. Which muscle acts as an antagonist to occipitofrontalis?**

- A. Zygomaticus major**
- B. Orbicularis oculi**
- C. Buccinator**
- D. Platysma**

**Answer: B**

# Question

**Q21. Which nerve passes anterior to the anterior scalene muscle?**

- A. Brachial plexus**
- B. Subclavian artery**
- C. Phrenic nerve**
- D. Vagus nerve**

**Answer: C**

# Question

Q22. The thyroid gland moves during deglutition because it is attached to the larynx by :

- A. Investing fascia
- B. Pretracheal fascia
- C. Carotid sheath
- D. Prevertebral fascia

**Answer: B**

# Question

**Q23. Which nerve supplies the skin and conjunctiva of the lateral part of the upper eyelid?**

- **A. Supraorbital nerve**
- **B. Infratrochlear nerve**
- **C. Lacrimal nerve**
- **D. Zygomatic nerve**

**Answer: C**

# Question

**Q24. What forms the lateral wall of the infratemporal fossa?**

- A. Lateral pterygoid plate**
- B. Ramus of mandible and masseter muscle**
- C. Maxilla**
- D. Temporal bone**

**Answer: B**

# Question

**Q25. Which of the following is a branch of the facial artery?**

- **A. Maxillary artery**
- **B. Superior labial artery**
- **C. Lingual artery**
- **D. Ascending pharyngeal artery**

**Answer: B**

# Question

**Q26. Which nerve carries secretomotor fibers to the parotid gland?**

- **A. Greater petrosal nerve**
- **B. Lesser petrosal nerve**
- **C. Chorda tympani**
- **D. Auriculotemporal nerve**

**Answer: D**

# Question

**Q27. Which nerve is responsible for sensing that food is very cold (general sensation from anterior 2/3 of tongue)?**

**A. Glossopharyngeal nerve**

**B. Facial nerve**

**C. Lingual nerve**

**D. Hypoglossal nerve**

**Answer: C**

# Question

Q28. A patient has ptosis, dilated pupil, and 'down and out' eye indicate paralysis of which nerve?

- A. Trochlear nerve
- B. Abducens nerve
- C. Oculomotor nerve
- D. Optic nerve

**Answer: C**

# Question

**Q29. Which muscle opens the mouth?**

**A. Masseter**

**B. Temporalis**

**C. Medial pterygoid**

**D. Lateral pterygoid**

**Answer: D**

# Question

**Q30. The anterior end of the falx cerebri is attached to :**

- A. Tentorium cerebelli**
- B. Crista galli**
- C. Clivus**
- D. Foramen magnum**

**Answer: B**

# رسالة من الفريق العلمي:

قال الله تعالى (رَبِّ قَدْ آتَيْتَنِي مِنَ الْمُلْكِ وَعَلَّمْتَنِي مِنْ تَأْوِيلِ الْأَحَادِيثِ فَاطِرَ السَّمَاوَاتِ وَالْأَرْضِ أَنْتَ وَليٌّ فِي الدُّنْيَا وَالْآخِرَةِ تَوَفَّنِي مُسْلِمًا وَأَلْحَقْنِي بِالصَّالِحِينَ) (سورة يوسف آية 101).

في زحمة النعم، ينسى الإنسان أحياناً أن كل ما بيده كان يوماً دعاء، وأن كل ما يملكه قد يزول في لحظة، إلا ما كان بينه وبين الله. هناك لحظة صفاء يدرك فيها القلب أن العزّ الحقيقي ليس في الملك، ولا في العلم، بل في أن يبقى الله قريباً منك، حاضرًا في الروح، ولياً لا يغيب. حينها تتلاشى رغبات الدنيا أمام رغبة واحدة صادقة: أن يُقبض القلب وهو ثابت، مطمئن، مُسلم لما أحبه الله، وأن يجد نفسه في النهاية بين وجوه أحبها لطاعتها، لا لدنياها. كأن الحياة كلّها تختصر في هذا الرجاء الهادئ، أن تكون الخاتمة أجمل من كل البدايات.

For any feedback, scan the code or click on it.



Corrections from previous versions:

Versions	Slide # and Place of Error	Before Correction	After Correction
V0 → V1	Slide 28; Q26	<b>Ans : B</b>	<b>Ans : D</b>
V1 → V2			