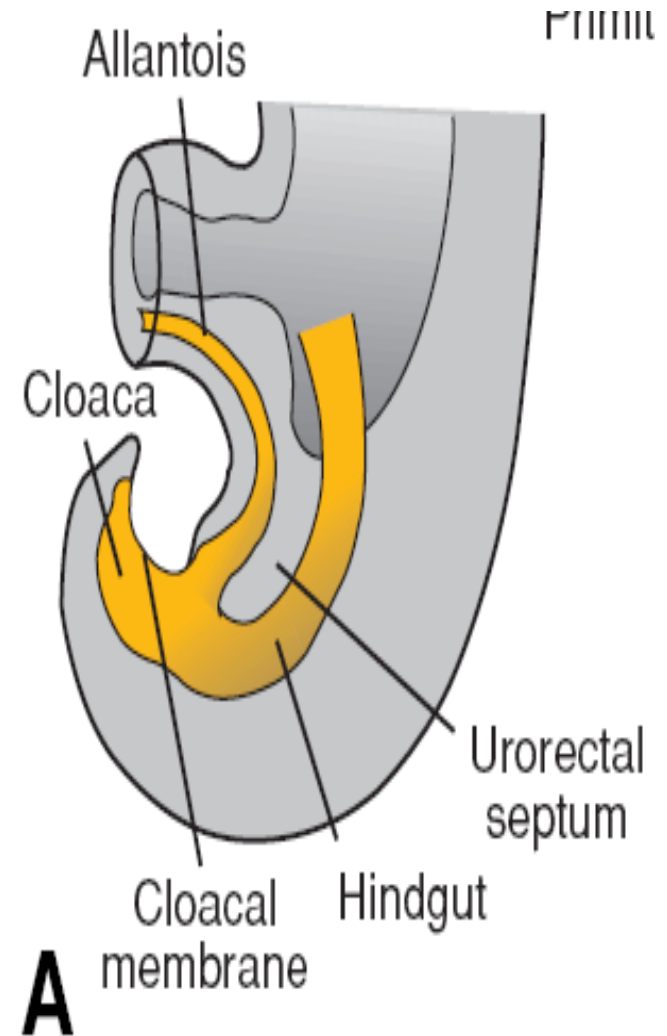


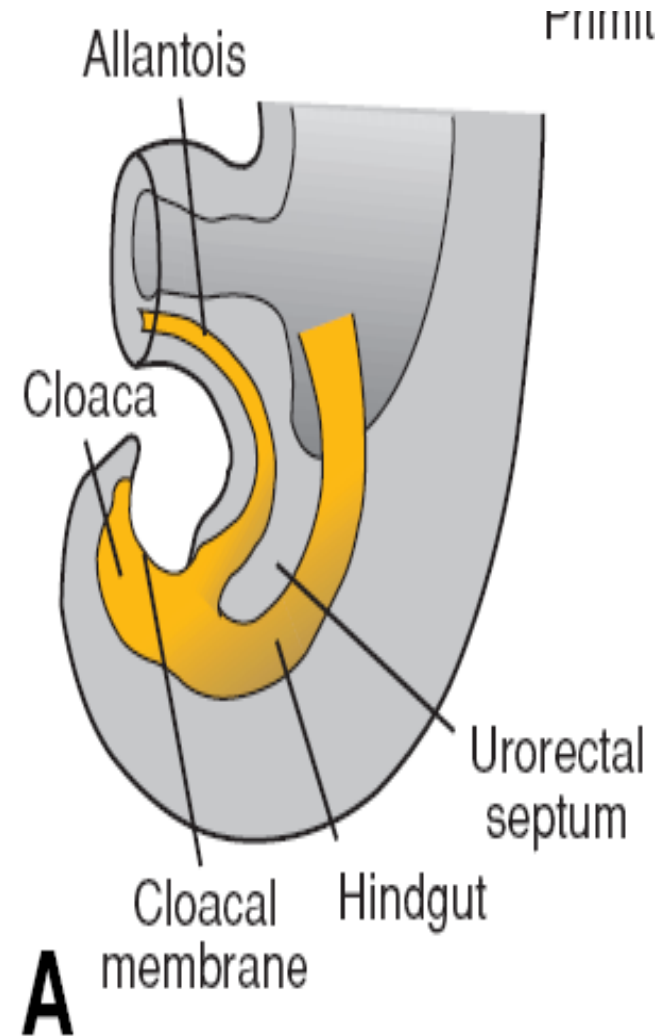
Gi Embryology 3

Hindgut

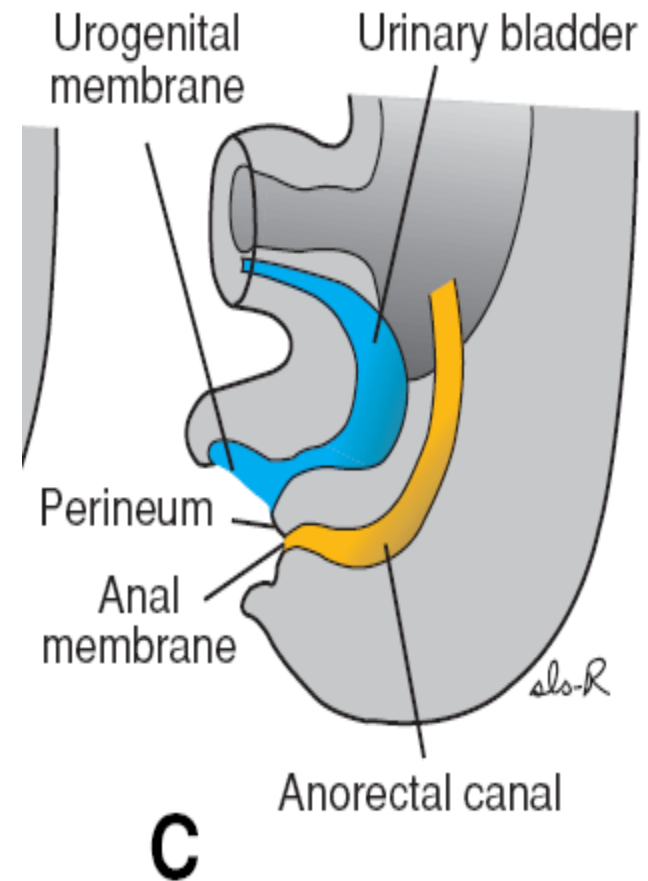
- The hindgut gives rise to the distal third of the transverse colon, the descending colon, the sigmoid, the rectum, and the upper part of the anal canal.
- The endoderm of the hindgut also forms the internal lining of the bladder and urethra
- The terminal portion of the hindgut enters into the posterior region of the cloaca, the primitive **anorectal canal**; the **allantois enters into the anterior** portion, the primitive **urogenital sinus**



- The cloaca itself is an endoderm-lined cavity covered at its ventral boundary by surface ectoderm.
- This boundary between the endoderm and the ectoderm forms the **cloacal membrane**
- A layer of mesoderm, the **urorectal septum, separates** the region between the allantois and hindgut.
- This septum is derived from the merging of mesoderm covering the yolk sac and surrounding the allantois



- At the end of the seventh week, the cloacal membrane ruptures, creating the anal opening for the hindgut and a ventral opening for the urogenital sinus.
- Between the two, the tip of the urorectal septum forms the perineal body
- proliferation of ectoderm closes the caudalmost region of the anal canal.
- During the ninth week, this region recanalizes
- Thus, the caudal part of the anal canal originates in the ectoderm, and it is supplied by the **inferior rectal arteries**, branches of the **internal pudendal arteries**

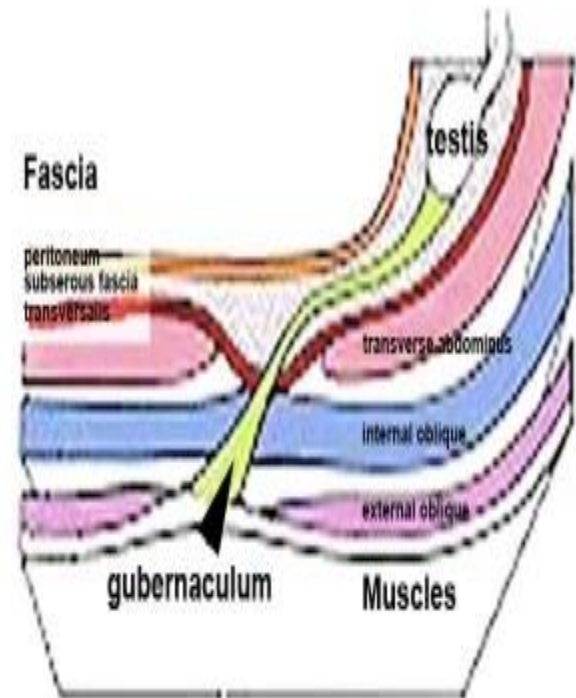


The junction between the endodermal and ectodermal regions of the anal canal is delineated by the **pectinate line, just below the anal columns**

- At this line, the epithelium changes from columnar to stratified squamous epithelium.

Testis

- Toward the end of the second month, the **urogenital mesentery attaches the testis** and mesonephros to the posterior abdominal wall
- Prior to descent of the testis, this band of mesenchyme terminates in the inguinal region between the differentiating internal and external abdominal oblique muscles.
- Later, as the testis begins to descend toward the inguinal ring, an extra-abdominal portion of the gubernaculum forms and grows from the inguinal region toward the scrotal swellings.
- When the testis passes through the inguinal canal, this extra-abdominal portion contacts the scrotal floor



- Normally, the testes reach the inguinal region by approximately 12 weeks gestation, migrate through the inguinal canal by 28 weeks, and reach the scrotum by 33 weeks
- The process is influenced by hormones, including androgens and MIS
- Independently from descent of the testis, the peritoneum of the abdominal cavity forms an evagination on each side of the midline into the ventral abdominal wall.
- This evagination, the **processus vaginalis**, follows the course of the gubernaculum testis into the scrotal swellings
- Hence the processus vaginalis, accompanied by the muscular and fascial layers of the body wall, evaginates into the scrotal swelling, forming the **inguinal canal**

