

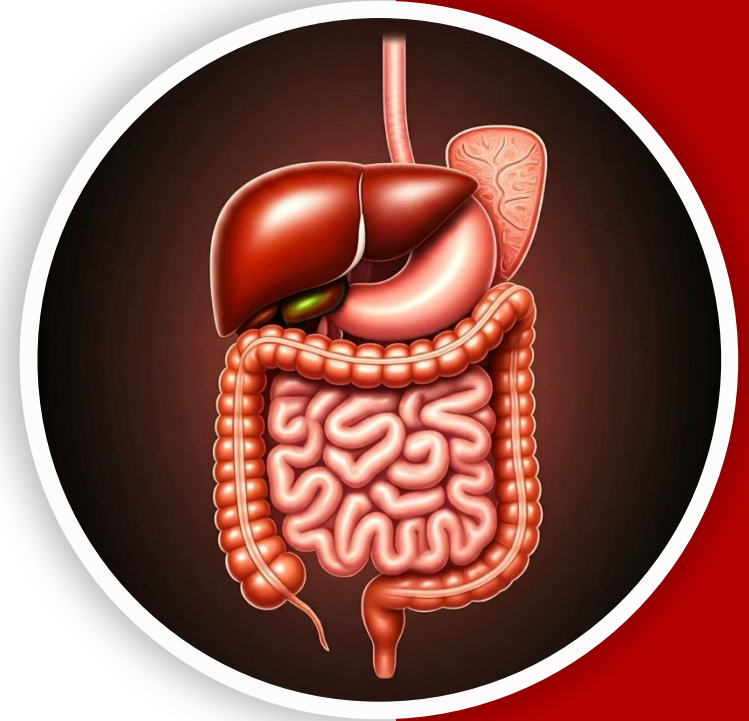
بِسْمِ اللّٰهِ الرَّحْمٰنِ الرَّحِیْمِ
(وَفَوْقَ كُلِّ ذِي عِلْمٍ عَلِيمٌ)



جراح

GIS Anatomy | MID 6

Large Intestines



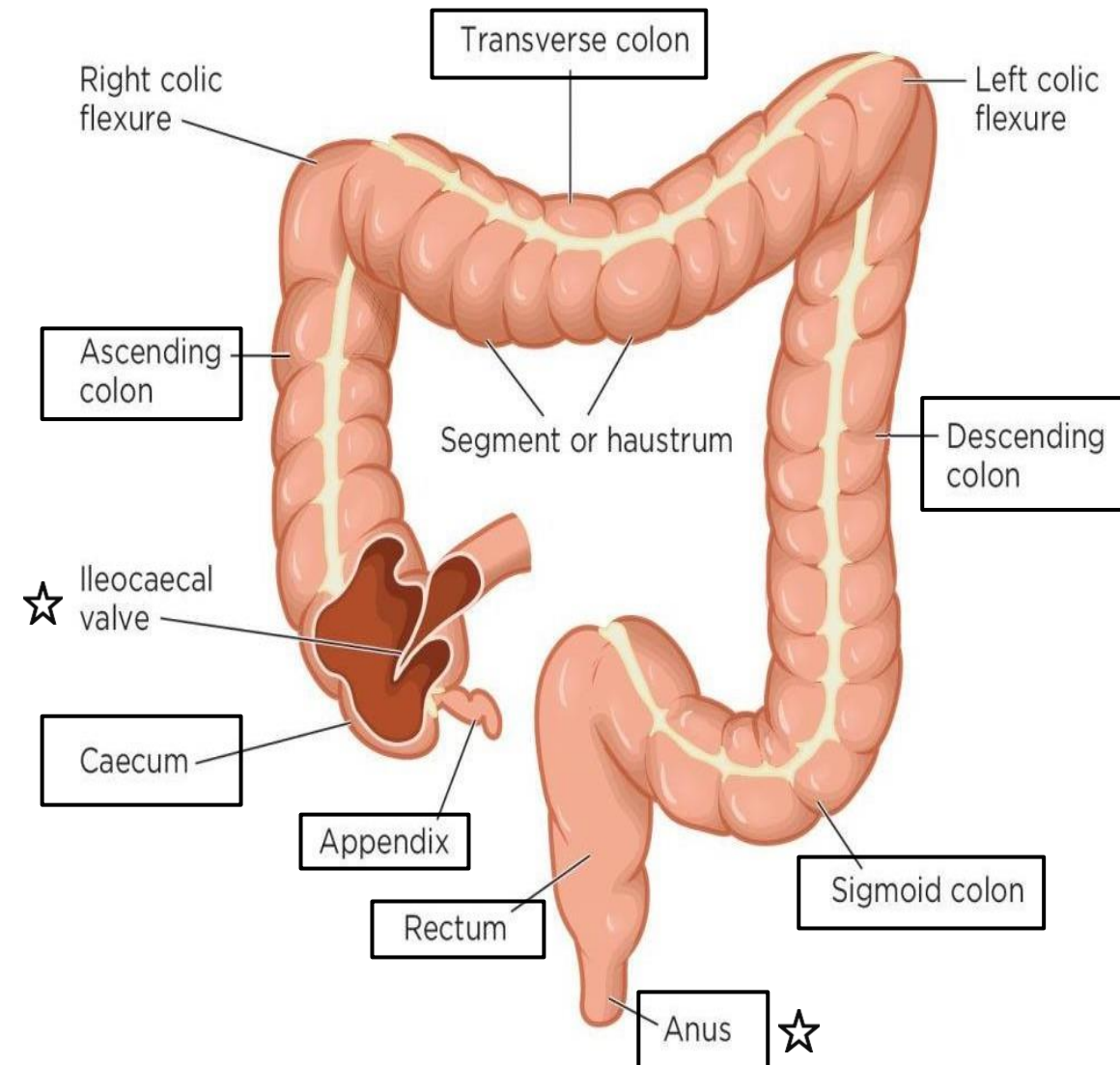
Written by : Sara Al -Khateeb

Reviewed by : NST Members

1- Large Intestine Parts

- ✓ The large intestine extends from the ileocecal valve to the anus, with a total length of approximately 1.5 to 2.5 meters (about 5 feet).

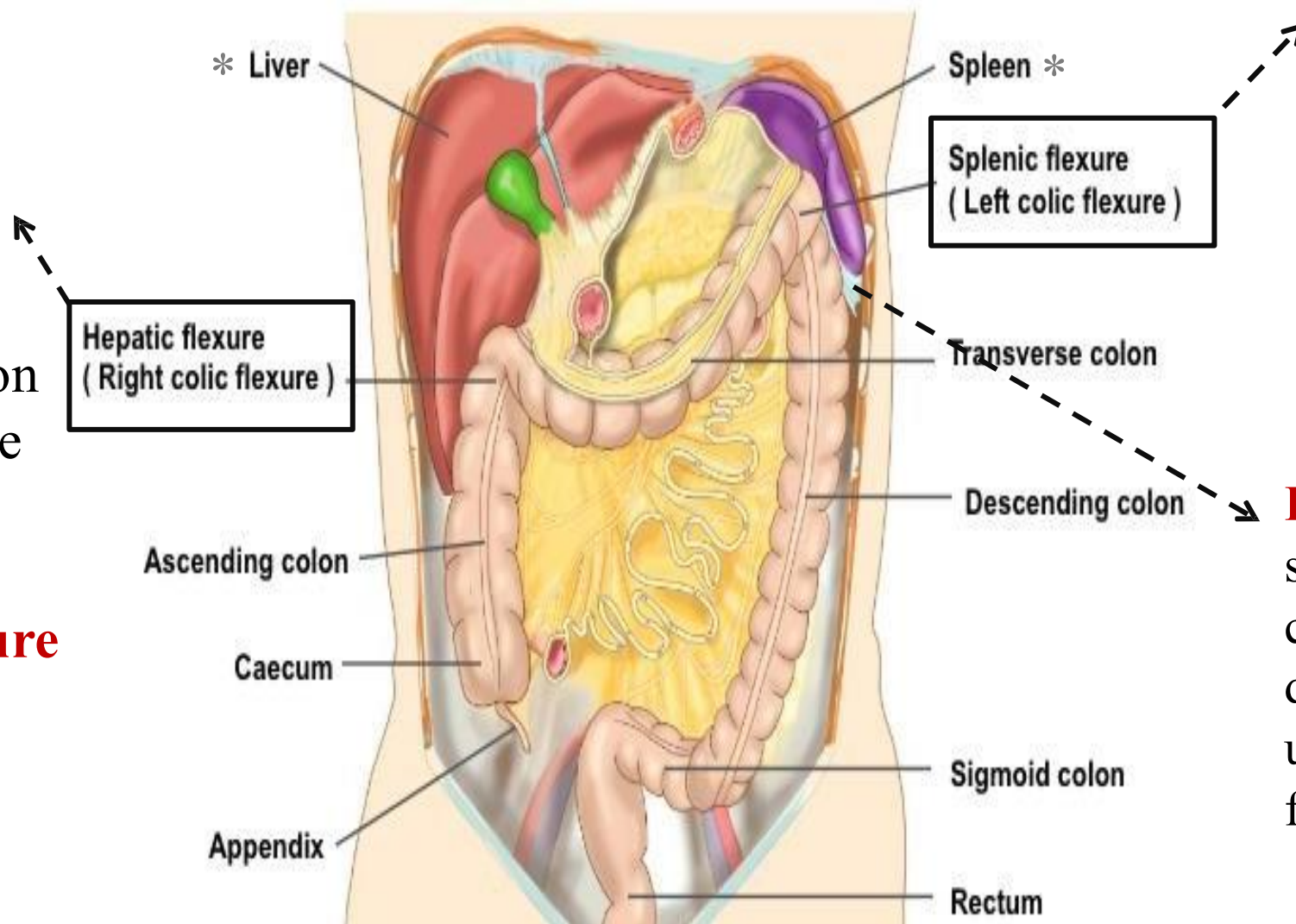
| Part | Length |
|-------------------------|-----------------------|
| Appendix | 3 – 5 inches |
| Cecum | 2.5 – 3 inches |
| Ascending colon | 5 inches |
| Transverse colon | 15 inches |
| Descending colon | 10 inches |
| Sigmoid colon | 10 – 15 inches |
| Rectum | 5 inches |
| Anal canal | 4 cm |



Numbers are required!

2- Colonic Flexures

The junction between the transverse and ascending colon is known as the **right colic flexure**, or ***hepatic flexure** (Since it is located near the liver).



The junction between the transverse and descending colon is referred to as the **left colic flexure**, or ***splenic flexure** (situated near the spleen).

Phrenicocolic ligament stretches from the left colic flexure to the diaphragm, separating the upper abdominal cavity from the lower one.

✓ The **splenic flexure** is typically positioned **higher** than the **hepatic flexure**.

3- Unique Features of the Large Intestine

- ✓ The large intestine has a **wider diameter** than the small intestine, thus the name, even though it is shorter in length. It measures about **1.5 to 2 meters**, whereas the small intestine is much longer, approximately 6 meters in length.
- ✓ The large intestine is characterized by the presence of **three features**:

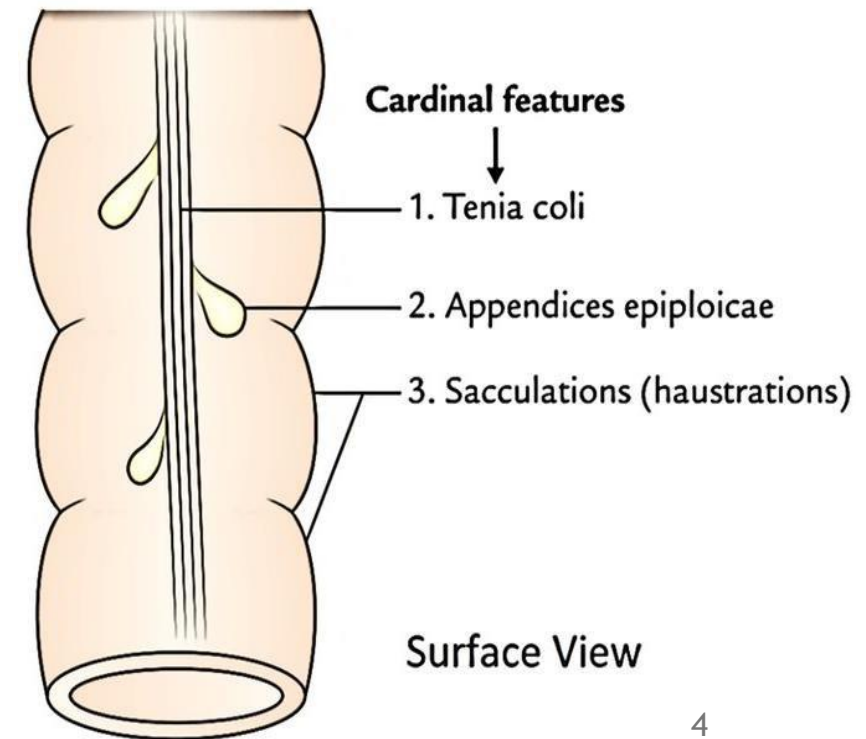
1. Sacculations (Haustra or Haustrations)

2. Taeniae Coli

- **Absent in the appendix and rectum**
- These are three distinct longitudinal bands of smooth muscle. They converge at the **base of the appendix**, making them a reliable 😊 **surgical landmark**. When the appendix is not easily visible, surgeons trace the taeniae coli to locate its base.

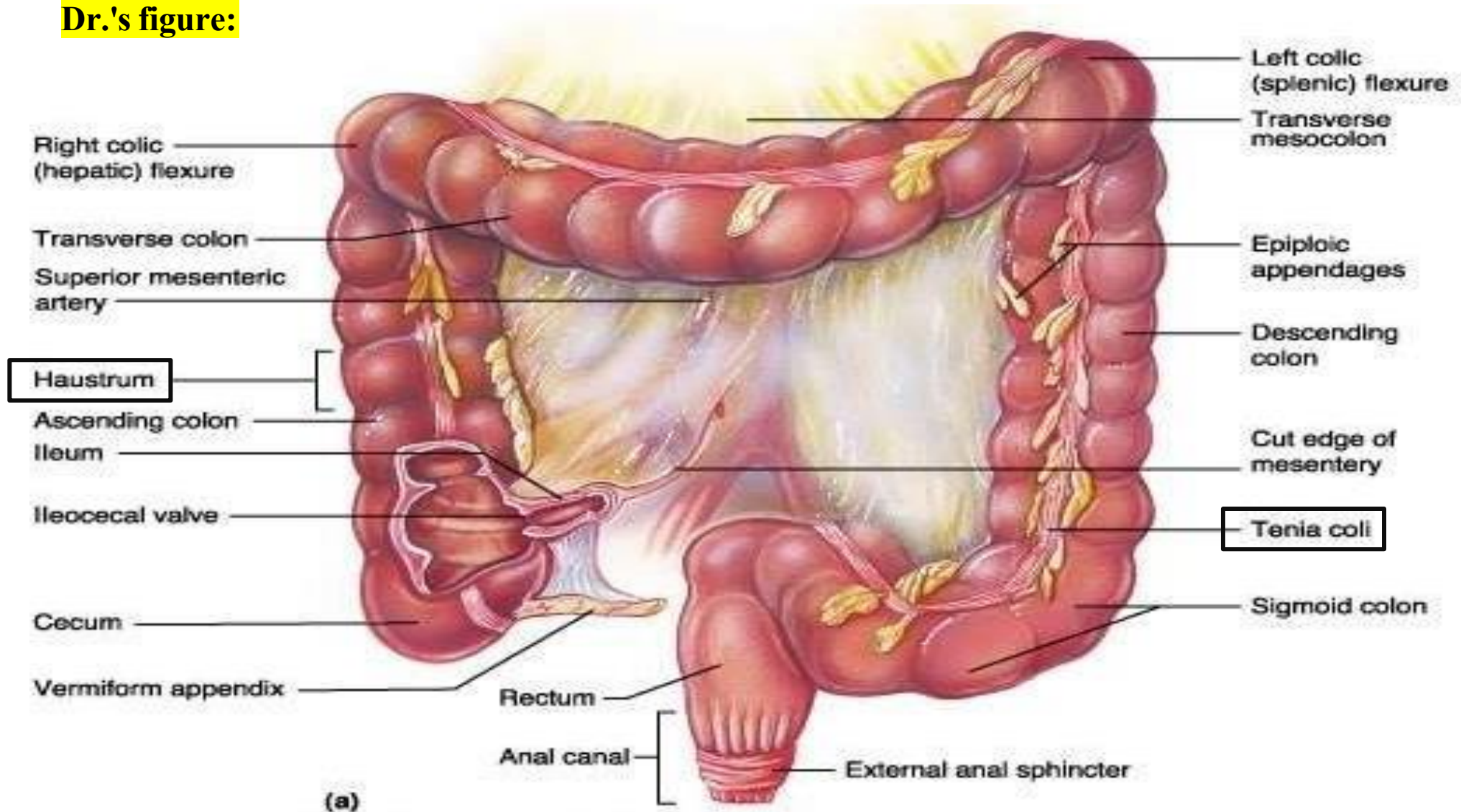
3. Epiploic Appendages (Appendices Epiploicae)

- **Absent in the appendix, cecum, and rectum**



Anatomy of the Large Intestine

Dr.'s figure:



4- Large Intestine HISTOLOGY!

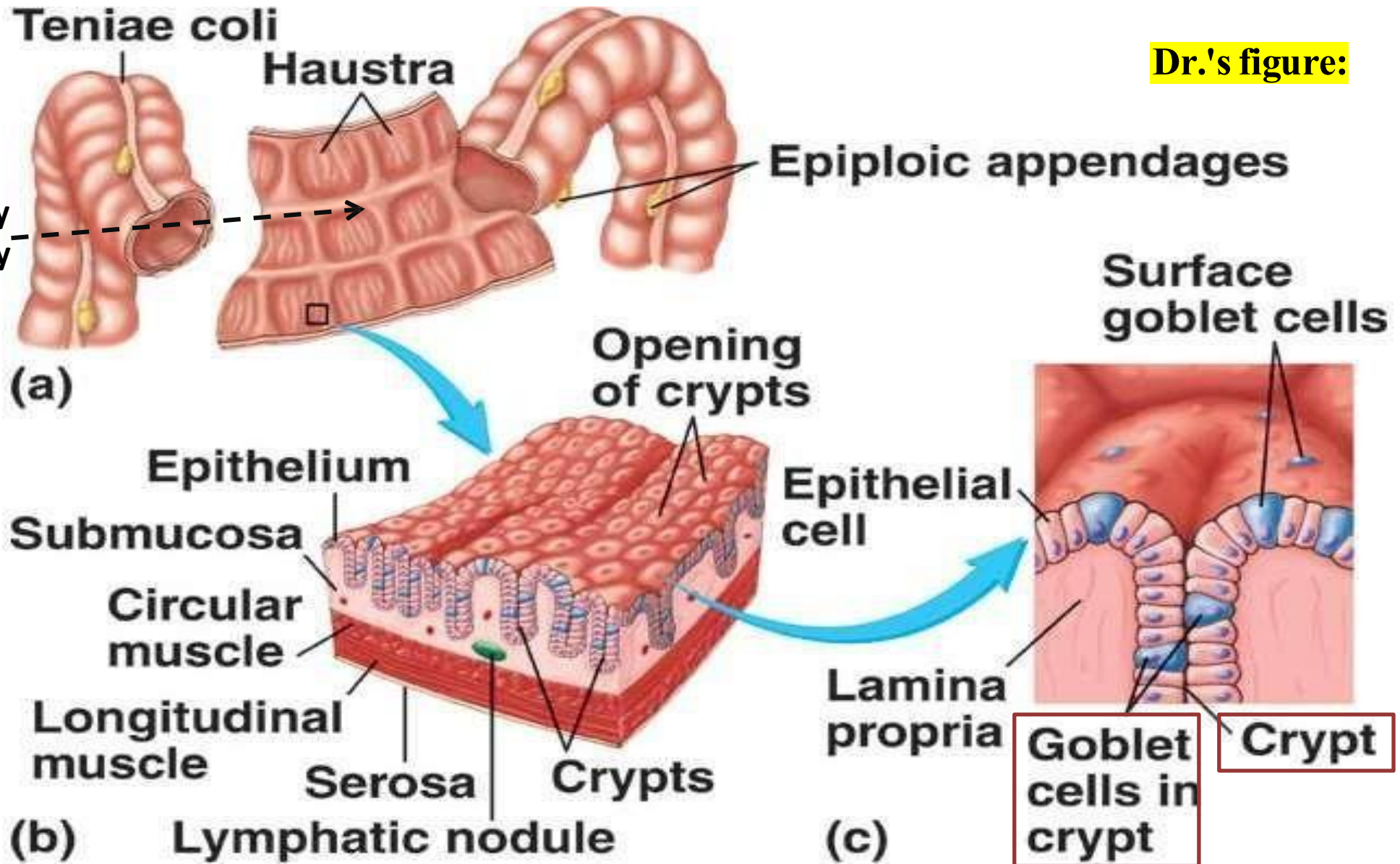
➤ Relate to Histology

- ✓ The epithelial lining of the large intestine is **simple columnar epithelium with numerous goblet cells**, significantly more than the small intestine.
- ✓ The abundance of goblet cells reflects the colon's function in **water absorption and feces formation**, since goblet cells secrete mucus essential for **lubricating the firm/hard stool**.
- ✓ The mucosa also contains **crypts of Lieberkühn** (intestinal glands), located **basally**. These crypts have a different cellular composition compared to those in the small intestine, Specifically, they **lack Paneth cells**. (*colon is rich in normal flora, and Paneth cells are antibacterial, their presence would disrupt the healthy microbial balance in the colon.*)

Histology of the Large Intestine

Dr.'s figure:

*Can be clearly seen in x-ray

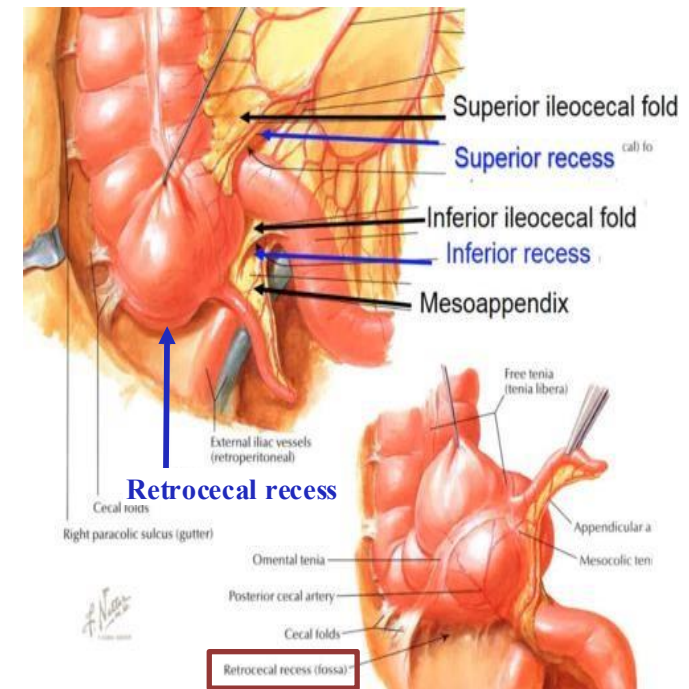
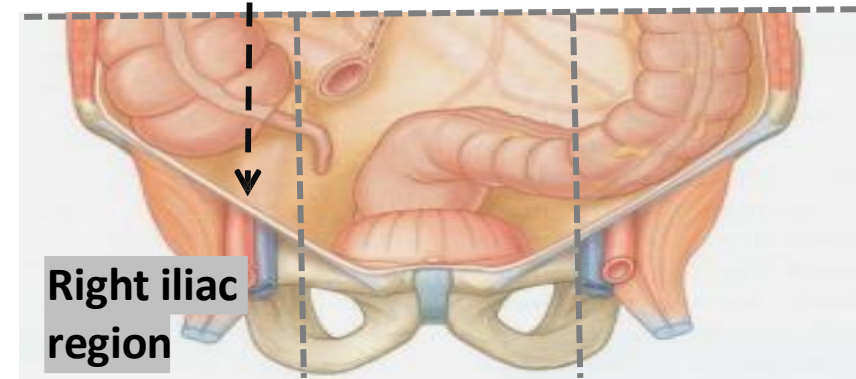


5- Cecum

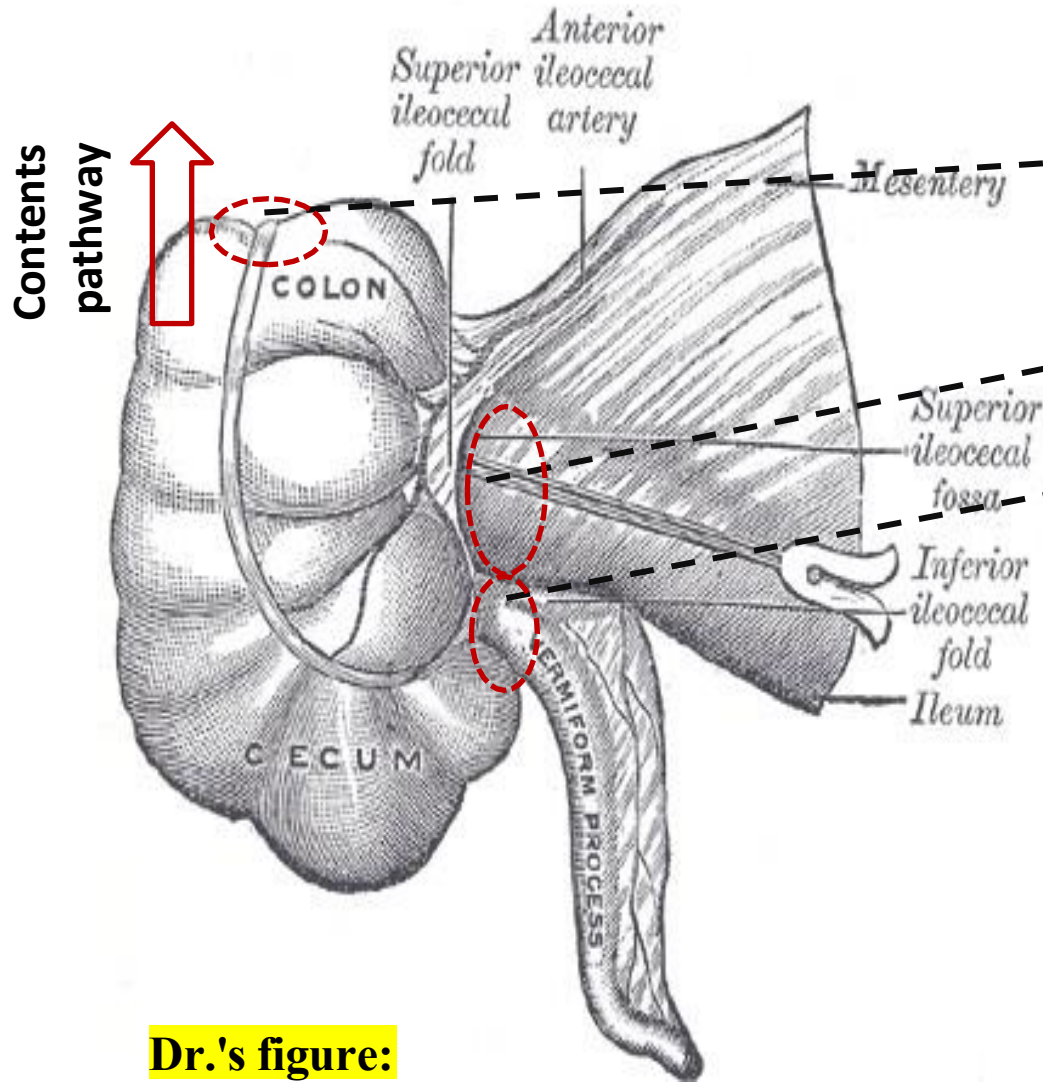
- ✓ **Type:** Blind-ended pouch (*sac*).
- ✓ **Location:** Located in the **right iliac fossa**, above the **lateral half of the inguinal ligament**.
- ✓ **Size:** About **2.5 - 3 inches in diameter**
- ✓ The **cecum** is entirely covered by **peritoneum**, classifying it as an **intraperitoneal organ**. However, it is **fixed** in the **right iliac fossa**.
- ✓ This fixation causes the formation of **peritoneal folds**, which create three distinct **recesses/fossa**:
 1. **Superior ileocecal recess**
 2. **Inferior ileocecal recess**
 3. **Retrocecal recess** (a common site for the appendix)

Refer to slide (19)

Inguinal ligament



5- Cecum



Dr.'s figure:

- **Cecum has three openings:**

- 1. Opening to the Ascending colon

- 2. Ileum orifice

- 3. Appendix orifice

- **Cecum function:**

The cecum maintains intracecal pressure, which serves two main functions:

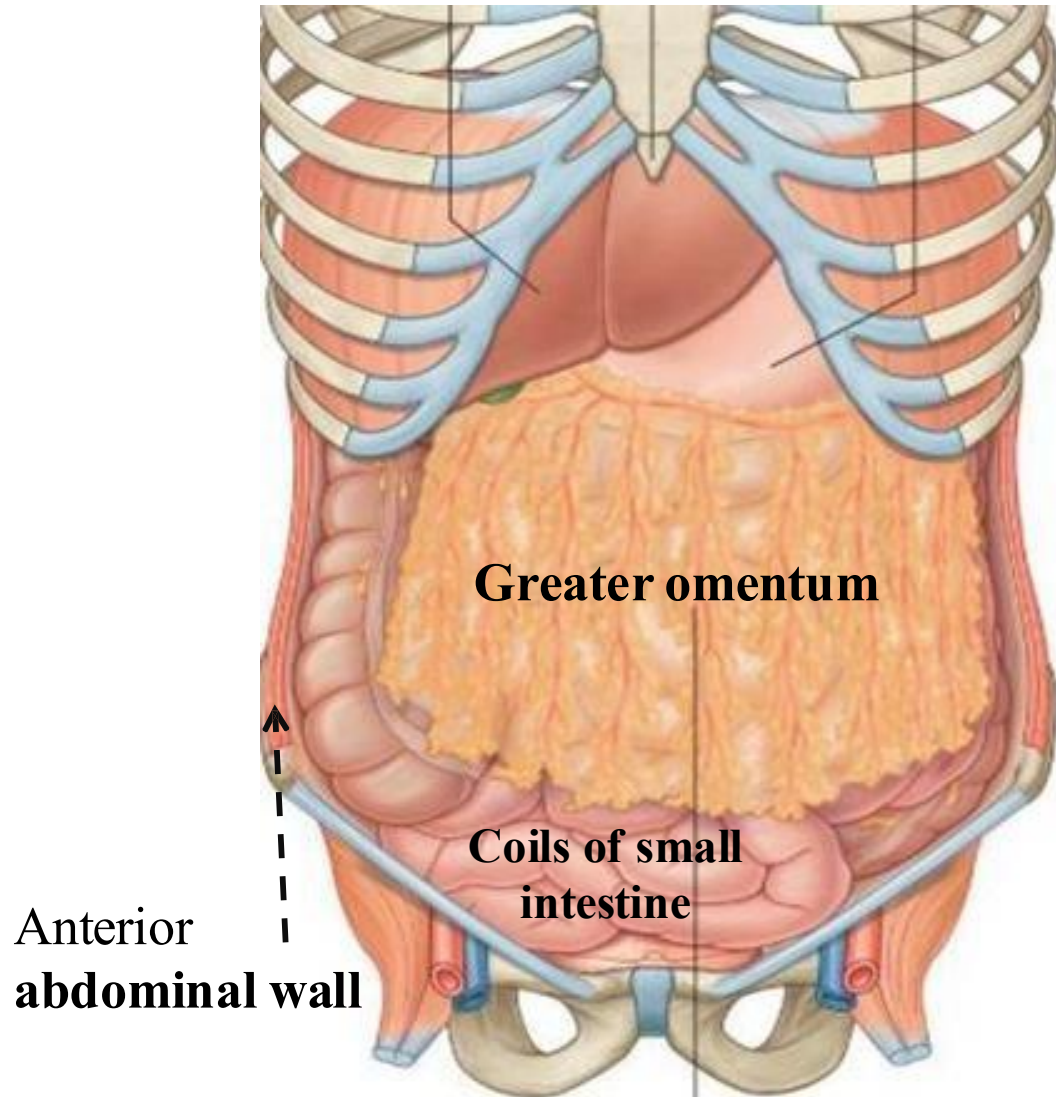
- Promotes upward movement of contents into the ascending colon.
- Aids in functional closure of the ileocecal valve. *Refer to slide (16)*

6- Relations of Cecum

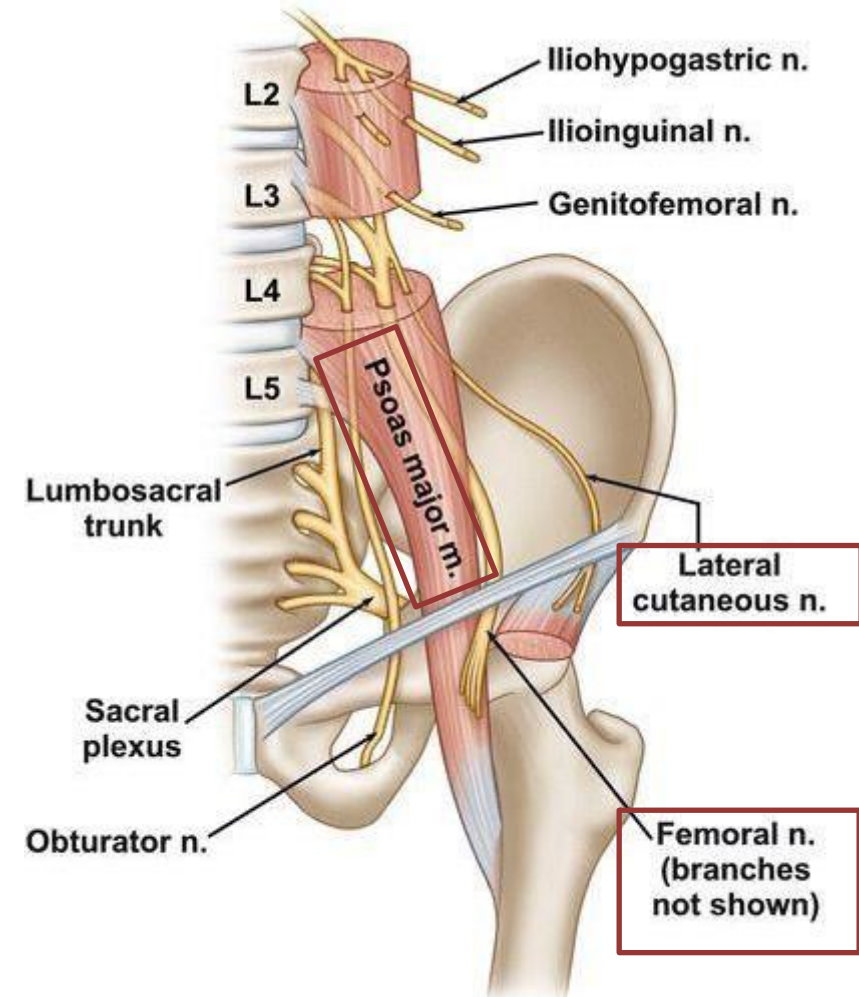
| Region | Structures |
|--|---|
| Anteriorly <i>Refer to next slide</i> | - Coils of small intestine , (mostly ileum) |
| | - Greater omentum , extending to the greater sac of stomach |
| | - Anterior abdominal wall in the right iliac region (☺ palpation here helps feel the cecum) |
| Posteriorly <i>Refer to next slide</i> | - Psoas and iliacus muscles --> together forms iliopsoas muscle. |
| | - External iliac vessels , Which eventually forms Femoral Artery. |
| | - Femoral nerve |
| | - Lateral cutaneous nerve of the thigh |
| Postero-medially | - The appendix |
| Medially | - Small intestine (ileum) |

Relations of Cecum

Anteriorly:



Posteriorly:



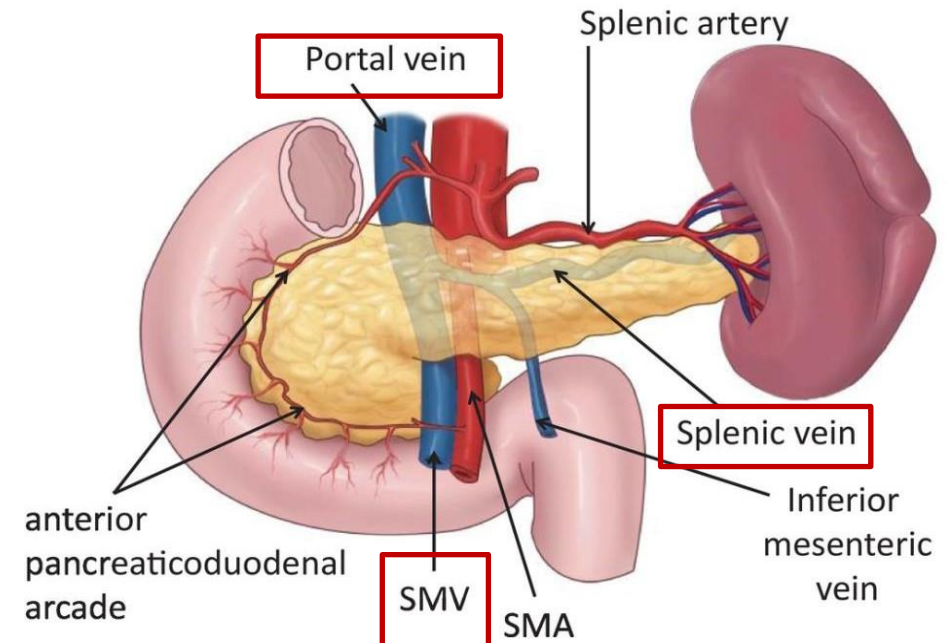
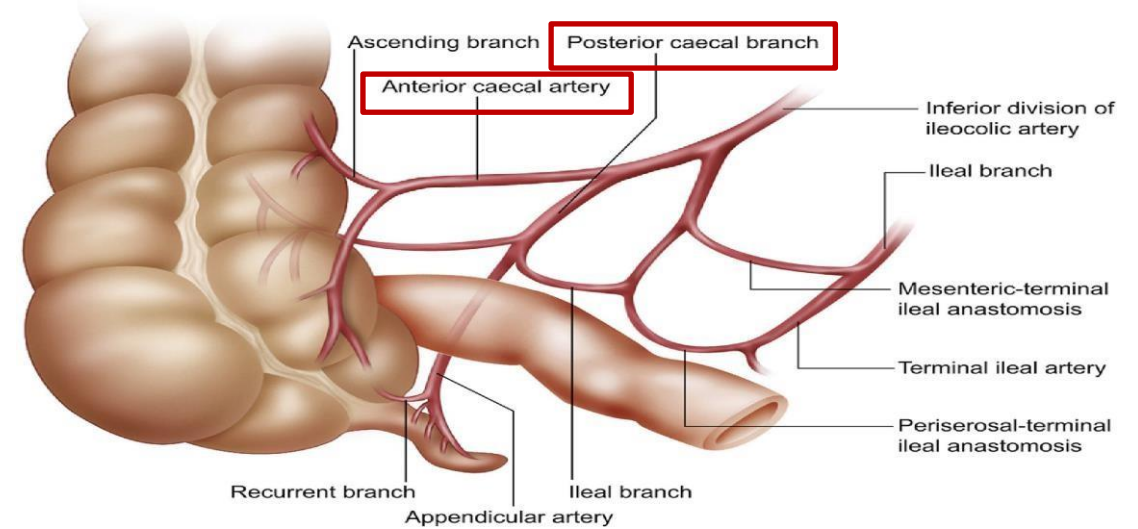
7- Blood Supply of Cecum

✓ Arterial Supply:

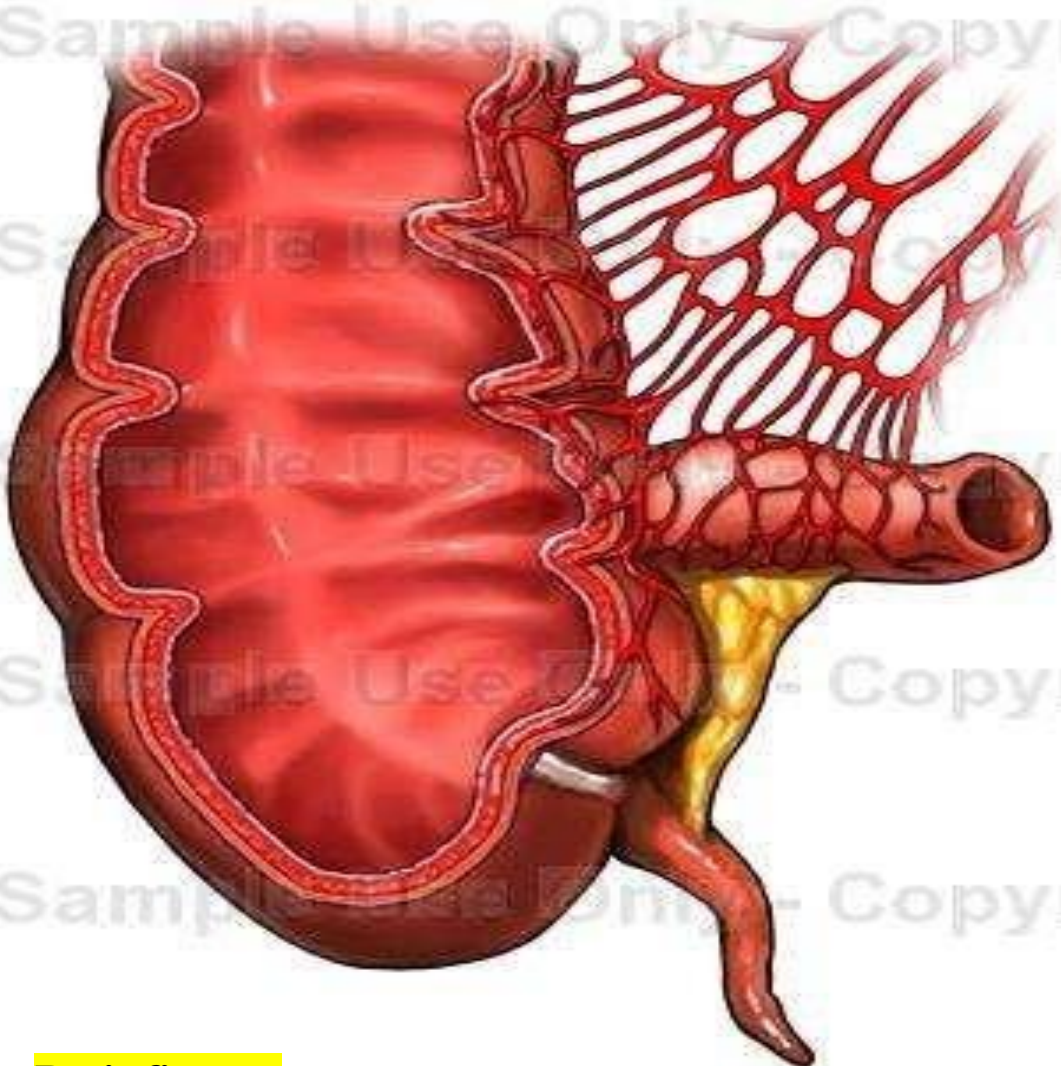
- Provided by the **anterior and posterior cecal arteries**, branches of the **superior mesenteric artery**.

✓ Venous Drainage:

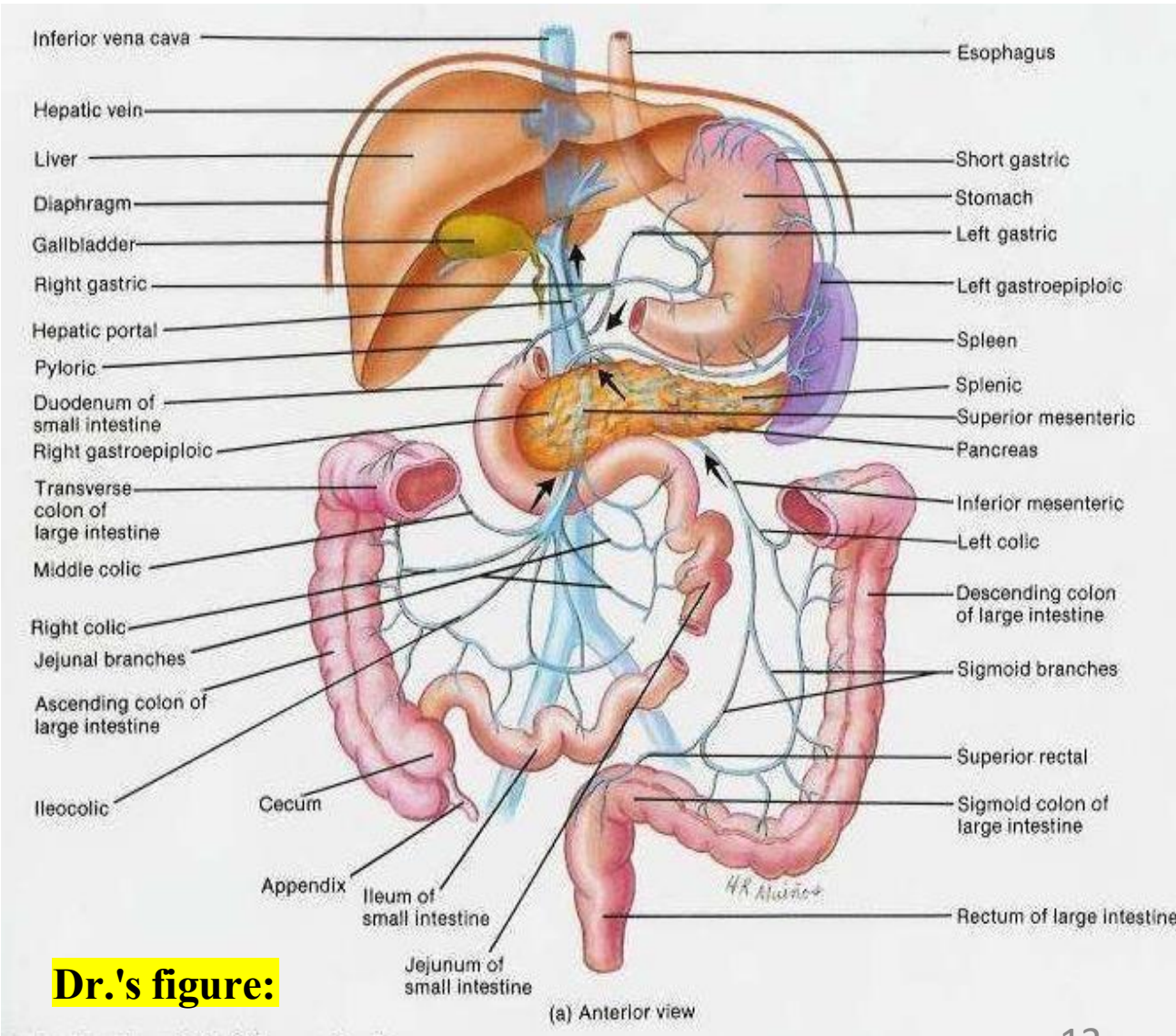
- The **anterior and posterior cecal veins** drains into the **superior mesenteric vein**, which ascends posterior to the pancreas, usually behind the **neck of the pancreas**, it joins the **splenic vein** to form the **portal vein**, delivering blood to the liver.



Blood Supply of cecum



Dr.'s figure:



Dr.'s figure:

Venous Drainage:

Portal vein

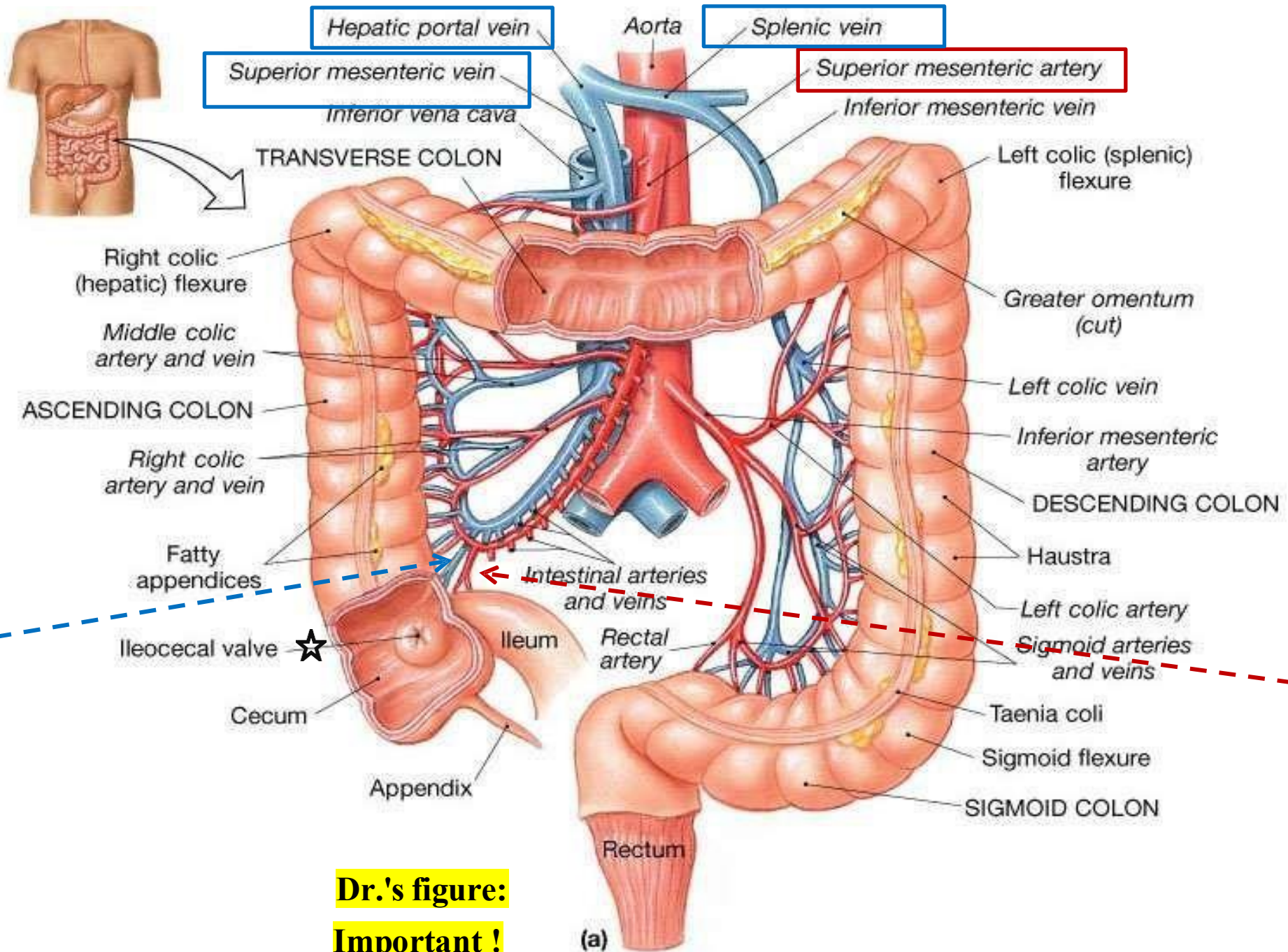
+ Splenic Vein



Superior mesentric V.



Anterior & posterior cecal V.



Arterial Supply:

Abdominal aorta



Superior mesentric A.



Anterior & posterior cecal A.

**Dr.'s figure:
Important!**

8- Nerve Supply & Lymphatics of Cecum

✓ **Lymphatic Drainage:**

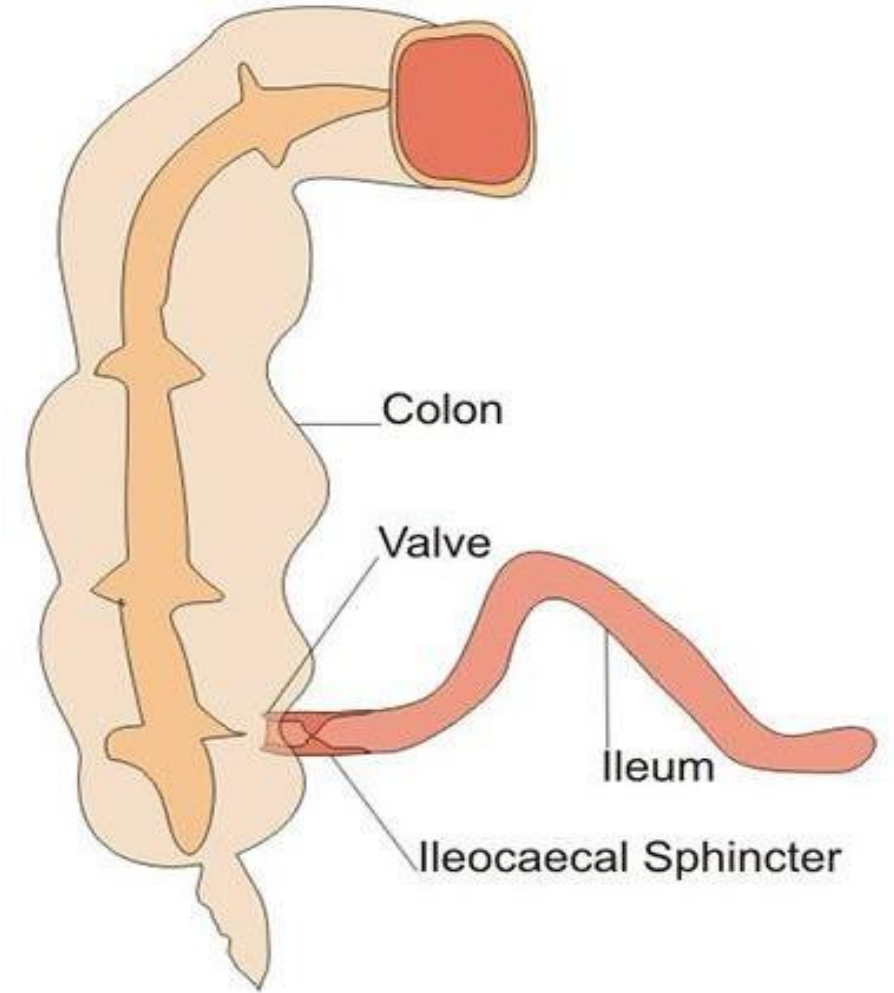
- Lymph flows through **mesenteric lymph nodes**, ultimately reaching the **superior mesenteric nodes**.

✓ **Nerve Supply:**

- Derived from the **superior mesenteric plexus**, formed by **sympathetic** and **parasympathetic (vagus)** fibers.
 - **Sympathetic fibers:**
Supply **blood vessels** and **sphincters**.
 - **Parasympathetic fibers:**
Supply **glands** and **smooth muscle** to promote peristalsis

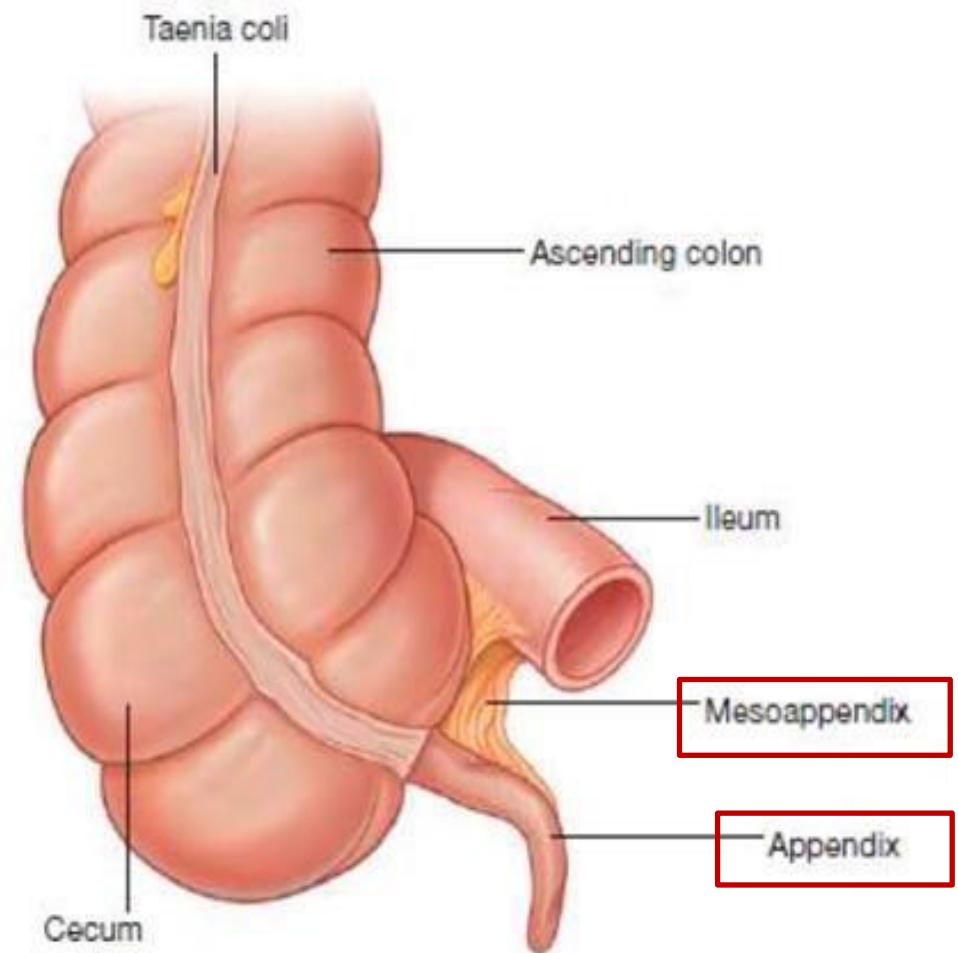
9- Ileocecal Valve

- ✓ A rudimentary structure acting as a **physiological** (not anatomical) **sphincter**.
- ✓ Composed of **two horizontal mucosal folds** located around the opening. **No prominent smooth muscle thickening** at the junction
- ✓ The **mucosal folds** and **intracecal pressure** work together to form a **valve-like mechanism**.
- ✓ Its main function is to **prevent regurgitation** of contents from the cecum back into the ileum.
- ✓ The activity of the valve is influenced by both **hormonal and neural** factors.

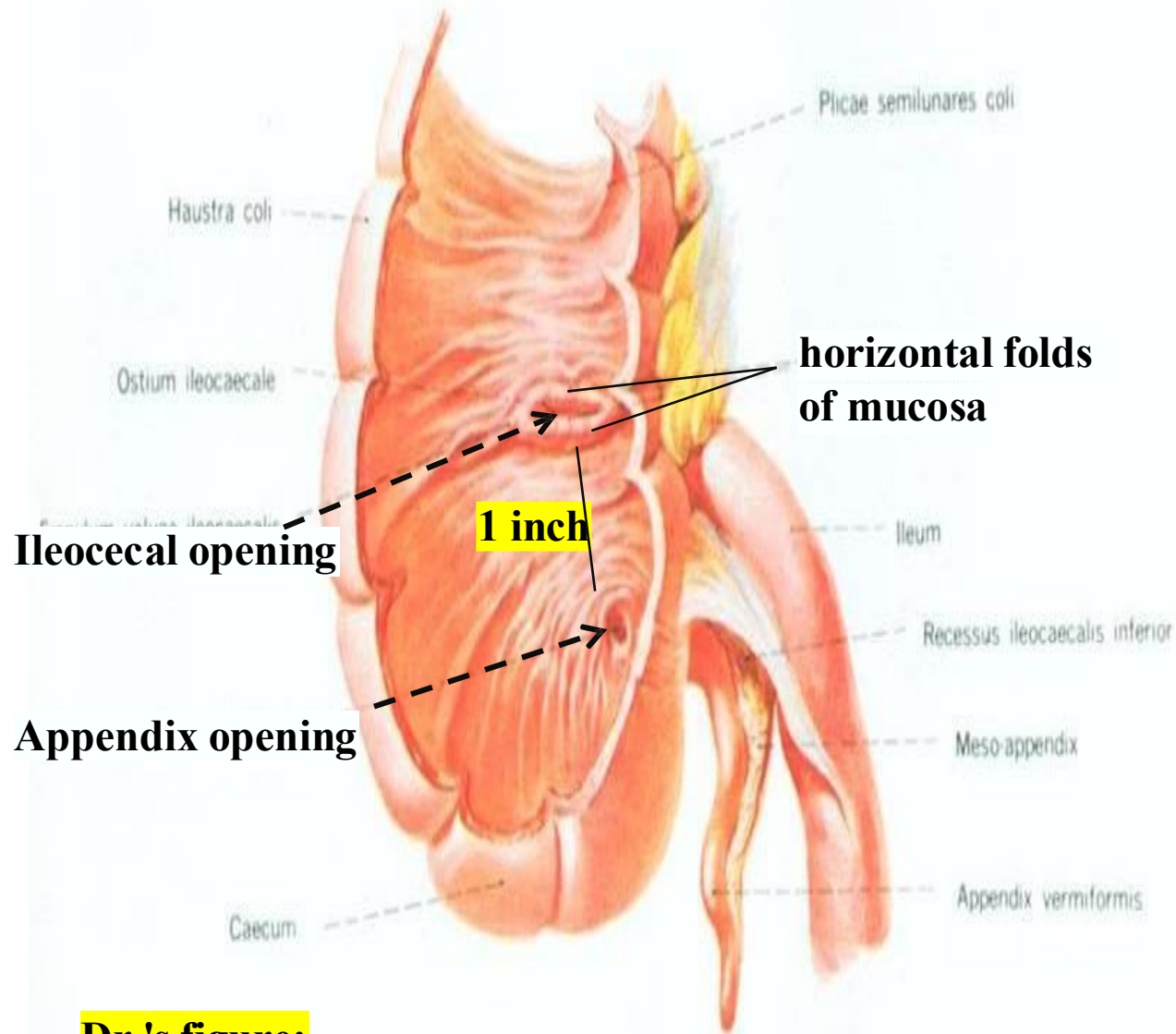


10- Appendix

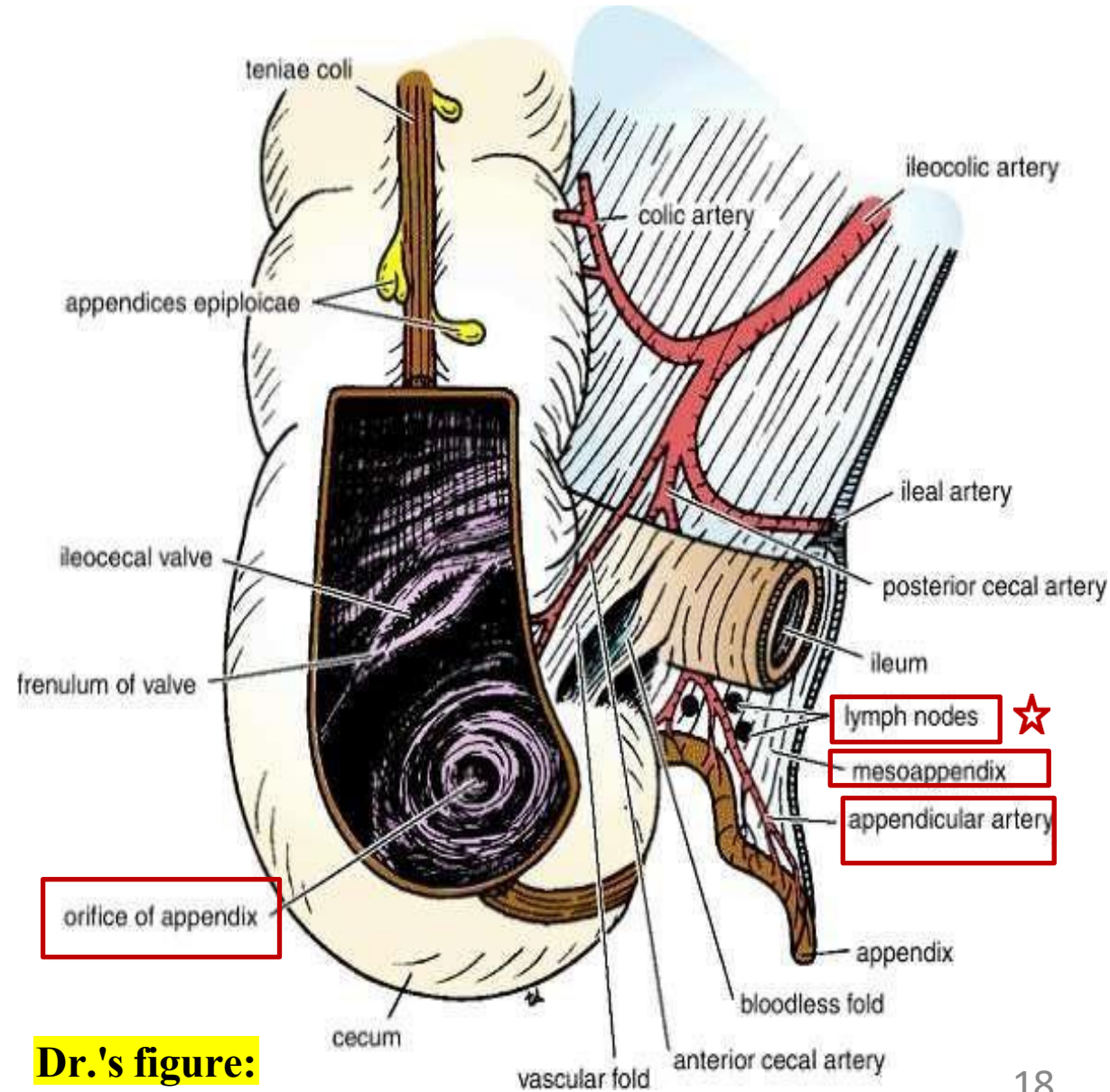
- ✓ The appendix is a narrow, muscular, blind-ended tube located in the right iliac fossa.
- ✓ It is rich in **lymphoid** tissue, playing an immune role rather than a digestive one.
- ✓ It is frequently ☹️ **inflamed (appendicitis)**, often requiring 😊 **surgical removal (appendectomy)**.
- ✓ **Length:** Varies from 3–5 inches (2–22 cm); may enlarge/expand when inflamed.
- ✓ The appendix is **completely covered by peritoneum**, making it **intraperitoneal**.
- ✓ It is suspended by a short mesentery called the **mesoappendix**, which attaches it to the mesentery of the small intestine.



Appendix



Dr.'s figure:

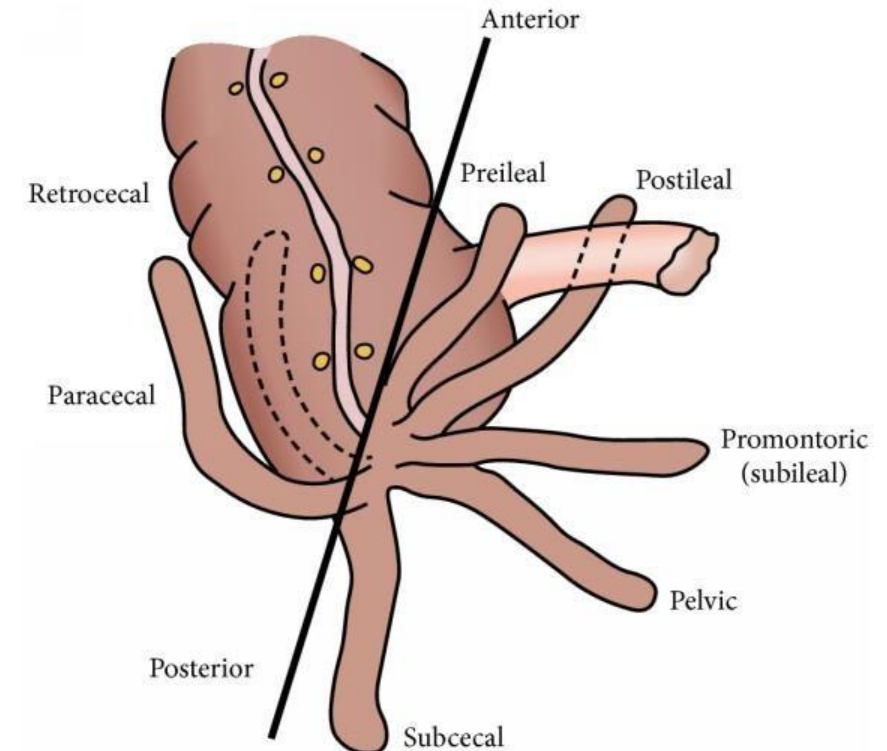


Dr.'s figure:

11- Appendix Position

- ✓ The position of the appendix can vary, but it always originates from the **posteromedial wall of the cecum**:

| Position | Description | Frequency |
|-------------------|--|--------------------|
| Retrocecal | Behind the cecum in the retrocecal recess | ~74% (most common) |
| Pelvic | Descends into the pelvis near right ovary / uterus | ~21% |
| Subcecal | below the cecum | Rare |
| Preileal | In front of the terminal ileum | Rare |
| Postileal | Behind the terminal ileum | Rare |



- ✓ The last two positions are located near the **ileocecal junction**, either Infront or behind.

12- Surface Anatomy of the Appendix

McBurney's Point:

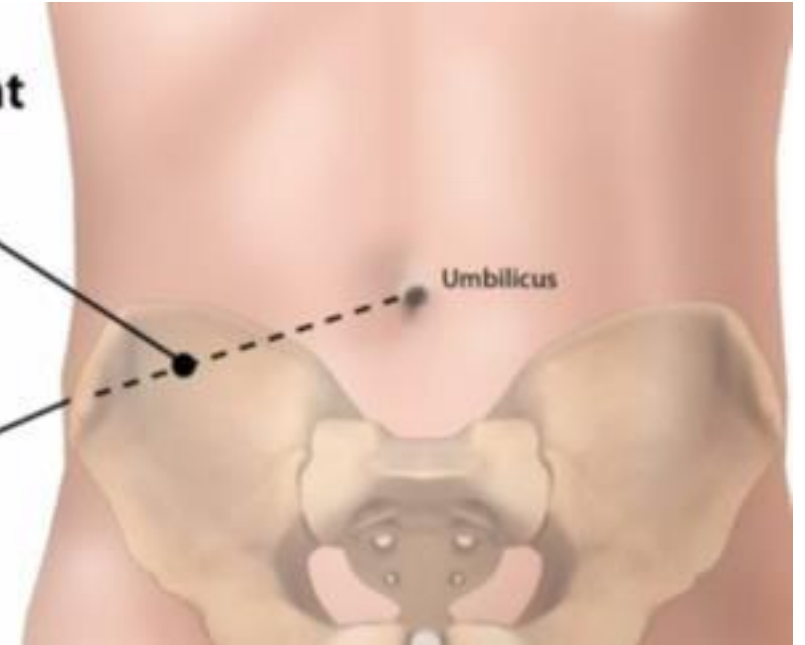
- ✓ A 😊 **landmark** used to locate the **base of the appendix** on the abdominal wall.
- ✓ It lies lower **one-third / upper two-thirds** of the distance from the **anterior superior iliac spine (ASIS)** to the **umbilicus** on the **right side**.
- ✓ The 😊 **McBurney's incision** is used in **appendectomy**, and is made at McBurney's point, which lies parallel to the inguinal ligament, Traditionally used for **open appendectomy**.
- ✓ Currently, the procedure is often performed using an **endoscope**, an incision is made near the umbilicus to insert the endoscope, through which the appendectomy is carried out.

McBurney's Point

2/3 of the way from
umbilicus to ASIS

Anterior Superior Iliac Spine

Umbilicus



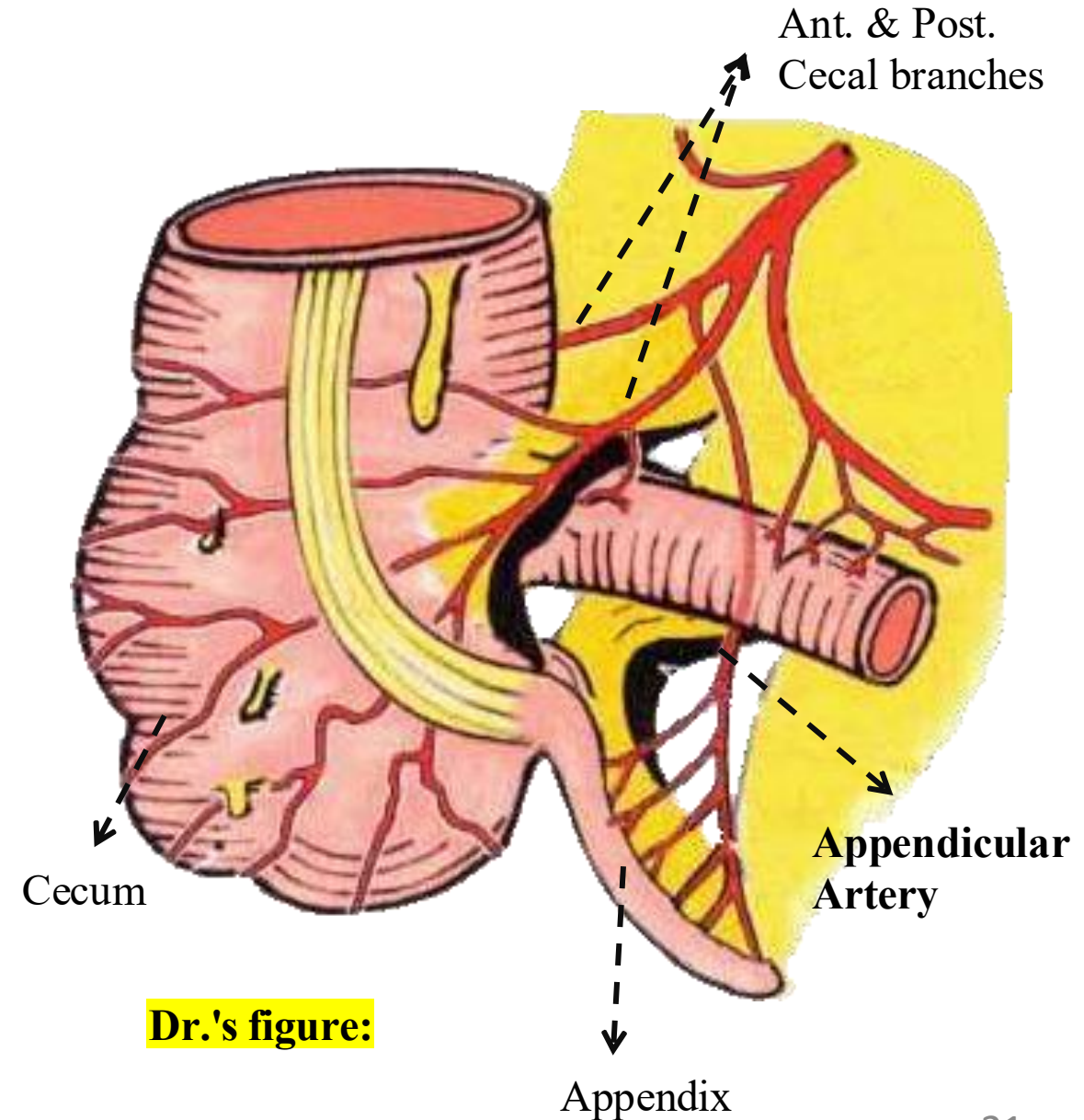
13- Blood Supply of The Appendix

✓ Arterial Supply

The **appendicular artery** is a branch of the **posterior cecal artery**.

✓ Venous Drainage

The **appendicular vein** accompanies the artery and **drains into the posterior cecal vein**, which then drains into the **superior mesenteric vein**.



Dr.'s figure:

14- Acute Appendicitis and Appendectomy

➤ Relate to Pathology

✓ **Epidemiology:**

Acute appendicitis is **uncommon at the extremes of age** (very young and elderly).

✓ **Vascular Complication – Gangrene & Perforation:**

The appendix is supplied by a single artery, the **appendicular artery**, a branch of the **posterior cecal artery**. Thrombosis of this artery can easily lead to **gangrene** and **perforation**, due to the absence of collateral circulation, since the appendix is isolated in the **mesoappendix** .

✓ **Why not in Acute Cholecystitis?**

In contrast, the **gallbladder** rarely undergoes gangrene. It lies on the liver and receives **direct blood supply** from it. This anatomical relation protects it from ischemic injury.

14- Acute Appendicitis and Appendectomy

➤ Relate to Pathology

✓ **Diagnosis and Surgical Decision-Making:**

When diagnosing appendicitis, we first analyze **the white blood cell (WBC) count**. A high WBC count typically indicates an **infection**. In some cases, the patient may be placed under observation and undergo additional tests to monitor their condition.

If the likelihood of appendicitis is around 60%, the decision is made to proceed with surgery. During the surgery, a sample from the appendix is taken to confirm the presence of inflammation.

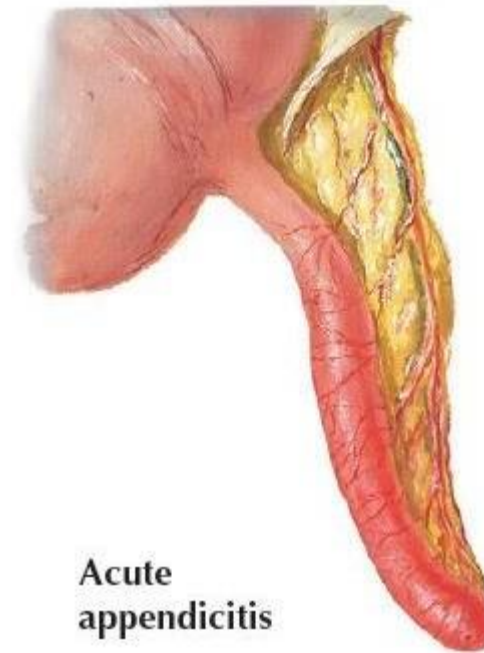
In some cases, if there is a strong clinical suspicion of appendicitis, the appendix may be removed even before confirmation, based on the judgment that the patient likely has appendicitis.

14- Acute Appendicitis and Appendectomy

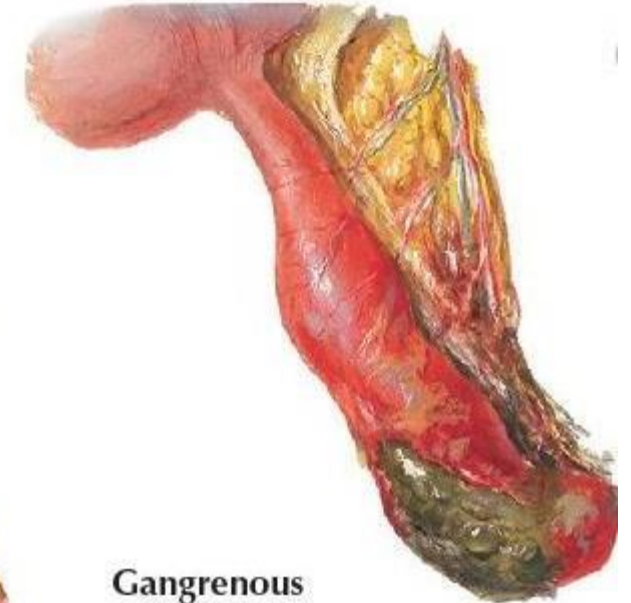
➤ Relate to Pathology

✓ Why Appendectomy is Necessary:

- The **appendix has a narrow lumen**, making it highly susceptible to obstruction during infection (due to inflammation and edema).
- If not treated early, this can lead to **rupture** and then to **peritonitis**.
- Therefore, once ☹ **acute appendicitis** is diagnosed, **surgical removal** ☺ (**appendectomy**) is necessary.



Acute
appendicitis



Gangrenous
appendicitis


14- Acute Appendicitis and Appendectomy

➤ Relate to Pathology

• Surgical Technique – Appendectomy

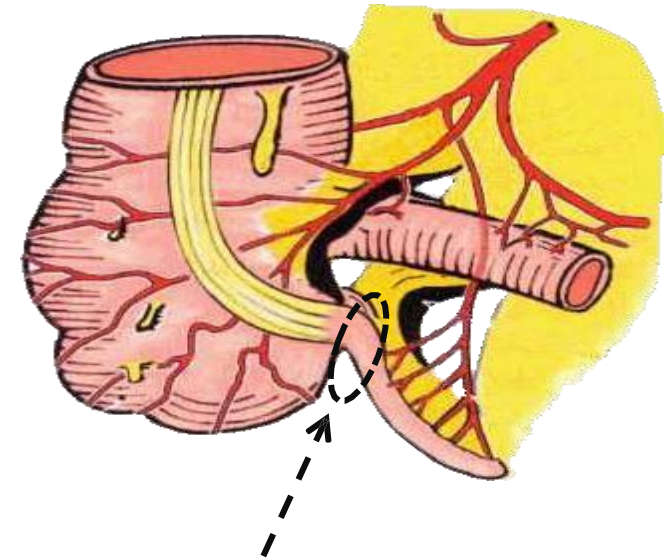
1. Double Ligation of Appendicular Vessels

- The **appendicular artery and vein** are identified in the **mesoappendix**.
- Two **ligatures (ties)** are applied to each vessel, one near the base and one farther away.
- A **cut is made between the two ligatures** to safely divide the vessels and prevent bleeding.



2. Management of the Appendix Base

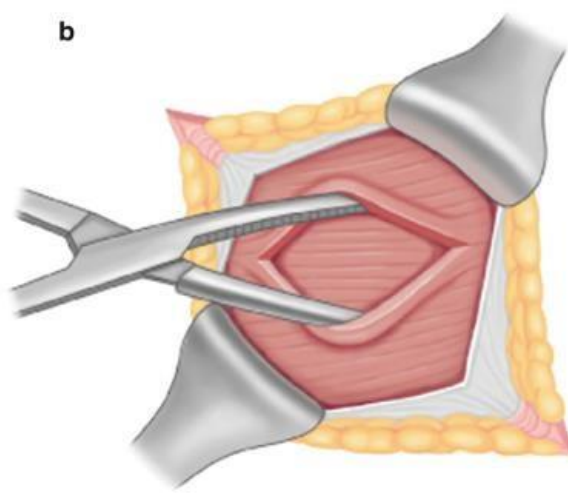
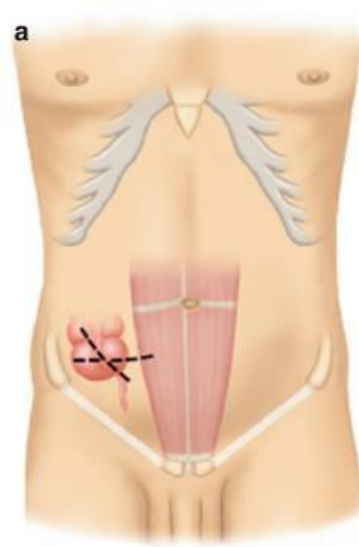
- At the **base of the appendix**, a ***circular stitch** is applied.
**Similar to sewing in a circular pattern using a needle and thread.*
- The suture is then tightened, securely narrowing and closing the base of the appendix.
- Finally, the **appendix is removed from its base**.



Highly recommended video: click [here](#) or refer to the next slide.

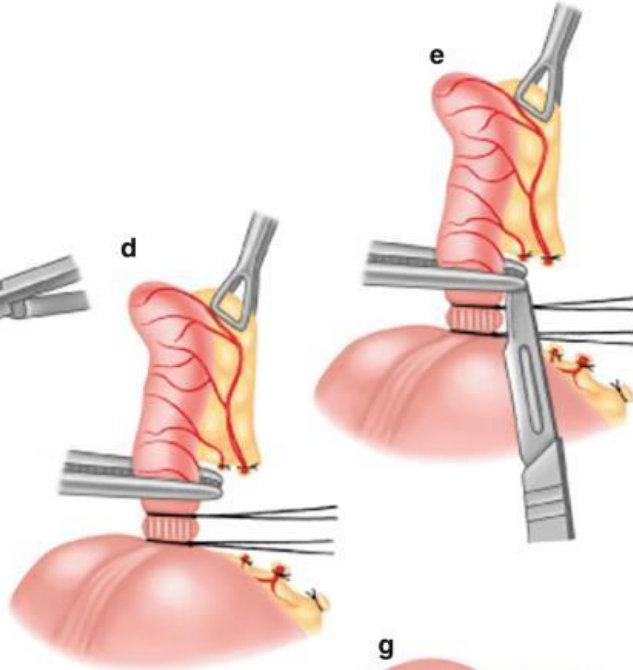
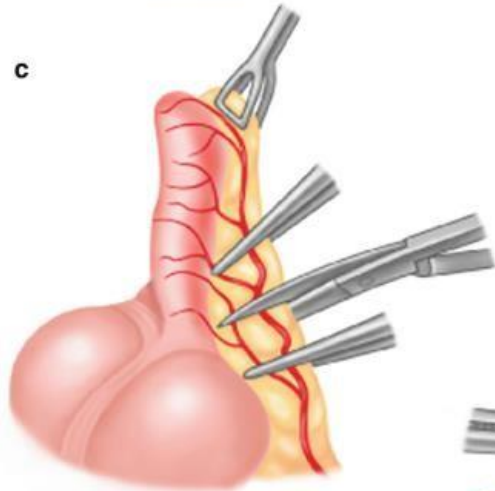
Further Clarification:
(Extra slide)

(a) A right lower quadrant incision (McBurney's) is made over the appendix location



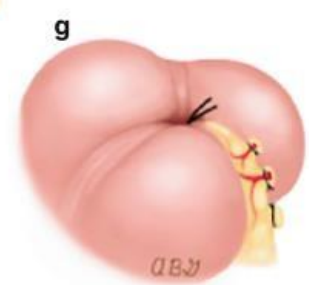
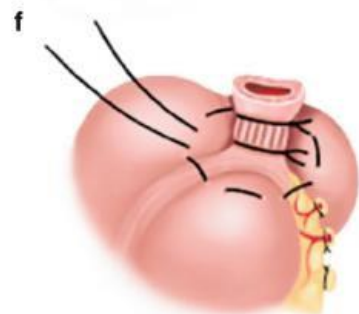
(b) Layers of the abdominal wall are retracted to expose the peritoneum and access the abdominal cavity.

(c) Mesoappendix is dissected, and vessels (appendicular artery and vein) are clamped.



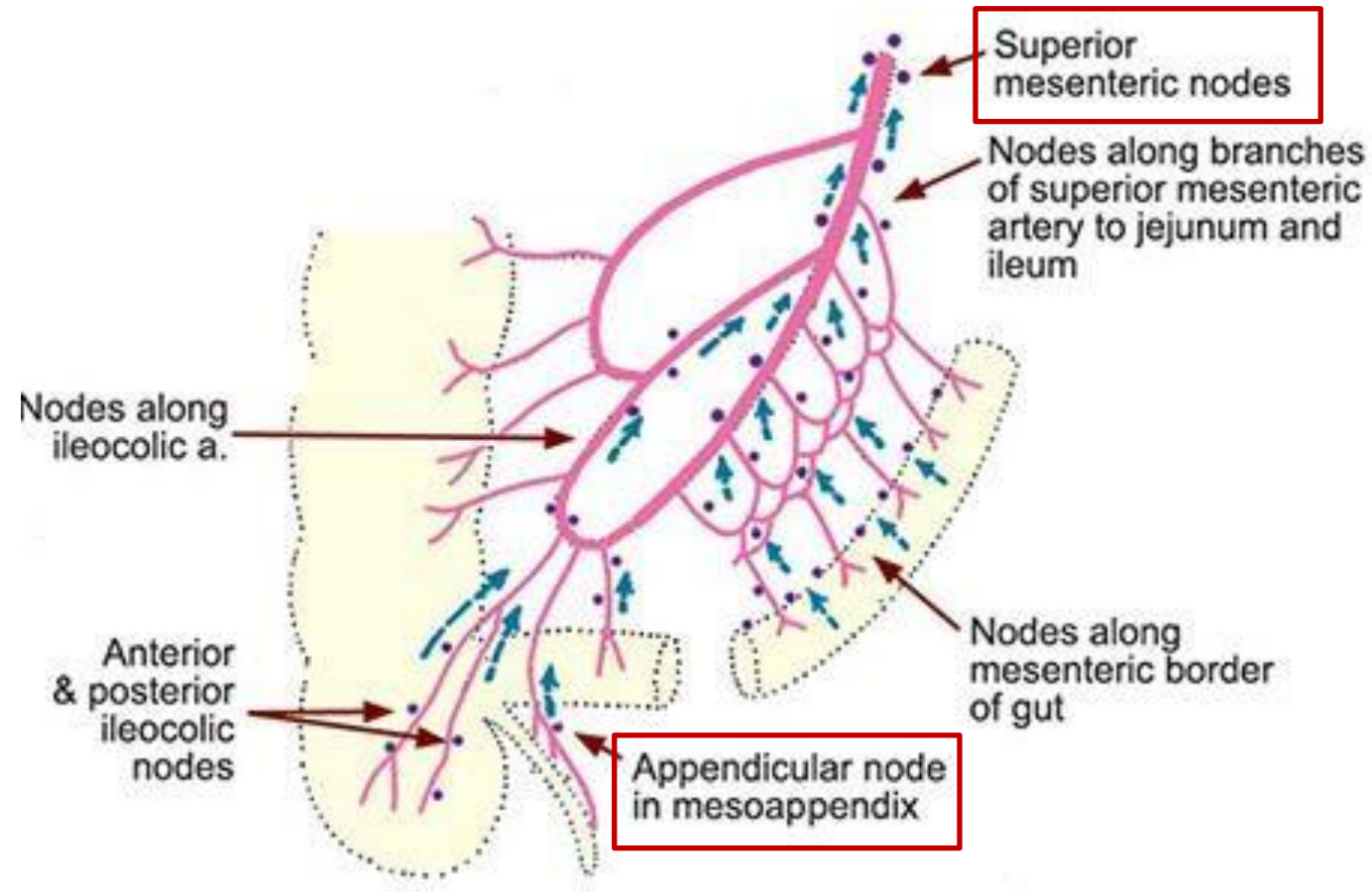
(d , e) The appendicular artery and vein are double-ligated in the mesoappendix and divided. & A tight ligature is then placed at the base of the appendix, near the cecum.

(f) A circular purse-string suture is placed around the base. The appendix is cut and removed.



(g) purse-string stitch is pulled tight to hide the stump and close it safely.

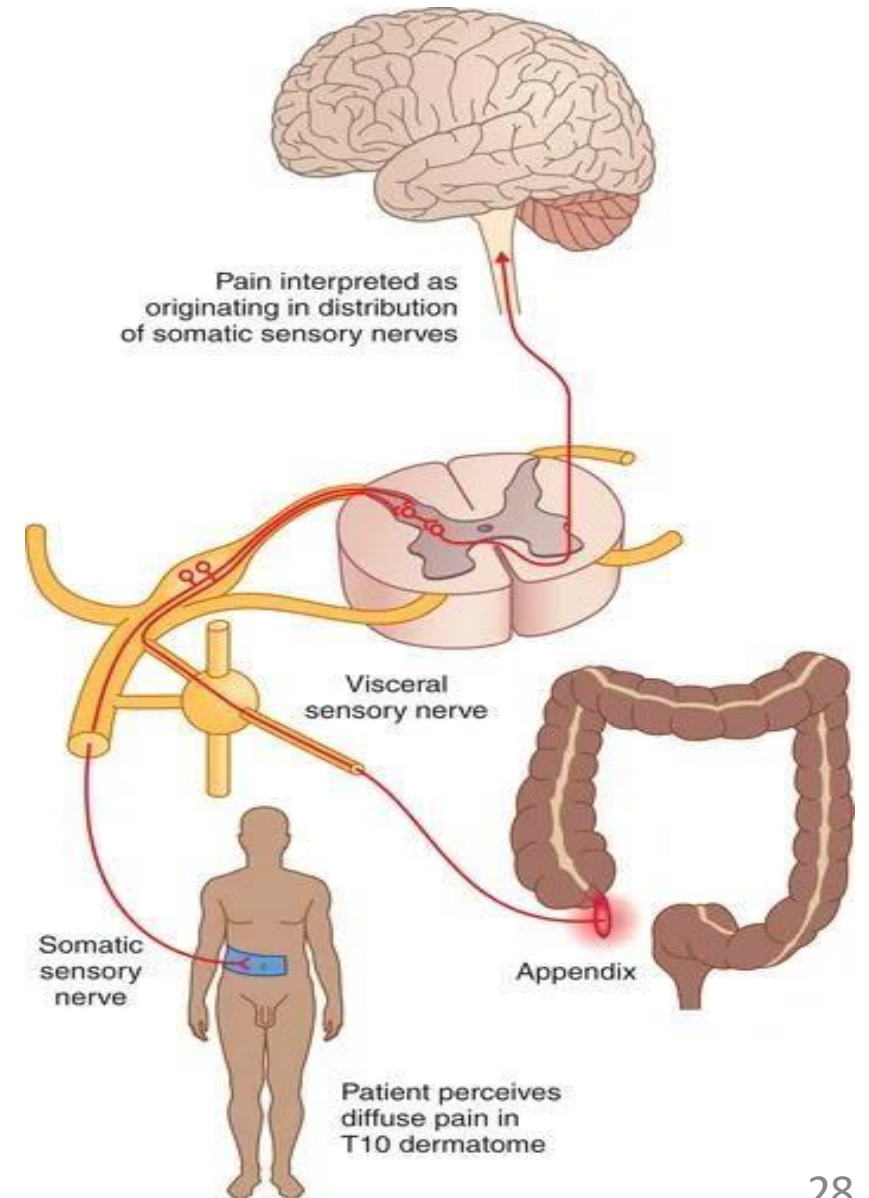
15- Lymphatic Drainage of appendix



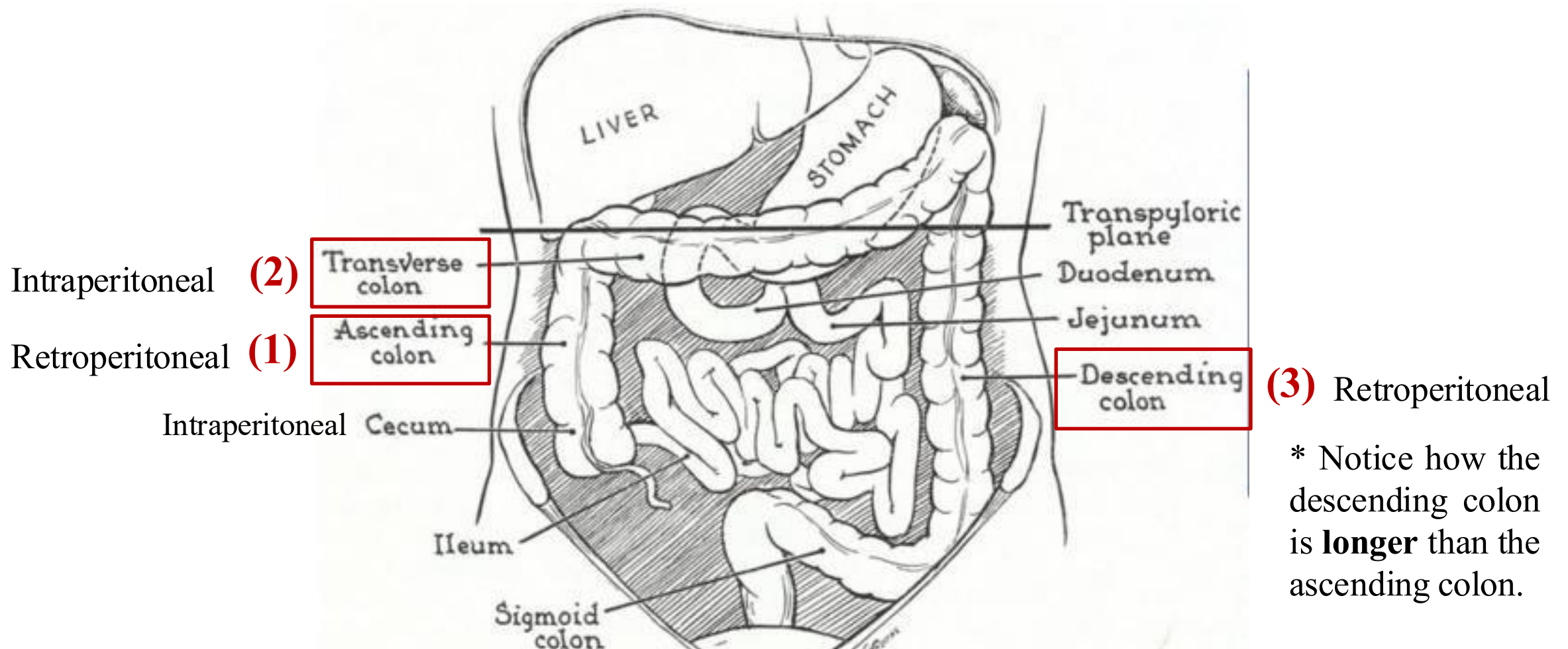
- ✓ The lymph vessels drain into one or two nodes lying in the mesoappendix, eventually into the **superior mesenteric nodes**.

16- Nerve Supply of appendix

- ✓ The sensory fibers supplying the **skin around the umbilicus** arise from the T10 spinal nerve.
- ✓ The **appendix** receives *visceral* innervation from the same spinal level (T10).
- ✓ Therefore, in **early** appendicitis, the pain is referred to the **umbilical region**.
- ✓ As inflammation **progresses** *involving the parietal peritoneum*, the pain becomes localized to the **right iliac fossa**.
- ✓ Briefly, **the peritoneum over the appendix is innervated by the 10th intercostal nerve, the same nerve that supplies the skin of the umbilicus.**



17- The COLON! - overview



The **entire** colon (Ascending/Transverse/Descending) contains:

1-Taenia coli, 2-Sacculations (haustra), and 3-Appendices epiploicae.

17- The COLON! - *overview*

Explained in Part 2, At 15:00.

- ✓ Not all organs in the abdomen are mobile; that is, **not all are intraperitoneal.**

Some are fixed to the posterior abdominal wall.

(?) If all the organs were mobile:

- 1 Viscera would not be properly fixed, and the **abdomen would be disorganized.**
- 2 It would make it **difficult to access** deeper organs.

For instance, during 😊 **abdominal surgery**, when searching for a deep organ, we move the intestines aside to reach the area. Even when some organs are mobile, they still have a specific range of movement because the fixed organs provide boundaries for them.

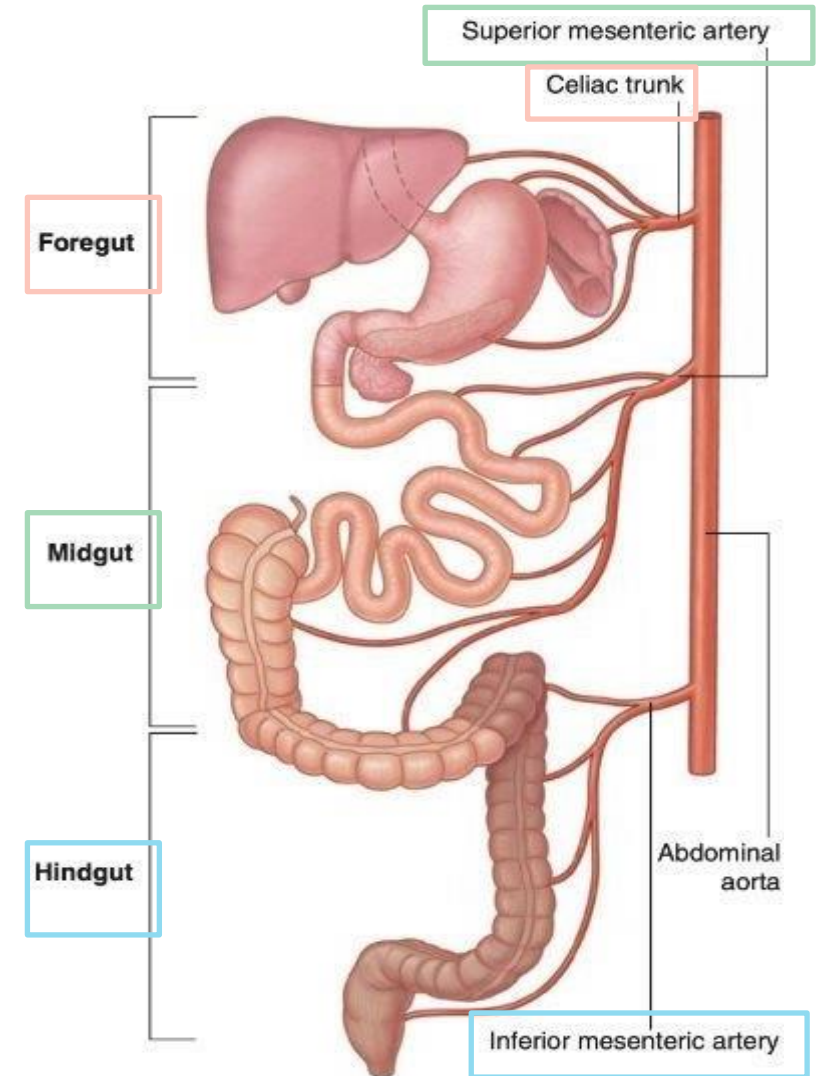
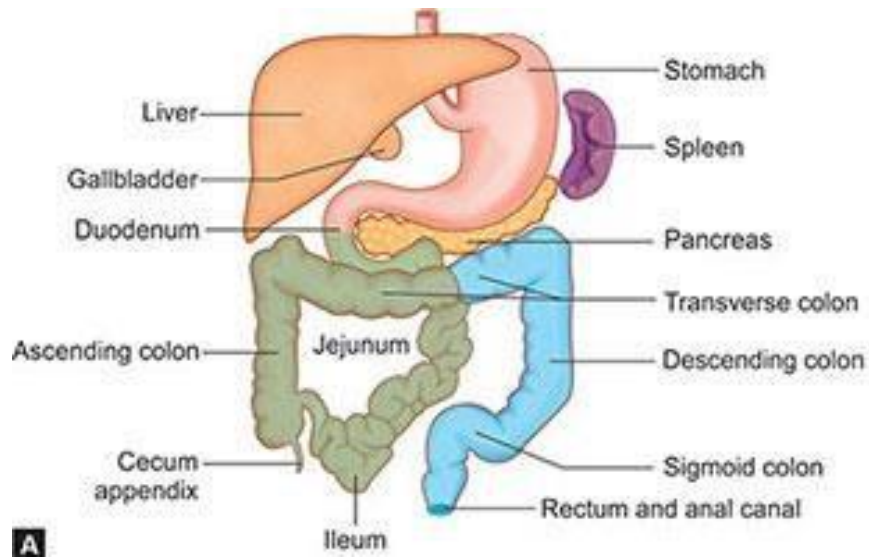
- ✓ **Lymph nodes** in the abdomen are removed during the treatment of 😞 **cancer in the large intestine (especially ascending / descending and sigmoid)** to prevent the spread of the disease.

**Recall: Cancer spreads mainly through lymphatics and the bloodstream*

17- The COLON! - overview

➤ Relate to Embryology:

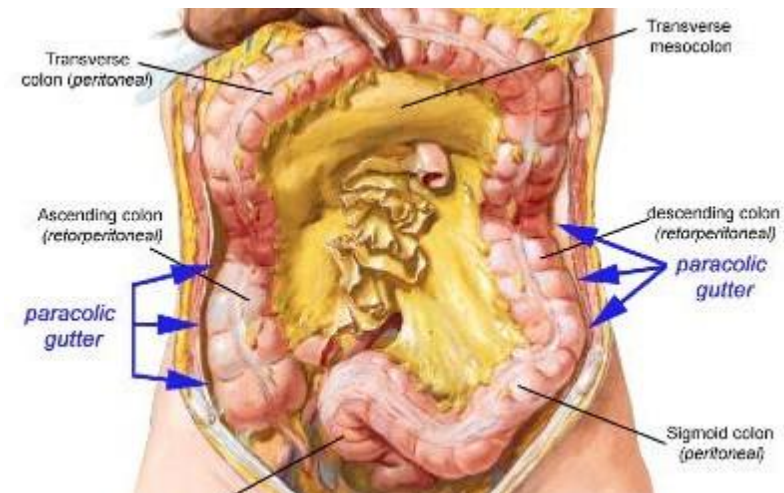
Keep this in mind, it's important for the next slides.



- **Ascending Colon + Medial 2/3 of Transverse Colon** originates from **Midgut** thus supplied by **Superior Mesenteric A.**
- **Lateral 1/3 of Transverse Colon + Descending Colon** originates from **Hindgut** thus supplied by **inferior Mesenteric A.**

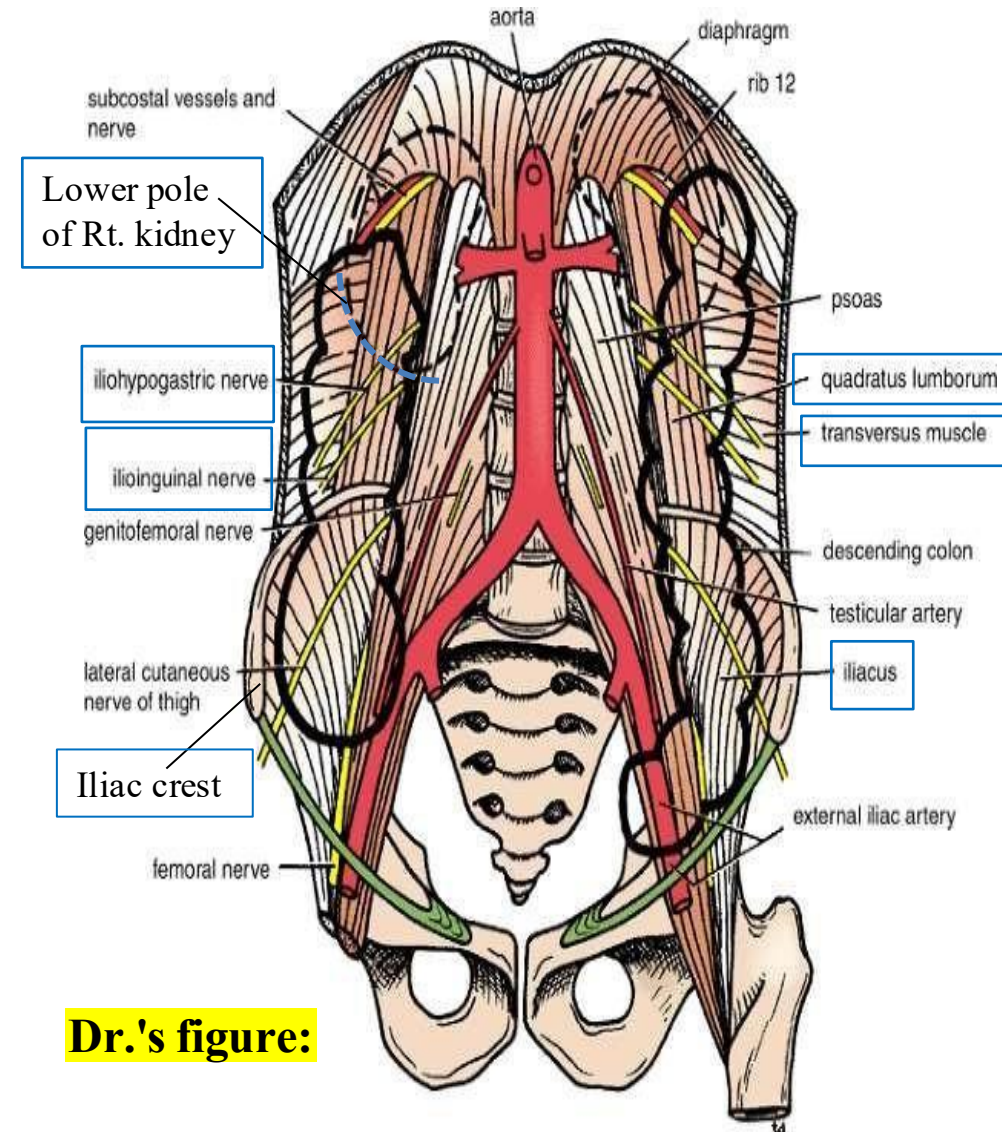
18- Ascending Colon

- ✓ The **ascending colon** is approximately **5 inches (13 cm)** long.
- ✓ It lies in the **right lower quadrant** of the abdomen.
- ✓ It extends upward from the **cecum** in the **right iliac fossa** to the **inferior surface of the liver**, where it bends to form the **right colic flexure (hepatic flexure)**.
- ✓ The **ascending colon is a retroperitoneal organ**, meaning it lies **behind the peritoneum**. Thus, The **peritoneum covers its anterior and lateral surfaces**, helping to **anchor it to the posterior abdominal wall**. (FIXED)
- ✓ This anatomical arrangement creates a **paracolic gutter** a **groove** alongside the colon through which **fluid and pus may collect or spread** in cases of ☹️ **peritoneal infection**.



19- Ascending Colon Relations

| Aspect | Structures Related |
|---|--|
| Anteriorly <i>Refer to Next slide</i> | <ol style="list-style-type: none"> 1. Coils of small intestine 2. Greater omentum 3. Anterior abdominal wall |
| *Posteriorly | <ol style="list-style-type: none"> 1. Iliacus muscle 2. Iliac crest 3. Quadratus lumborum 4. Origin of transversus abdominis muscle 5. Lower pole of right kidney 6. Iliohypogastric nerve (L1) 7. Ilioinguinal nerve (L1) |



Dr.'s figure:

Common Question:

20- Common relations

- ✓ The **greater omentum** can be positioned anterior to the cecum, appendix, ascending colon due to its length. Additionally, it plays a role in localizing infections.
- ✓ Due to the anatomy of **the anterior abdominal wall**, the ascending and descending colon can be 😊**palpated from the front**, as they are located anteriorly rather than posteriorly.

21- Blood Supply & lymphatics of Ascending colon

Recall: The ascending colon is of **midgut origin**; thus, arterial, venous, and lymphatic drainage is through the **superior mesenteric vessels and nodes**.

✓ Arterial Supply:

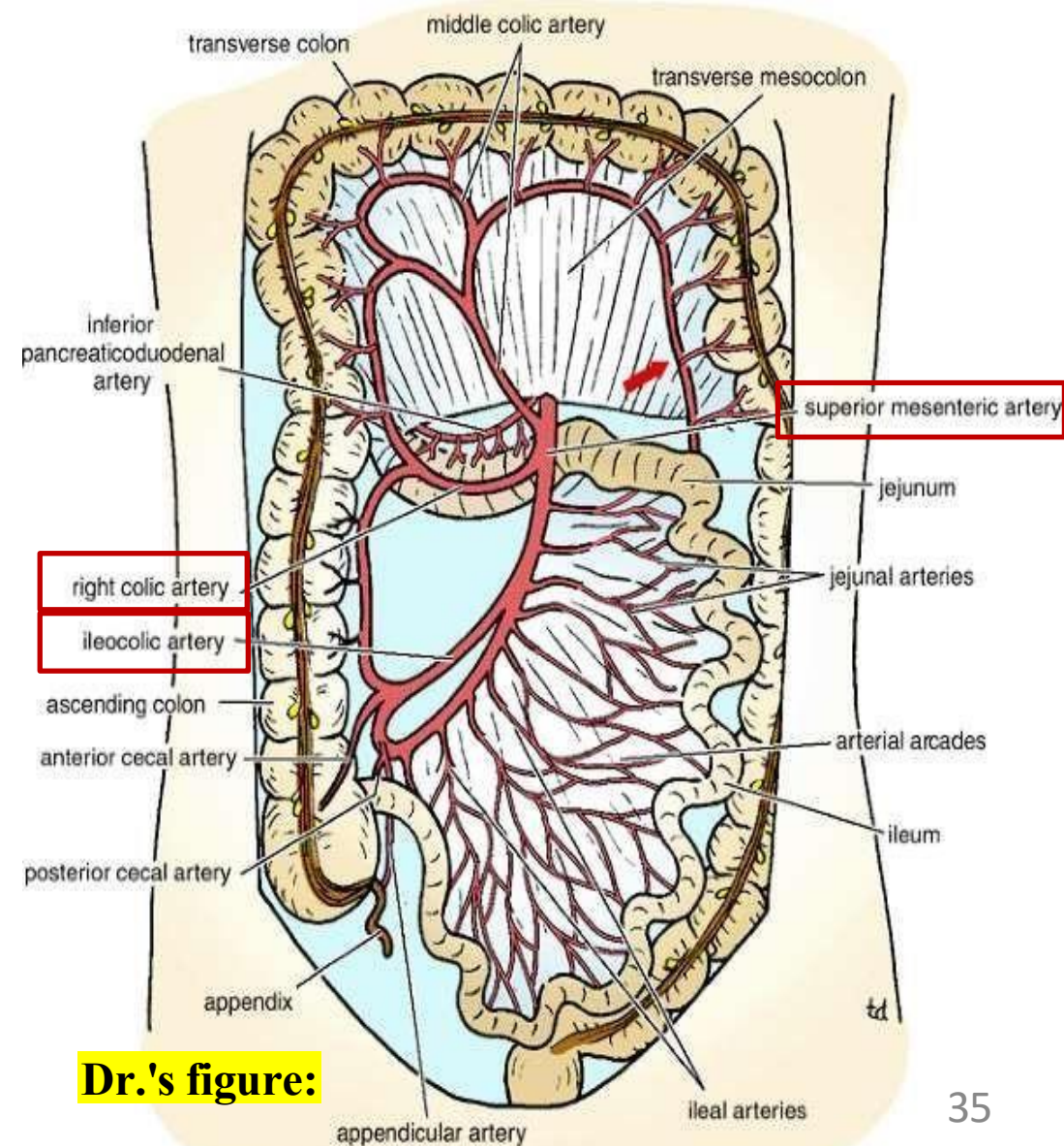
The **ileocolic** and **right colic arteries**, branches of the **superior mesenteric artery (SMA)**, supply the ascending colon and adjacent ileum.

✓ Venous Drainage:

The corresponding veins drain into the **superior mesenteric vein (SMV)**.

✓ Lymphatic drainage:

Superior mesenteric nodes.



Dr.'s figure:

22- Nerve Supply of ascending colon

✓ **Parasympathetic Innervation:**

Supplied by the **vagus nerve**.

✓ **Sympathetic Innervation:**

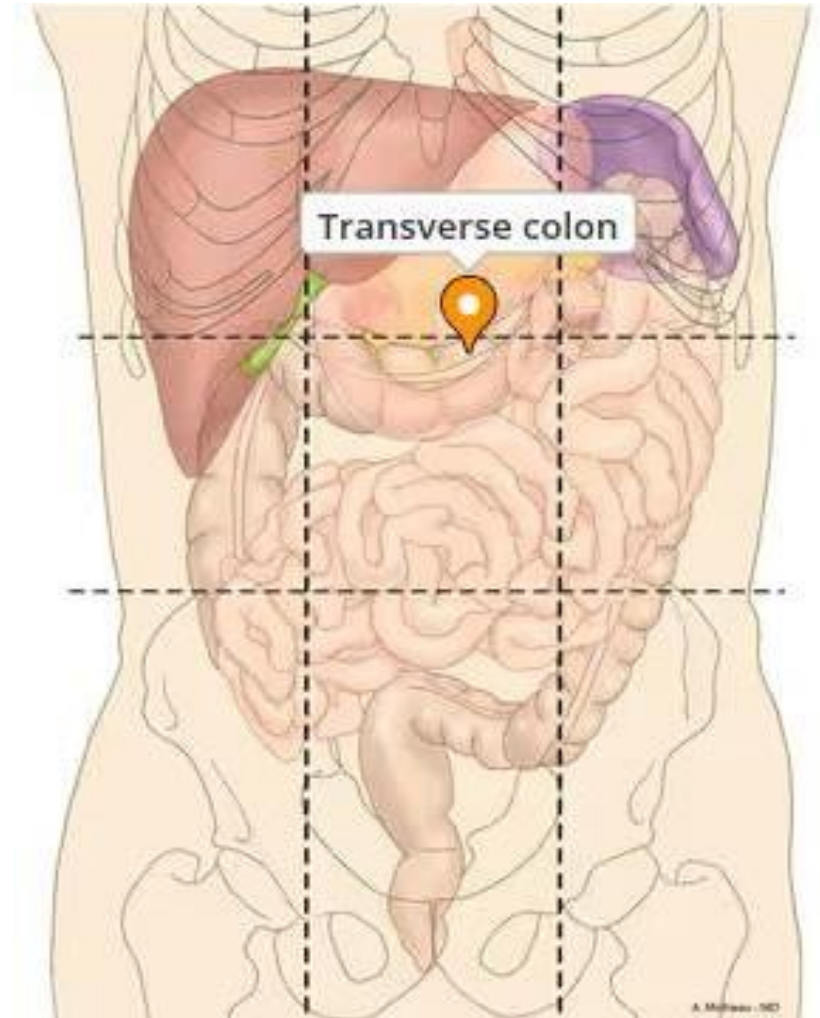
Derived from the **superior mesenteric ganglia**.

✓ **Formation of Plexus:**

Branches from the **vagus nerve** and **sympathetic fibers** join together to form a **nerve plexus**, which follows the **branches of arteries** supplying the ascending colon.

23- Transverse colon

- ✓ Approximately **15 inches (38 cm)** long.
- ✓ Lies **intraperitoneally**.
- ✓ **Crosses the umbilical region.**
- ✓ **Begins at the right colic (hepatic) flexure**
- ✓ **Ends at the left colic (splenic) flexure**
- ✓ **Hangs downward**

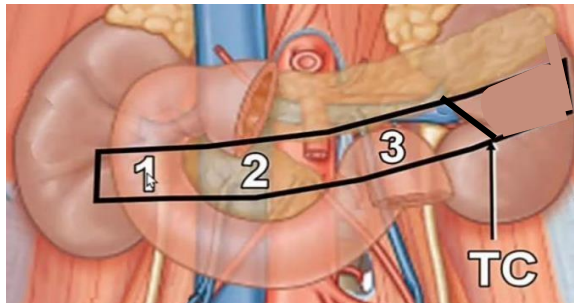


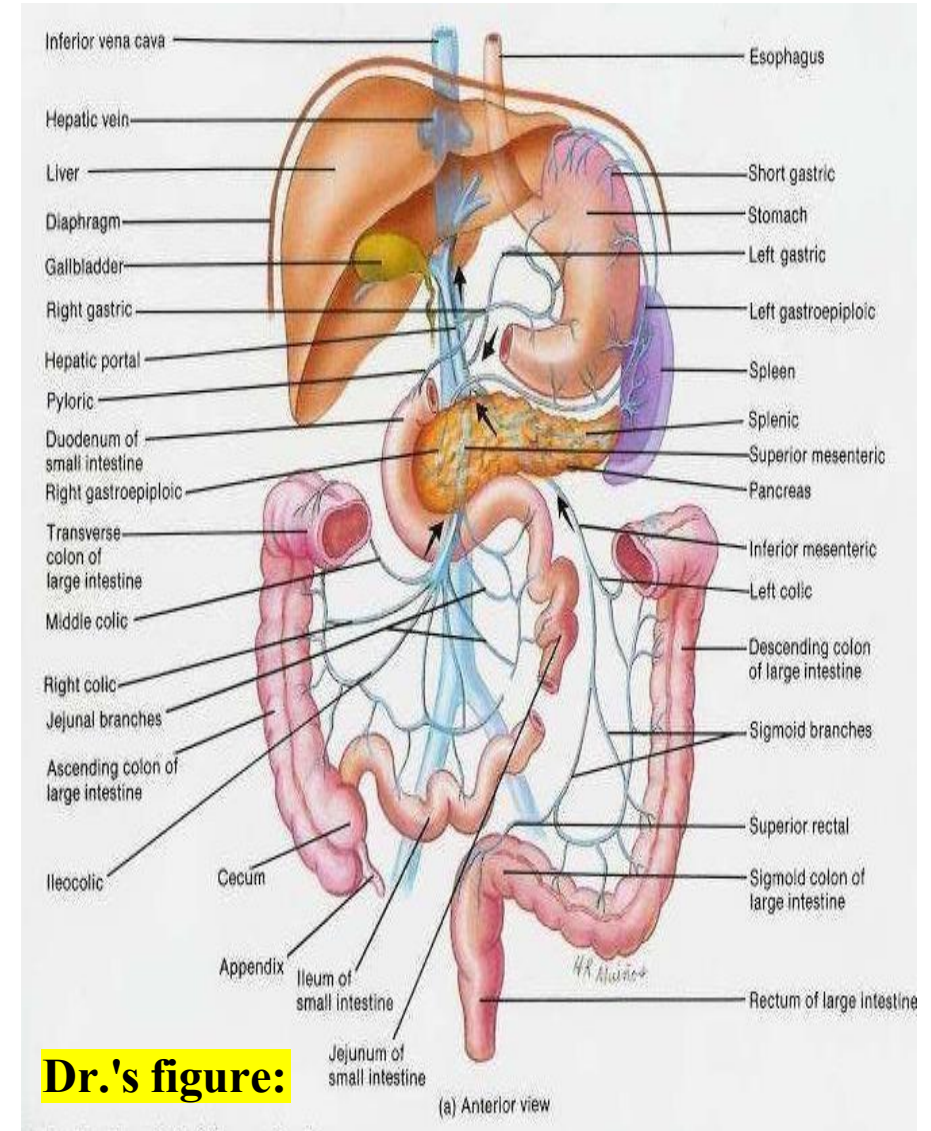
24- Transverse Mesocolon

- ✓ Transverse colon is suspended by the **transverse mesocolon** (colonic mesentery).
- ✓ The **transverse mesocolon is formed by the greater omentum**, which:
 - Descends from the **greater curvature of the stomach** as **two layers of peritoneum**.
 - Then **ascends as two separate layers**, one passing **above** and the other **below** the **transverse colon**.
 - These layers reunite to form the **transverse mesocolon**, which ultimately attaches to the **anterior border of the pancreas**.
- ✓ **The transverse mesocolon is mobile**, Its **length varies** among individuals:
 - If long, it can descend deeply downward.
 - If short, it keeps the colon positioned higher in the abdominal cavity.

**This anatomical variation affects the posterior relations of the transverse colon. If low-hanging, it may lie anterior to ileum or jejunum. If high, it lies Antero-superior to the small intestine loops.*

25- Relations of Transverse colon

| Relation | Structures |
|-------------|--|
| Anteriorly | <ol style="list-style-type: none"> 1. Greater omentum 2. Anterior abdominal wall |
| Posteriorly | <ol style="list-style-type: none"> 1. 2nd part of the duodenum 2. Head of the pancreas 3. Coils of small intestine (may become anterior due to mobility of transverse colon)  |

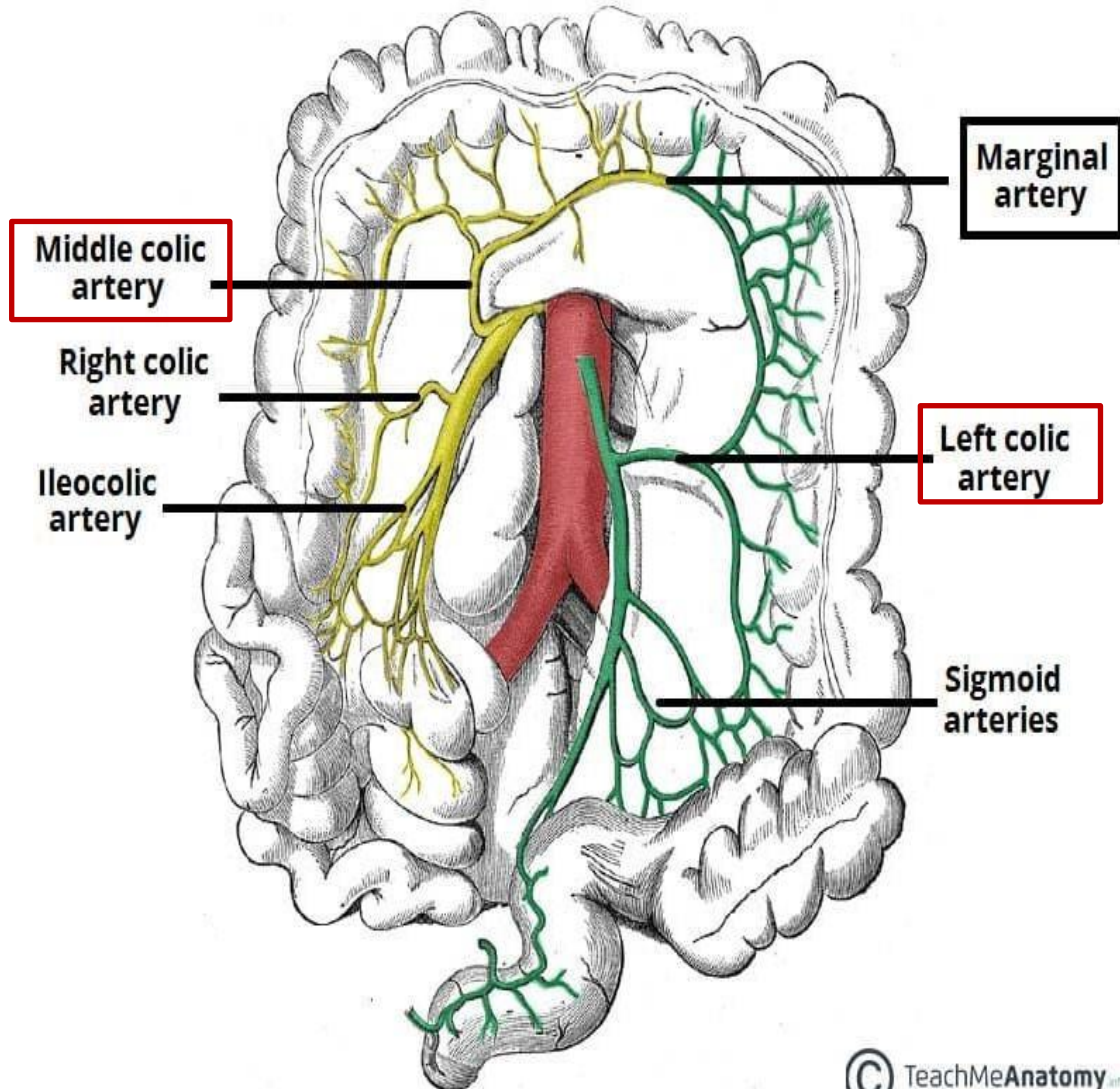


26- Transverse colon Supply

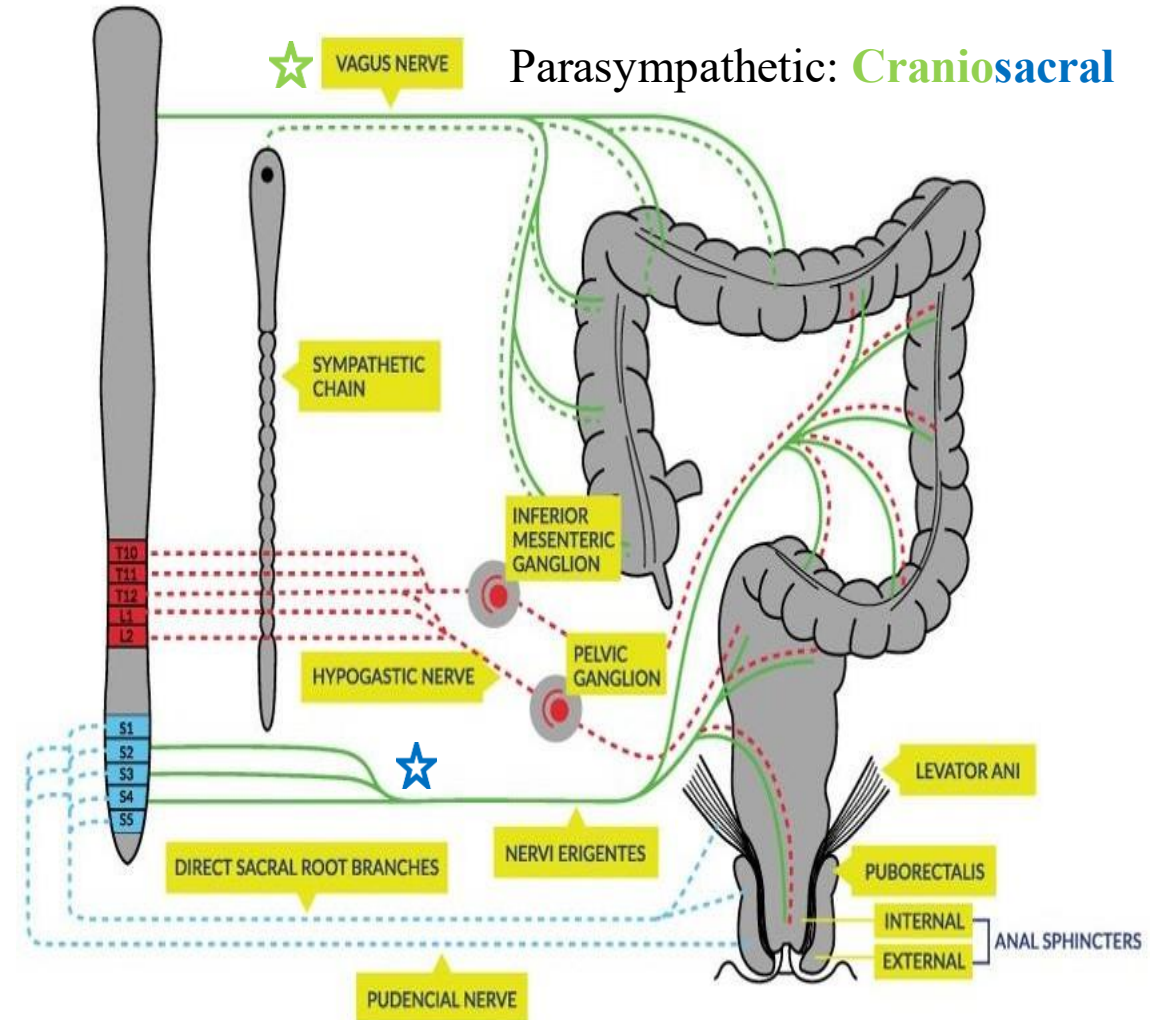
| Aspect | Proximal Two-Thirds of Transverse colon | Distal One-Third of Transverse colon + descending + sigmoid + rectum. |
|--------------------|---|---|
| Origin | Midgut | Hindgut |
| Arterial Supply | Middle colic artery branch of Superior Mesenteric Artery | Left colic artery branch of Inferior Mesenteric Artery |
| Venous Drainage | Superior mesenteric vein → Portal V. | Inferior mesenteric vein → Portal V. |
| Lymphatic Drainage | Superior mesenteric nodes | Inferior mesenteric nodes |
| Innervation | <ul style="list-style-type: none"> • Parasympathetic: Vagal nerves • Sympathetic: Superior Mesenteric ganglia (thoracic segments) <p>= Superior Mesenteric Plexus</p> | <ul style="list-style-type: none"> • Parasympathetic: S2/S3/S4 • Sympathetic: Inferior mesenteric ganglia (L1 and L2) <p>= Inferior Mesenteric Plexus</p> |

Transverse Colon Supply

Arterial Supply:



Innervation:

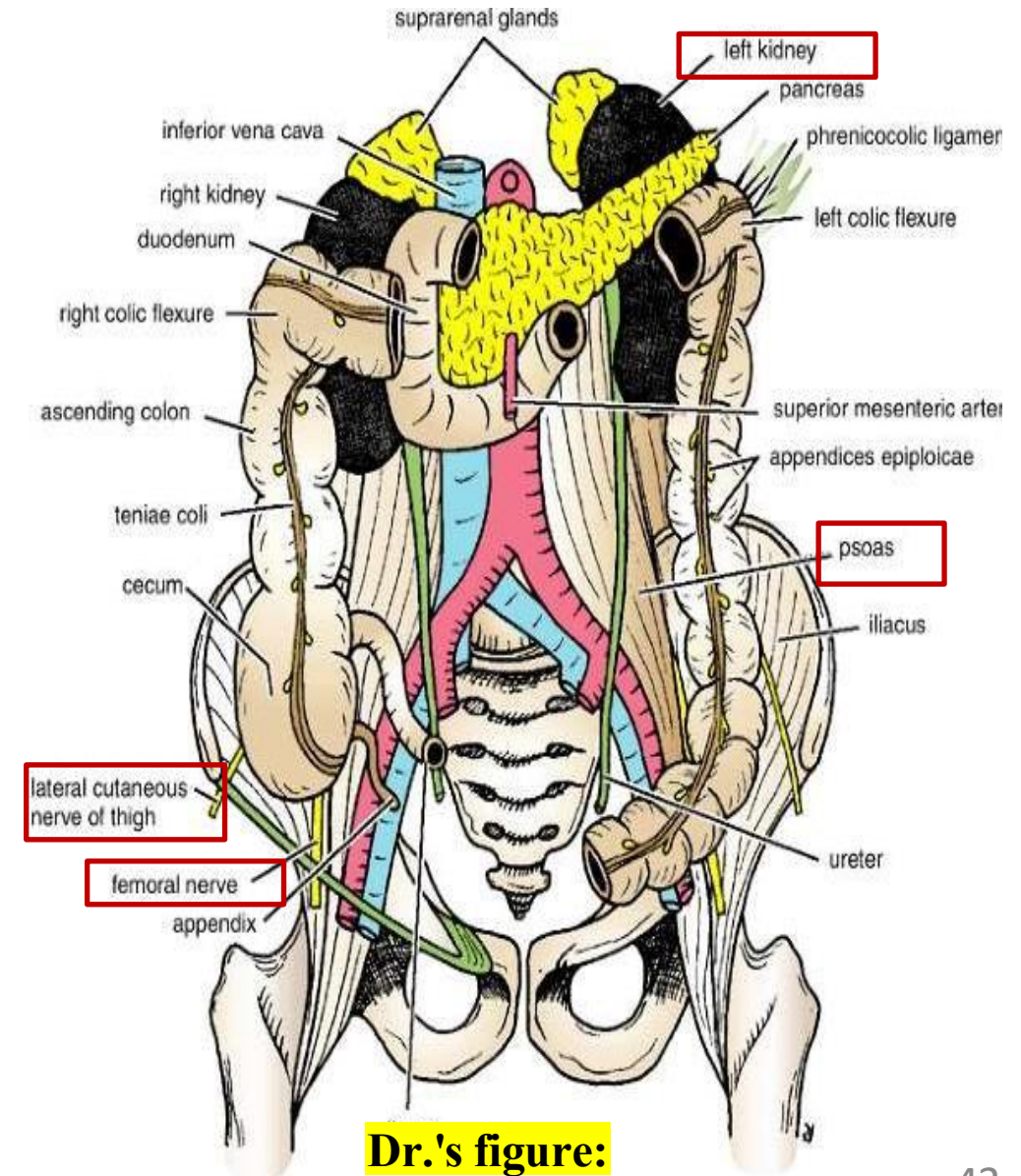


27- Descending colon

- ✓ It is Approximately **10 inches (25 cm)** long.
 - Begins at the **left colic flexure**.
 - Ends at the **pelvic brim**, where it becomes continuous with the **sigmoid colon**.
- ✓ **The peritoneum:**
 - The peritoneal covering is similar to the **ascending colon**.
 - It covers the **front and sides** of the descending colon.
 - Binds the colon to the **posterior abdominal wall**, forming **medial and lateral gutters**.

28- Descending colon relations

| Aspect | Structures Related |
|--|---|
| Anteriorly <i>(same to those in ascending colon)</i> | <ol style="list-style-type: none"> 1. Coils of small intestine 2. Greater omentum 3. Anterior abdominal wall |
| Posteriorly <i>(same to those in ascending colon but in addition to *)</i> | <ol style="list-style-type: none"> 1. Iliacus muscle 2. Iliac crest 3. Quadratus lumborum 4. Origin of transversus abdominis muscle 5. Iliohypogastric nerve (L1) 6. Ilioinguinal nerve (L1) 7. lateral border of the left kidney 8. left psoas 9. lateral cutaneous nerve of the thigh 10. femoral nerve |



29- Descending colon Supply

✓ Arterial Supply

Left colic artery and 1st sigmoid branch from the **inferior mesenteric artery**.

✓ Venous Drainage

The veins correspond to the arteries and drain into the **inferior mesenteric vein**, it ends in the **splenic vein**, Which then joins the SMV to form portal Vein.

✓ Lymphatic Drainage

Lymph drains into the **inferior mesenteric nodes**.

✓ Nerve Supply

- **Parasympathetic: S2/S3/S4**
- **Sympathetic: Inferior mesenteric ganglia (L1 and L2)**

= Together they form **inferior mesenteric plexus / Hypogastric plexus**.

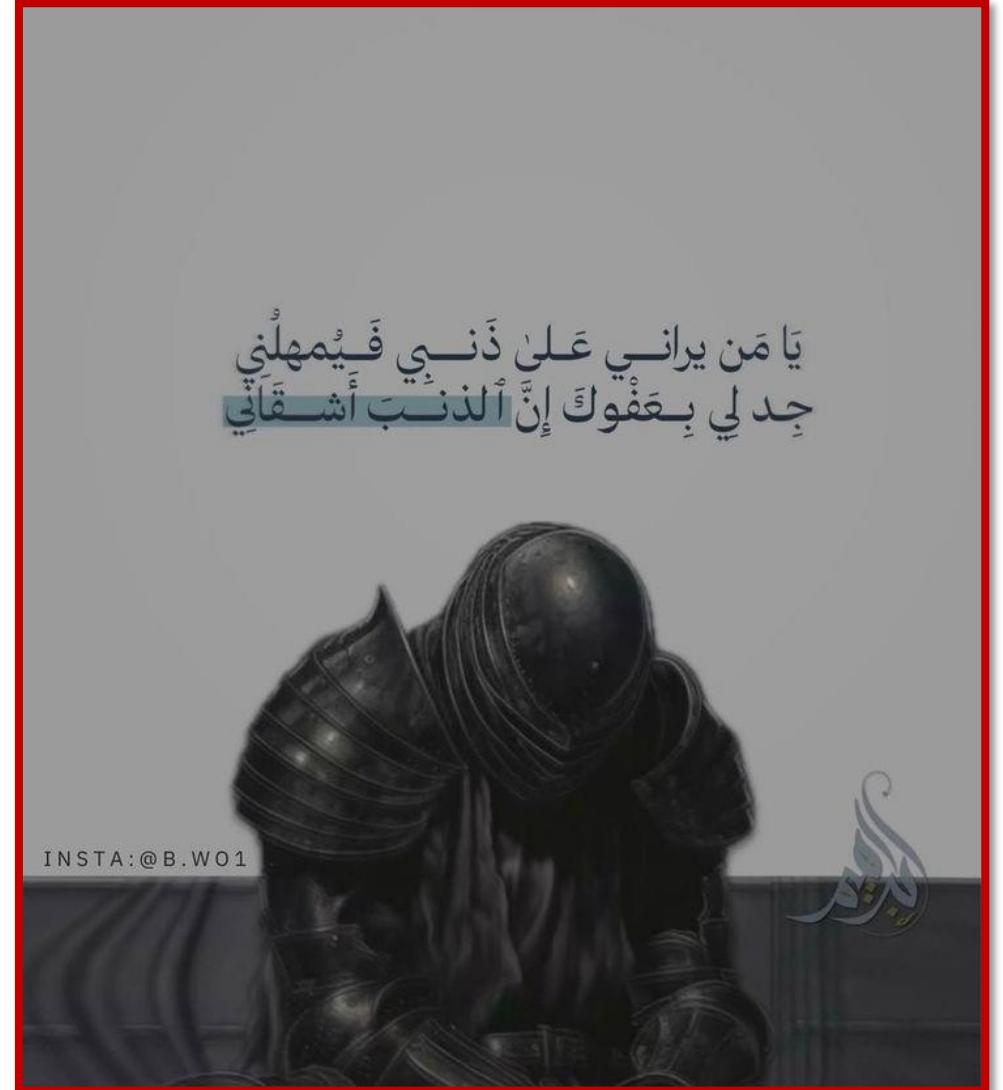Additional Resources:

رسالة من الفريق العلمي:

Watch these videos:

1. Click [here](#)

2. Click [here](#)



For any feedback, scan the code or click on it.



Corrections from previous versions:

| Versions | Slide # and Place of Error | Before Correction | After Correction |
|----------|----------------------------|-------------------|------------------|
| V0 → V1 | | | |
| V1 → V2 | | | |