

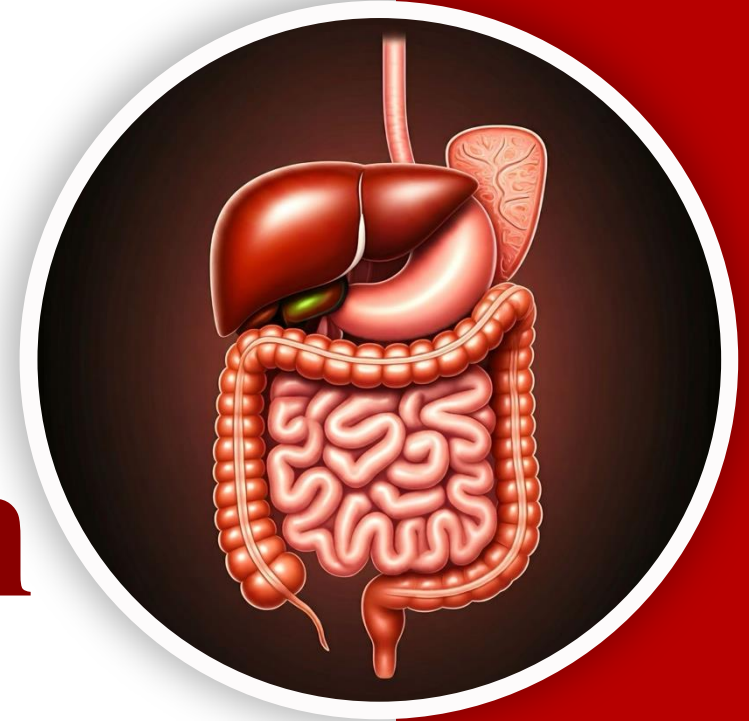
بِسْمِ اللّٰهِ الرَّحْمٰنِ الرَّحِیْمِ  
(وَفَوْقَ كُلِّ ذِي عِلْمٍ عَلِيمٌ)



جراح

GIS Anatomy | MID 5





# Abdominal wall & Rectus Sheath



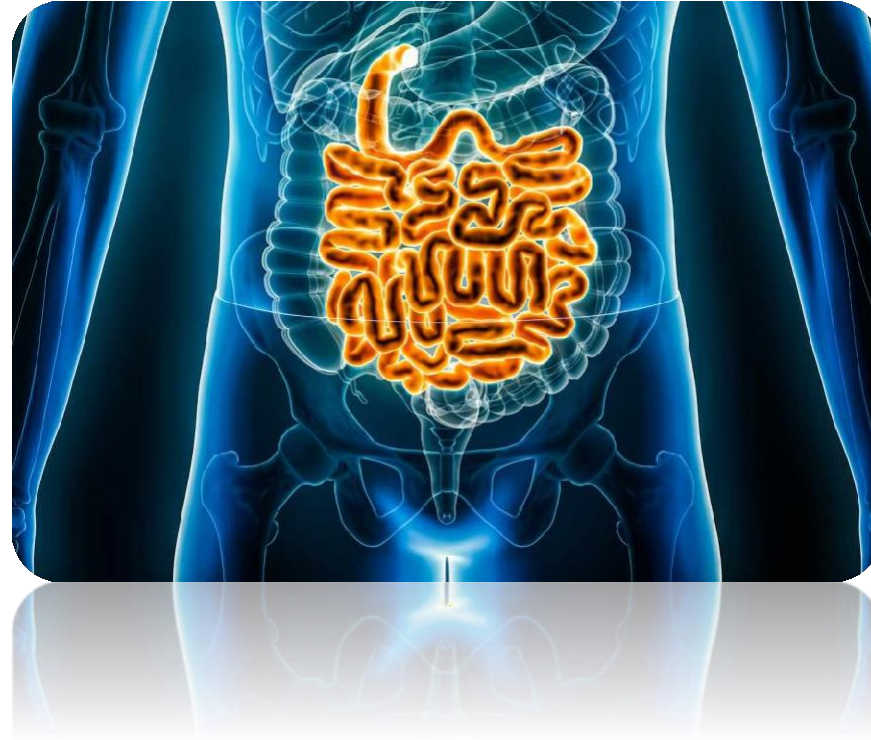Written by : DST

Reviewed by : Ibrahim Alnajjar  
Tala Othman

## **Color code of the Modified :**

-  **Doctor's words that are not in the slides.**
-  **Doctor's Slide that wasn't mentioned in the lecture (Not Required).**
-  **Extra information (Not Required).**
-  **Doctor's slide that was mentioned in the Lecture.**

# Quiz on the previous lecture.



# Abdominal wall

- The abdominal wall plays a crucial role in medical procedures. Through palpation, a physician can assess which organ may be affected and determine its approximate location. Also, most open surgeries are through the anterior abdominal wall; my advice? Study this system well as it's really important now and along our long years of practice.
- The abdominal wall is divided into;
  - **Anterior abdominal wall.** (will be addressed this lecture)
  - **Posterior Abdominal wall.** (will be discussed later)



# Borders of the Abdomen

- The abdomen is the region of the trunk located between the diaphragm above and the pelvic inlet below; it is separated superiorly from the thoracic cavity by the diaphragm and connected inferiorly to the pelvis.

## Borders:

- Superior:

- 1 Xiphoid process ( at the lower part of sternum) → located to the midline of the body.
- 2 Lower 6 Costal cartilages (7-12) → at the lateral sides.

- Inferior:

Pubic bone and iliac crest( upper border of the hip bone ): at the level of L4.

- Umbilicus:

Level of IV disc L3-L4

# Abdominal Quadrants

Formed by two intersecting lines:

(1) Vertical (**perpendicular**)

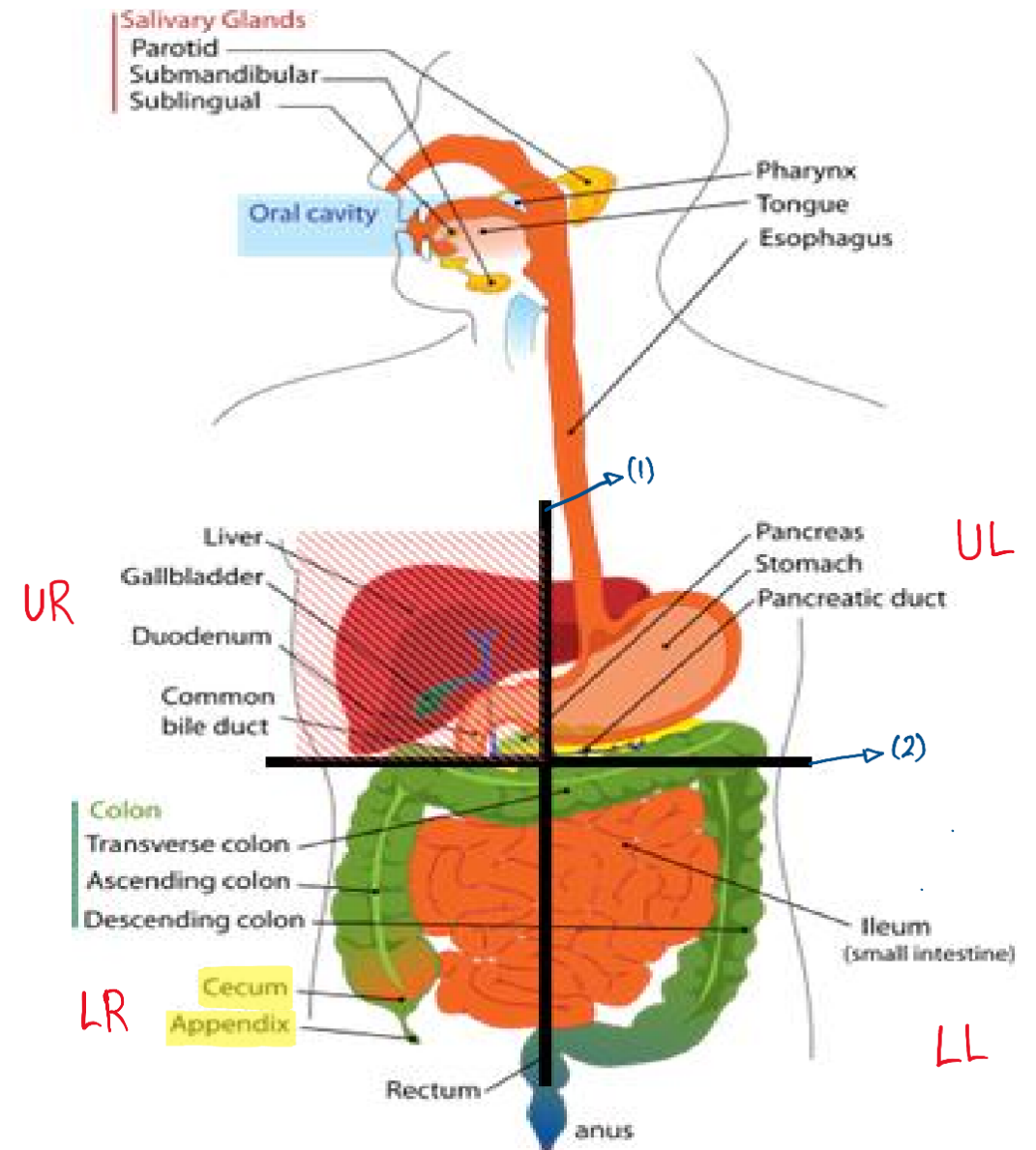
(2) Horizontal (**transverse**)

Intersect at umbilicus.

## Quadrants:

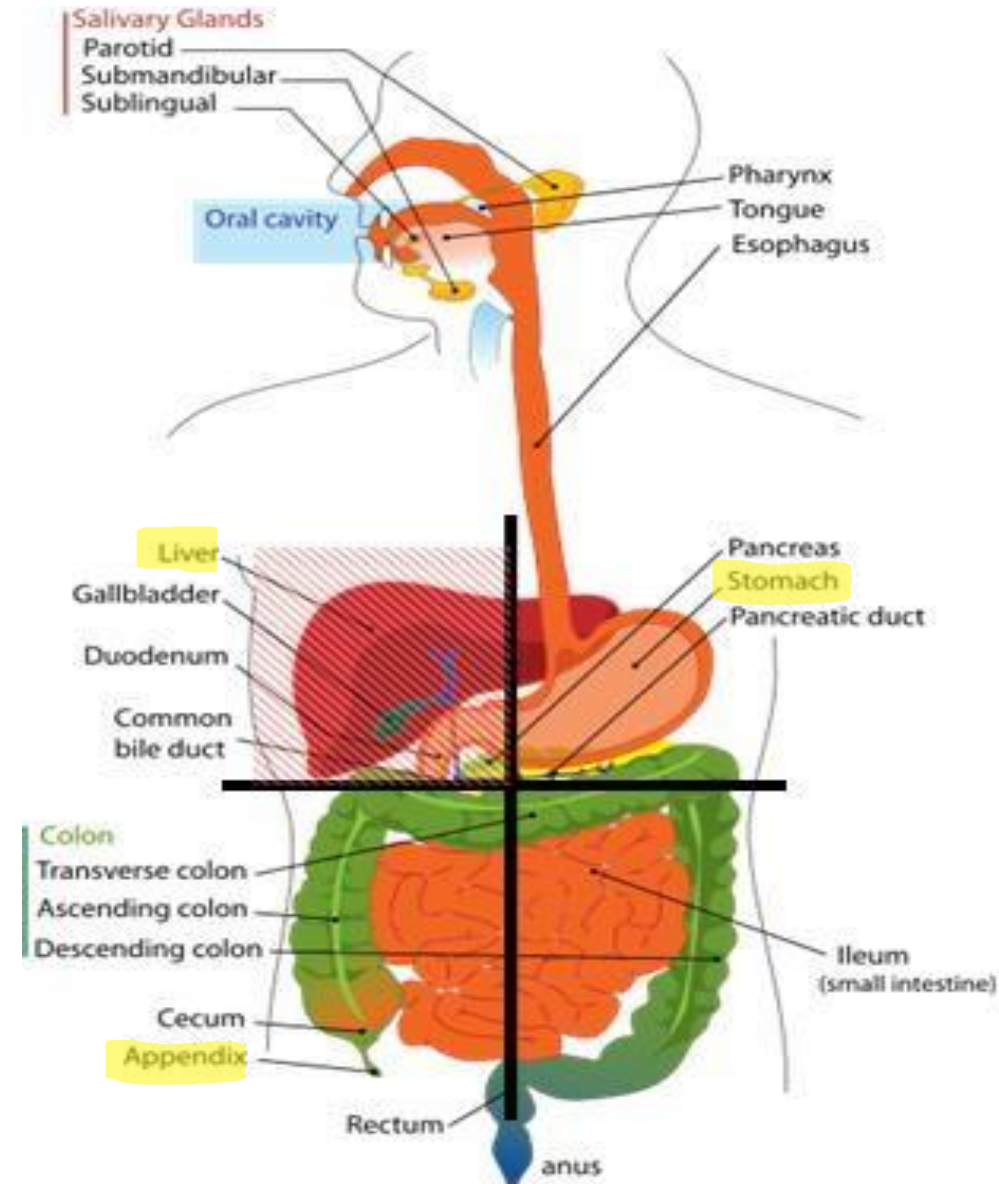
- Upper left, **UL**.
- Upper right, **UR**.
- Lower left, **LL**.
- Lower right, **LR**.

➤ This division was previously used, now it's replaced by 9 abdominal regions.



# Abdominal Quadrants - Clinical correlation

- The appendix is located in the lower right quadrant, so patients with appendicitis they present with severe pain in their LR quadrant.
- The liver is located in the upper right quadrant, so conditions causing damage to the liver (ex. Cirrhosis) produce pain in the UR quadrant. Same for stomach (ULQ), etc.



# Abdominal Regions

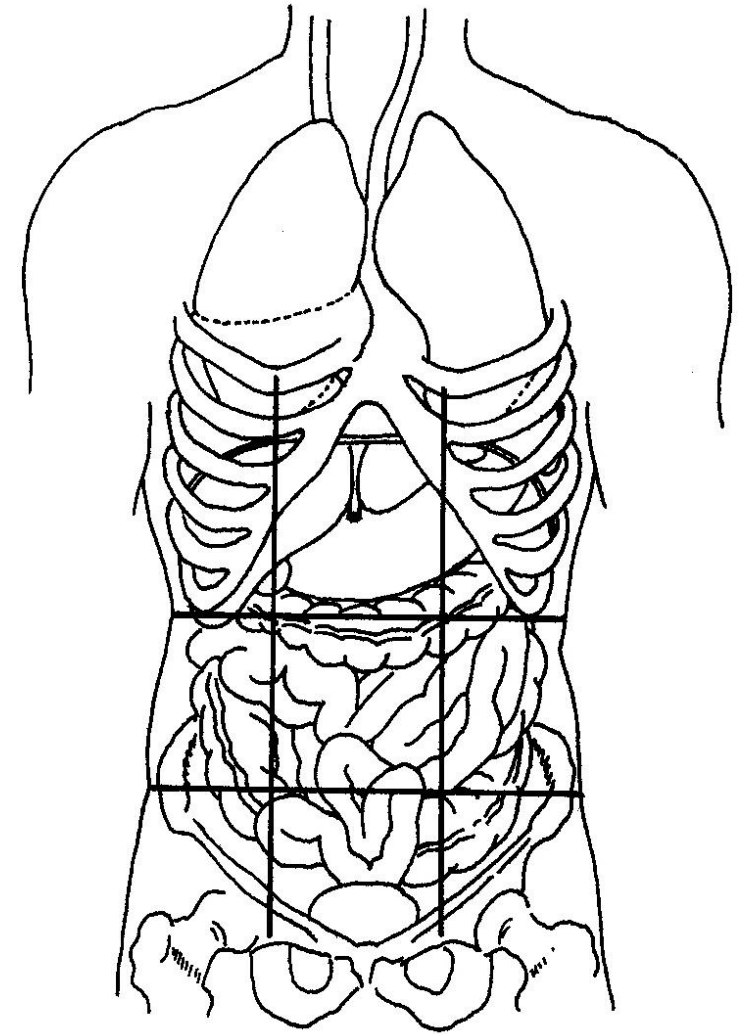
Divided into **9 regions** by two pairs (**two of each**) of planes:

## 1 Vertical Planes:

- Left and right lateral planes
- Midclavicular planes (**lines**), as the name implies passes **through the midline of the clavicle (superiorly)**.
- Inferiorly passes through the midpoint between the ant.sup.ilic spine and symphysis pubis.

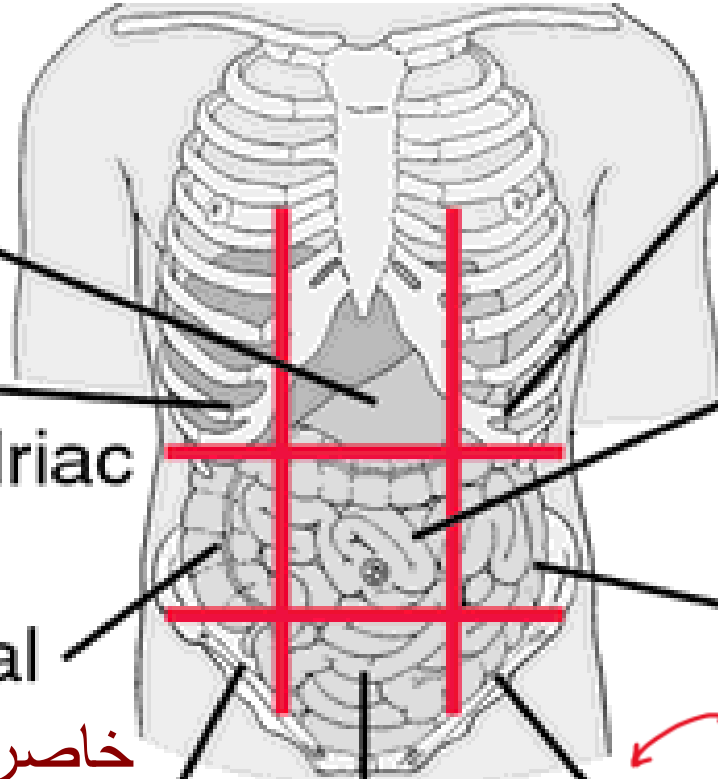
## 2- Horizontal Planes:

- **Subcostal plane**
  - At level of L3 vertebra, **below the 9th rib**.
  - Joins the lower end of costal cartilage on each side
- **Intertubercular plane:**
  - At the level of L5 vertebra
  - Through (**between**) tubercles of iliac crests **of hip bone**.



**Everything is included, but it was mentioned that it's important to know regions and what organs are in each one.**

# Names of Abdominal Regions



**Stomach**

Epigastric region

Right hypochondriac region

Right lateral (lumbar) region (flank) *خاصرة*

Right iliac (inguinal) region

Suprapubic (pelvic) (hypogastric) region

Left hypochondriac region **Spleen**

Umbilical region **Small intestine**

Left lateral (lumbar) region (flank)

Left iliac (inguinal) region **End of the descending colon & the left ovary**

Liver & gall bladder

Right kidney & Ascending colon

Left kidney & descending colon

Urinary bladder & part of male & female genital organs

Cecum, appendix & right ovary

# Abdominal regions – Notes.

- Terminology, Hypo means below (wow!)
  - Hypochondriac = below costal cartilage.
- Lumbar regions are related to the kidneys.
- ❖ Clinical correlation, again.
  - According to this division, the appendix is located in the right iliac/inguinal region, therefore if appendicitis has developed, patients present with severe pain in that region.
  - Appendicitis can develop in both sexes, but when it comes to females, **dysmenorrhea** (pain related to the menstrual cycle) should be ruled out, important to differentiate between them both.
  - Patients with renal colic, present with pain in the lumbar region (either (Rt. or Lt.) (or both, one side is more common), this pain is called renal colic pain.

# Abdominal wall divided into:-

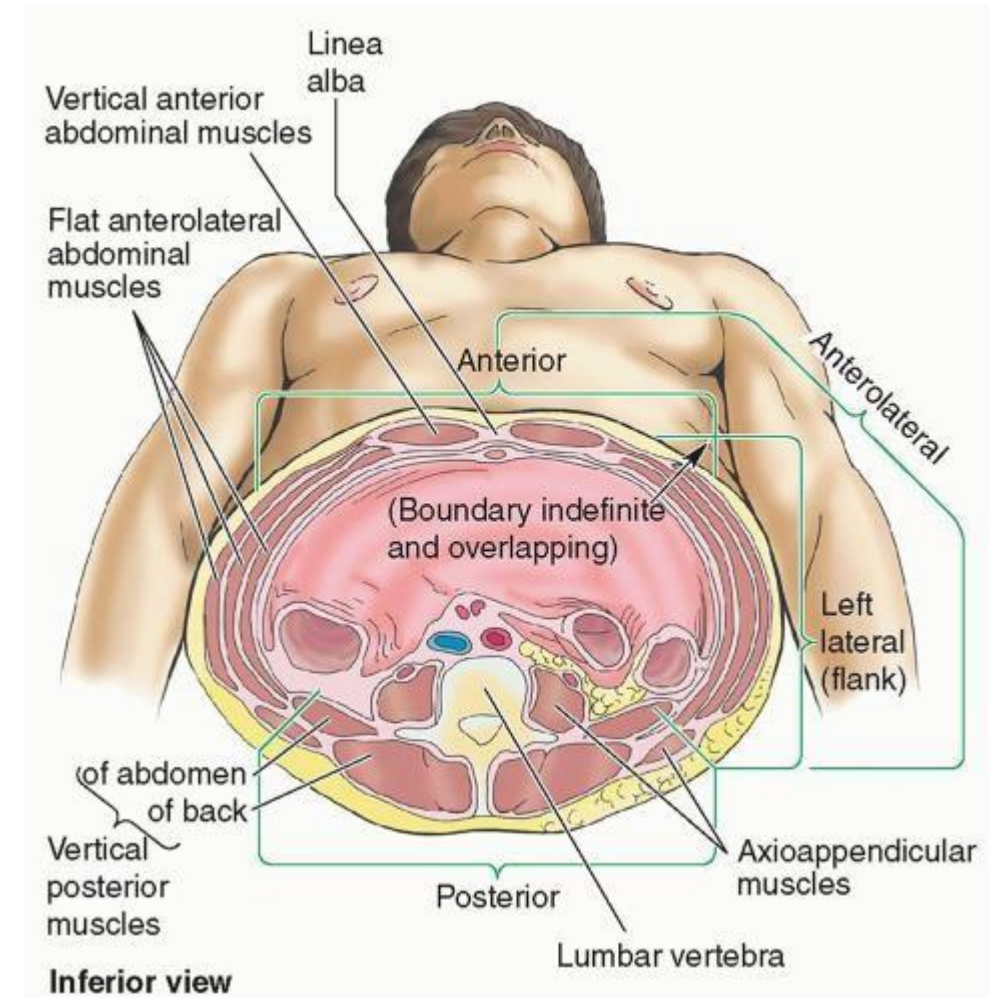


**Anterior abdominal wall**



**Posterior abdominal wall**

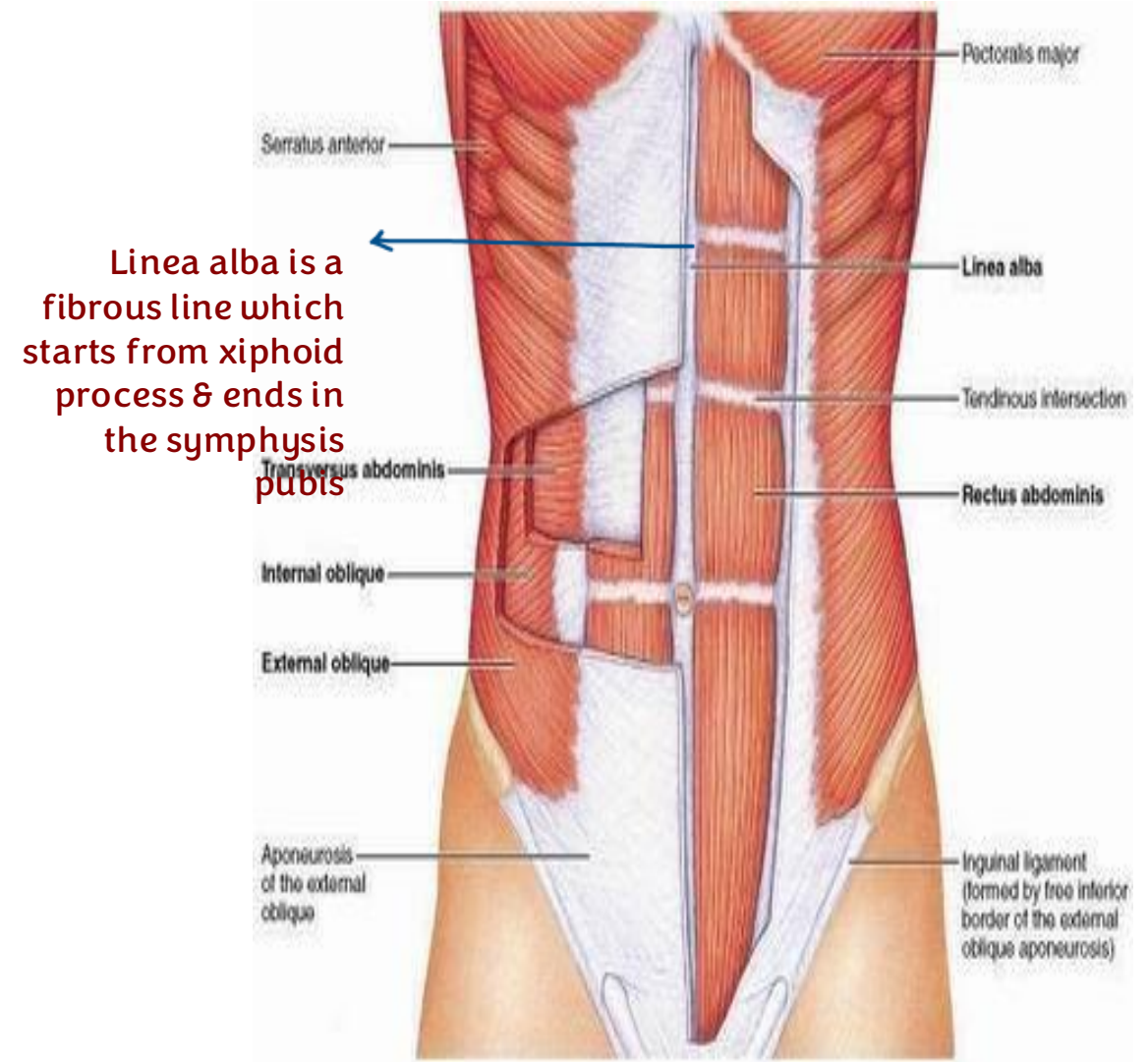
The kidney lies on the posterior abdominal wall



Extra image.

# What are the Layers of Anterior Abdominal Wall

- ✓ 1. Skin
- ✓ 2. Superficial Fascia
  - Above the umbilicus one layer → **Camper's fascia**
  - Below the umbilicus two layers
    - Camper's fascia - fatty superficial layer.
    - Scarp's fascia - deep membranous layer.
- ✓ 3. Deep fascia :
  - Thin layer of C.T covering the muscle, may be absent.
- ✓ 4. Muscular layer
  - External oblique muscle
  - Internal oblique muscle
  - Transverse abdominal muscle
- ✓ 5. Transversalis fascia
- ✓ 6. Extraperitoneal fascia
- ✓ 7. Parietal Peritoneum



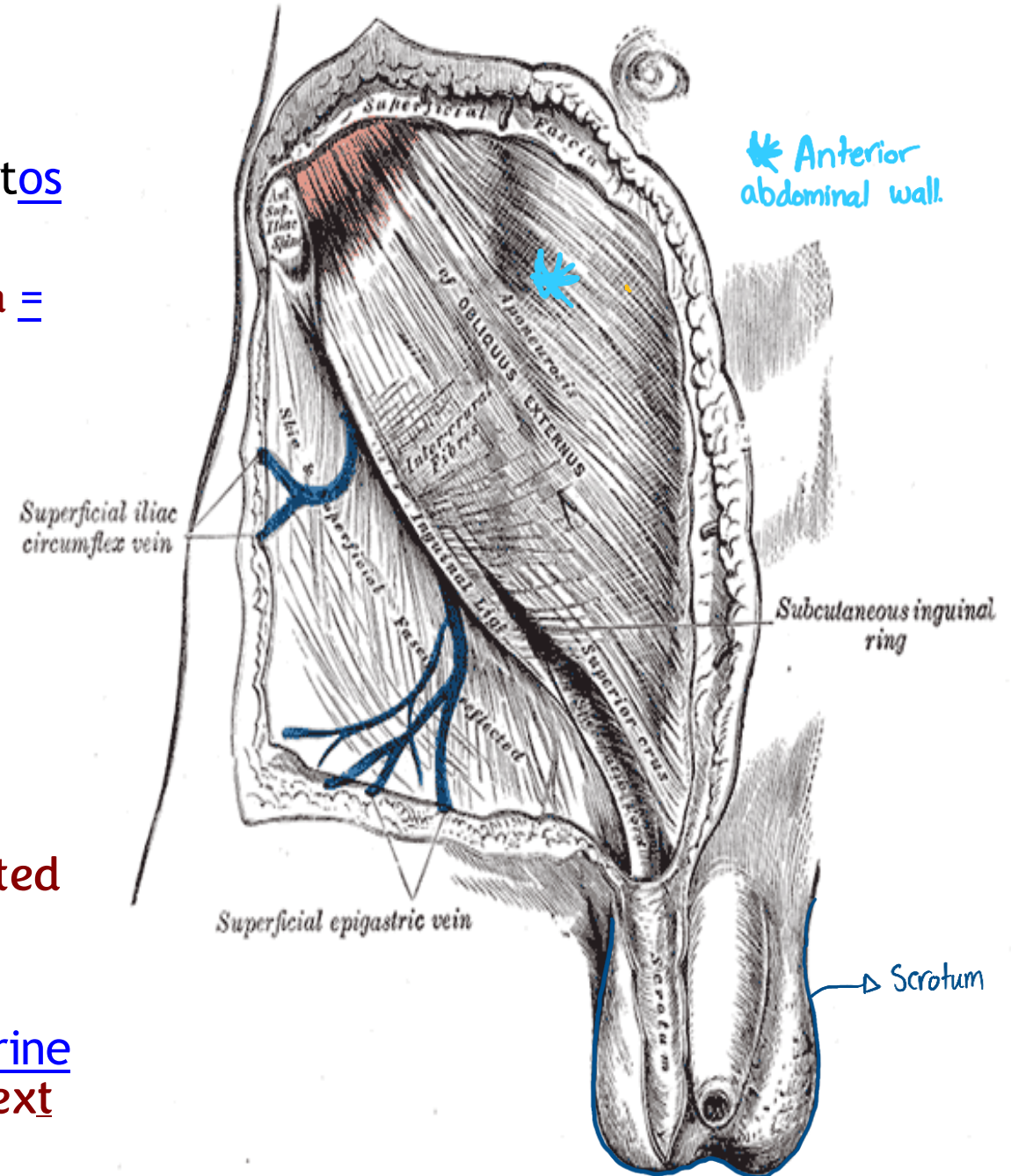
The white regions indicate CT or Aponeurosis.

# Anterior Abdominal Wall – Layers.

- Most superficial lies the (1)skin, then (2a)camper's fascia, deep to it lies the (2b)scarpa's fascia. Beneath the superficial fascia is the (3)deep fascia that is absent in females, to accommodate for the enlargement of the uterus during pregnancy, while in males it's composed of a thin layer of CT. As known, deep fascia surrounds (4)muscles (see slides 13 and 14), deep to these muscles is the (5)transversalis fascia, recall in the lower limb: where it forms the anterior layer of the femoral sheath, followed by (6)extraperitoneal fascia/fat. Finally, (7)parietal peritoneum forms the deepest layer.
- The parietal peritoneum is like a balloon lining the abdominal cavity. It has significant medical and surgical importance because, to access intraperitoneal organs (ex. stomach), this layer must be incised during surgery.

# Superficial Fascia

- Camper's fascia - fatty layer, **around scrotum** = dartos muscle in male.
- Scarpa's fascia - membranous layer, **around scrotum** = Colle's fascia
- **Attachment of Scarpa's fascia (membranous fascia) (surrounds the penis & scrotum):**
  - INF: Fascia lata, **extends for 4cm below the inguinal ligament.**
  - Function of the attachment: to close the space above the membranous layer.**
  - Sides: Pubic arch**
  - Post: Perineal body, mass of fibrous tissue located in the perineum in front of anal canal.**
- Rupture of penile urethra leads to extravasations of urine into (scrotum, perineum, penis & abdomen) – **see next slide.**



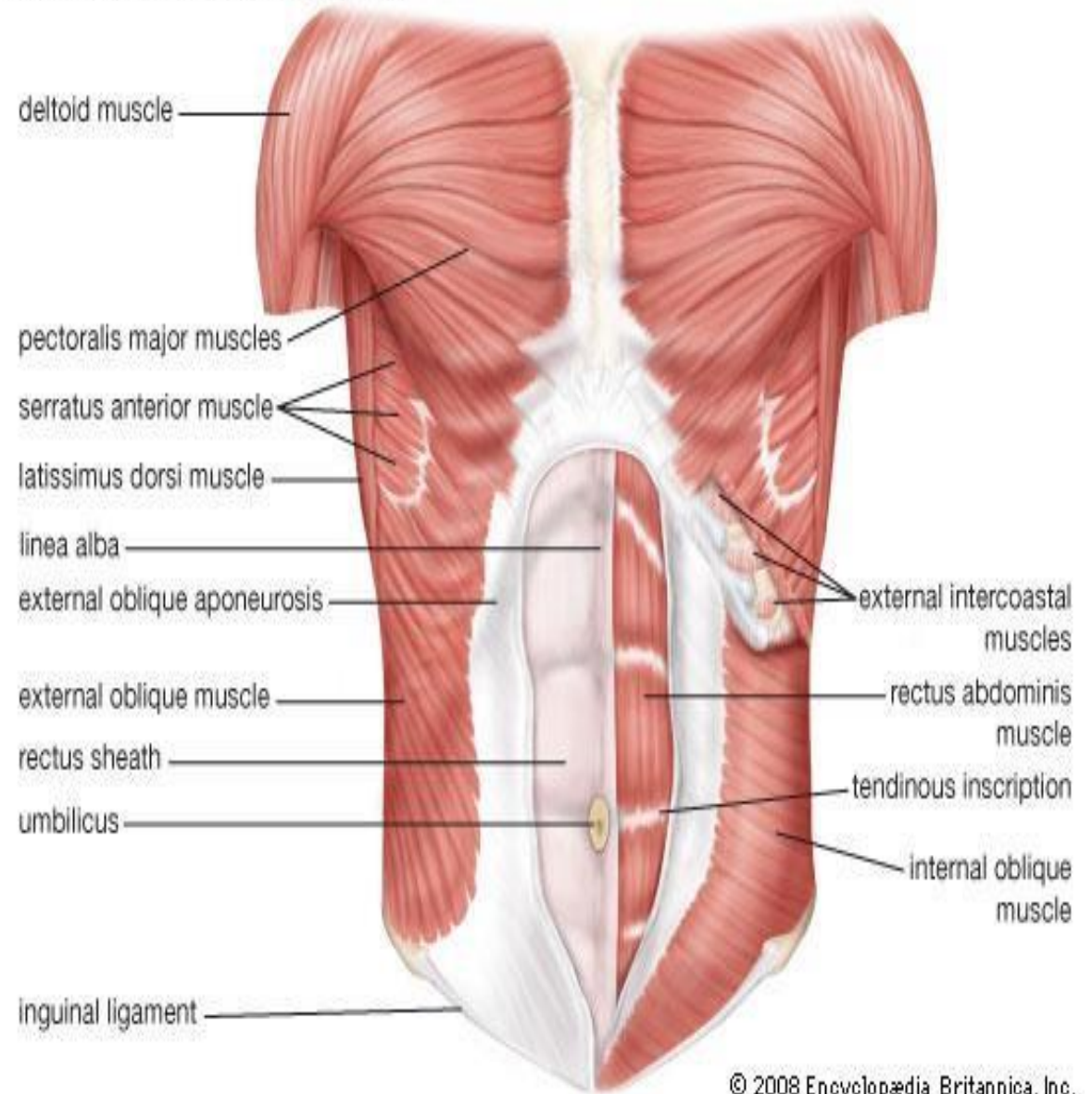
# Clinical issue – Rupture of Penile Urethra.

- If penile urethra got ruptured, urine goes deep to the membranous layer, reaching:
  - The umbilicus in the abdomen, as this layer starts below the umbilicus.
  - Fascia lata in the thigh(2 fingers below the inguinal ligament), if there's no fascia lata urine will reach low in the lower limb, therefore, the presence of fascia lata confines urine to the upper part of the thigh.
  - Around the scrotum and the penis reaching the perineal body posteriorly & the 2 pubic archs laterally .

## ✓ Muscles

- Rectus abdominis
- External oblique muscle
- Internal oblique muscle
- Transverse abdominal muscle

Muscles of the abdominal wall



# Anterior Abdominal Wall – Muscles (pt.1)

- Muscles of the abdominal wall are very strong muscles, where they form a network that contribute to this feature.
- These muscles originate as fleshy fibers and terminate as connective tissue (aponeurosis).
- These muscles insert, and contribute to the formation of, Linea alba.
  - A fibrous, midline structure extending from the xiphoid process down to symphysis pubis (where the 2 hip bones meet) passing the umbilicus.
- Fibers of external oblique are going downward, forward and medially, while those of internal oblique are upward, forward and medially.
- Fibers of transversus abdominis are transverse.

# Anterior Abdominal Wall – Muscles (pt.2)

- Rectus abdominis is adjacent to Linea alba, its lateral edge is called Linea semilunaris. This muscle appears segmented into squares by tendinous intersections (fibrous lines) - (This is the muscle of six packs).
- This segmented organization originates from the embryonic myotomes, where the rectus abdominis initially develops in segments separated by fibrous tissue.
- The aponeuroses of the lateral 3 muscles, form the rectus sheath.
- The rectus sheath splits into anterior and posterior walls to surround the rectus abdominis muscle.

# External oblique muscle Broad & thin

## Direction:

Downward forward medially

## ✓ Origin

outer surface of lower 8 ribs.

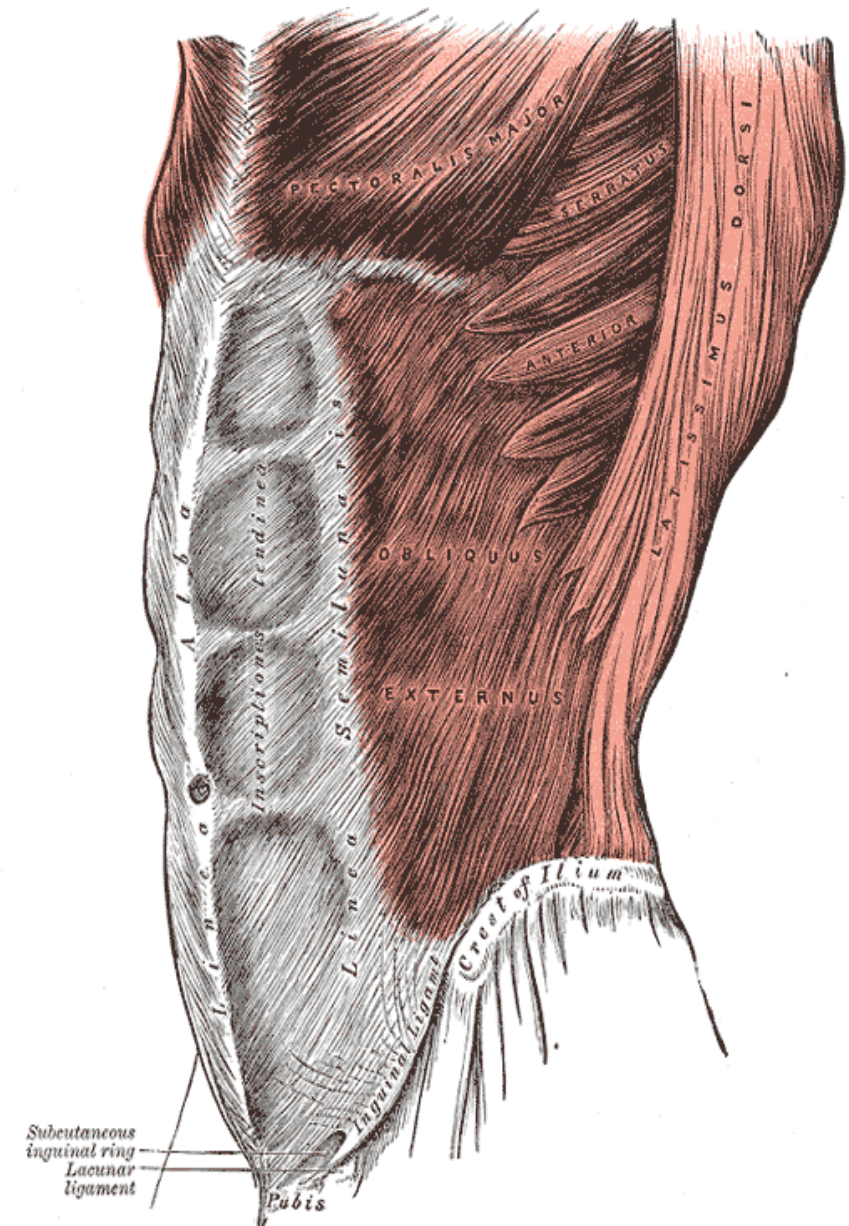
## ✓ Insertion

Xiphoid process, **symphysis pubis**, Linea alba, pubic crest, pubic tubercle, iliac crest (ant. Half).

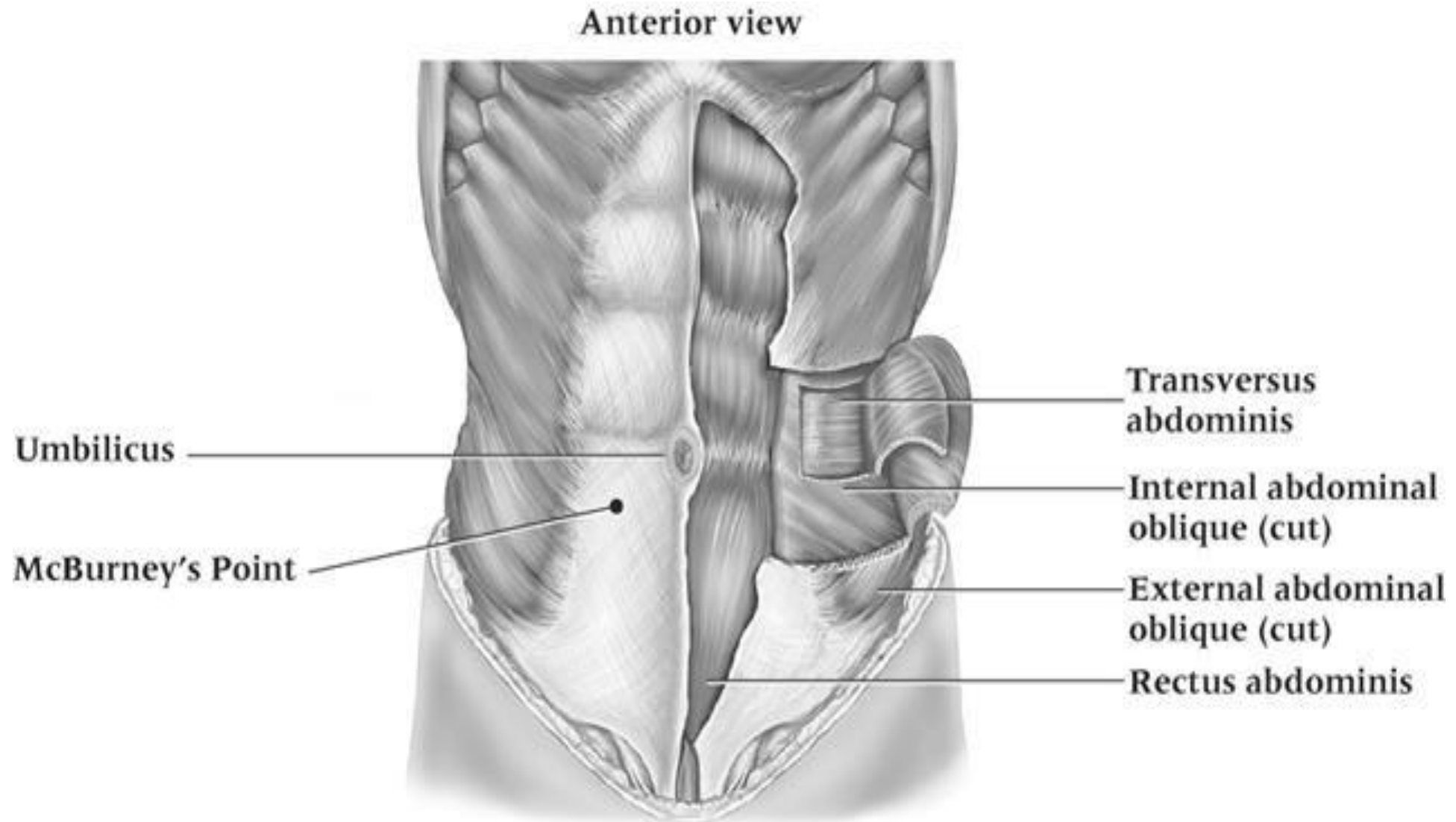
## ✓ Nerve Supply

- 1- Lower 6<sup>th</sup> thoracic nerves (or lower 6th intercostal nerves)(they enter the abdominal wall & run between the internal oblique & transversus abdominis muscles , then pierces the rectus sheath to supply the anterior abdominal wall )
- 2- L1(1st lumbar spinal nerve)( a)iliohypogastric n.,  
b)ilioinguinal n.)

- There are 12 thoracic nerves, also named thoracic spinal nerves.
  - Lower 6 supply all the muscles of the abdominal wall.
- L1 (first lumbar spinal nerve), gives a and b.



# Muscles of the anterior abdominal wall



# Aponeurosis of external oblique muscle (its insertion) :

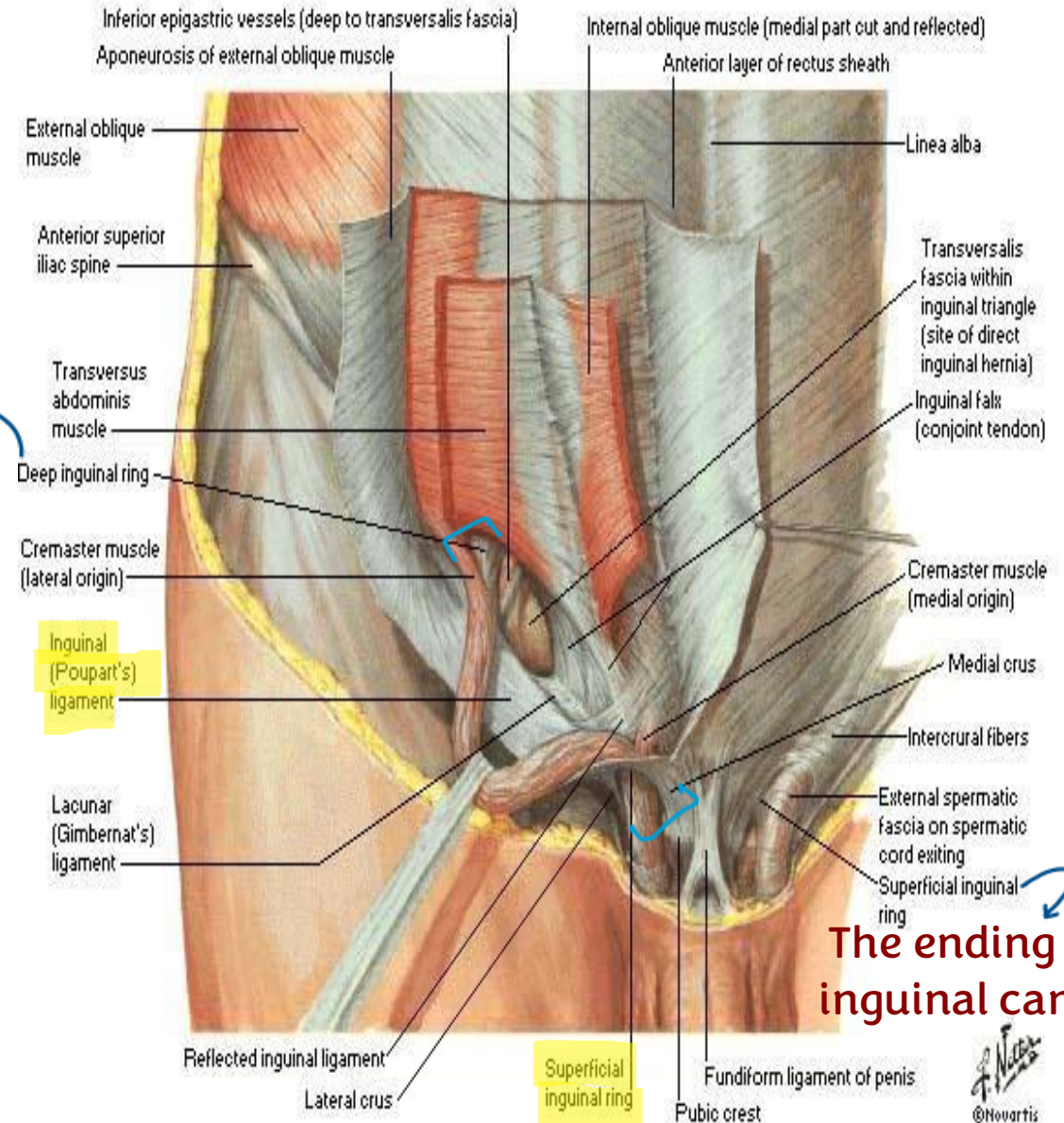
- It forms the following:

- Superficial inguinal ring
- Inguinal ligament.
- Lacunar ligament. (1)
- Pectineal ligament. (2)
- Boundaries of inguinal canal ( anterior wall ) (3).

- Formation of rectus sheath. (by all three muscles)( Ext oblique forms the ant wall of the rectus sheath)

1. Lacunar ligament:
  - a. Present at the medial edge of femoral ring
  - b. Part of the inguinal ligament
  - c. attached to the pubic ramus and pectineal line
2. Attached to pectineal line of pubis.
3. Passes through it the spermatic cord.

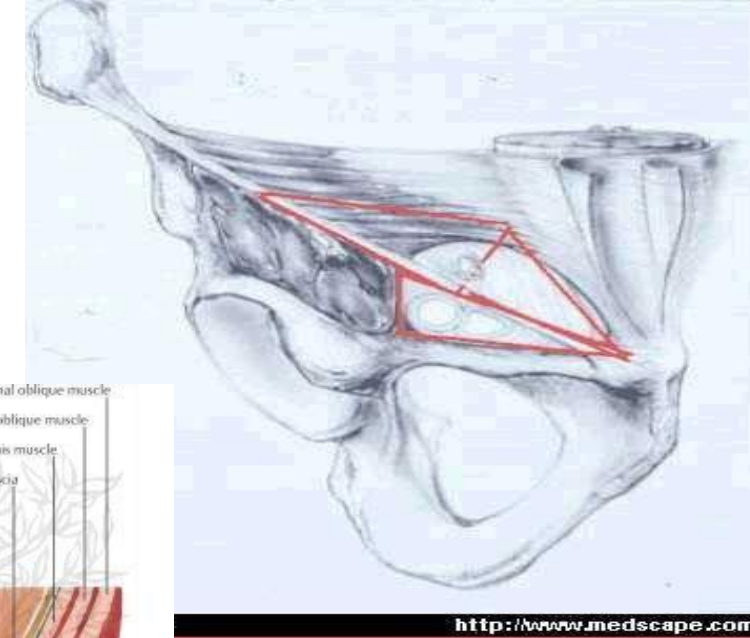
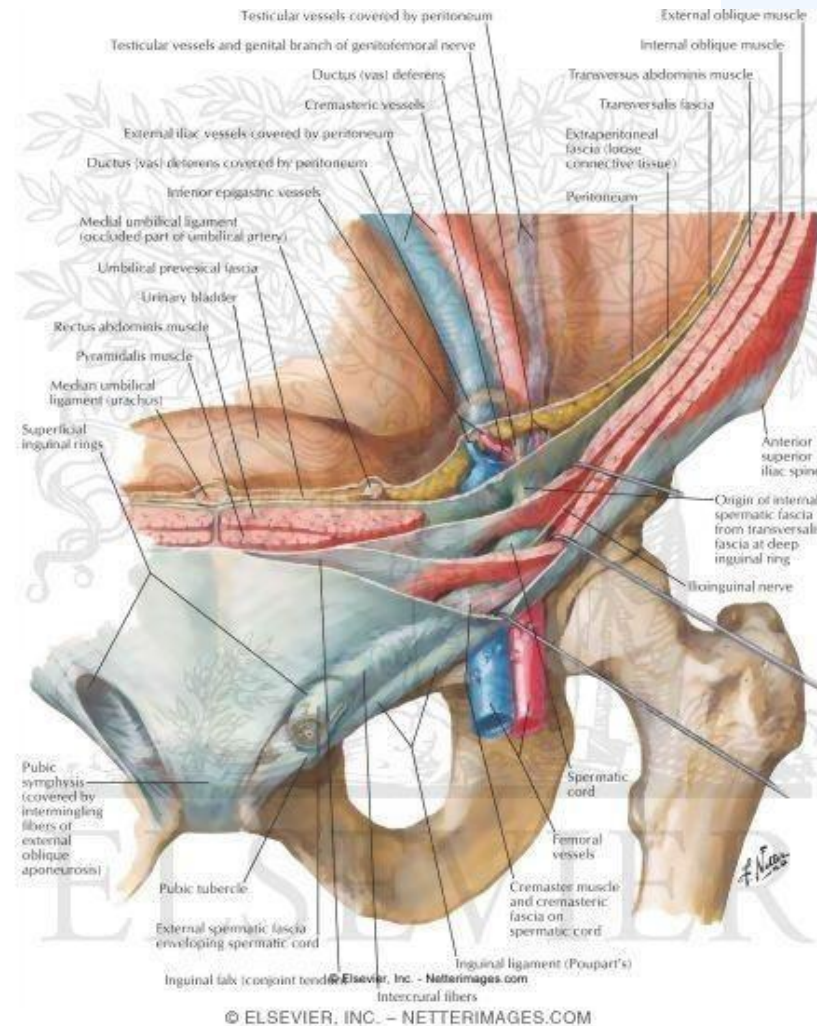
The beginning of inguinal canal



The ending of inguinal canal

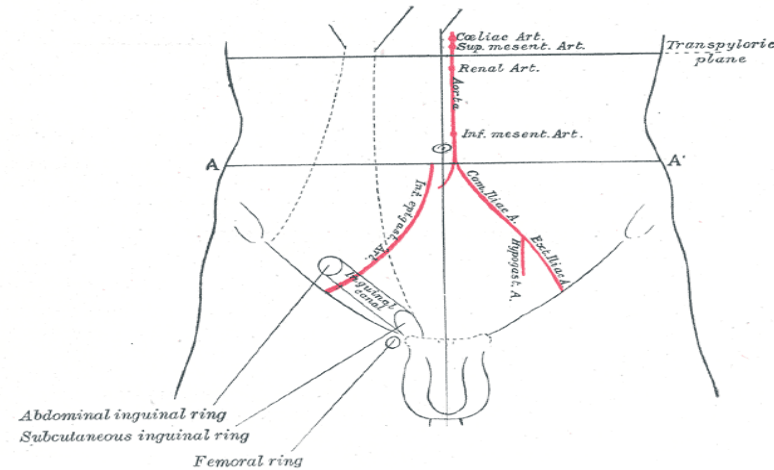
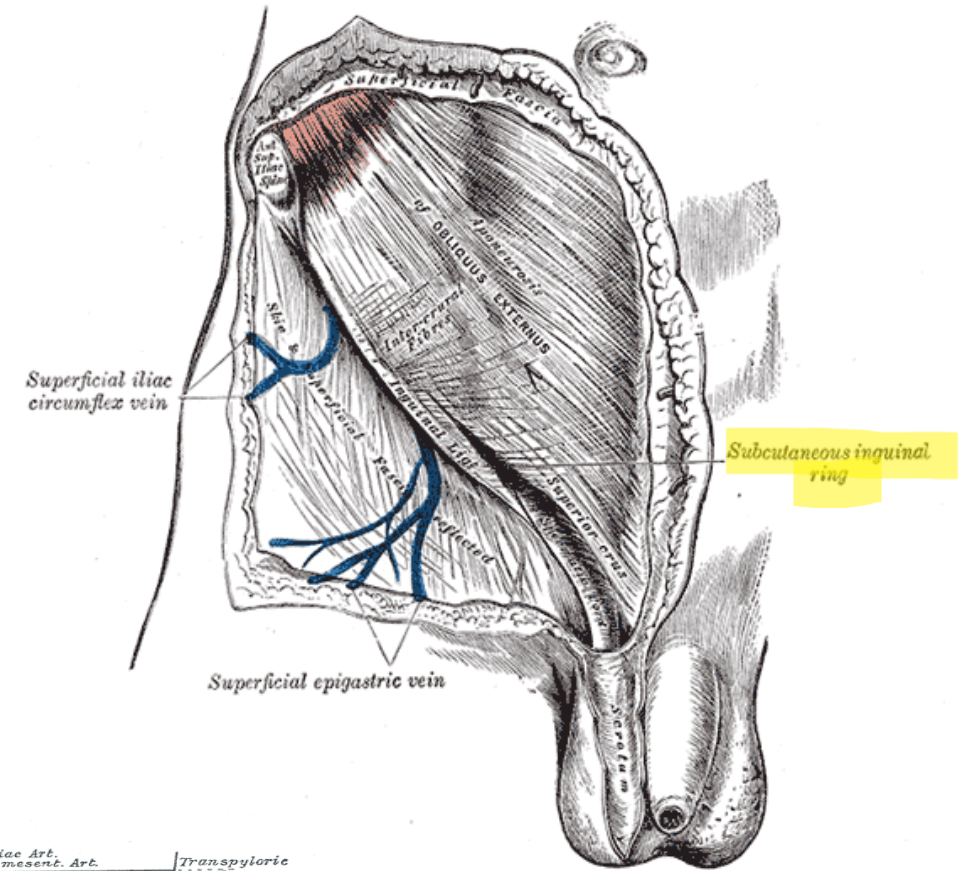
# Inguinal ligament

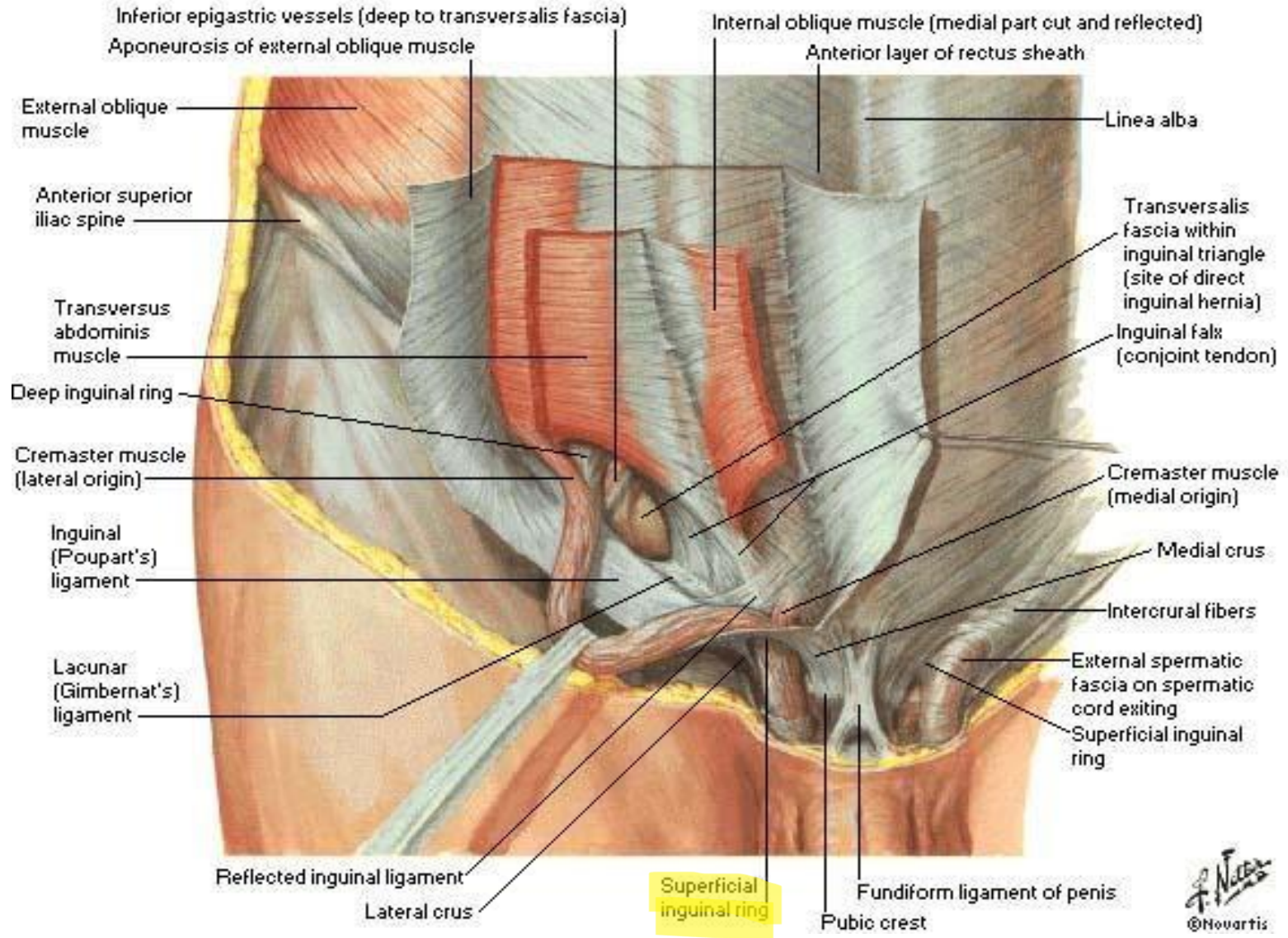
- 1 folded backward the lower border of aponeurosis of external muscle on itself.
- 2 between ant.sup.ilic spine and the pubic tubercle.



# Superficial inguinal ring.

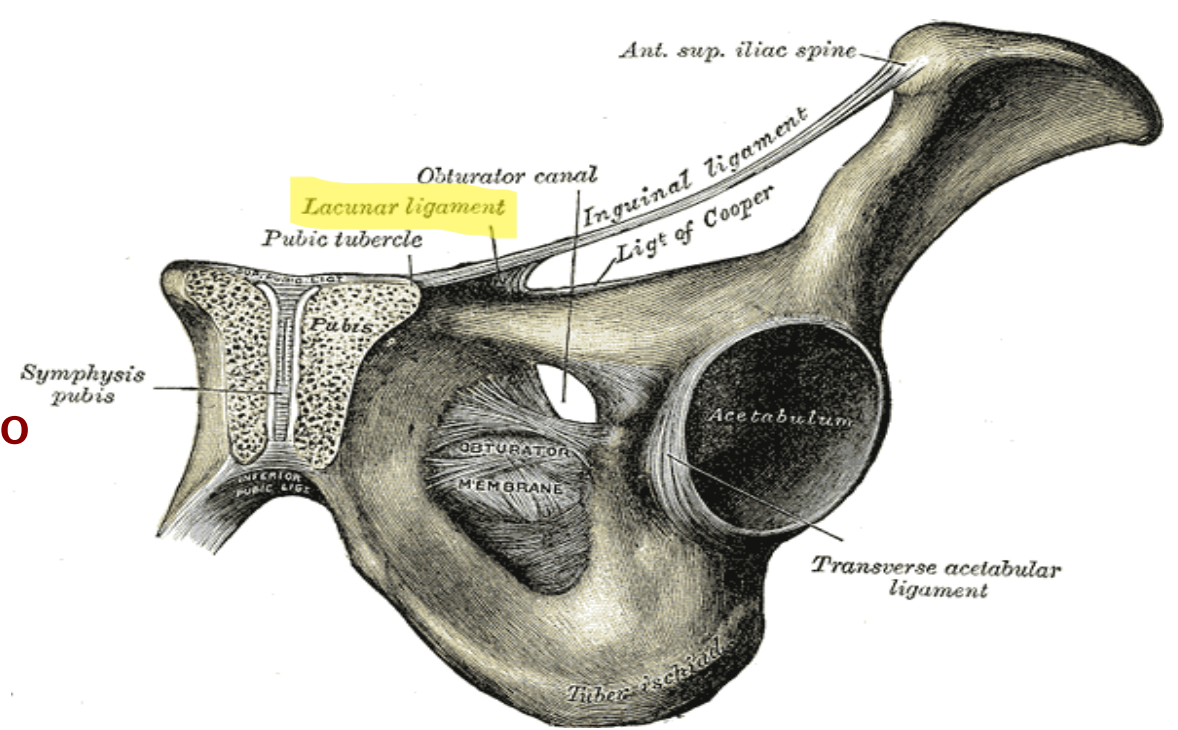
1. Triangular shape
2. Defect in external oblique aponeurosis
3. Lies immediately above and medial to the pubic tubercle
4. Opening for passing the spermatic cord, or **round ligament of uterus to the labia majora.**





# Lacunar ligament

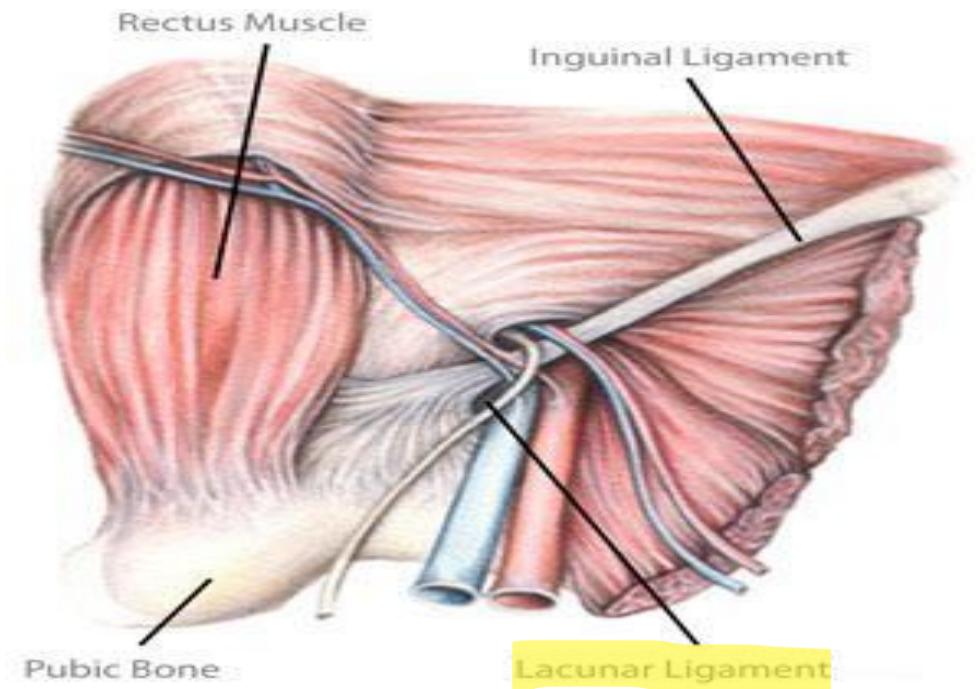
- 1 extension of aponeurosis of external muscle backward and upward to the pectineal line
- 2 **on the superior** ramus of the pubis **and attached to pectineal line**
- 3 its sharp, free crescentic edge forms the medial margin of the femoral ring
- 4 **It forms the medial boundary for the femoral canal**



---

# **Pectineal ligament** (attached to the pubic)

- 1 Continuation of the lacunar ligament at pectineal line **of the pubis part of hip bone.**
- 2 Continuation with **a thickening** of the periosteum



# Internal Oblique

## ✓ Direction:

upward forward medially **towards the linea alba**

## ✓ Origin

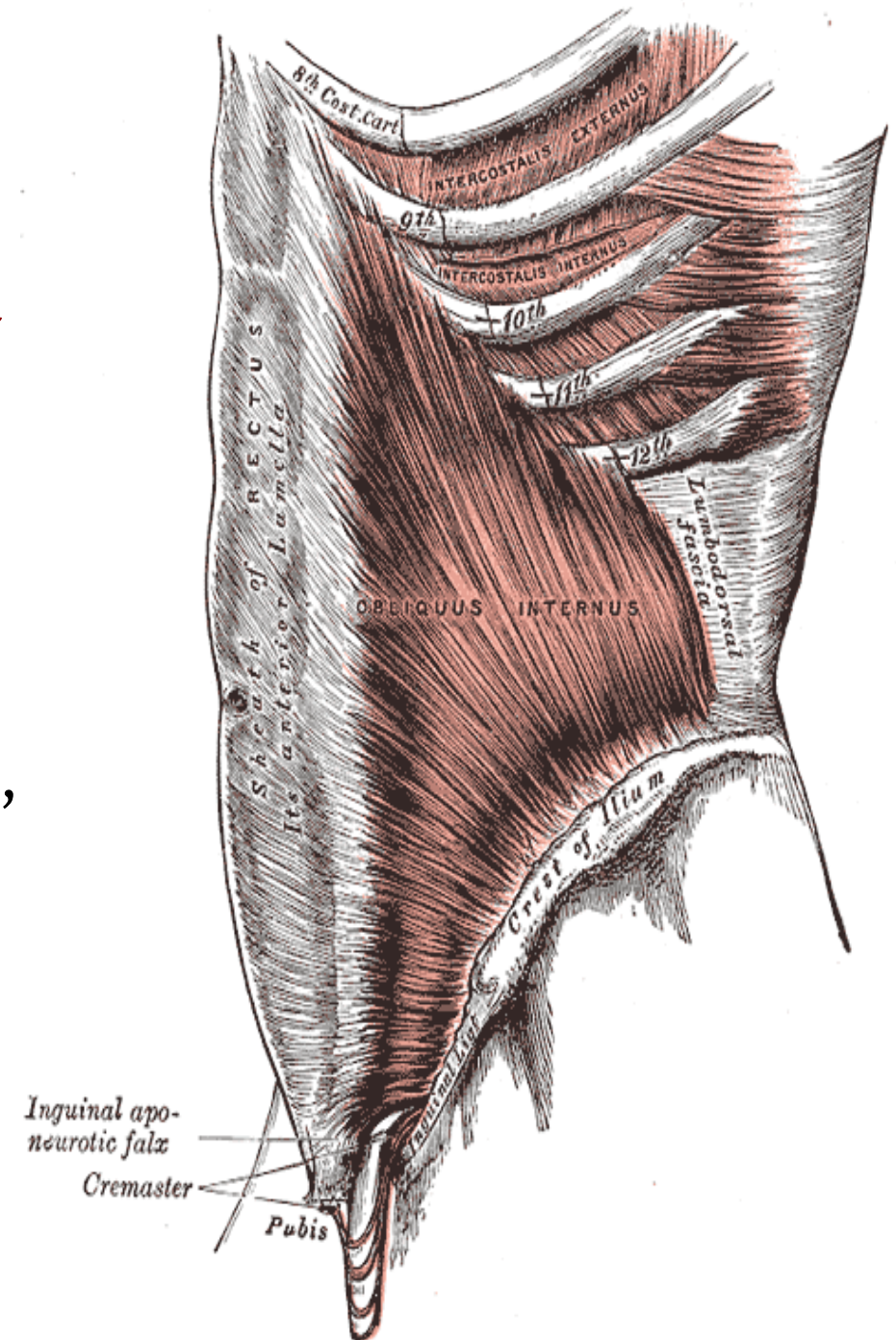
Lumbar Fascia, **Ant 2/3** iliac crest, **lateral two thirds** of inguinal ligament.

## ✓ Insertion

- Lower three ribs costal cartilage, Xiphoid process, Linea alba, symphysis pubis.

## ✓ Nerve Supply (the same as the external oblique)

Lower 6<sup>th</sup> thoracic nerves, iliohypogastric n  
C ilioinguinal n → L1.



# Internal oblique muscle - Cont.

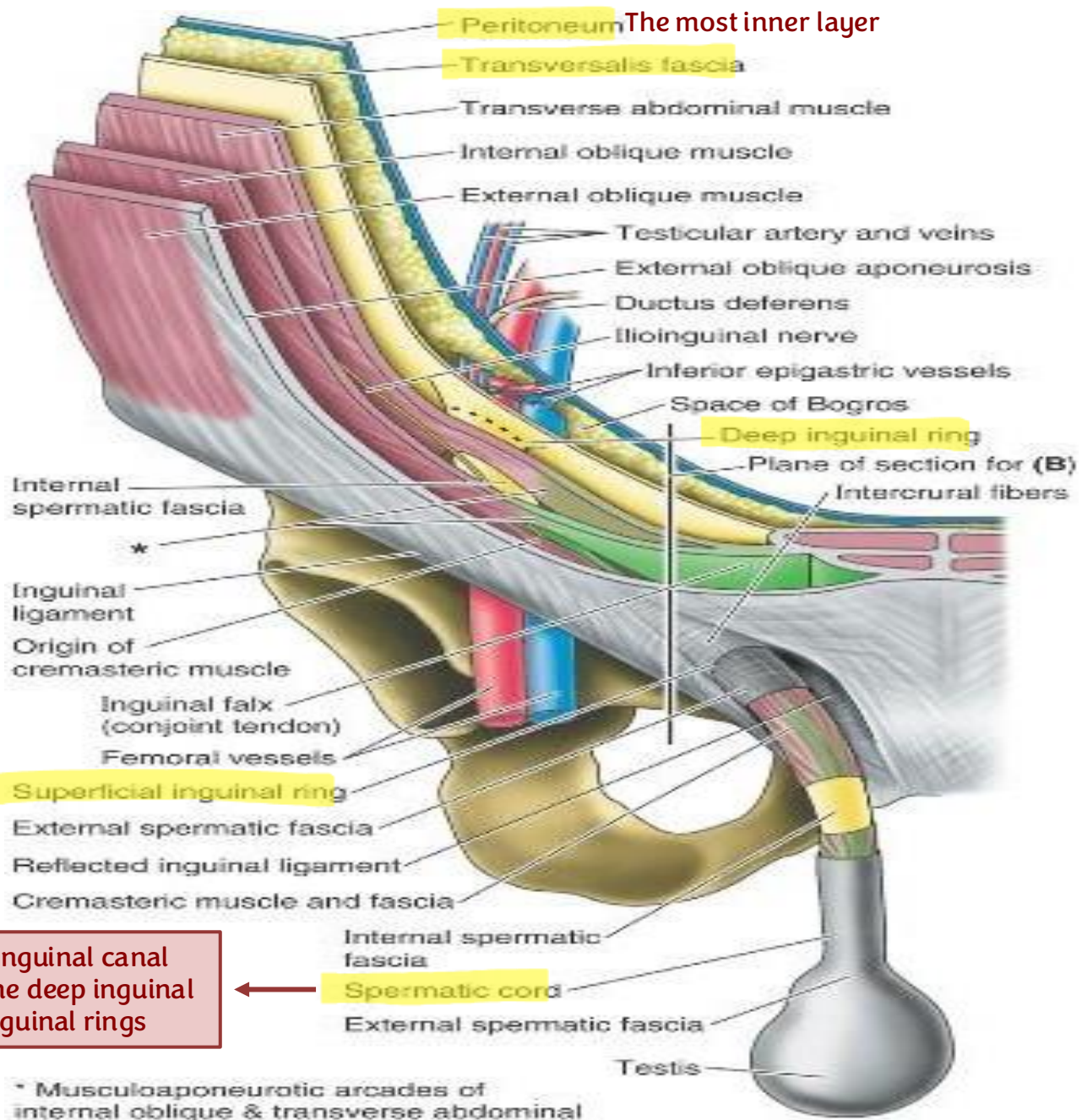
## ❖ Conjoint tendon

- The lowest tendinous fibers of internal oblique which joins with transversus abdominis and attached to the pubic bone
  - Attach medially to linea alba
  - Support the inguinal canal
  - Has lateral free border
  - Conjoint tendon is important as it's used as stitches for herniorrhaphy because it's a tough organ

## ❖ Cremasteric fascia

Internal oblique has free lower border arches over the spermatic cord (**spermatic fascia**) or ligament of uterus **in the inguinal canal**

- **It surrounds the Cremasteric muscle** making what is named the Cremasteric muscle Fascia
- **Int. abd. muscle assist in the formation of the Roof of the inguinal canal**



Peritoneum The most inner layer

Transversalis fascia

Transverse abdominal muscle

Internal oblique muscle

External oblique muscle

Testicular artery and veins

External oblique aponeurosis

Ductus deferens

Ilioinguinal nerve

Inferior epigastric vessels

Space of Bogros

Deep inguinal ring

Plane of section for (B)

Intercrural fibers

Internal spermatic fascia

\*

Inguinal ligament

Origin of cremasteric muscle

Inguinal falx (conjoint tendon)

Femoral vessels

Superficial inguinal ring

External spermatic fascia

Reflected inguinal ligament

Cremasteric muscle and fascia

Internal spermatic fascia

Spermatic cord

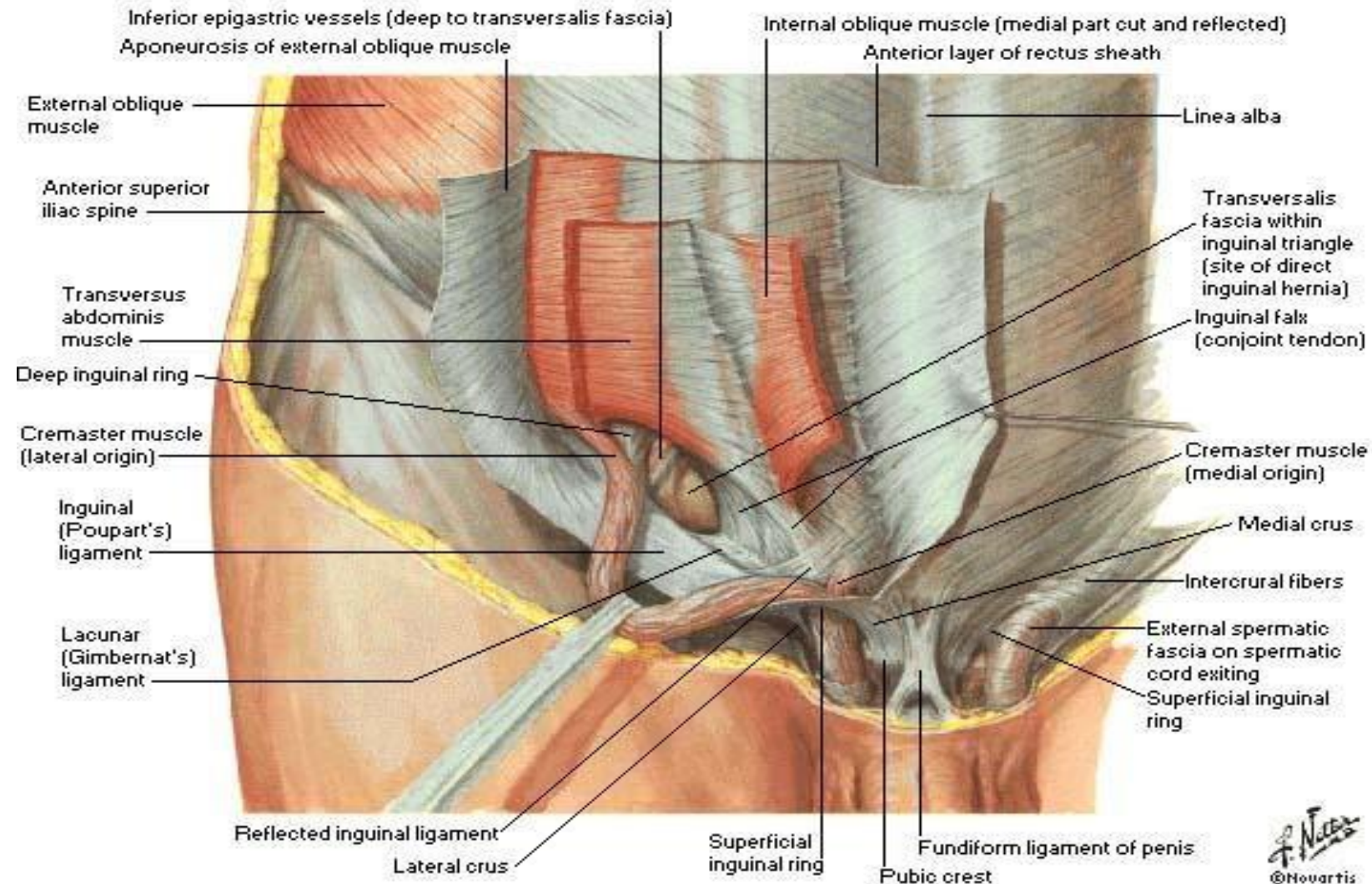
External spermatic fascia

Testis

Passing through the inguinal canal which lies between the deep inguinal and the superficial inguinal rings

\* Musculoaponeurotic arcades of internal oblique & transverse abdominal

# Conjoint tendon C Cremasteric fascia



## ❖ Transversus Abdominis

### ✓ Direction

- Its fibers run horizontally forward under the internal oblique

### ✓ Origin

- Inner surface of lower six costal cartilage,  
lumbar fascia,  
anterior two thirds of iliac crest,  
lateral third of inguinal ligament.

### ✓ Insertion

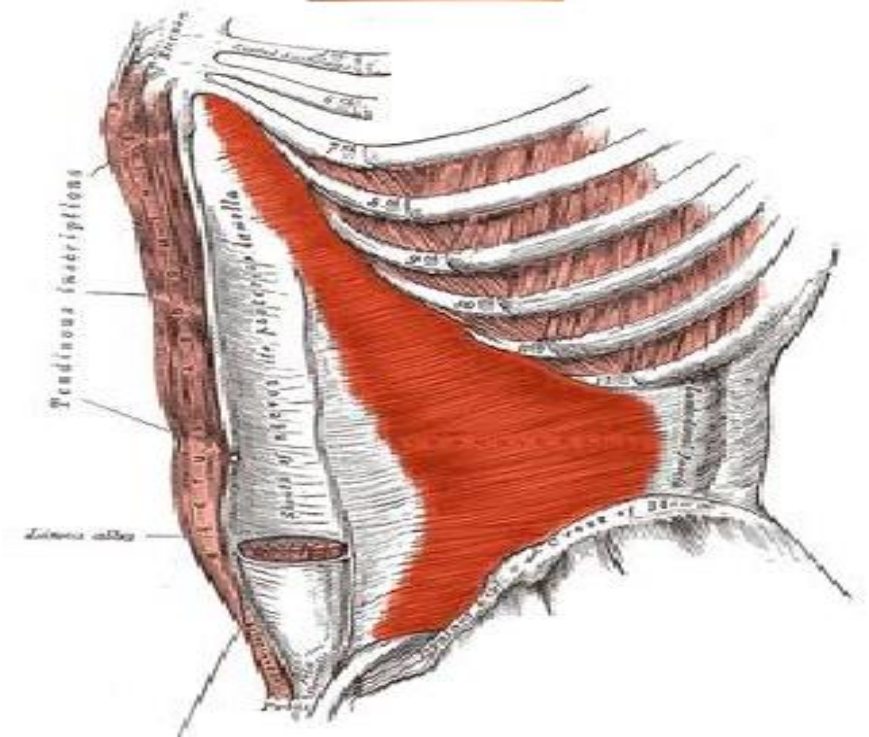
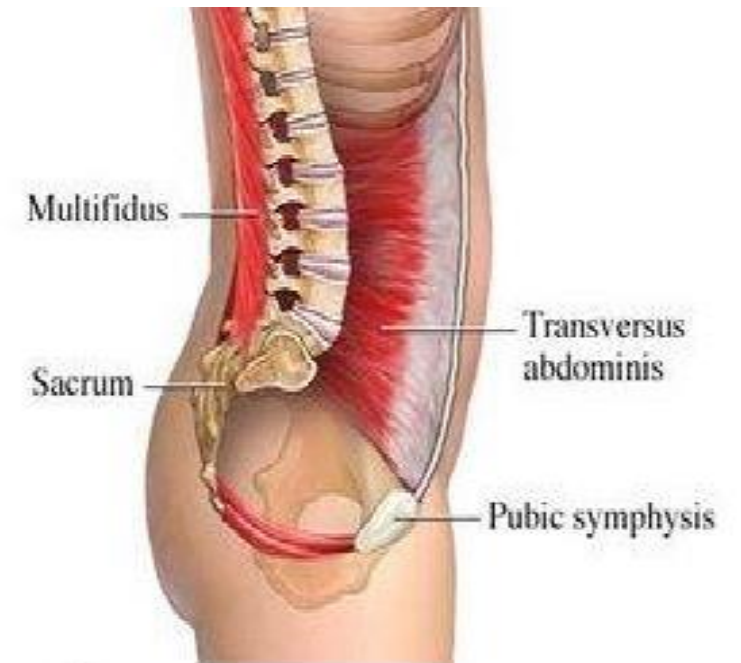
Xiphoid process, Linea alba, symphysis pubis.

The lower part fuses with internal oblique to form conjoint tendon which attach to pubic crest and pectineal line

### ✓ **Nerve Supply** the same as the two oblique muscles

Lower six thoracic nerves,

L1( iliohypogastric n.C ilioinguinal n.)



# Transversus Abdominis.....cont

Assist in the formation of

- Conjoint tendon
- Rectus sheath

The different fibres direction in the three muscles gives the strength to the abdominal muscles

# RECTUS ABDOMINIS

- Long strap muscle
- Extends along the whole length of the anterior abdominal wall

Which starts from the linea semilunaris laterally to the linea alba medially

- In the rectus sheath

✓ Origin:

Symphysis pubis, pubic crest

✓ Insertion:

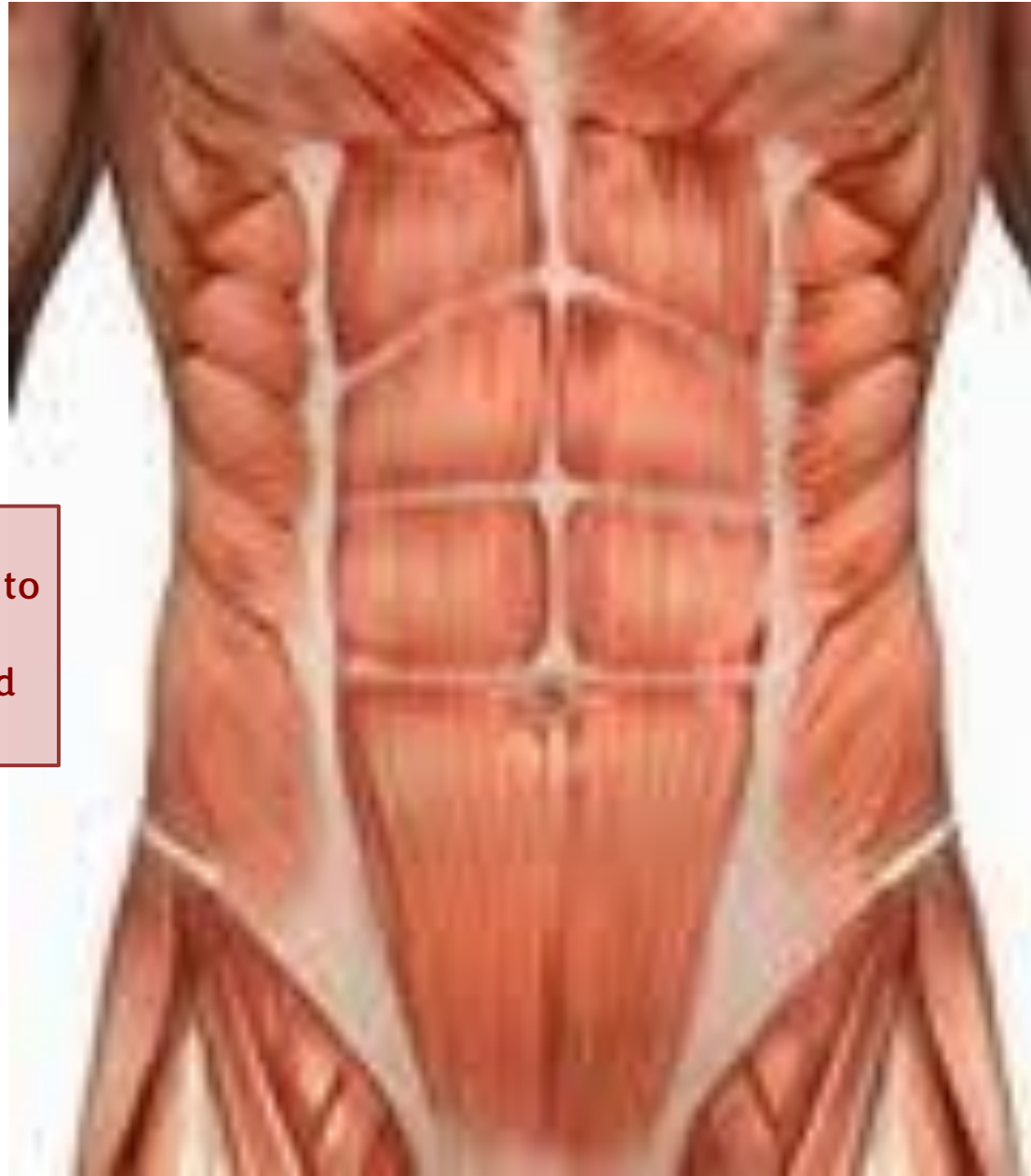5<sup>th</sup>, 6<sup>th</sup> and 7<sup>th</sup> costal cartilage and xiphoid process.

✓ Nerve Supply

Lower 6<sup>th</sup> thoracic nerves

Notice that L1 here doesn't assist in the innervation because this muscle is inside the rectus sheath and L1 doesn't pass the rectus sheath

The direction from the origin to the insertion is from downward to upward



# Rectus abdominis muscle.....cont

- **Linea alba (midline)**
- **Linea semilunaris (the edge)**
- **Tendinous intersection (at anterior wall)**

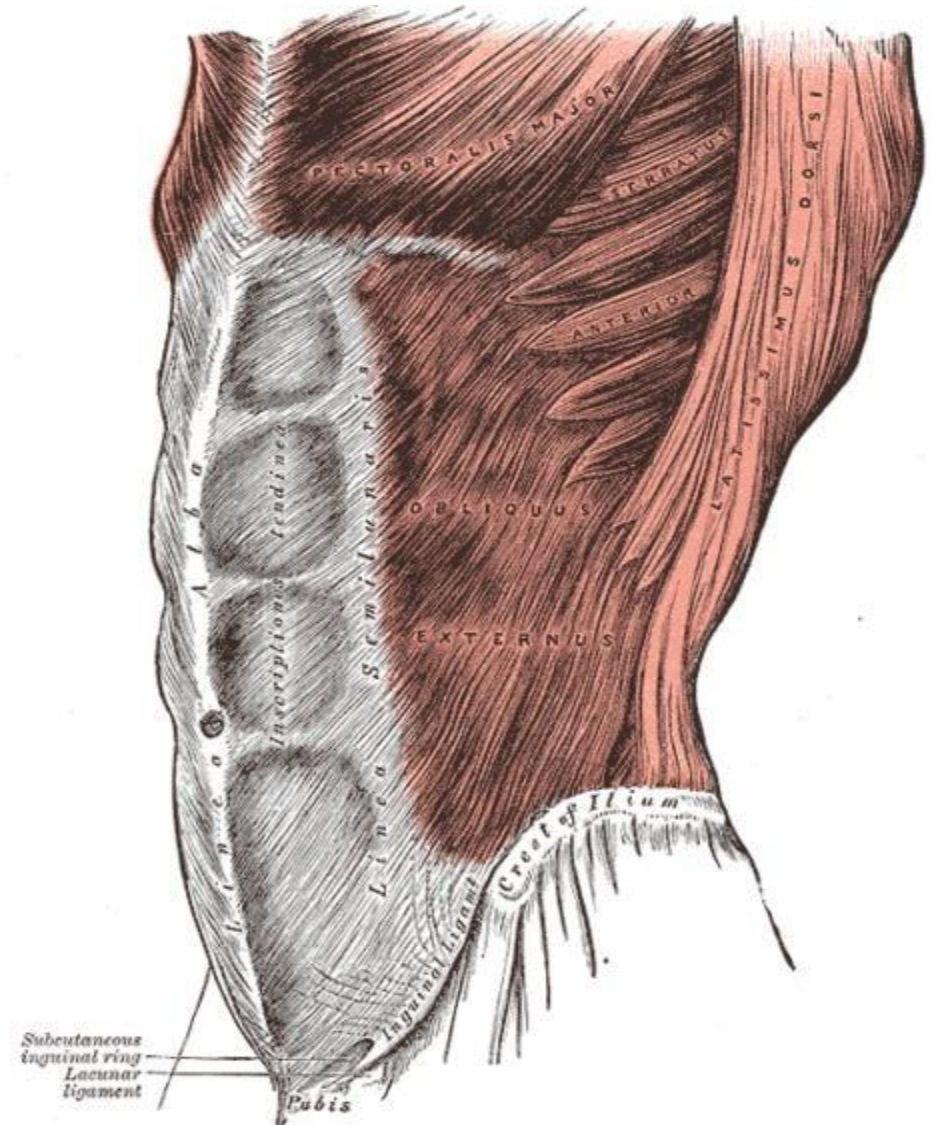
## Lines & Land marks of the Anterior Abdominal Wall:

### - Linea alba:

- It's a fibrous tissue located along the midline.
  - Between the xiphoid process & symphysis pubis
  - Formed by the fusion of aponeuroses of three abdominal wall (Ex.In, Tran. Abd. muscle)
  - Importance : it is the targeted site for wide field abdominal surgeries ( midline incision)
- Its poor blood supply has an advantage and a disadvantage
- Advantage : minimal bleeding
- Disadvantage : poor healing that takes a long time

### - Linea semilunaris

- Lateral margins of rectus sheath & rectus abd. .muscle
- Can be palpated
- Extend from 9th c.c to pubic tubercle

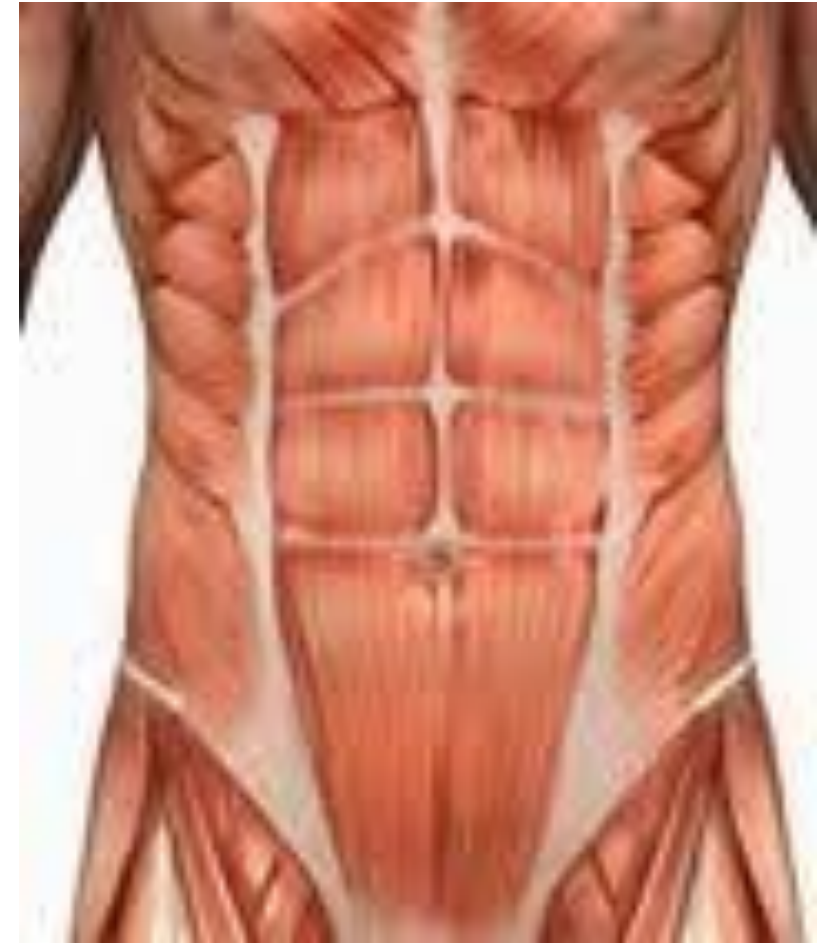

# Tendinous intersection: = Linea transverses

- 3 transverse fibrous bands (could be 4)
- divide the rectus abdominis muscle into distinct segments
  - 1 one at level of xiphoid process
  - 2 one at level of umbilicus and
  - 3 one half way between these two
  - 4 Below the umbilicus

Those tendinous intersections are adherent to the anterior wall of the rectus sheath

- They can be palpated as a transverse depressions



# Pyramidalis muscle

## -Origin

Ant. Surface of the pubis

## -Insertion:

Linea alba

-It lies in front of the lower part of the rectus abdominis muscle **inside the rectus sheath**

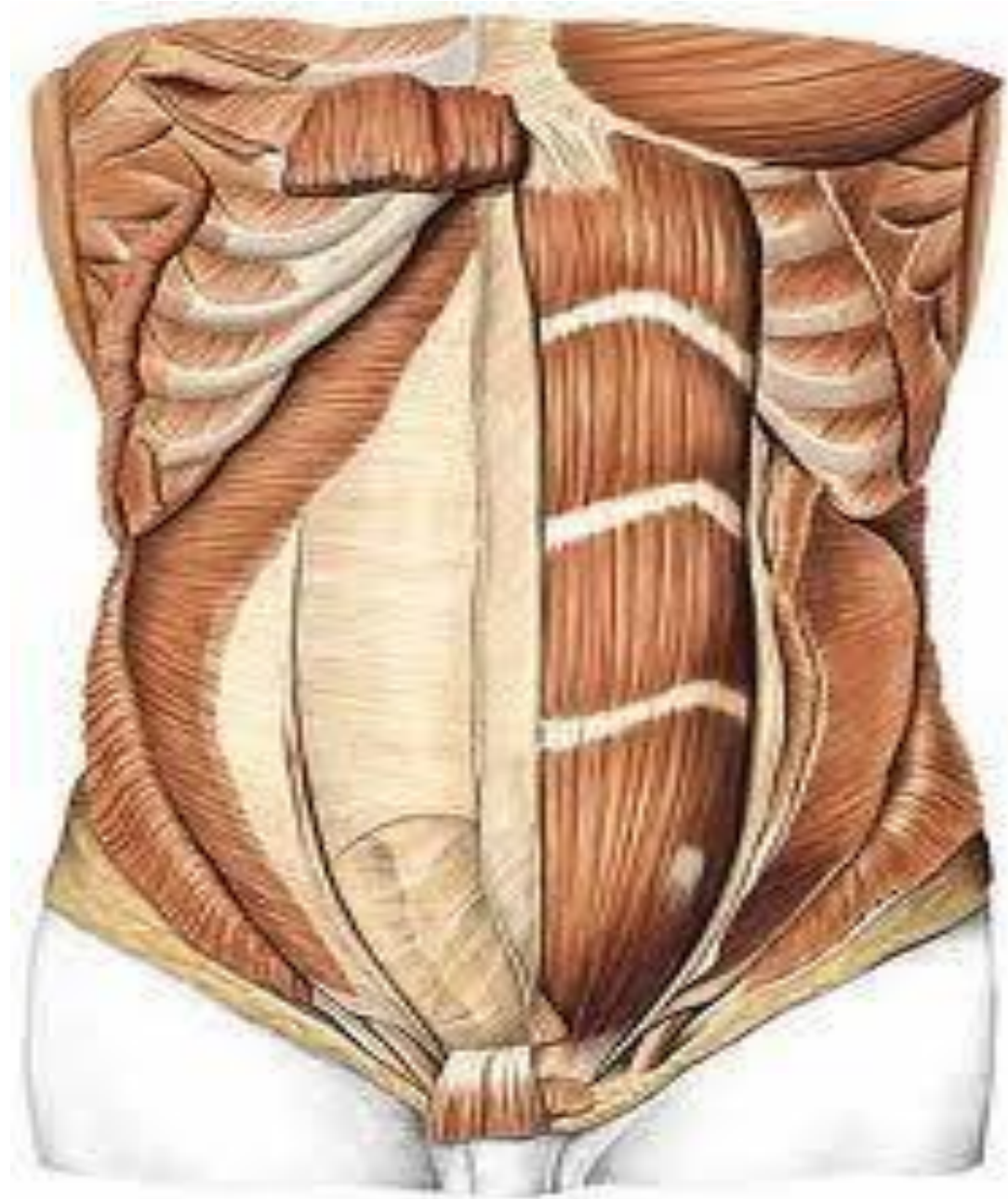
## -Nerve supply

12<sup>th</sup> subcostal nerve

## -Action :

pulls the linea alba downward .

- Can be absent



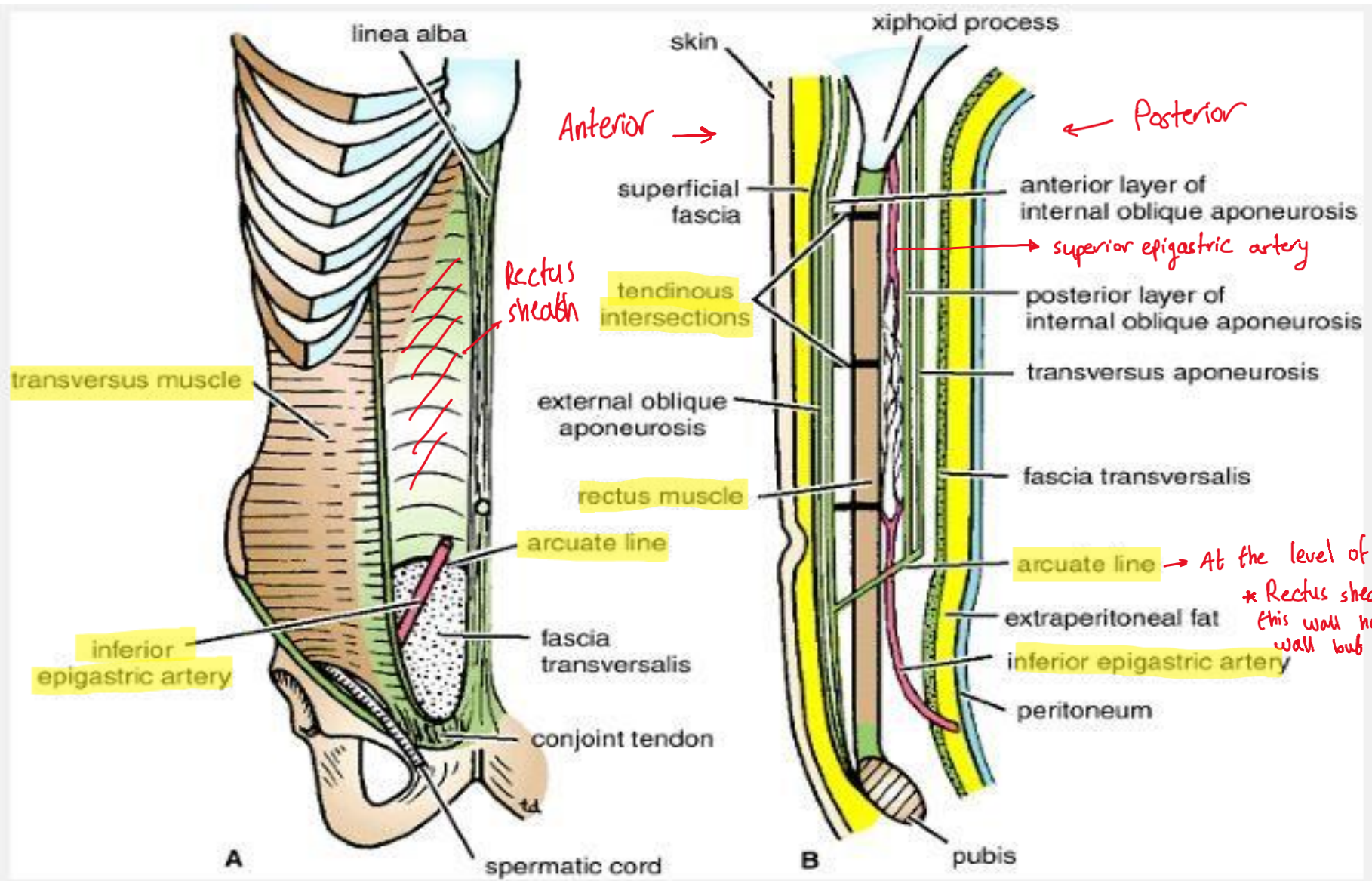
**Rectus sheath**

# Rectus sheath.....cont

- The rectus sheath is a long fibrous sheath
- Formed mainly by the aponeuroses of the three lateral abdominal muscles.
- Found on both sides of the linea alba
- Bounded laterally by linea semilunaris ( edge of rectus abdominus )
- **Contents - important -**
  - Rectus abdominis muscle
  - Pyramidalis muscle (if present)
  - The anterior rami of the lower six thoracic ( **intercostal** ) nerves ( they originate from the thorax between 2 muscles : transversus abdominis and internal oblique and then arrives the rectus sheath from lateral to medial and **supply the rectus abdominus** and terminate finally as anterior cutaneous nerves to the abdomen )
  - The superior and inferior epigastric vessels
  - Lymphatic vessels.

# Rectus sheath.....cont

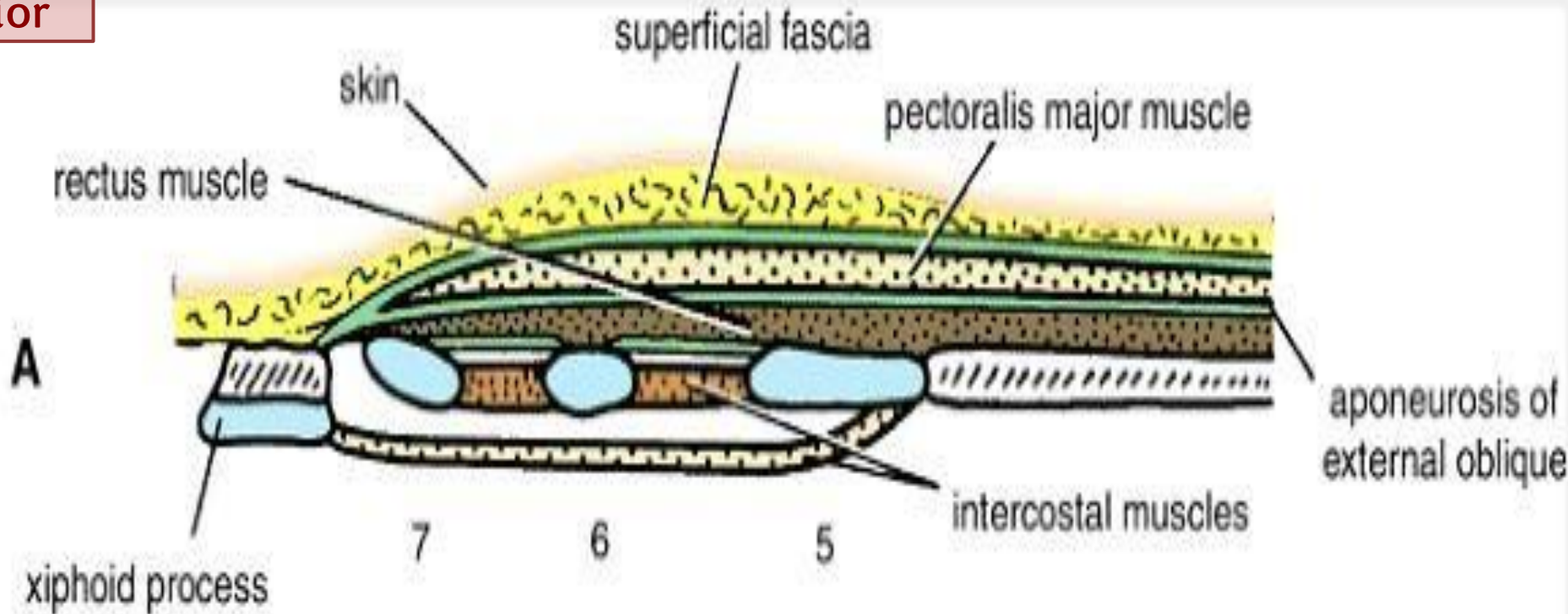
- Description the rectus sheath is considered at three levels.
  - 1 Above the costal margin ( **at the xiphoid process** )
  - 2 Between the costal margin and the level of the anterior superior iliac spine ( **between the xiphoid & umbilicus** )
  - 3 Between the level of the anterosuperior iliac spine and the pubis the anterior wall ( **below anterior superior iliac spine** )



This slide is just a quick overview to help you picture things better. We'll go through everything in detail soon.

**Figure 4-10** Rectus sheath in anterior view (A) and in sagittal section (B). Note the arrangement of the aponeuroses forming the rectus sheath.

Anterior



Dr said that you should know what lies anterior and posterior on each level.

Hint: by observing the image you could easily memorize them.

Posterior

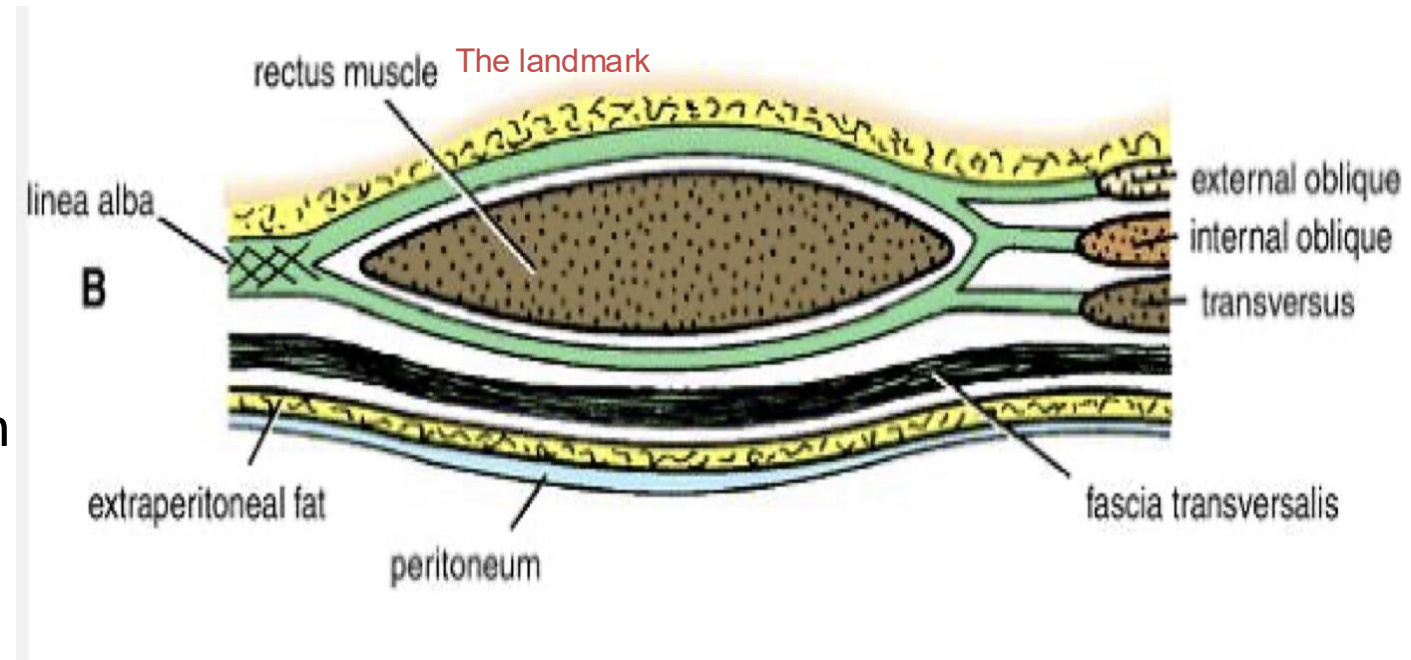
***Above the costal margin, first level :***

- Anterior wall # **Skin** → **superficial fascia** → **deep fascia** → **pectoralis muscle** → aponeurosis of the external oblique.

- Posterior wall # **xiphoid process** , thoracic wall that is, the fifth, sixth, and seventh costal cartilages and the intercostal spaces, **intercostal muscles**.

***Between the costal margin and the level of the anterior superior iliac spine (above and below the umbilicus )***  
**second level :**

- The aponeurosis of the internal oblique splits to enclose the rectus muscle → **giving one anterior and one posterior layers.**
- the external oblique aponeurosis is directed in front of the muscle
- the transversus aponeurosis is directed behind the muscle.



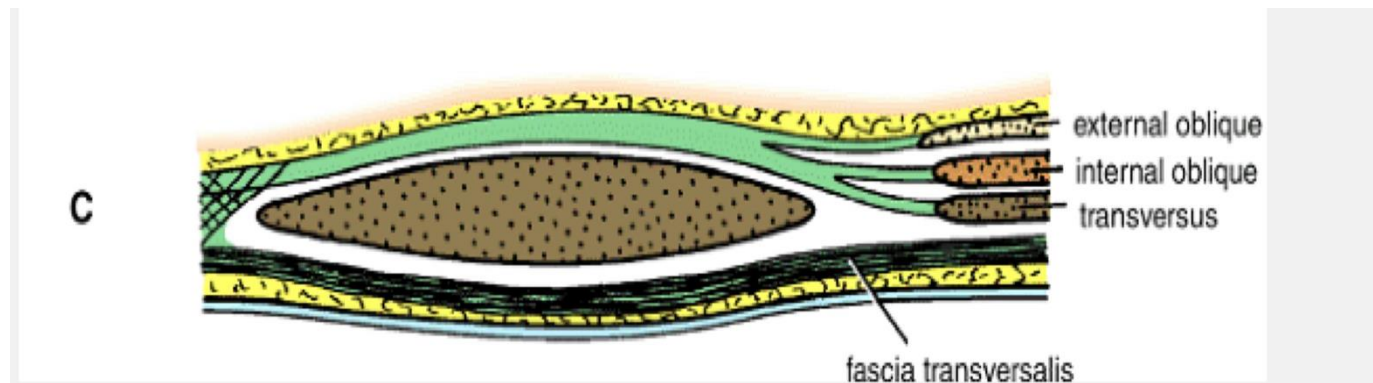
- **Anterior : skin → superficial fascia → aponeurosis of external oblique → ant. layer of internal oblique**
- **Posterior : post. layer of internal oblique → transversus abdominis → transversalis fascia → extraperitoneal fat → parietal peritoneum**

***Between the level of the anterosuperior iliac spine and the pubis***  
( below ASIS (anterior superior iliac spine) )

**Third level :**

The anterior wall : **skin** → **superficial fascia** → the aponeurosis of all three muscles form.

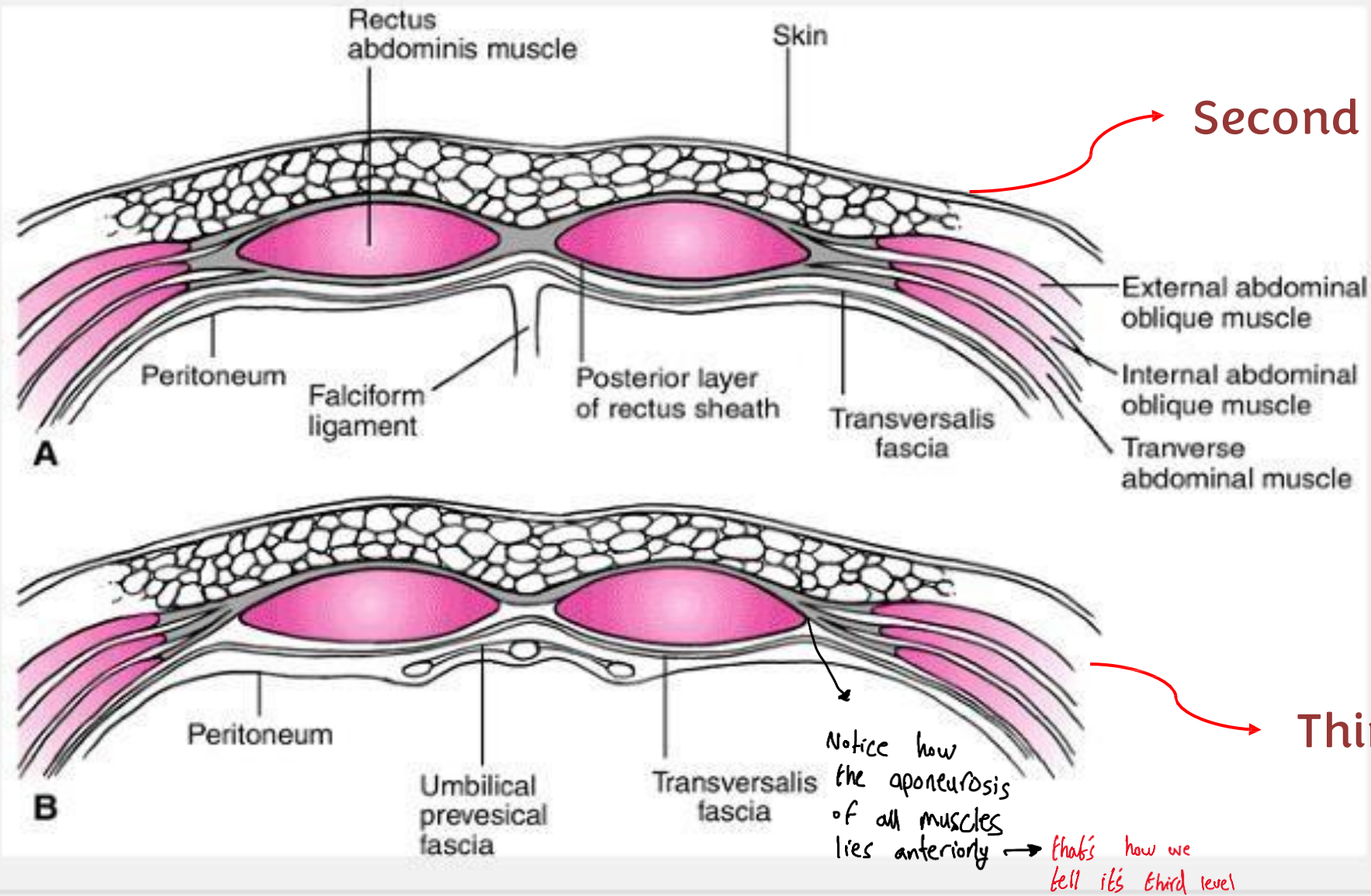
The posterior wall is absent, and the rectus muscle lies in contact with the fascia transversalis. So:  
**transversalis fascia** → **extraperitoneal fat** → **parietal peritoneum**



**Figure 4-13** Transverse sections of the rectus sheath seen at three levels. **A.** Above the costal margin. **B.** Between the costal margin and the level of the anterior superior iliac spine. **C.** Below the level of the anterior superior iliac spine and above the pubis.

# Rectus sheath.....cont

- The posterior wall of the rectus sheath is not attached to the rectus abdominis muscle. The anterior wall is firmly attached to it by the muscle's tendinous intersections
- **Linea semicircularis (arcuate line)**  
This line lies approximately at the level of the anterior superior iliac spine (ASIS). It is clinically significant because the inferior epigastric artery arises inferior to it and enters the rectus sheath at this level.
- Is a crescent-shaped line marking the inferior limit of the posterior layer of the rectus sheath just below the level of the iliac crest.



Second level

Third level

Notice how the aponeurosis of all muscles lies anteriorly → that's how we tell it's third level

**Figure 5-2** Arrangement of the rectus sheath above the umbilicus (upper) and below the arcuate line (lower).

# Others fascia in the ant. abdominal wall

## ❖ Transversalis fascia

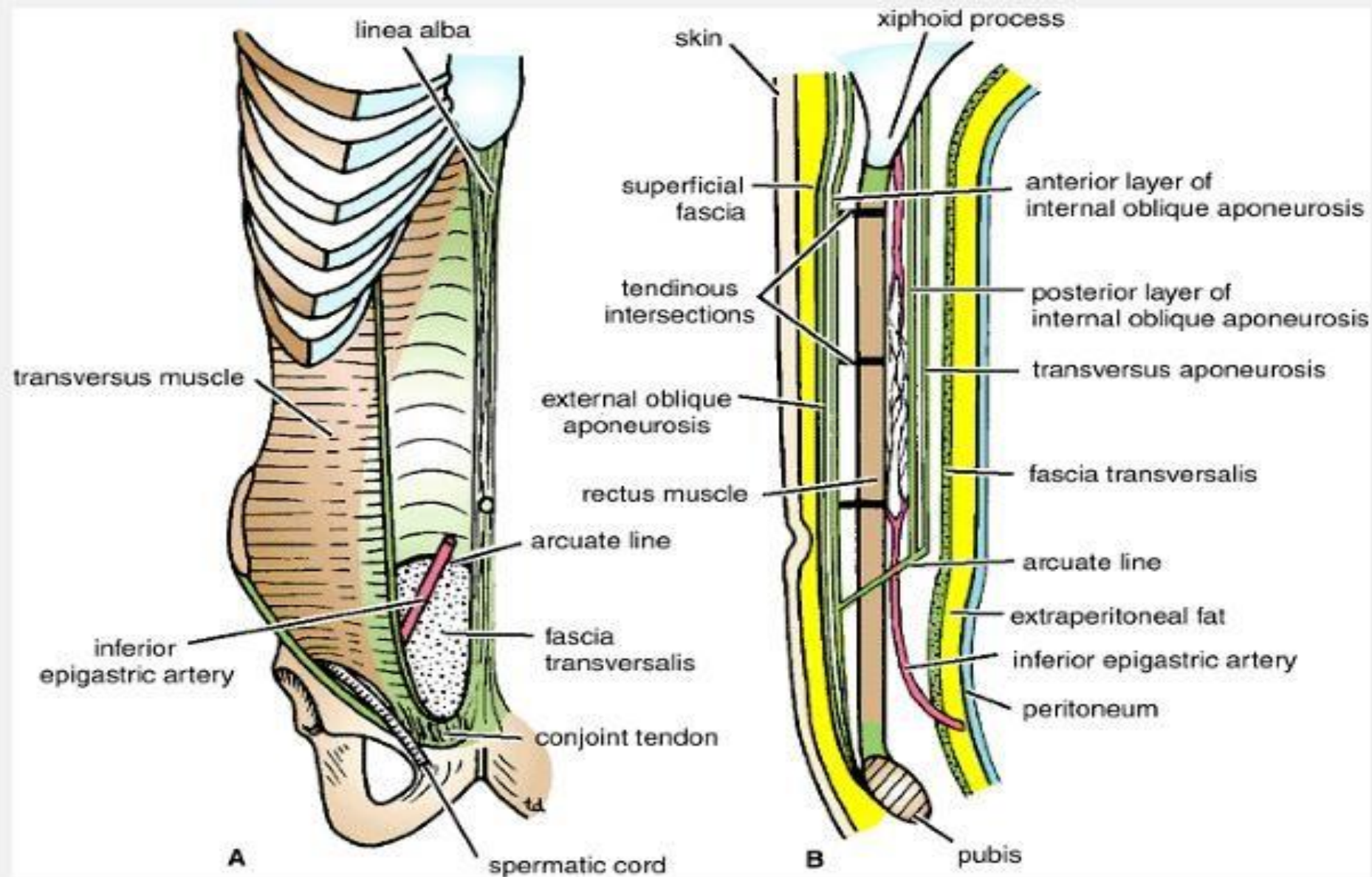
- a thin layer of fascia that lines the Transversus Abdominis muscle
- continue to diaphragm , iliac muscle & pelvis fascia
- contribute to femoral sheath
- Forms the posterior wall of the rectus sheath below the arcuate line
- Forms deep ring of the inguinal canal

## ❖ Extraperitoneal Fascia

- ✓ The thin layer of C.T and adipose tissue between the peritoneum and fascia transversalis.

## ❖ Parietal peritoneum

- ✓ It is a thin serous membrane
- ✓ Continuous below with the parietal peritoneum lining the pelvis.



**Figure 4-10** Rectus sheath in anterior view (A) and in sagittal section (B). Note the arrangement of the aponeuroses forming the rectus sheath.

# Action of the Ant. Abdominal muscle

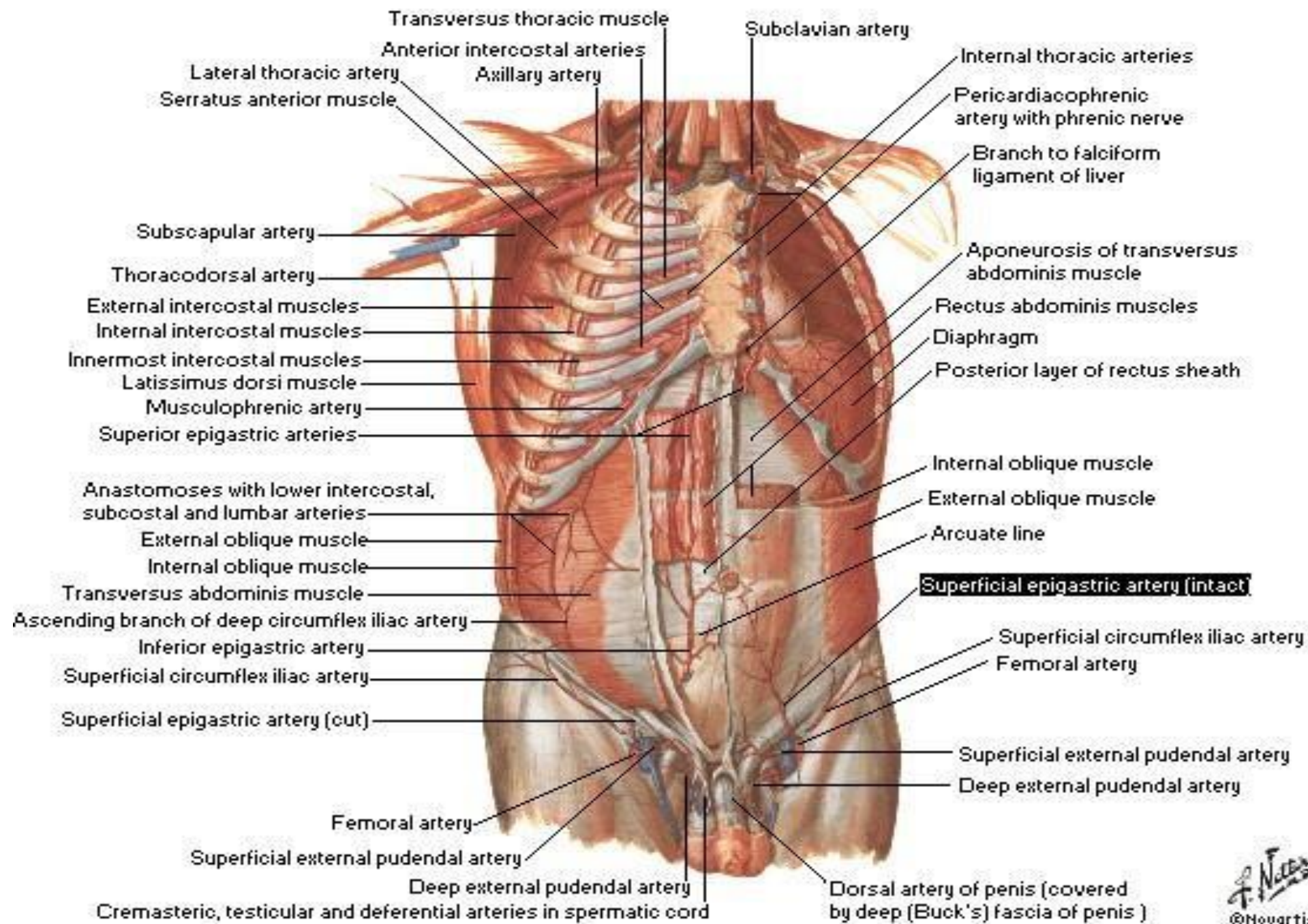
- Deep expiration (**the most important action**)
- Increase the intra abdominal pressure in
  - Vomiting
  - Cough
  - Defecation
  - Labour
- Protect viscera
- keep viscera in position
- Rectus abdominis → bends trunk forward

# Blood supply of the ant. Abdominal wall

## Arteries

- Sup. Epigastric artery
  - Inf. Epigastric artery
  - Intercostal arteries ( run along the nerves from the thorax )
  - Lumbar arteries from abdominal aorta
  - Deep circumflex artery
- Inside the rectus sheath

# Arteries of Anterior Abdominal Wall



# Blood supply.....cont

## Veins

### **1- Above the umbilicus**

- Lat. Thoracic. vein. → Axillary vein

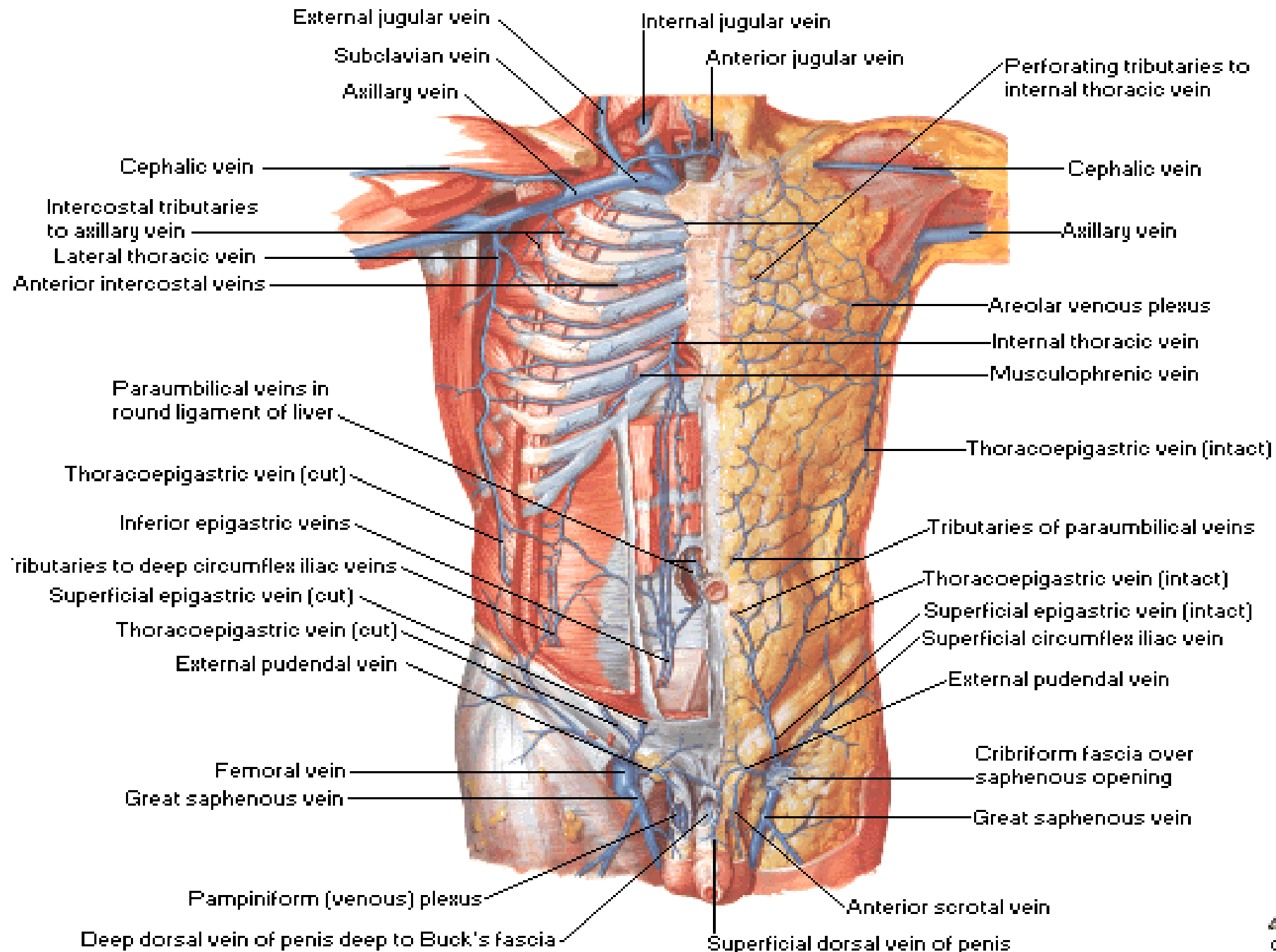
### **2- Below the umbilicus**

- Inf. Epigastric → Femoral vein

### **3- Paraumbilical veins**

- Ligamentum teres → portal vein( Porto- systemic anastomosis)

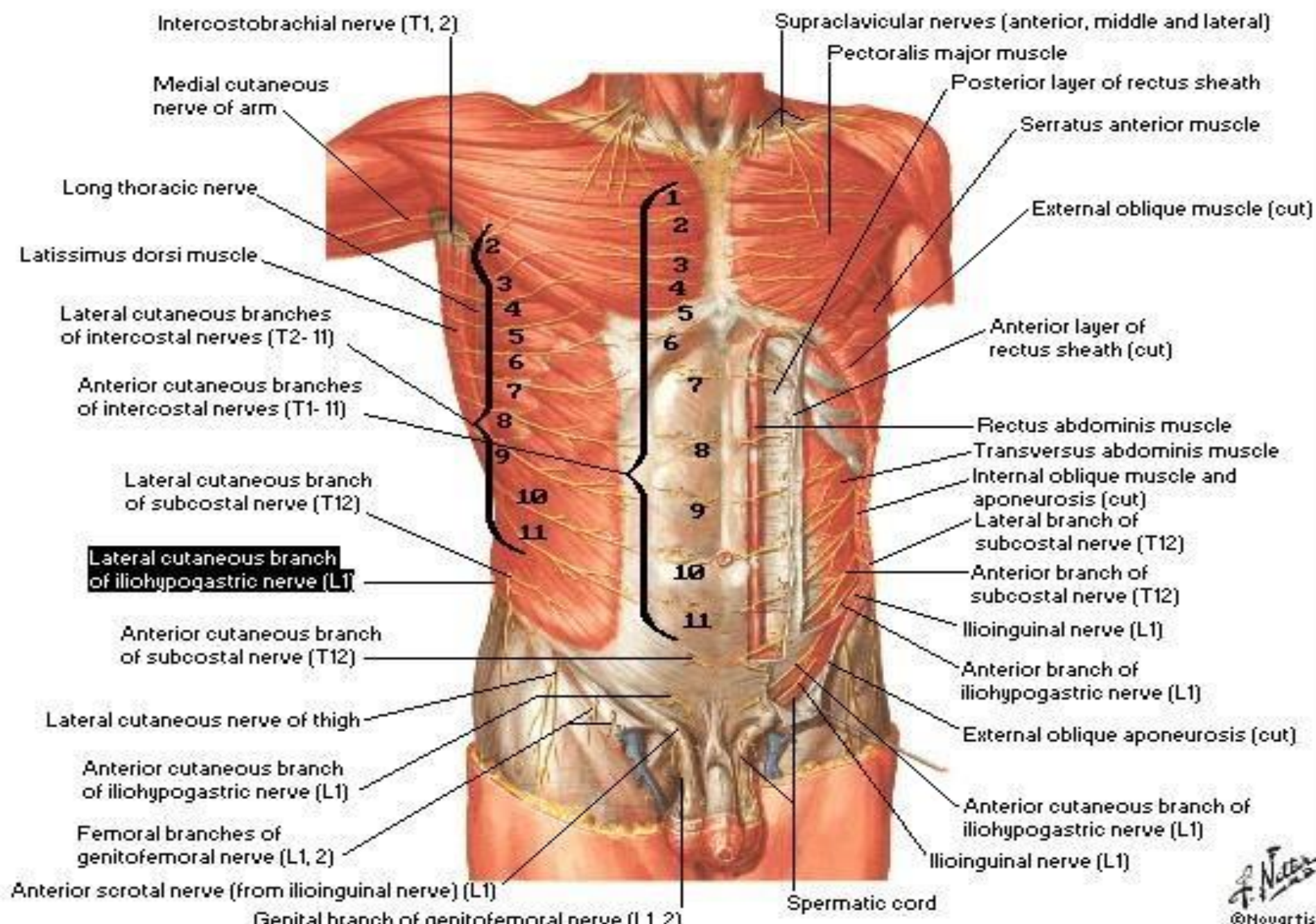
# Veins of Anterior Abdominal Wall



# Nerve supply of the ant. Abdominal wall

- **Thoracoabdominal nerve:** Lower 6<sup>th</sup> thoracic nerves & 12<sup>th</sup> subcostal nerve
- **Dermatomes (skin sensation)**
- (Anterior, lateral cutaneous nerve terminal branches of Thoracoabdominal nerve)
  - T7 to skin superior to umbilicus **below xiphoid process**
  - T10 to skin surrounding umbilicus
  - L1 to skin inferior to umbilicus above sym. pubis
- **L1 nerve** → for lower abdomen and scrotum
  - Iliohypogastric nerve
  - Ilioinguinal nerve

# Nerves of Anterior Abdominal Wall



# Lymphatic drainage of ant. Abdominal wall

- Above the umbilicus → Ant.axillary L.N
- Below the umbilicus → Sup. Inguinal L.N
- Above the iliac crest → Post.axillary.L.N (subscapular L.N)
- Below the iliac crest → Sup.inguinal L.N

L.N = lymph node

# Clinical notes

Abdominal stab wounds

Surgical incision

Important to read for future  
clinical knowledge

# Abdominal stab wounds

- Structures in the various layers through which an abdominal stab wound depend on the anatomical location :

- Lateral to rectus sheath
- Ant. To rectus sheath
- In the midline= Linea alba

# Surgical incision

- The length and direction of surgical incision through the ant. Abdominal wall to expose the underlying viscera are largely controlled by
  - 1 position & direction of nerves
  - 2 direction of muscle fibers
  - 3 arrangement of the aponeurosis forming the rectus sheath
- The incision should be made in the direction of the line of cleavage in the skin so that the hairline scar is produced

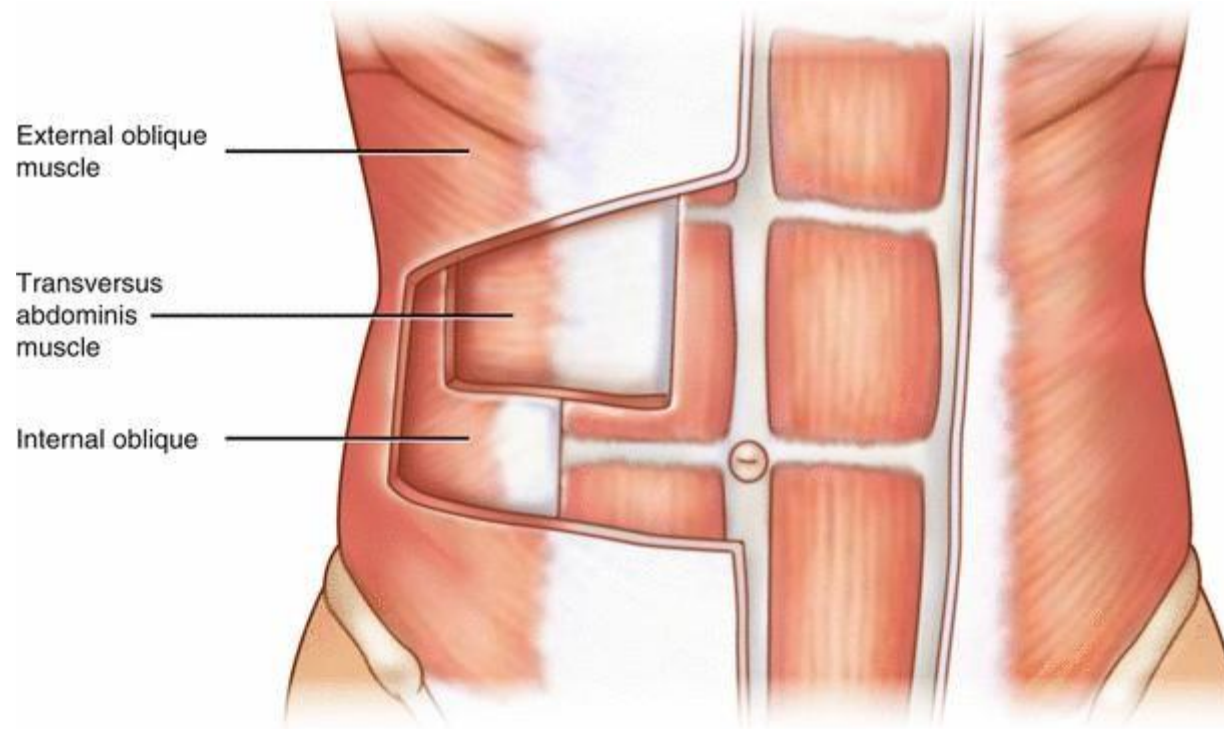
# Incision through the rectus sheath

- Widely used
- The rectus abdominis muscle and its nerve supply are kept intact
- On closure the ant C post wall of the sheath are sutured separately and the rectus muscle back into position between the suture lines

# Common types of incisions

- Paramedian incision
- Pararectus incision
- Midline incision
- Transrectus incision
- Transverse incision
- Muscle splitting
- Abdominothoracic incision

# Quiz on this lecture



# رسالة من الفريق العلمي:

وَكَانَ مِنْ دُعَائِهِ ﷺ:  
« وَأَسْأَلُكَ نَعِيمًا لَا يَنْفَدُ، وَأَسْأَلُكَ  
قُرَّةَ عَيْنٍ لَا تَنْقَطِعُ وَأَسْأَلُكَ الرِّضَا  
بِالْقَضَاءِ وَأَسْأَلُكَ بَرْدَ الْعَيْشِ بَعْدَ  
الْمَوْتِ وَأَسْأَلُكَ لَذَّةَ النَّظَرِ إِلَى  
وَجْهِكَ وَالشَّوْقَ إِلَى لِقَائِكَ  
فِي غَيْرِ ضَرَاءٍ مُضِرَّةٍ وَلَا فِتْنَةٍ مُضِلَّةٍ  
اللَّهُمَّ زَيِّنَا بِزِينَةِ الْإِيمَانِ وَاجْعَلْنَا هُدًى  
مُهْتَدِينَ »

# For any feedback, scan the code or click on it.



Corrections from previous versions:

Versions	Slide # and Place of Error	Before Correction	After Correction
V0 → V1			
V1 → V2			