

بِسْمِ اللّٰهِ الرَّحْمٰنِ الرَّحِیْمِ

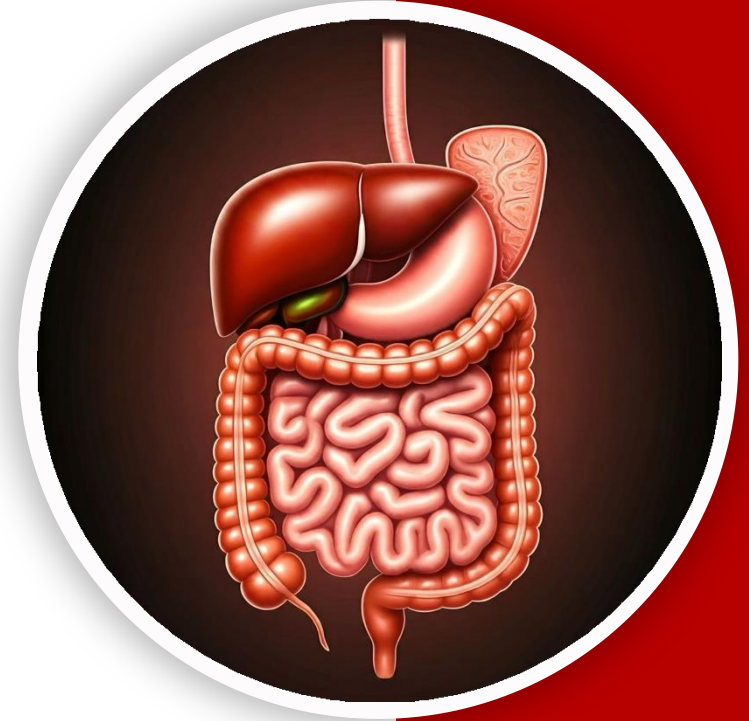
(وَفَوْقَ كُلِّ ذِي عِلْمٍ عَلِيمٌ)



جراحین

GIS Anatomy | Final

Past Papers



Written by : DST, RST

Reviewed by : Rawan okour



Past Papers



● ● ● ● ●



***Liver, Gallbladder,
Pancreas & Spleen***

● ● ● ● ●



Q1:Liver: all the following statements are correct EXCEPT

- a. Caudate lobe drains into left hepatic duct.
- b. Clamping of the structures in the free edge of the lesser omentum may prevent liver bleeding.
- c. It may reach up to the fifth intercostal space.
- d. It is larger relatively in newborn infants than adults.
- e. Caudate process forms the anterior boundary of the epiploic foramen.

Q2:Regarding the bile duct (common bile duct) all the following statements are correct EXCEPT:

- a. It runs anterior to the head of pancreas.
- b. It opens into the second part of duodenum independent of the pancreatic duct.
- c. It is 3-4 inches long.
- d. Descends through the free edge of the lesser omentum.
- e. It runs posterior to the first part of duodenum.

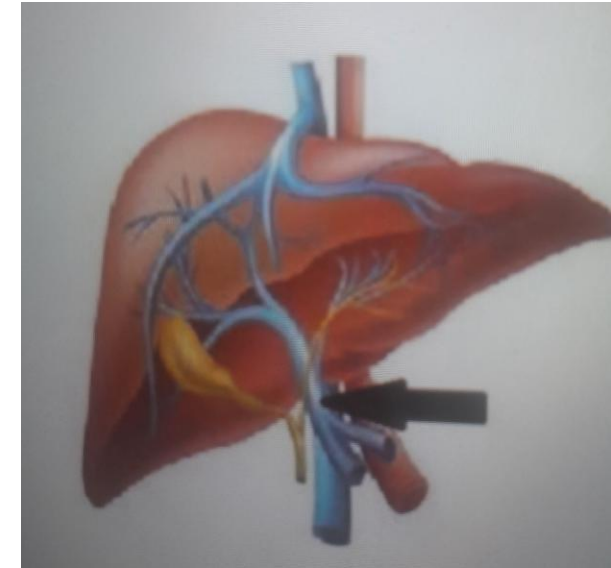
Q3: The pancreas: all the following statements are correct EXCEPT:

- A. The splenic artery runs on its upper (superior) border.
- B. The splenic vein runs on its posterior surface.
- C. Left psoas muscle lies posterior to it.
- D. The uncinate process lies between the aorta and the superior mesenteric vessels.
- E. The transverse mesocolon is attached to its inferior border

Ans: E

Q4: All of the following organs drain into the pointed structure EXCEPT:

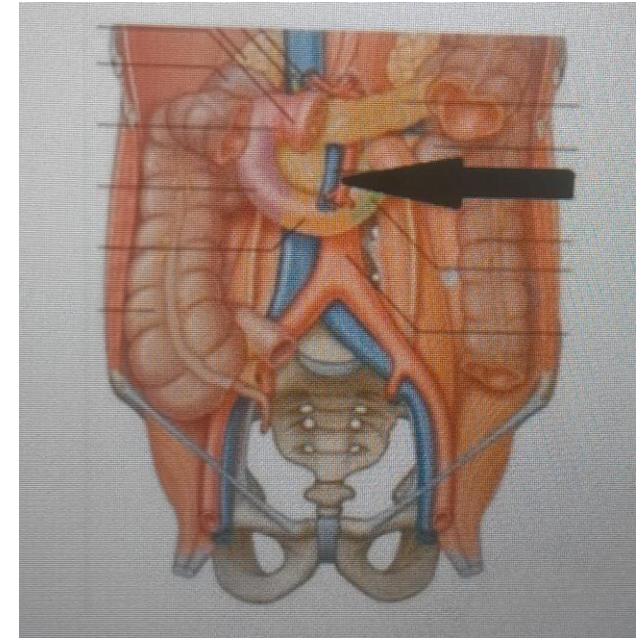
- A. Stomach.
- B. Gallbladder.
- C. Duodenum.
- D. Pancreas.
- E. Liver.



Ans: E

Q5: The pointed structure supplies all of the following organs
EXCEPT:

- A. Appendix.
- B. Duodenum.
- C. Pancreas.
- D. Ilium.
- E. Spleen.



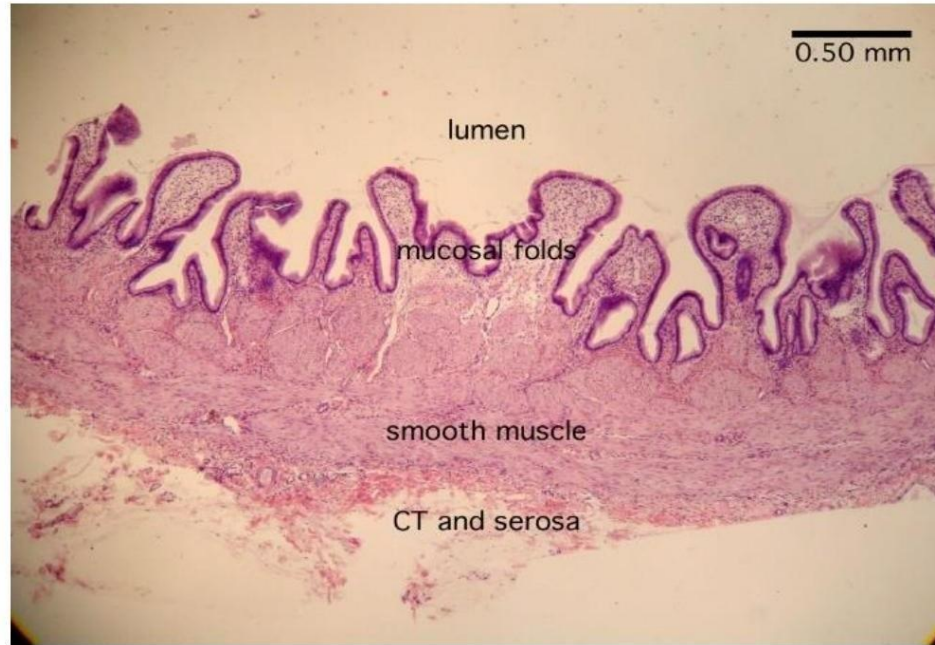
Ans: E

Q6: The portal vein, all the following statements are correct EXCEPT:

- A. It ends in porta hepatis of the liver.
- B. It passes behind the third part of duodenum.
- C. It receives the venous blood of duodenum.
- D. It lies on the free edge of lesser omentum.
- E. It is formed behind the neck of the pancreas.

Q7:Identify this section:

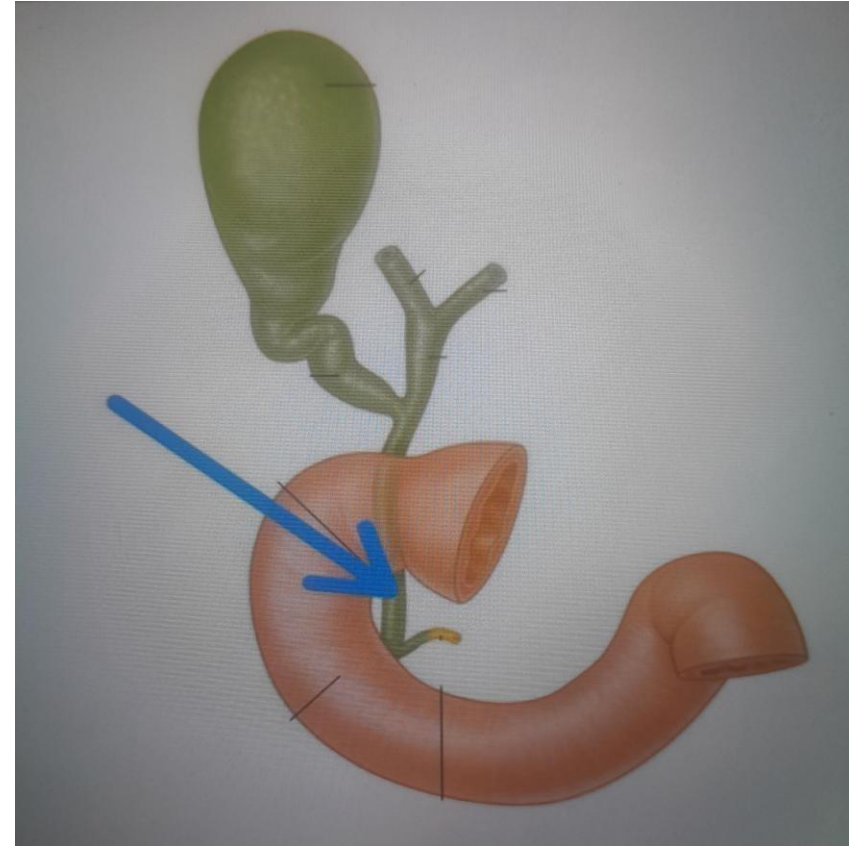
- A. Esophagus.
- B. Duodenum.
- C. Colon.
- D. Appendix
- E. Gallbladder.



Ans: E

Q8: The length of the pointed structure is:

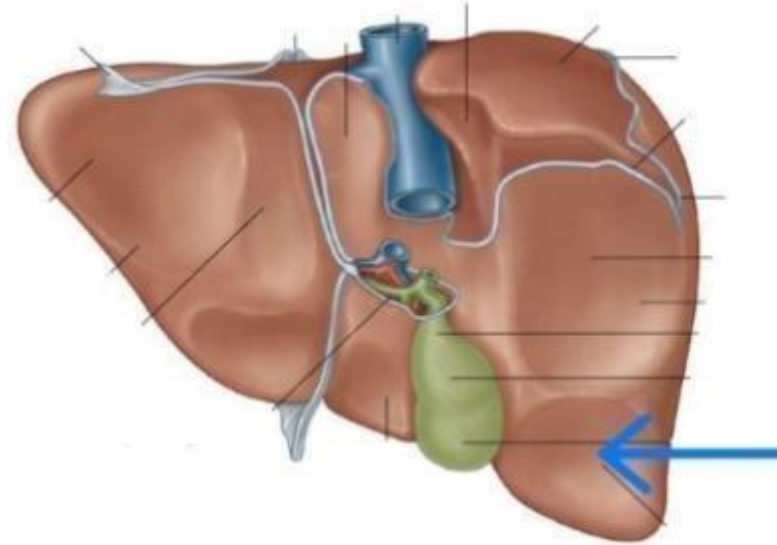
- A) 6–7 cm
- B) 8–10 cm
- C) 2–3 cm
- D) 4–5.5 cm
- E) 11–12 cm



Ans: B

Q9: Identify the pointed impression:

- A. Right colic flexure.
- B. Duodenum.
- C. Stomach.
- D. Renal.
- E. Esophagus.



Ans: A

Q10: The transverse mesocolon is characterized by all of the following EXCEPT:

- A. Contains parasympathetic fibers from vagus and sacral spinal nerves
- B. Contains lymph nodes that drain into preaortic lymph nodes.
- C. Attached to the inferior border of pancreas.
- D. Envelopes the transverse colon
- E. Contains branches from superior and inferior mesenteric arteries.

Ans: C

Q11: Which of the following statements about the pancreas is WRONG?

- A. It lies retroperitoneally on the posterior abdominal wall.
- B. The head of the pancreas is related to the duodenum.
- C. The portal vein is formed behind the neck of the pancreas.
- D. The pancreas drains into both the portal and systemic venous systems.
- E. The main pancreatic duct opens into the second part of the duodenum.

Ans: D

Q12: Choose the wrong statement in the following:

- A) The posterior surface of the pancreas is covered by the peritoneum of the lesser sac.
- B) The inferior surface of the pancreas is covered by peritoneum of the greater omentum.
- C) The anterior surface is covered by peritoneum of post. Wall of lesser sac.
- D) The formation of the portal vein occurs behind the neck of pancreas

Ans:A

Q13: Application of clamp at the free edge of lesser omentum, all of the following are correct EXCEPT:

- A. It helps to reduce the bleeding during liver injury
- B. The hepatic artery and portal vein are occluded
- C. The common bile duct will not get affected
- D. It interrupts the blood flow to the stomach

Ans:c

Q14:All of the following statements about the liver are correct except

- A) The liver has two main lobes: the right and the left lobes
- B) Quadrate lobe drains into right hepatic bile duct
- C) The liver has five surfaces
- D) The liver receives blood supply from both the hepatic artery and the portal vein

Ans: B

Q15: All the following are portal veins except:

A-left gastric

B-right colonic

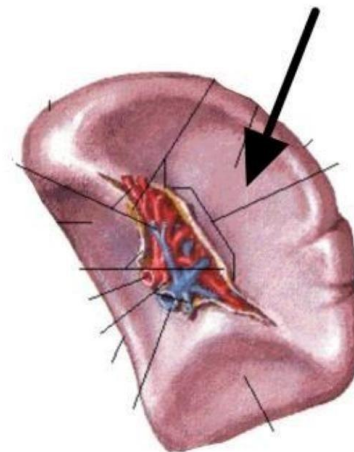
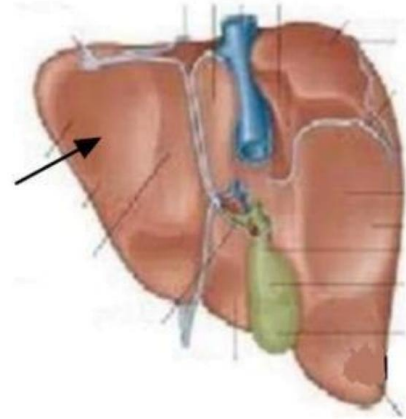
C-azygous

D-Inferior Vena Cava.

Ans: c

Q16+17: Which of the following correctly identifies the two impressions?

- A) Gastric and Gastric
- B) Gastric and Pyloric
- C) Duodenal and Colic
- D) Colic and Renal
- E) Pyloric and Duodenal



Ans: A


Q17: All the following are portal veins except:

A-left gastric

B-right colonic

C-azygous

Ans: C



The Posterior

Abdominal wall Pt.1



Q1: A male police officer came to the ER after experiencing a blunt trauma while working, further investigations proved that the site of trauma extended from the left deep inguinal ring as far as the left pubic tubercle, which of the following structures could be damaged by the trauma?

- A. Inferior epigastric artery
- B. Genital branch of genitofemoral nerve
- C. Testicular artery
- D. B+C
- E. All of the above

Ans: E

Q2:examinations showed that the patient retained, partially, the function of psoas major and quadratus lumborum, while he experienced total loss of function for the iliacus muscle, between which two vertebrae the injury is most probably located?

- A. T8-T9
- B. L4-L5
- C. L1-L2
- D. T11-T12
- E. S1-S2

Ans: C

Q3: Inferior mesenteric vessels, all the following are correct EXCEPT:


- A. The gonadal vessels cross anterior to the branches of the artery.
- B. The branches of the artery lie anterior to the left ureter.
- C. The vein drains to the splenic vein.
- D. The artery lies lateral to the inferior mesenteric vein.
- E. The artery arises from the aorta immediately behind the 3rd part of duodenum.

Ans: D

Q4: All of the following are paired branches of the abdominal aorta except:

- A) Middle suprarenal
- B) Superior mesenteric
- C) Testicular
- D) Renal
- E) Inferior phrenic

Ans: B



***Sigmoid Colon, Rectum,
Anal Canal & Posterior
Abdominal wall Pt.2***



Q1: The preganglionic parasympathetic innervation for the hindgut will be provided by:

- A. Sacral spinal nerves.
- B. Lumbar splanchnic nerves.
- C. Greater splanchnic nerves .
- D. Lesser splanchnic nerves.
- E. Vagus nerve.

Ans:A

Q2:A patient came to the emergency room with a stab wound slightly to the right of the umbilicus, which of the following structures will not be damaged?

- A. Inferior epigastric artery
- B. Superior epigastric artery
- C. Rectus abdominis muscle
- D. Iliohypogastric nerve
- E. All of the above

Ans: D

Q3: A female patient with history of IBD came to the hospital complaining of abdominal tenderness, chills, and fever. After further examination the doctor diagnosed her with peritonitis as a result of perforation of the descending colon, the doctor wanted to check if any abscesses have formed elsewhere in the abdomen.

Which of these sites represent a potential site for abscess formation?

- A. Rectovesicular pouch
- B. Morrison's pouch
- C. Lesser sac
- D. Rectouterine pouch
- E. Left subphrenic space

Ans: D

Q4: A 57-year-old female came to the ER complaining of pain in her chest and right shoulder, after you checked all her vital signs and made sure she's not having an angina; you decided to do a per rectal examination. What are the structures that you can examine?

- A. Prostate
- B. Ampulla of ductus deferens
- C. Vagina
- D. Posterior wall of the bladder
- E. Left Kidney

Per rectal exam in male → prostate, seminal vesicles, vas deferens, bladder.
Per rectal exam in female → posterior wall of vagina.

Ans: C

Q5: Which of the following matches is incorrect regarding the sympathetic innervation of the GI tract?

- A. The stomach -> Greater splanchnic nerve
- B. The jejunum -> Lesser splanchnic nerve
- C. Ascending colon -> Least splanchnic nerve
- D. Rectum -> lumbar splanchnic nerves
- E. All the matches are correct

Ans: C

Q6: All of the following statements are incorrect except:

- A. The lower half of the anal canal is lined by scarpa's fascia
- B. An internal hemorrhoid is very painful
- C. The anal canal is surrounded laterally by fat pads
- D. The external anal sphincter is involuntary
- E. The white line determines the end of the upper half and the beginning of the lower half of the anal canal

Ans: C

Q7: Wrong about the ischioanal fossa:

- A. Crossed by the middle rectal nerve.
- B. Contains the pudendal canal on its lateral wall.
- C. The medial wall is formed the sloping levator ani muscle.
- D. The lateral wall is formed by the lower part of the obturator internus muscle.

Ans: A

Q8:Regarding the lower half of the anal canal, all of the following are correct, except:

- A. External hemorrhoids.
- B. Venous drainage to the systemic vein .
- C. Lymphatic drainage to the superficial inguinal lymph nodes.
- D. Visceral sensation.
- E. Origin from the ectoderm.

Ans: D

Q9: All of the following are correct regarding the sigmoid mesocolon, except:

- A. V shaped attachment.
- B. Its medial limb contains the superior rectal artery.
- C. Ends in front of the third sacral vertebrae.
- D. Contains branches from the superior & inferior mesenteric arteries.

Ans: D

Q10:By per-rectal examination, which of the following can't be palpated:

- A. Prostate gland.
- B. Vas deferens.
- C. Stone in the left ureter.
- D. Seminal vesicle.

Ans: C

Q1 1: Internal hernia occurs in all the following except:

- A. Retrocecal.
- B. Epiploic foramen.
- C. Intersigmoid.
- D. Rectovesical pouch.

Ans: D

Q13: All factors are related to the Anal canal below pectinate line except:

- A) It drains into inferior vena cava
- B) Lymphatic drainage into superficial inguinal lymph nodes
- C) Epithelium longitudinal anal column
- D) Sensitive to touch, stretch and temperature
- E) considered as external hemorrhoids

Ans: C

Q14: What is the Preganglionic sympathetic fiber that synapses into superior mesenteric ganglia?

- A) Lesser splanchnic nerves
- B) Greater splanchnic nerves
- C) Lowest splanchnic nerves
- D) S2,3,4 spinal nerves
- E) Lumber splanchnic nerves

Ans:A

رسالة من الفريق العلمي:

في غمرة الركض المتواصل وراء الطموح، وبين أكوام الكتب، والمحاضرات، وضغوط الامتحانات التي لا تنتهي، نجد أنفسنا أحياناً ننسى حتى أنفسنا من فرط الإرهاق. نعود بيوتنا مثقلين بضغطة نفسي لا يُطاق، لكن الخطيئة الكبرى هي أن نُفرِّغ هذا الغضب وهذا التعب في وجوه من انتظرونا بشوق.. في كلمة جافة، أو نظرة حادة، أو ضيق صدرٍ لا يليق بأبٍ وأب.

يارفيق السعي..

مهما بلغت ضغوطاتك، ومهما تملك التعب؛ تذكر أن الله سبحانه وتعالى لم يقرن عبادته بشيء كما قرنها ببر الوالدين: **{وَقَضَى رَبُّكَ أَلَّا تَعْبُدُوا إِلَّا إِيَّاهُ وَبِالْوَالِدَيْنِ إِحْسَانًا}**.

إن الموت حق، والرحيل قادمٌ لا محالة، وباب الجنة المفتوح أمامك الآن بوجودهما قد يُغلق في أي لحظة. حتى لا يستوطن الندم قلبك—وهو ألمٌ أقسى من أي حزن—لا تضيع دقيقة واحدة دون أن تكون قريباً منهما.

حتى وإن لم تكن شخصيتك معبرة أو عاطفية؛ اكسر هذا الحاجز لأجلهما فقط؛ اضحك معهما، اسعَ لفرحهما، واجعل لهما من يومك المزدحم ساعة أو ساعتين تكون لهما خالصتين، تاركاً كل هموم دراستك وعملك خارج العتبة.

واحذر أن يخدعك علمك! مهما حصدت من شهادات، ومهما بلغت من المعرفة، وصرت في تخصصك "عالم زمانك".. إياك أن تُشعر بقعة الضوء التي تقف فيها أنهم أقل منك، بل "اخفض لهما جناح الذل من الرحمة".

لازلت اذكر تلك النصيحة الثمينة للشيخ أنس كَرِيم حين قال ما معناه: **(اعمل حالك مش فاهم!)**.. نعم، حتى وإن كنت أعلم الناس في تخصصك وفي مجالك، ادخل عليهما وتظاهر بقلّة المعرفة، اسألهما واستشرهما، اشعرهما دائماً بأنك لا تزال ذاك الطفل الذي يحتاج إلى حنانهم وحكمتهم، وأن فضلهم بعد الله هو الأساس في كل ما وصلت إليه.

الحياة تمضي سريعة، والنجاح الحقيقي ليس شهادة تُعلّق على جدار، بل هو دعوة رضا تفتح لك أبواب التوفيق في الدنيا والآخرة. اجعلهم يشعرون بمكانتهم قبل أن يفوت الأوان.

For any feedback, scan the code or click on it.



Corrections from previous versions:

Versions	Slide # and Place of Error	Before Correction	After Correction
V0 → V1			
V1 → V2			