

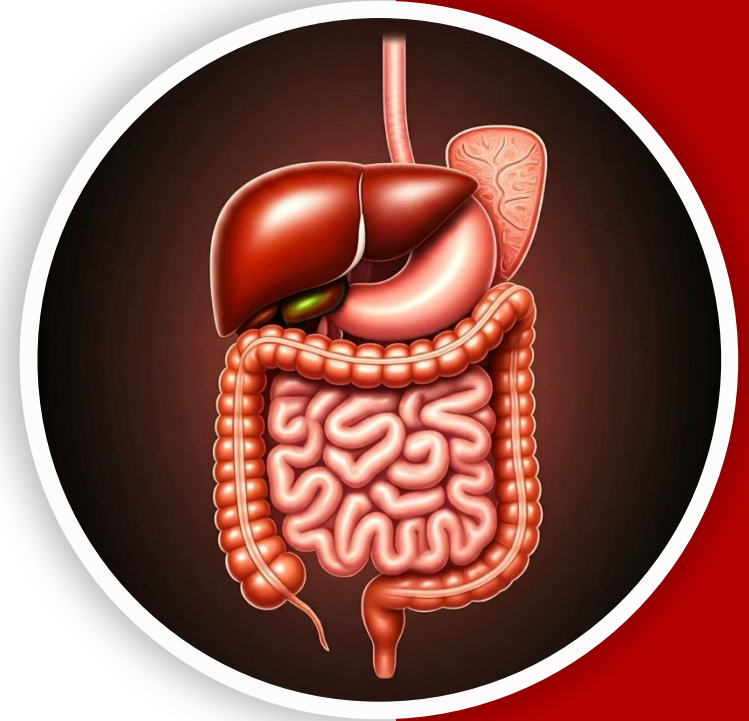
بِسْمِ اللّٰهِ الرَّحْمٰنِ الرَّحِیْمِ
(وَفَوْقَ كُلِّ ذِي عِلْمٍ عَلِيمٌ)



جراح

GIS Anatomy | FINAL 3

Rectum, Sigmoid Colon, Anal Canal & Posterior Abdominal Wall



Written by : Sara Al-Khateeb

Reviewed by : Shorouq Matakah
Tuqa Al-Soud

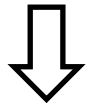L(3) - Rectum, Anal Canal

**The lecture mixed up the rectum and anal canal, so I reorganized the material to clearly separate them while keeping all the content covered.*

1 – large intestine overview

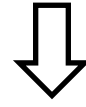
Parts of large intestine according to their anatomical site:

Abdomen




1. Cecum
2. Appendix
3. Ascending colon
4. Transverse colon
5. descending colon

★ **Pelvis**

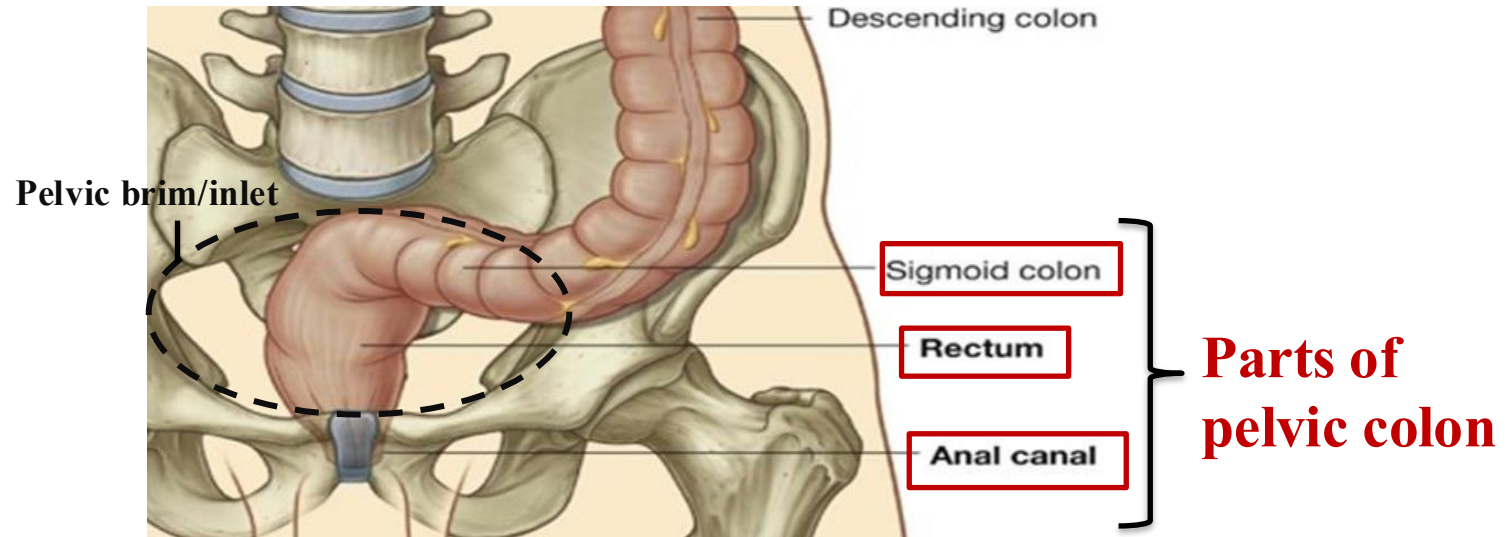


1. Sigmoid colon.
2. Rectum.
3. *upper part of Anal canal*

Perineum



1. lower part of Anal canal.

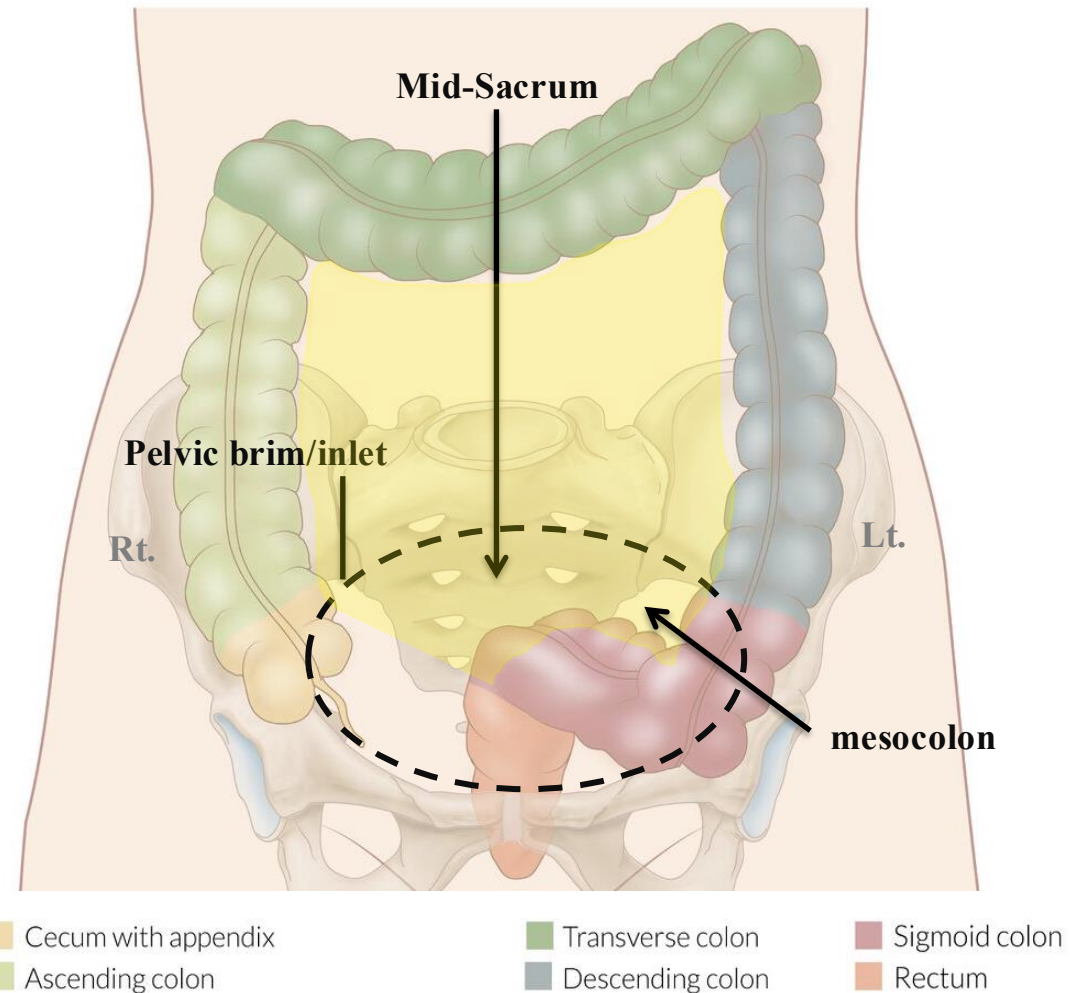


**Just to make things in context.*

2 – Sigmoid Colon

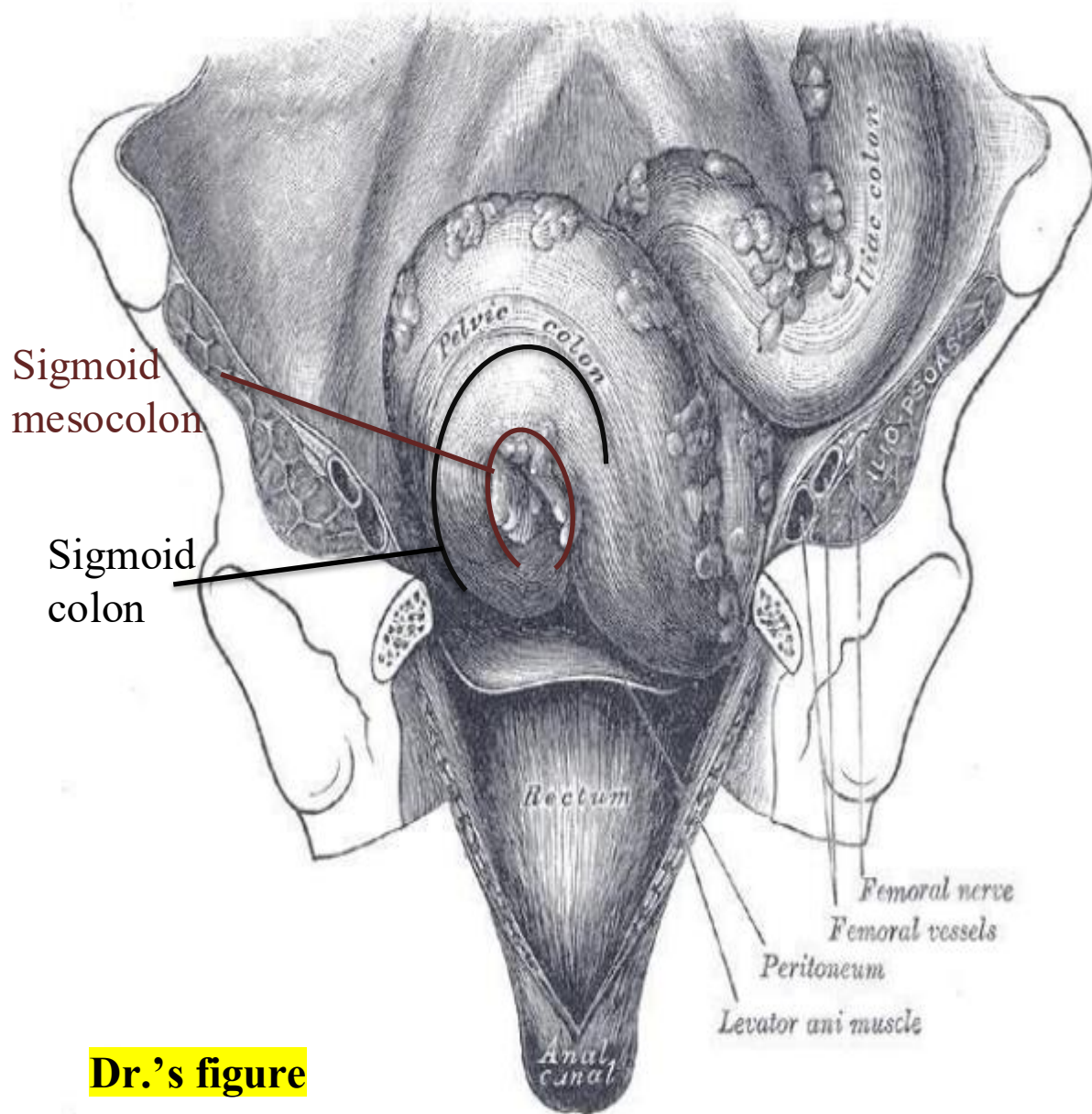
Location & Description:

- ✓ Length: ~38 cm (10–15 inches).
- ✓ It Lies in the pelvic cavity.
- ✓ It is an **Intraperitoneal** organ, Suspended by the **sigmoid mesocolon**.
- ✓ **Begins:** At the pelvic inlet on the left side, as a continuation of the descending colon.
- ✓ **Ends:** In the pelvis, anterior to the middle piece of the sacrum, where it continues as the rectum.
- ✓ The sigmoid colon is distinguished by the presence of **numerous** appendices epiploicae (tags of fat).

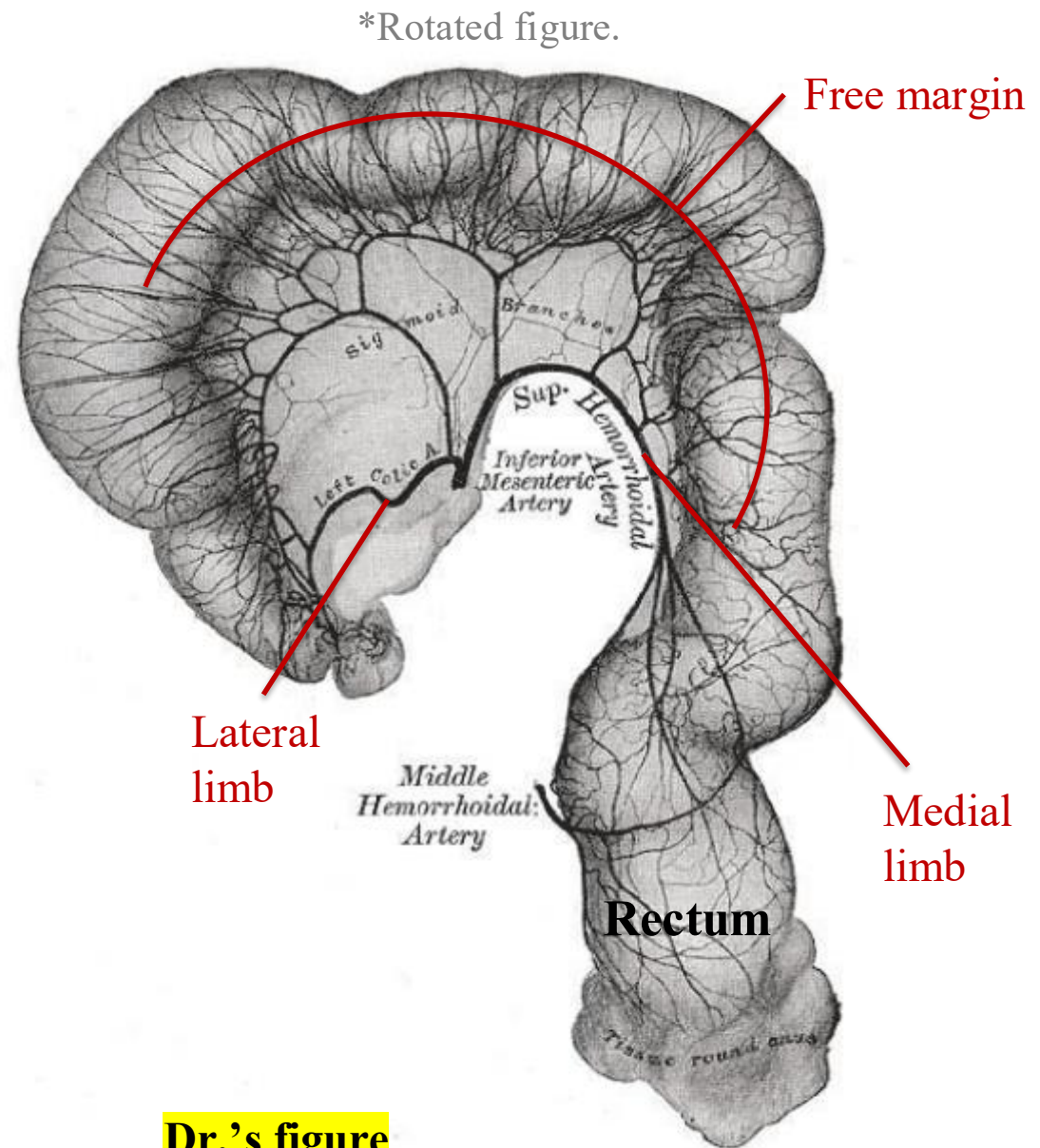


3 – Sigmoid Colon Parts

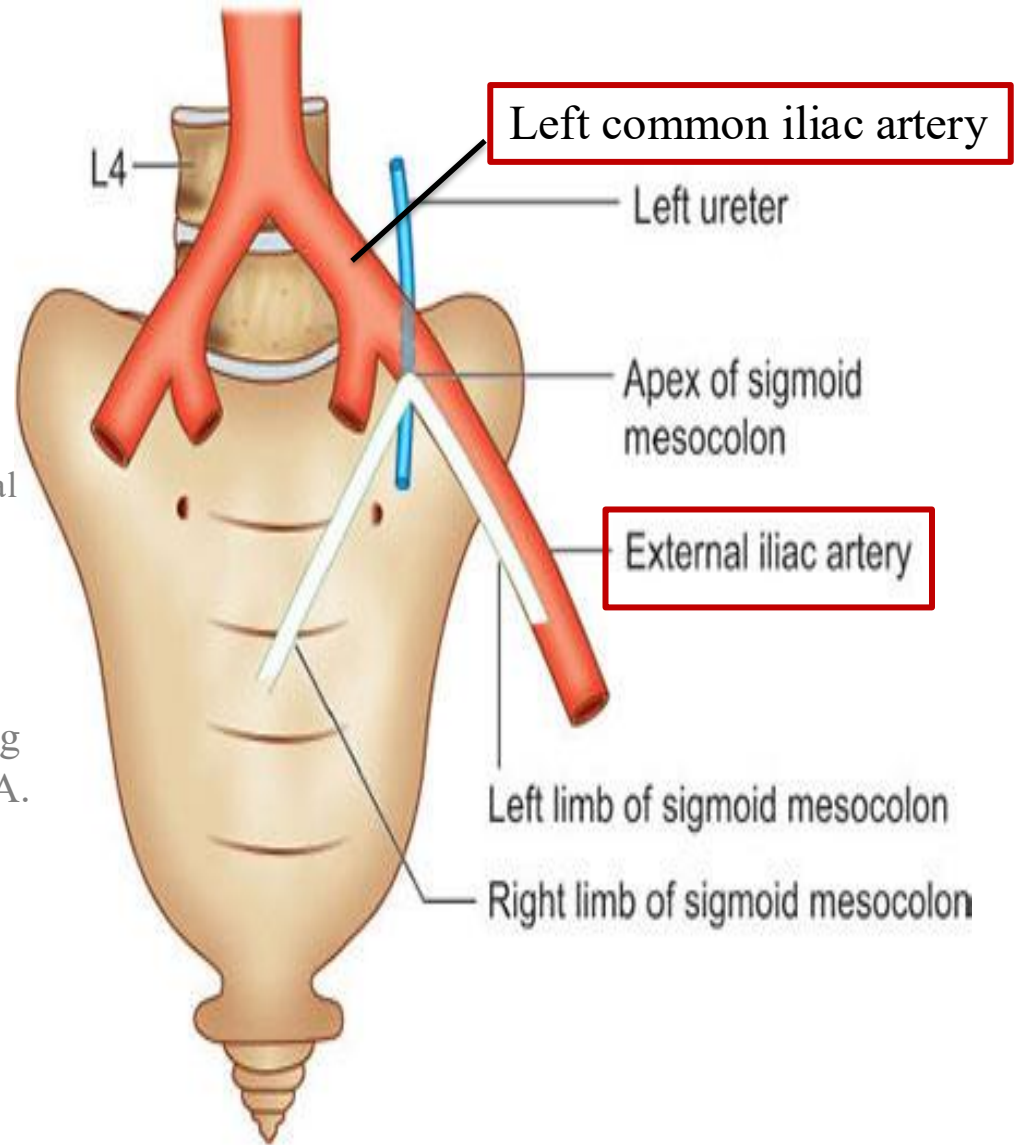
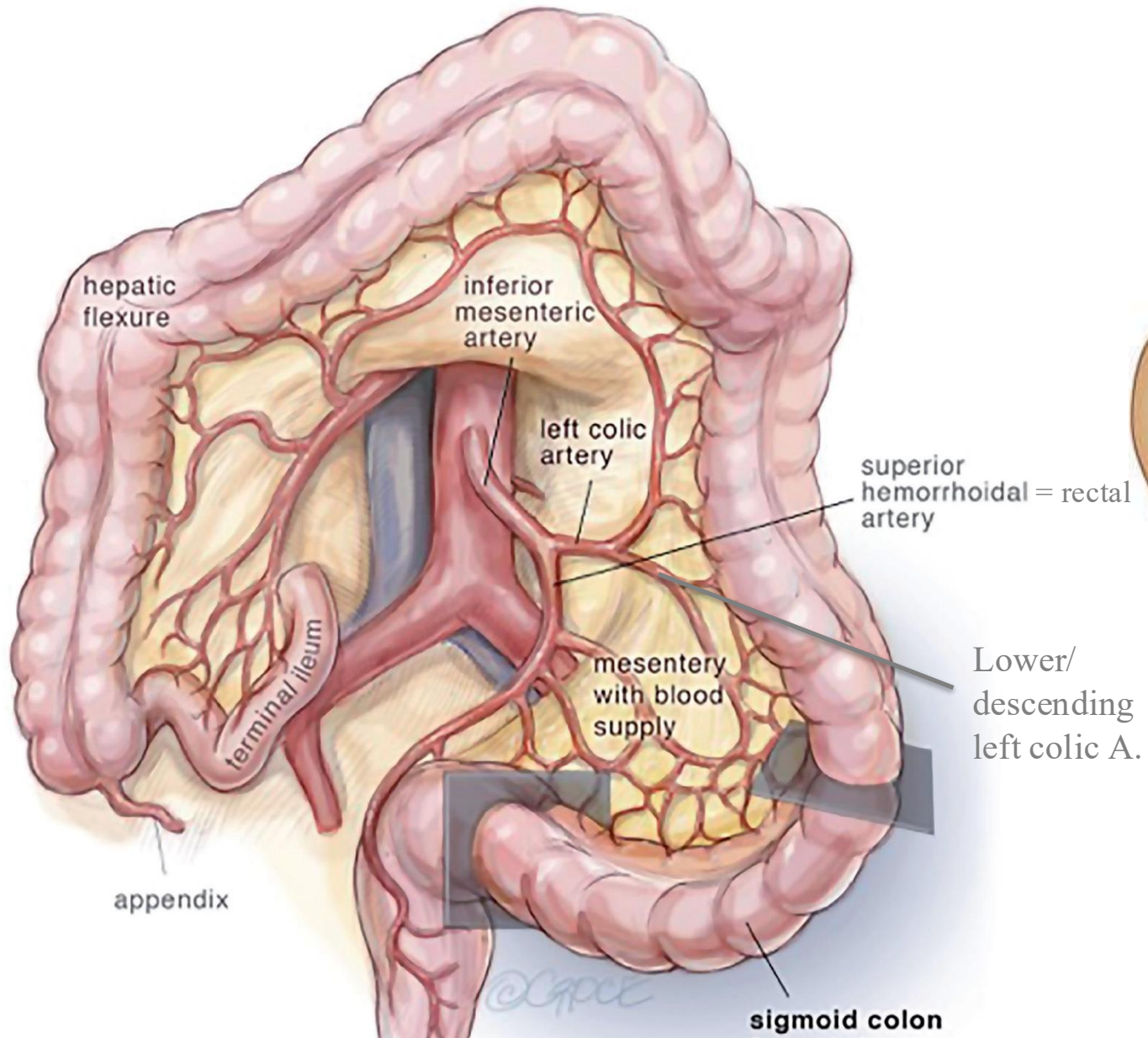
Component	Description
Lateral Limb	Contains the <i>lower</i> left colic artery (on the left side).
Medial Limb	Contains the inferior mesenteric artery , continuing as the superior rectal artery .
Free Margin	It contains the sigmoid colon (38cm), Extends from left pelvic inlet to the mid-sacrum .
Root	Mesenteric attachment. <ul style="list-style-type: none">○ Begins at the middle piece of the sacrum.○ Runs towards the left common iliac artery.○ Ends at the adventitia of the left external iliac artery.



Dr.'s figure

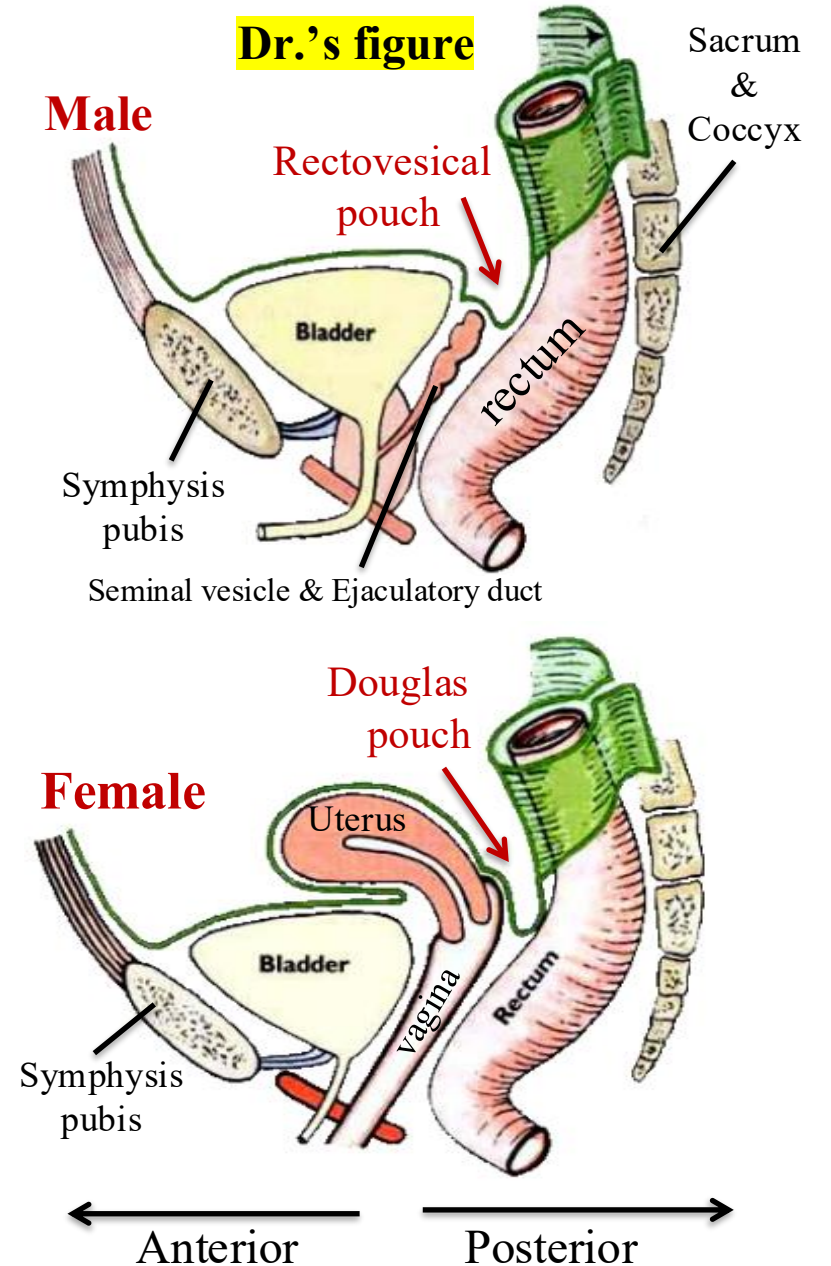


Dr.'s figure



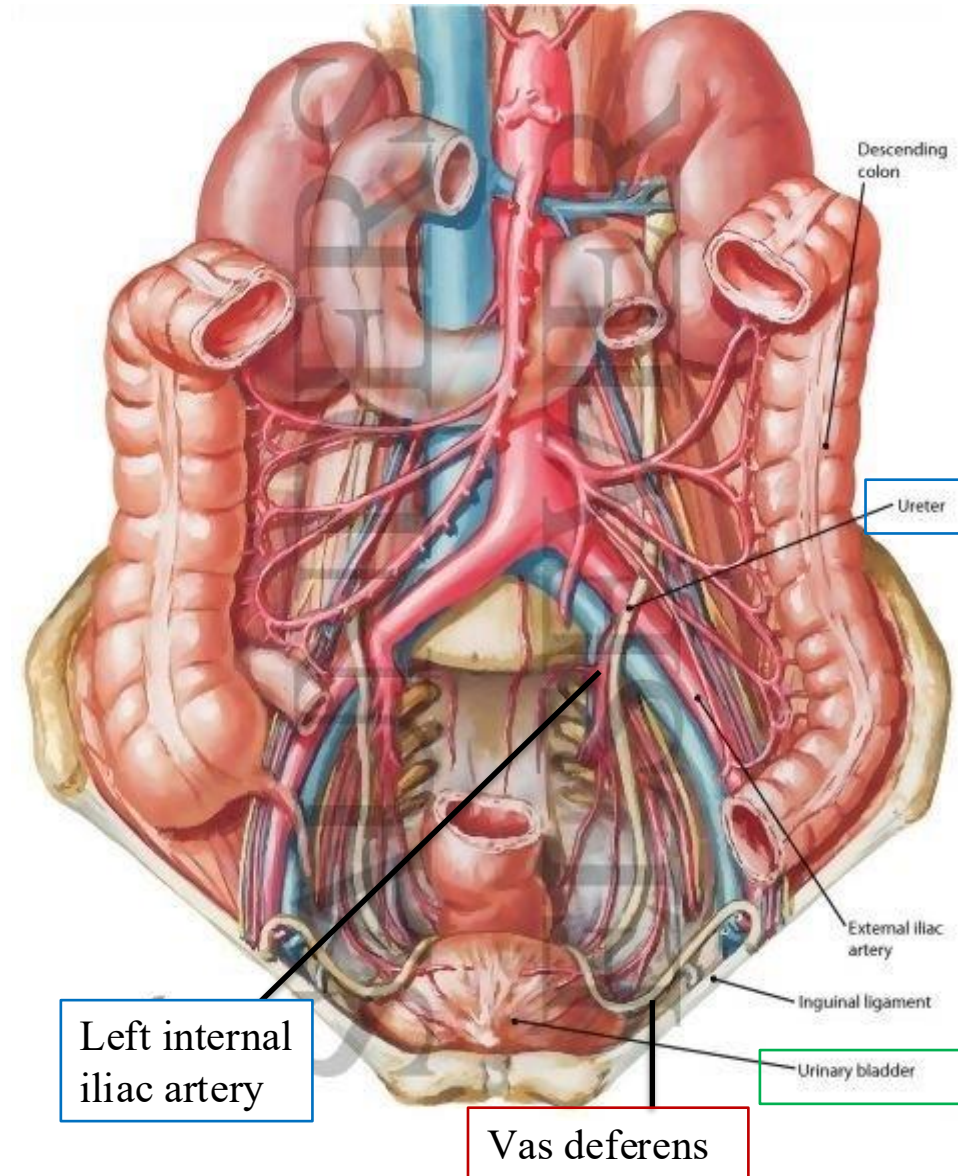
4 – Sigmoid Colon Site

Feature	Male	Female
Pelvic pouch	<ul style="list-style-type: none"> • Rectovesical pouch 	<ul style="list-style-type: none"> • Rectouterine pouch (Douglas pouch)
Located between	<ul style="list-style-type: none"> • Rectum and • bladder 	<ul style="list-style-type: none"> • Rectum and • uterus
Contains	<ul style="list-style-type: none"> • Sigmoid colon & Small intestine. 	
Structures beneath pouch	<ul style="list-style-type: none"> • Seminal vesicle • Ejaculatory duct which opens in prostatic urethra 	<ul style="list-style-type: none"> • vagina



5 – Sigmoid Colon Relations

Direction	Structures
*Left	<ol style="list-style-type: none"> 1. Left external iliac vessels 2. Lateral wall of the pelvis 3. Vas deferens (male) / Ovary (female)
Right & Superior	<ul style="list-style-type: none"> • Loops of small intestine
*Inferior	<ul style="list-style-type: none"> • Urinary bladder (male) / Uterus (female)
*Posterior	<ol style="list-style-type: none"> 1. Rectum 2. Sacrum 3. Coils of ileum 4. Sacral plexus of nerves 5. Left piriformis muscle 6. Left external iliac vessels 7. Left ureter 8. Left internal iliac artery



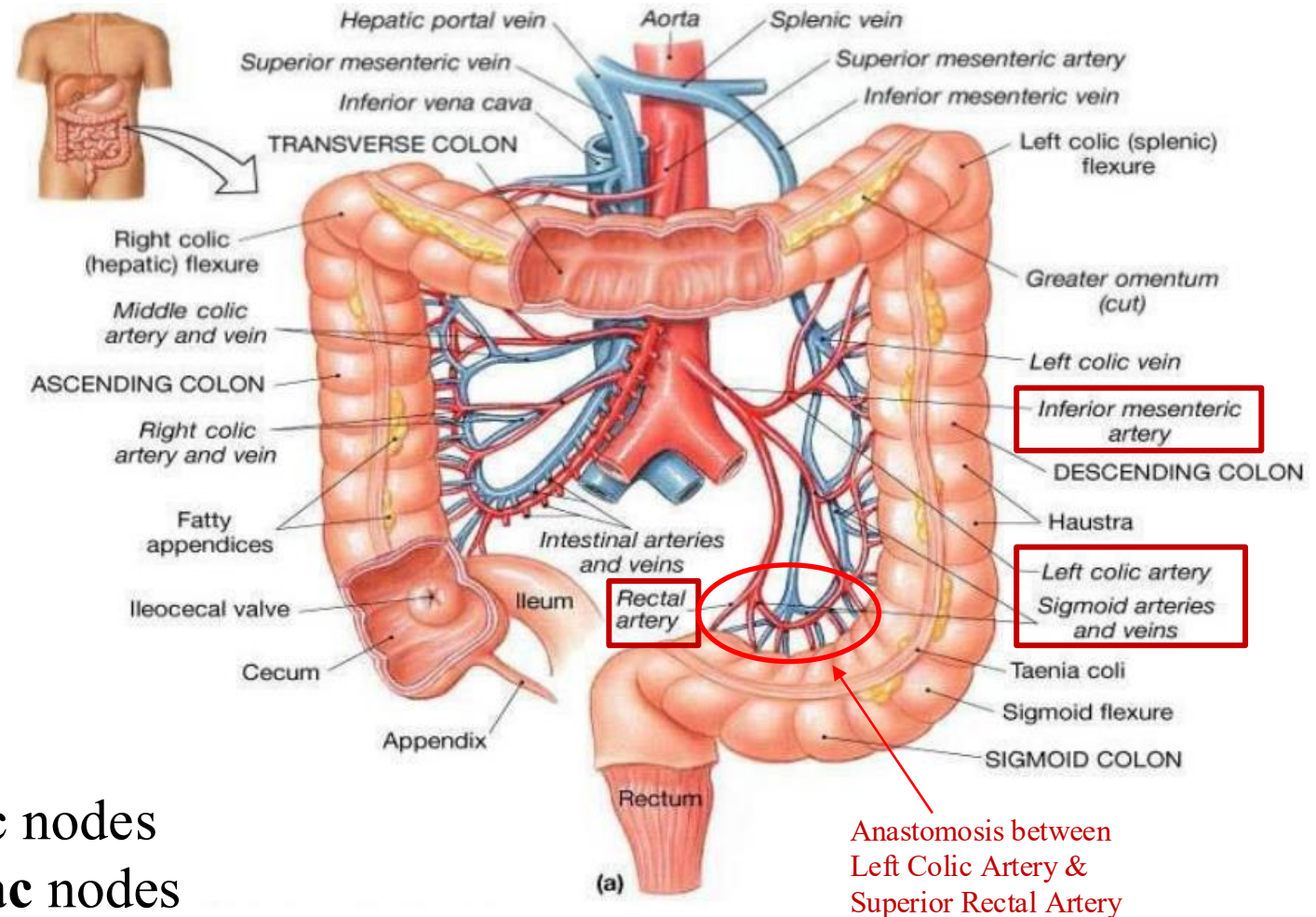
6 – Sigmoid Colon Blood supply & Lymphatics.

Blood supply:

- The sigmoid colon is part of the **hindgut** → So it is supplied by branches of the **inferior mesenteric artery (IMA)**.
- Branches from the IMA:
 1. Left colic artery
 2. Sigmoidal arteries
- **Arteries** lie **medial** to the veins; veins lie lateral to the arteries.

Lymphatics:

- Lymph drains into **inferior** mesenteric nodes → **superior** mesenteric nodes → **celiac** nodes → **cisterna chyli (in the abdominal Aorta)** → **Left thoracic duct.** – common pathway-



Dr.'s figure

7 – Sigmoid Colon Innervation.

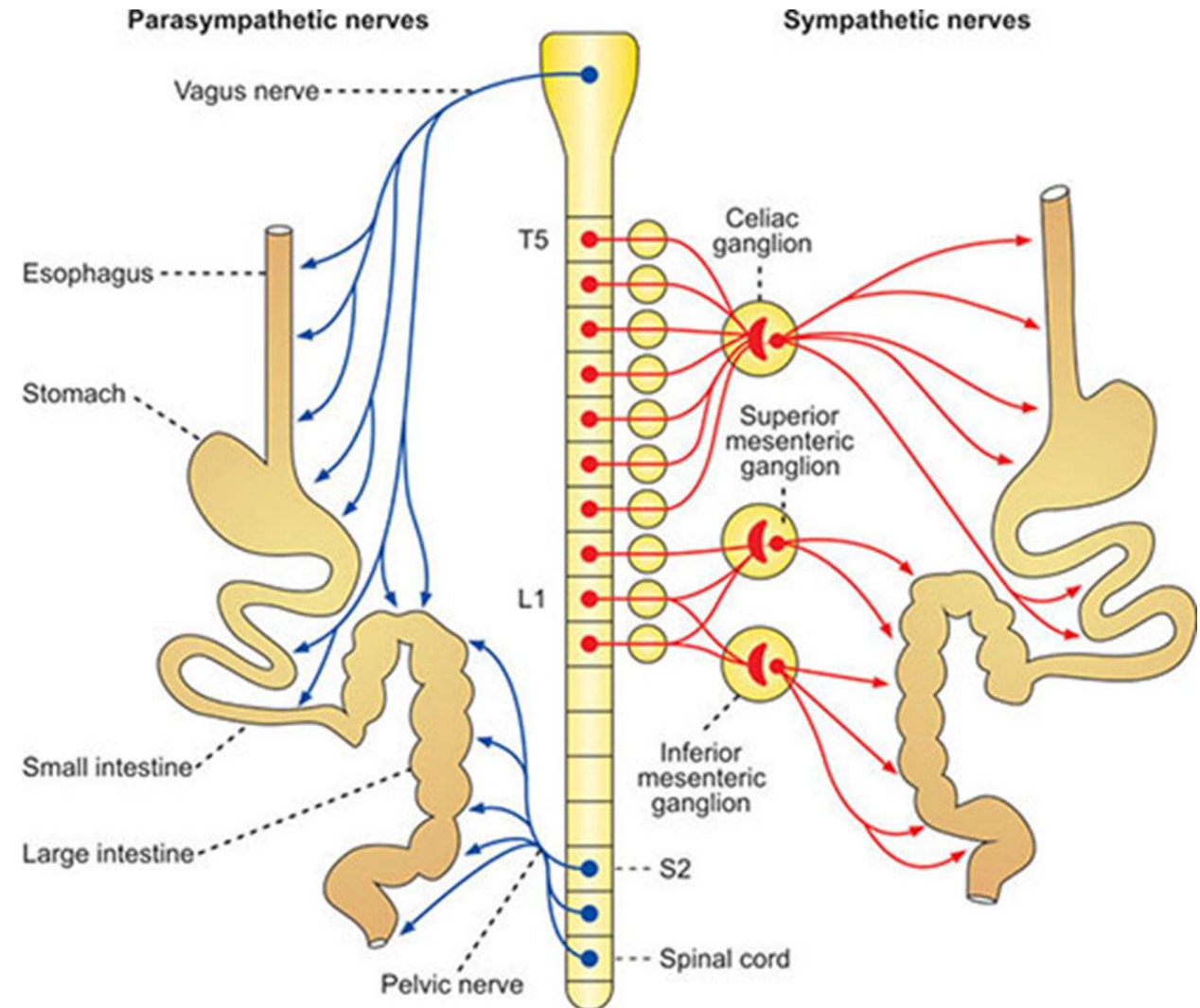
Sympathetic Supply:

- Originates from **L1–L2** segments.
- Preganglionic fibers travel via **Splanchnic N.**
- Synapse in the **inferior mesenteric ganglion.**
- Postganglionic fibers form the **hypogastric plexus**; This plexus carries both **sympathetic and parasympathetic fibers.**

Parasympathetic Supply:

- Originates from **S2, S3, S4.**

Recall: The vagus nerve provides parasympathetic innervation up to the left (distal) one-third of the transverse colon. Beyond this point, supply is taken over by the pelvic splanchnic nerves (S2–S4).

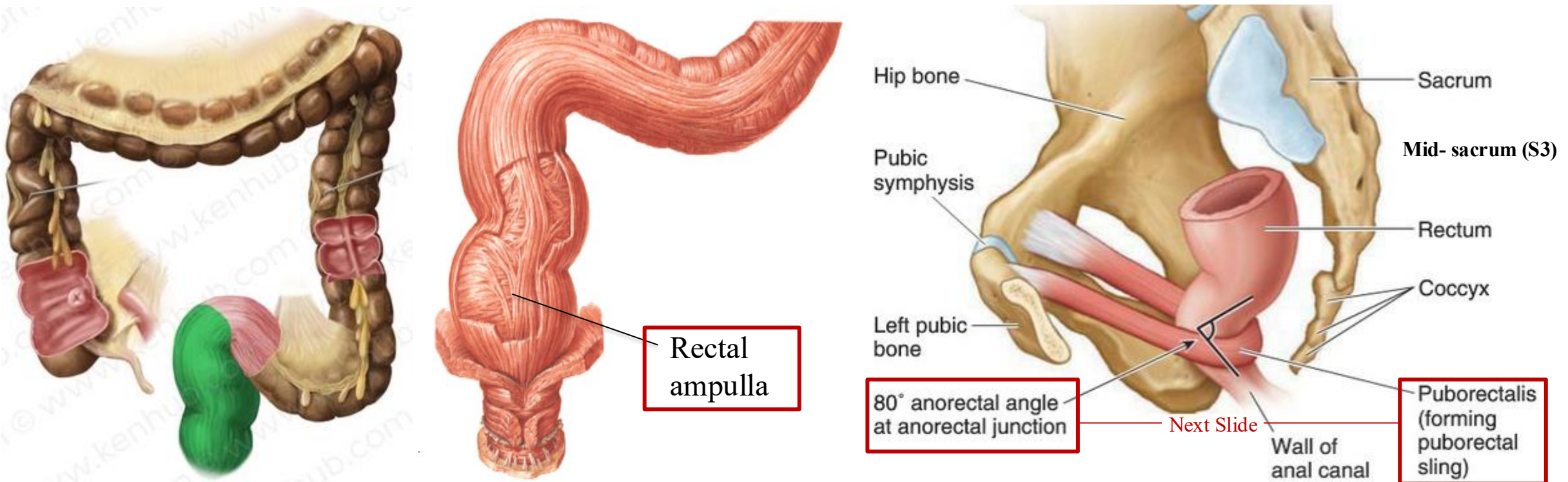


8 – The Rectum

- **Length:** 5 inches (13 cm)
- **Begins:** In front of the middle piece of the sacrum as a continuation of the sigmoid colon.
- **Ends:** About 1 inch beyond the tip of the coccyx. (then continues as Anal Canal)

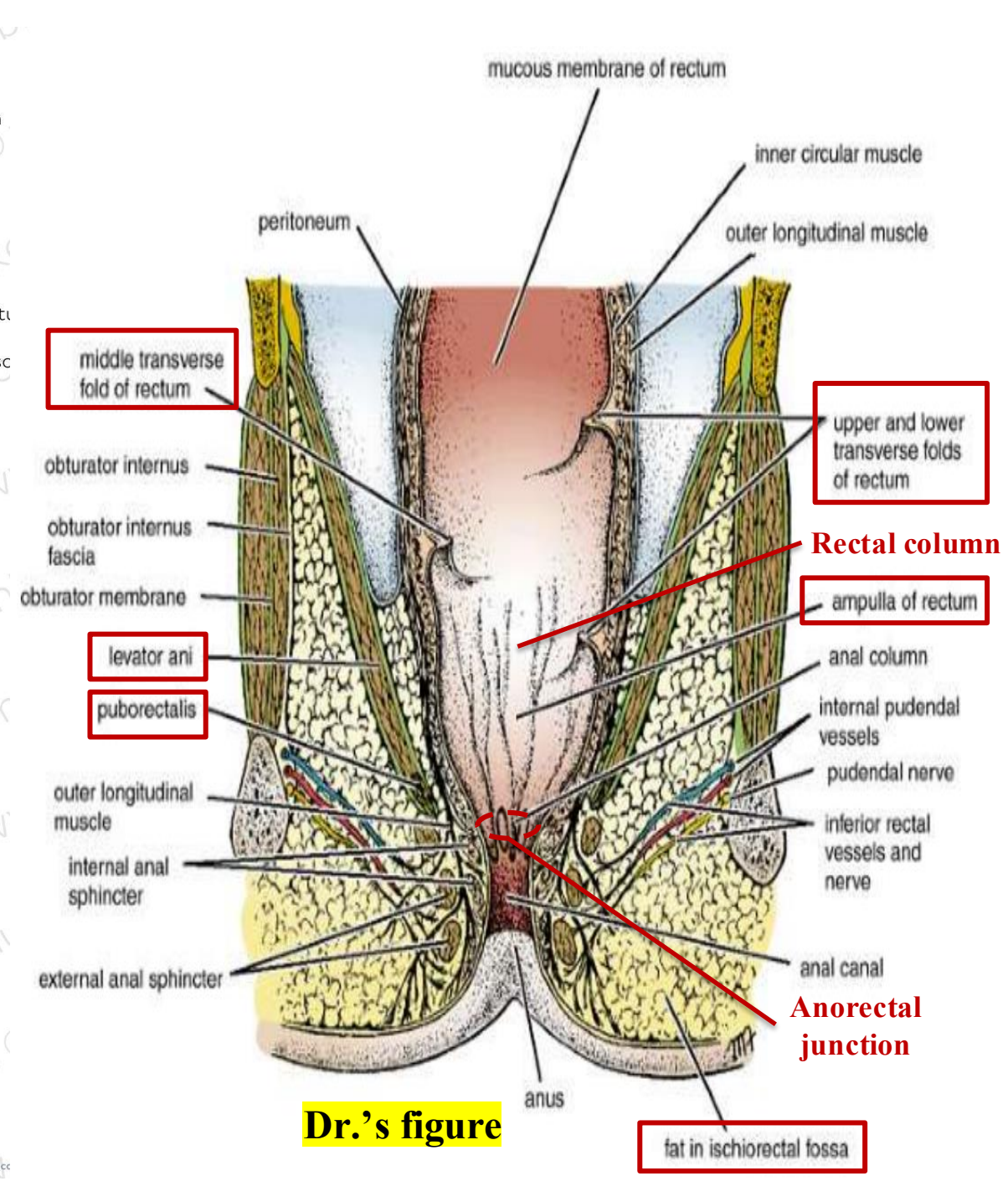
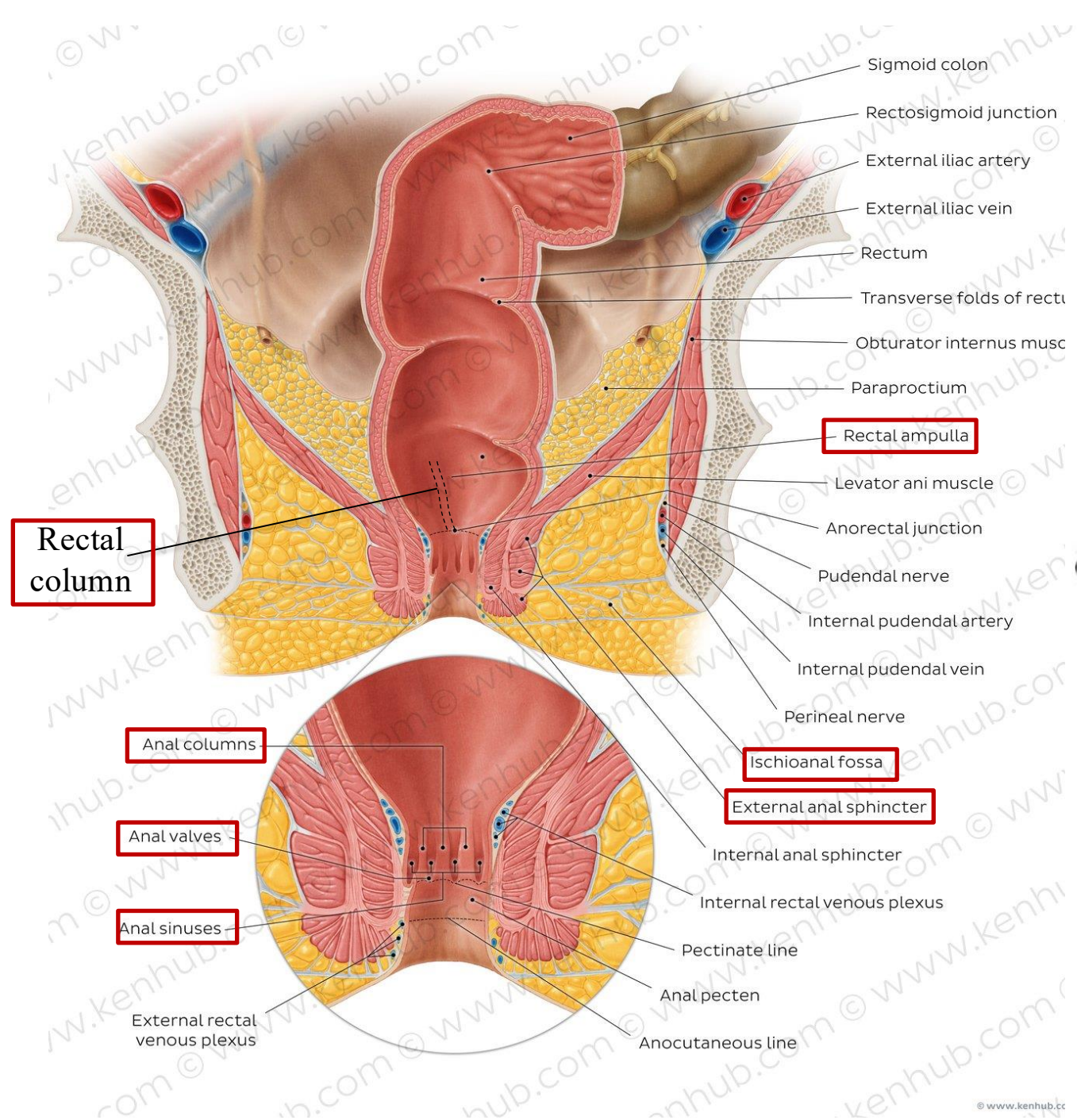
➤ Relate to Histology:

The **epithelium** of the rectum and colon is **simple columnar with goblet cells**.



8 – The Rectum

- The **puborectalis muscle**, a portion of the **levator ani**, forms a muscular **sling** around the **anorectal junction** - a junction between the rectum and the anal canal-. *Refer to slide(27)*
This sling plays a vital role in maintaining continence and **facilitating defecation**.
- The **lower part of the rectum** expands/dilates to form the **rectal ampulla**, which serves as a temporary **reservoir for stool**.
- On either side of the rectum and anal canal lies the **ischiorectal fossa**, a **fat-filled** space that allows for expansion of the rectum and anal canal during defecation. However, this fossa can become **infected**, leading to the formation of a ☹️ **perianal abscess** *Refer to slide(33)*.
- Internally, the rectum exhibits **longitudinal mucosal folds** known as **rectal columns**, which continue into the anal canal as **anal columns**. At the lower ends of these columns are **anal valves**, and the spaces/pockets between them form **anal sinuses**.



8 – The Rectum

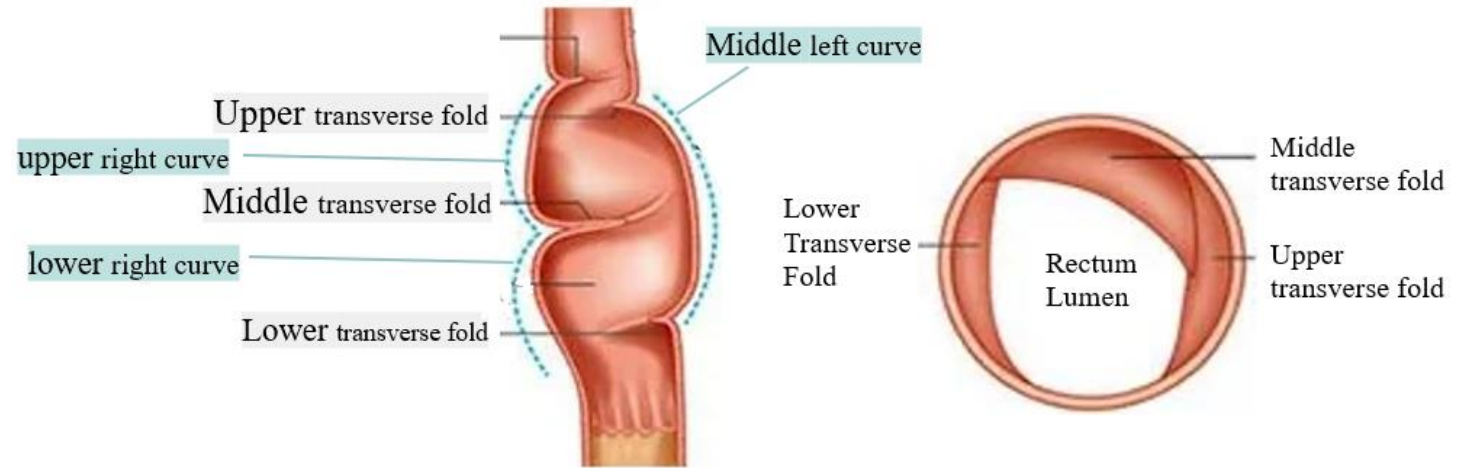
- **Transverse folds:** (*valves of Houston*)

Mucosal folds inside the rectum,

There are usually **three** folds:

- **Upper fold** (concave to the left)
- **Middle fold** (concave to the right)
- **lower fold** (concave to the left)

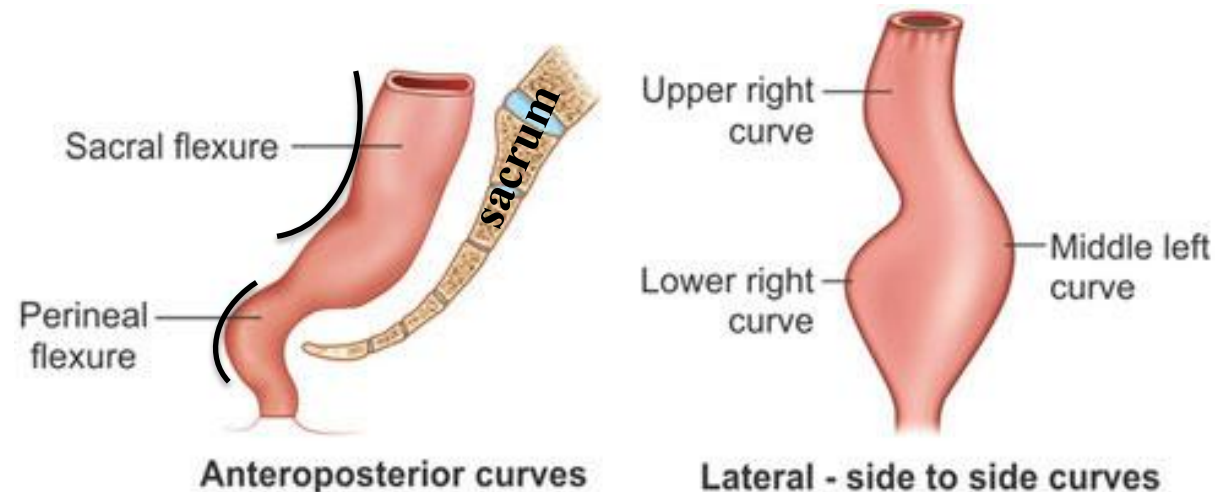
They are the reason behind the rectal concavities on both sides.



- **Rectal concavities:**

The rectum follows the **anterior concavity of the sacrum**. When viewed from the side:

- **Left view:** two lateral concavities.
- **Right view:** one concavity.



9 – Rectal Examination

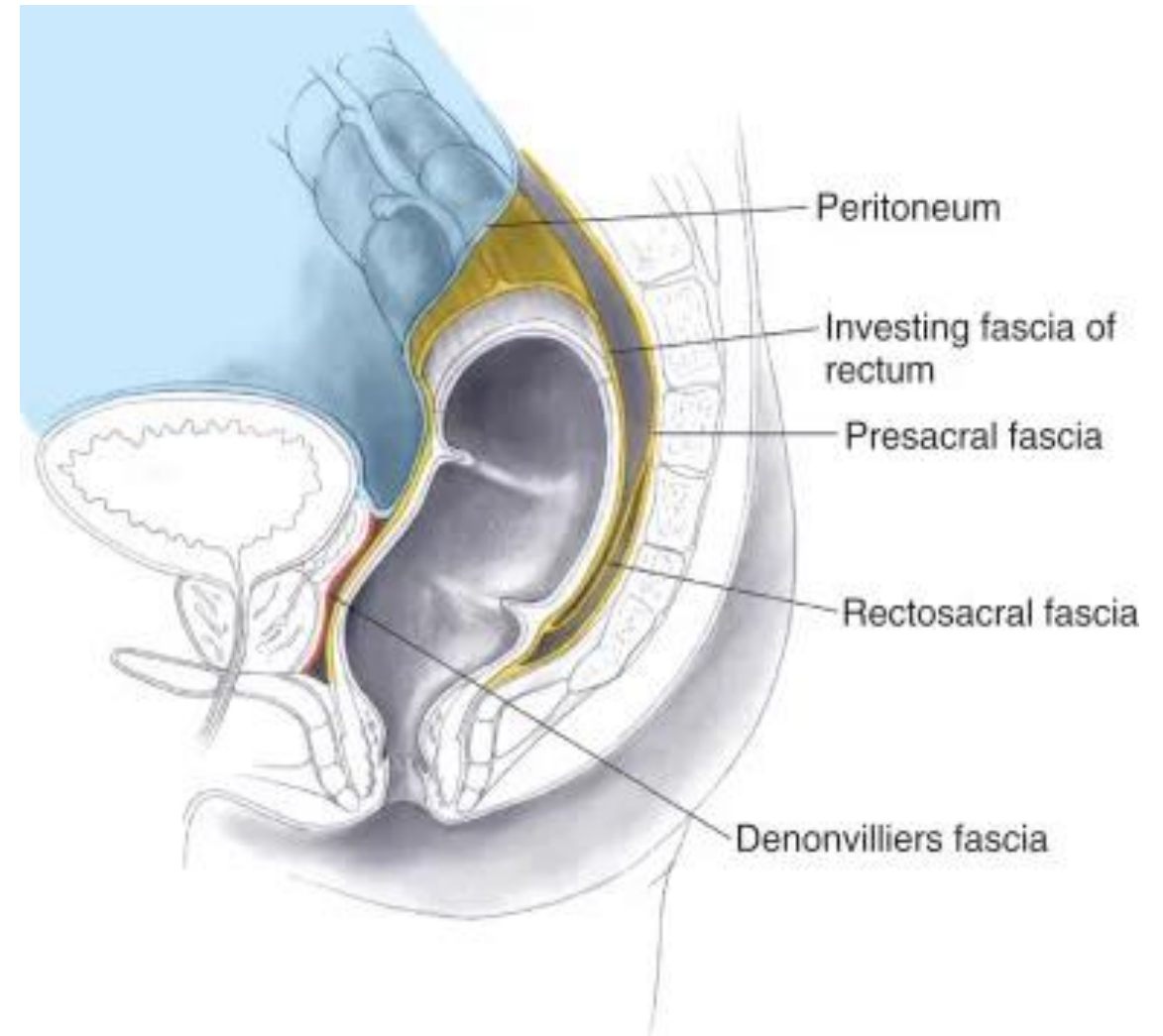
A **Bare (digital) rectal examination** is performed by inserting the examiner's finger into the anal canal and rectum to **palpate the anterior wall of the rectum**. This allows assessment of structures such as the **urinary bladder, seminal vesicles, vas deferens**, and most importantly, the **prostate gland** in males.

This examination is especially important in **men over 50 years**, as the **prostate normally becomes firm with age due to ☹️ fibrosis**, and in **cases of ☹️ malignancy**, it may feel **very hard or irregular**. A firm or hard prostate should prompt further investigation.

10 – Rectal peritoneum

The **rectum** is anatomically divided into **three parts** based on its **peritoneal covering**:

1. The **upper third** is covered by peritoneum **anteriorly and on both lateral sides**, similar to the descending colon.
2. The **middle third** is covered by peritoneum **only on the anterior surface**, forming the rectouterine pouch (pouch of Douglas) in females and the rectovesical pouch in males.
3. The **lower third** of the rectum is **completely devoid of peritoneal covering**.



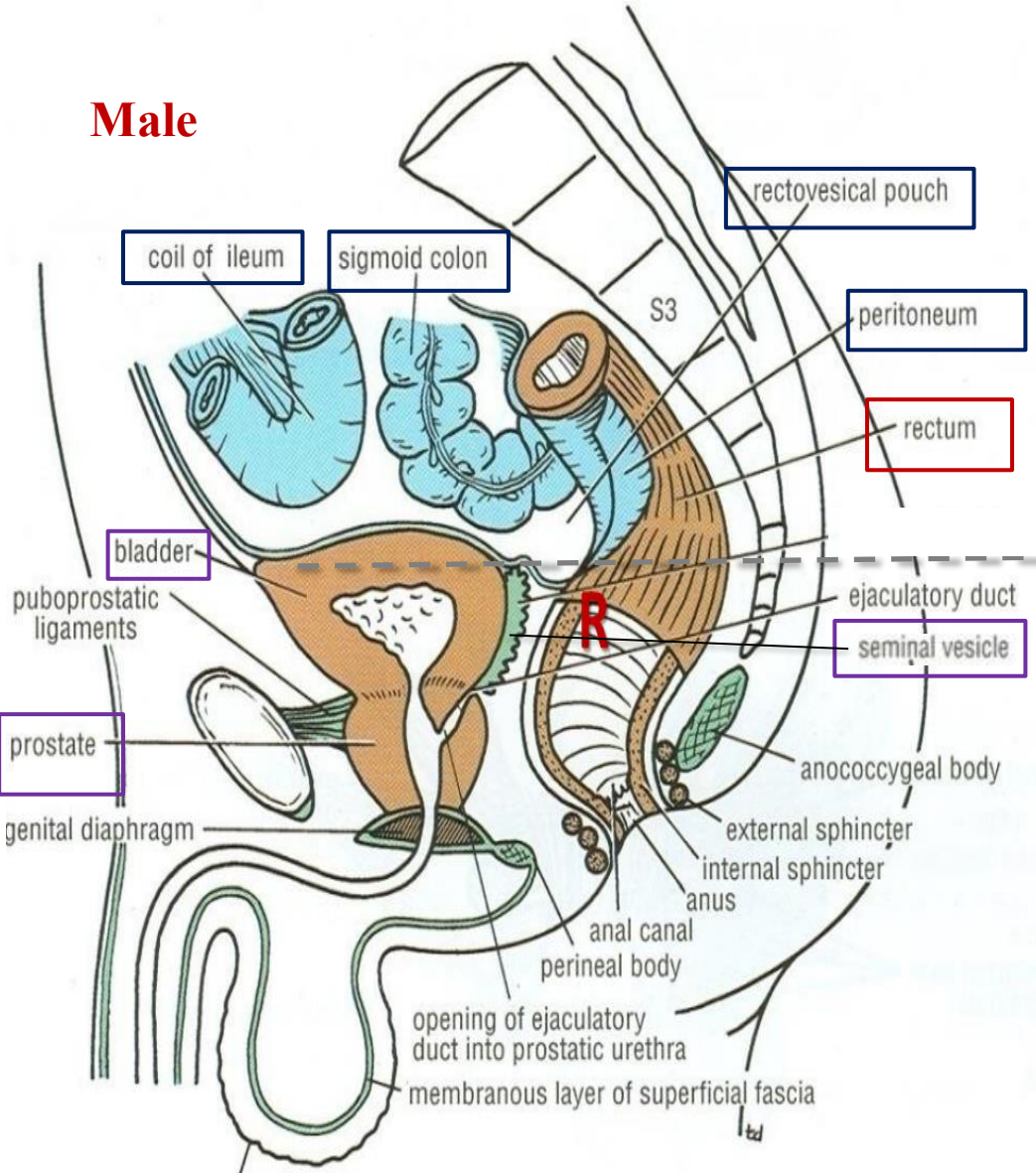
11 – Rectal relations

Aspect	Level	Peritoneal Covering	Structures in Contact
Anterior	Male - Upper 2/3	Covered by peritoneum	<ul style="list-style-type: none"> - Sigmoid colon (in rectovesical pouch) - Coils of ileum (in rectovesical pouch)
	Male - Lower 1/3	Devoid of peritoneum	<ul style="list-style-type: none"> - Urinary bladder - Vas deferens - Seminal vesicles (on each side) - Prostate
	Female - Upper 2/3	Covered by peritoneum	<ul style="list-style-type: none"> - Sigmoid colon (in rectouterine pouch) - Coils of ileum (in rectouterine pouch)
	Female - Lower 1/3	Devoid of peritoneum	<ul style="list-style-type: none"> - Posterior surface of the vagina
Posterior	Entire rectum	—	<ul style="list-style-type: none"> - Sacrum & coccyx - Piriformis, Coccygeus & Levator ani Muscles. - Sacral plexus - Sympathetic trunks - Lateral sacral arteries

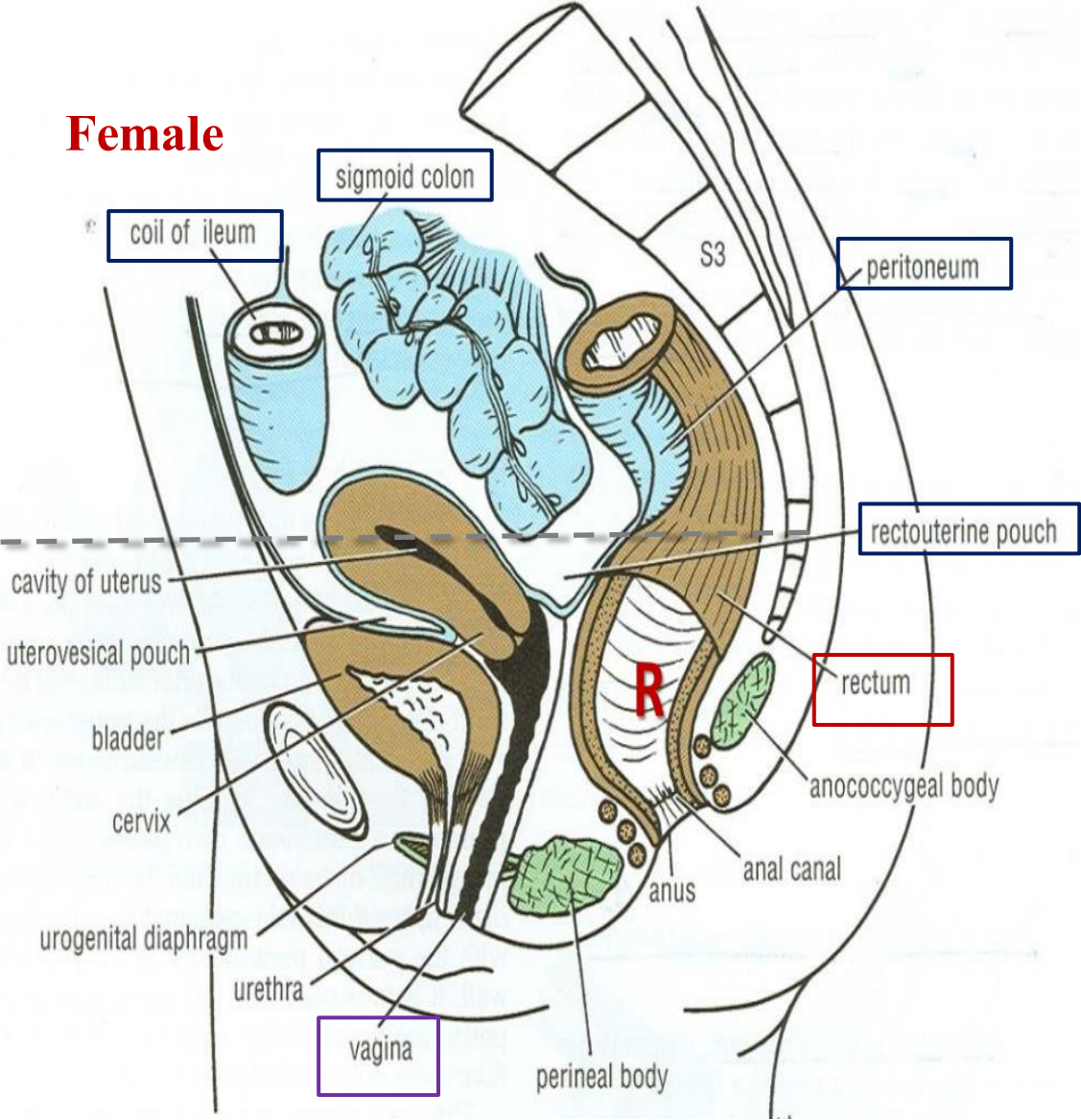
Anteriorly:

Dr.'s figure

Male



Female

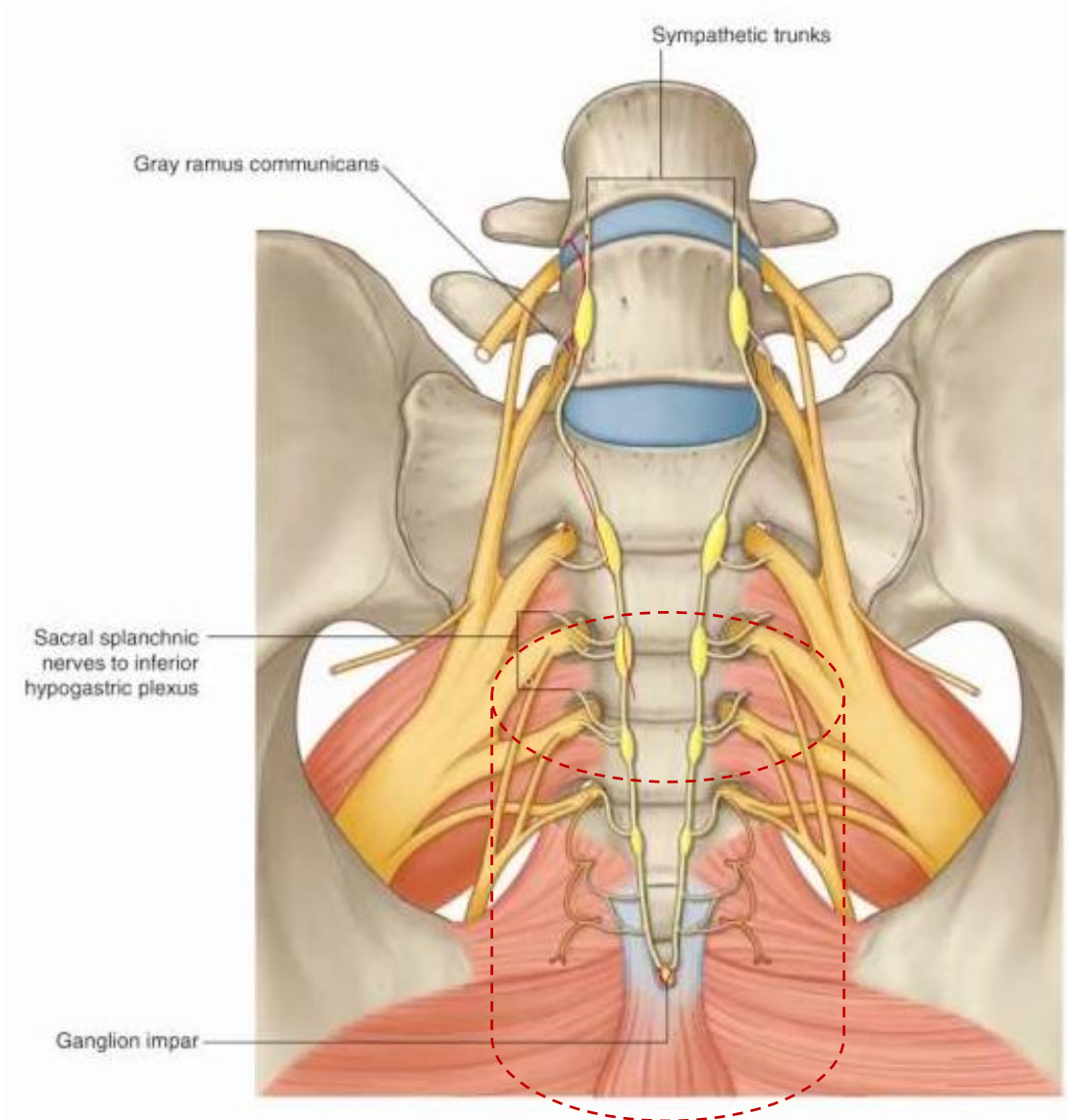


Upper 2/3

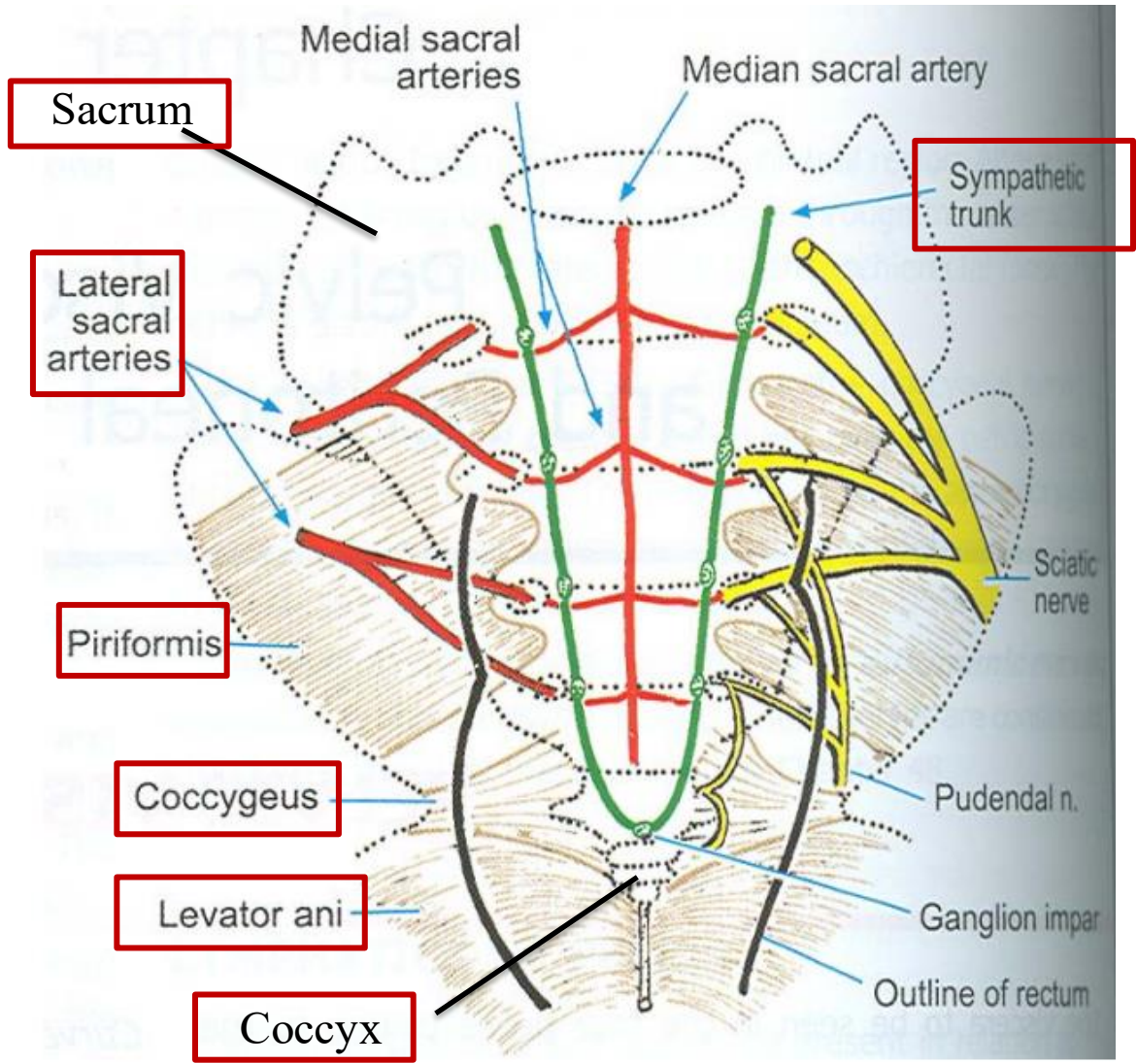
*common relations!

lower 1/3

Posteriorly:



Imagine the rectum



12 – Rectal Blood supply

Arterial Supply:

1. Superior Rectal Artery

- Continuation of the **inferior mesenteric artery**.
- It enters the pelvis by descending in the root of the sigmoid mesocolon and divides into right and left branches, which pierce the muscular coat and supply the mucous membrane.
- **Supplies:** Rectum and **upper part** of the anal canal.

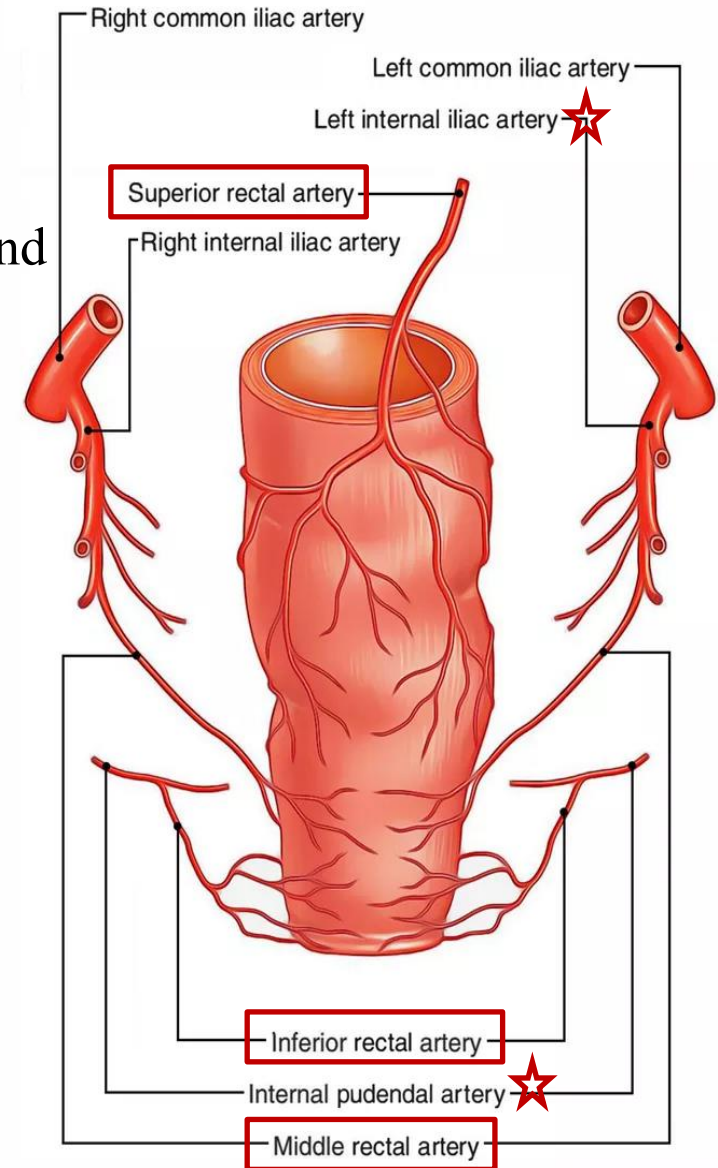
2. Middle Rectal Artery

- Branch of the **internal iliac artery**.
- **Supplies:** Rectum & **Lower part** of the anal canal.

3. Inferior Rectal Artery

- Branch of the **internal pudendal artery**
(from internal iliac A.)
- **Supplies:** Rectum & **Lower part** of the anal canal.

There are **anastomoses** between these arteries, ensuring collateral circulation.



12 – Rectal Blood supply

Venous Drainage of the Rectum

1. Superior Rectal vein

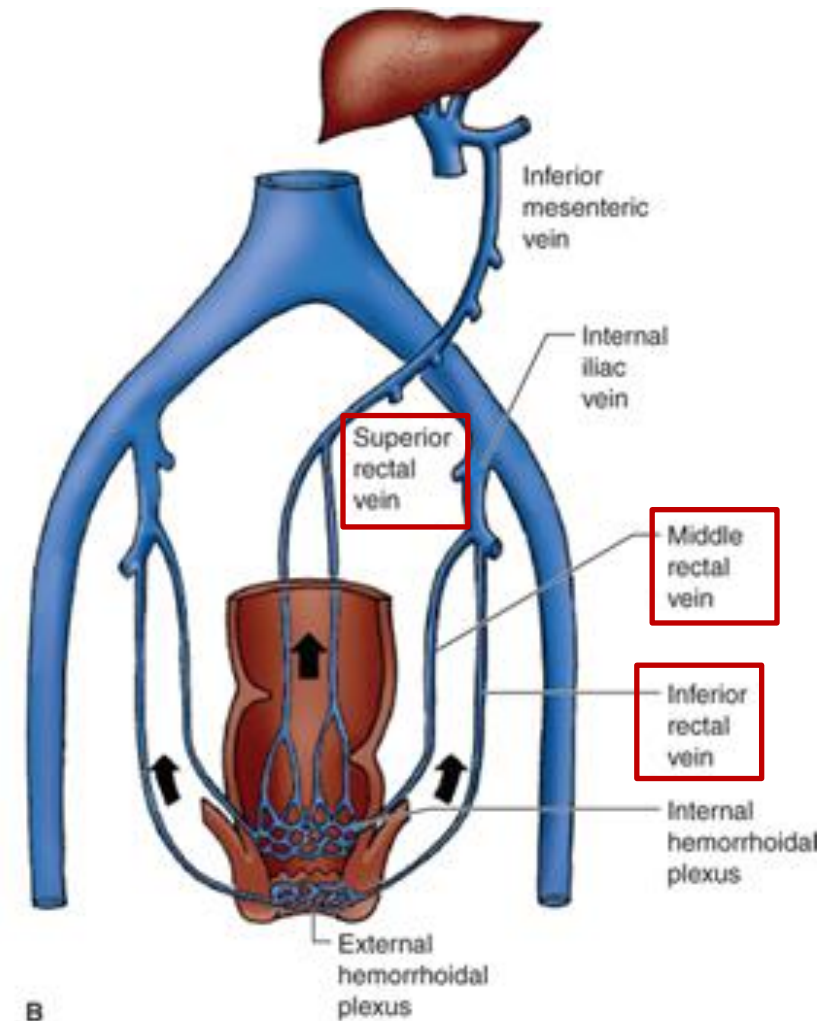
- Drains into the **inferior mesenteric vein** which drains into splenic vein **then into the portal vein.**
(portal circulation)

2. Middle Rectal Artery

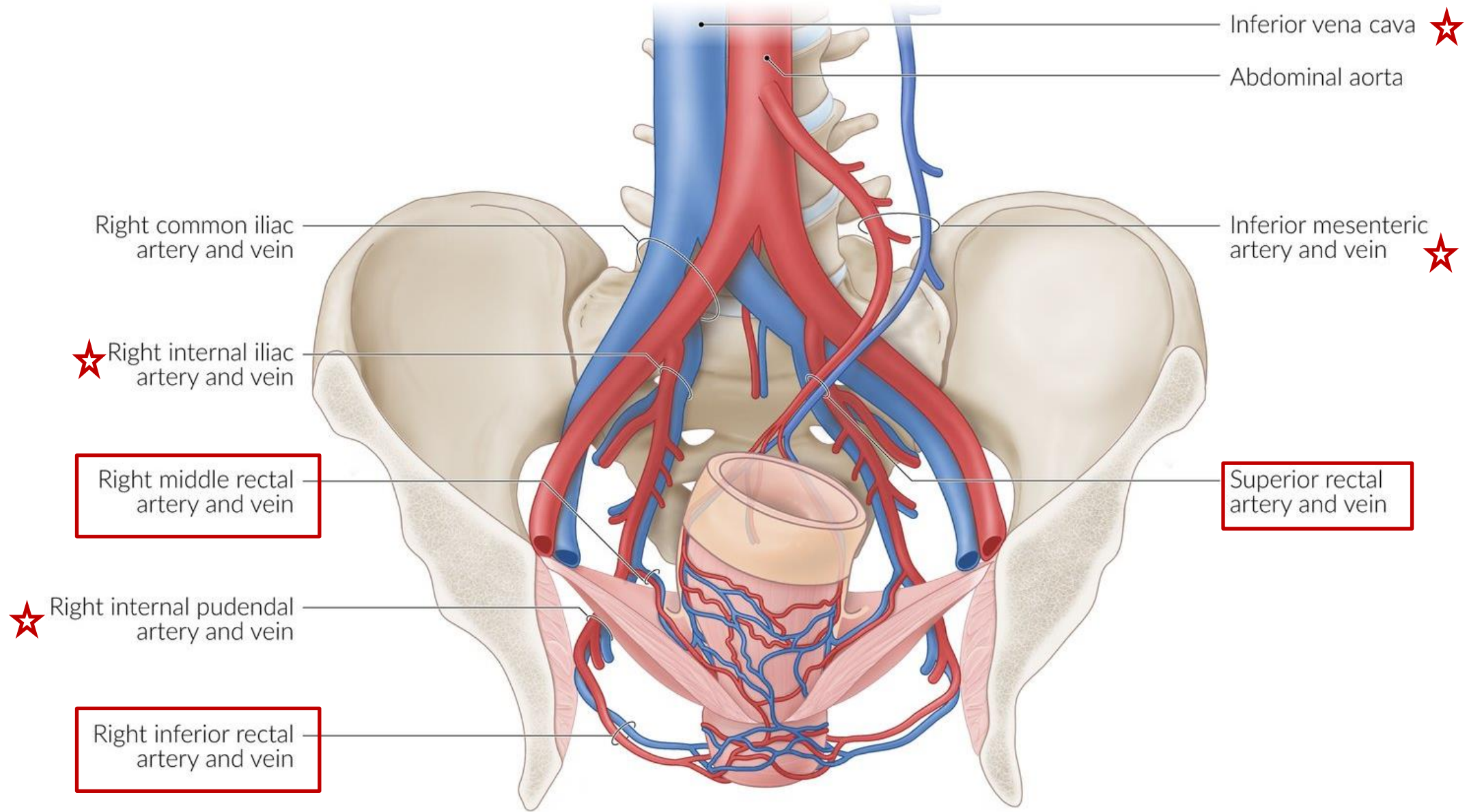
- It drains into internal iliac vein **then into the IVC.**
(systemic circulation)

3. Inferior Rectal Artery

- It drains into internal pudendal vein, a branch of internal iliac vein **then into the IVC.**
(systemic circulation)



*There is a **porto-systemic anastomosis** between these venous systems.



Inferior vena cava ☆

Abdominal aorta

Right common iliac artery and vein

Inferior mesenteric artery and vein ☆

☆ Right internal iliac artery and vein

Right middle rectal artery and vein

Superior rectal artery and vein

☆ Right internal pudendal artery and vein

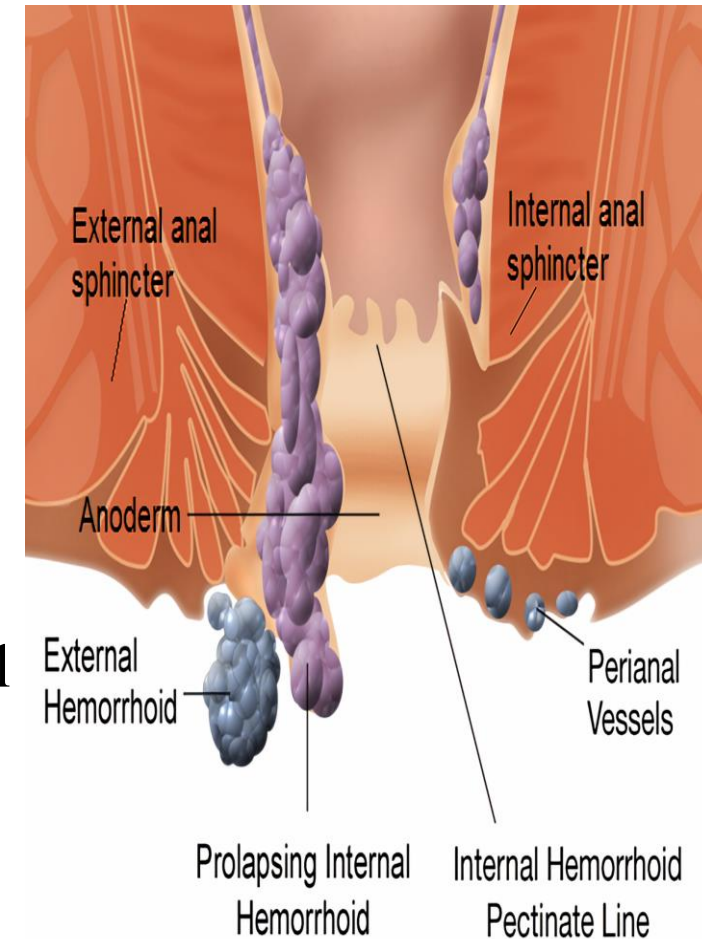
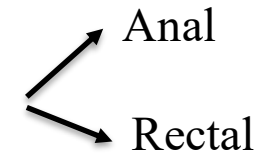
Right inferior rectal artery and vein

Pay attention to this topic ;) **13-Hemorrhoids (Piles)**

Definition: Dilated, tortuous, and engorged veins in the venous plexus.

Types:

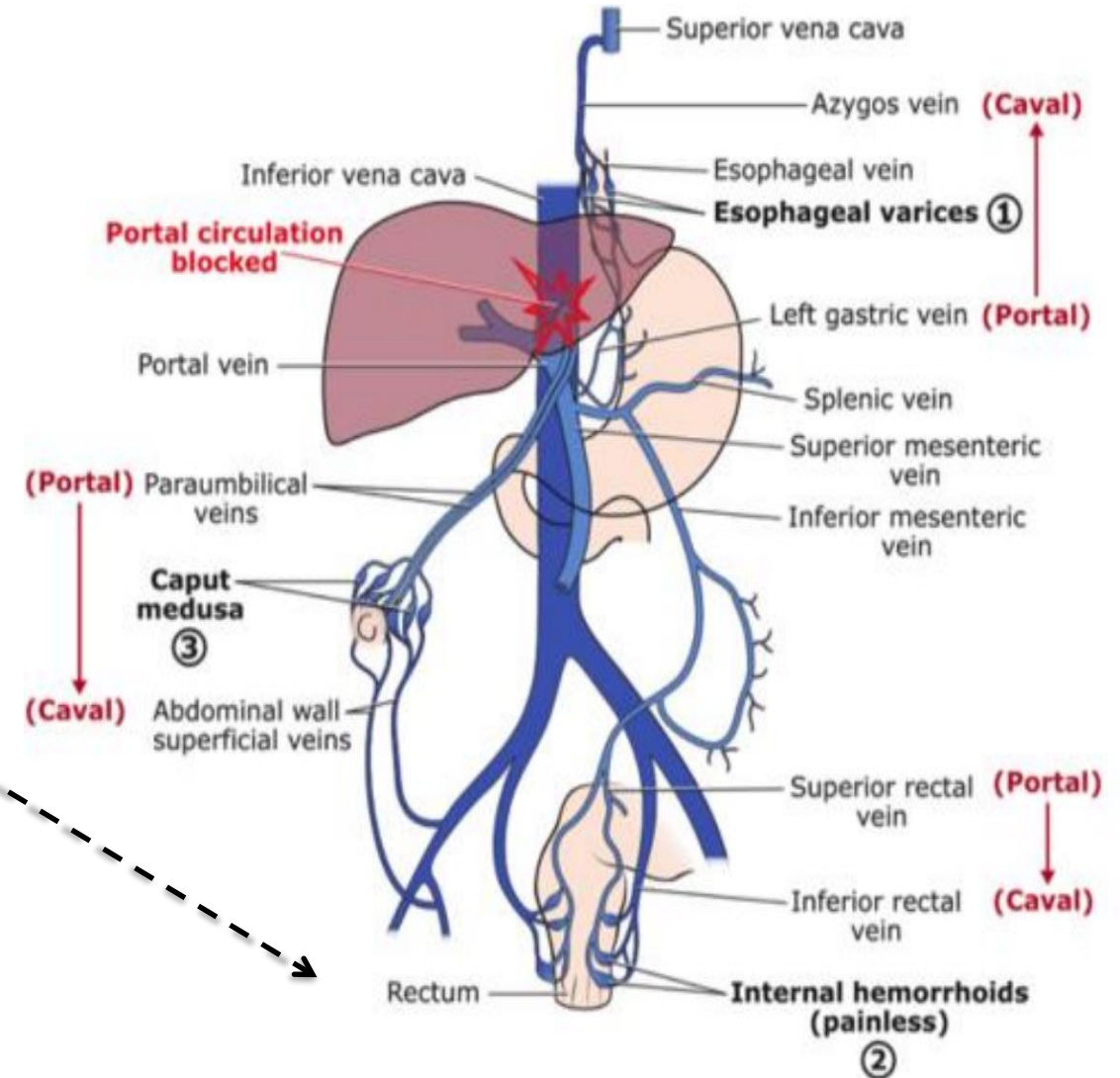
- **Internal Hemorrhoids:**
 - Involve the **superior rectal vein**
 - Located in the **upper anal canal**
 - Typically, **painless** (innervated by autonomic nerves)
 - Become painful only in **Stage IV**, when prolapsed with defecation outside the anus.
- **External Hemorrhoids:**
 - **Mainly involve the inferior rectal vein**, but the middle rectal artery may also contribute
 - Located in the **lower anal canal**
 - Located **subcutaneously**
 - Always **painful /tender** (somatic innervation via **S4**) & they may cause bleeding.



13-Hemorrhoids (Piles)

Causes of Hemorrhoids:

- Congenital weakness of venous walls.
- Chronic constipation or chronic cough.
- Pregnancy.
- **Portal hypertension** (increased flow via porto-systemic anastomosis).
- Rectal cancer (increasing pressure on rectal veins)



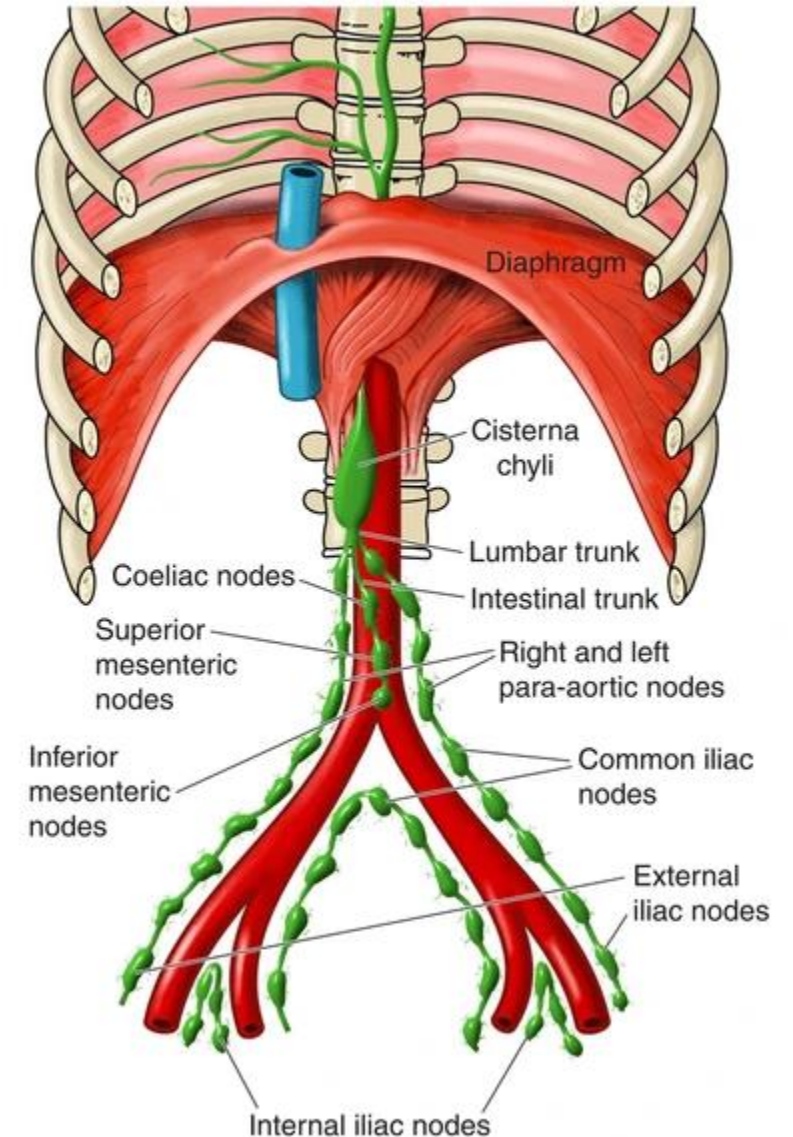
14 – Lymphatics & innervation of the rectum

Lymphatic Drainage:

- **Rectum & Upper Part of Anal Canal**
 - Drain into pre-aortic lymph nodes
 - Pathway: Inferior mesenteric nodes → Superior mesenteric nodes → Celiac nodes → Thoracic duct.
- **Lower Half of Anal Canal**
 - Drain into superficial inguinal lymph nodes
 - Located in the femoral triangle

Nerve Supply:

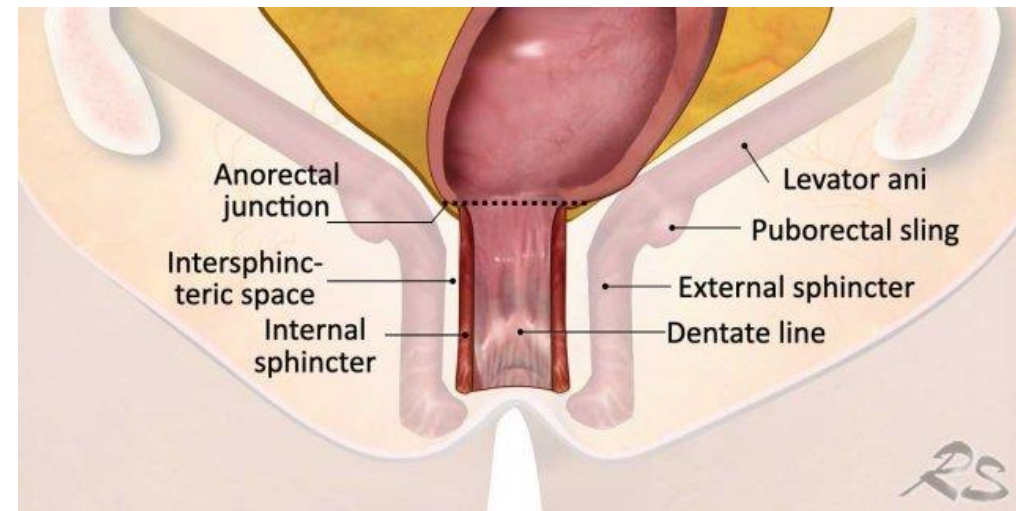
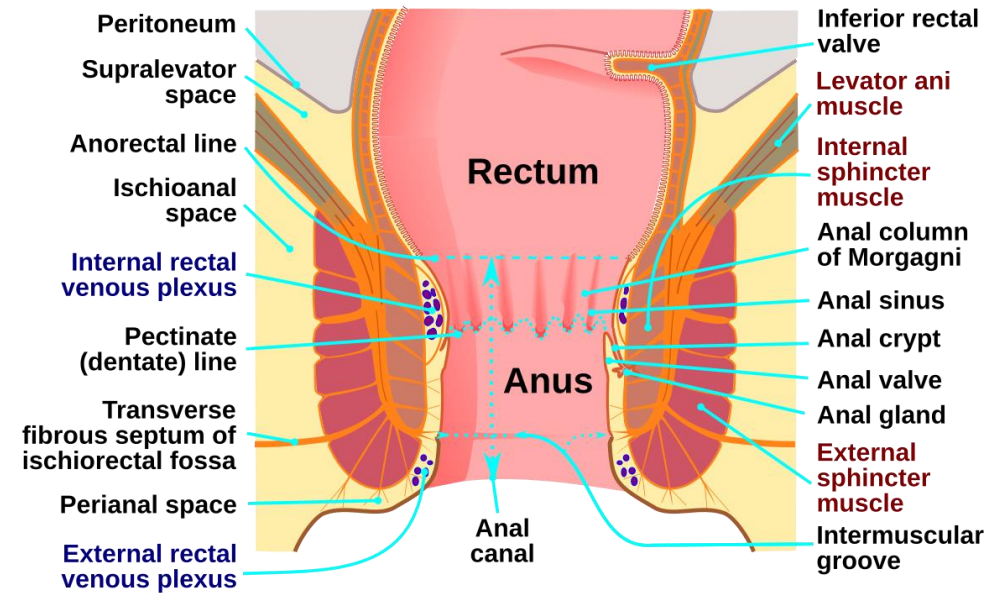
- Same as sigmoid colon.
- The rectum is sensitive only to stretch.



15- Anorectal junction

- The **anorectal junction** marks the transition between the rectum and the anal canal.
- It contains three key structures:
 1. The **puborectalis muscle**
 2. A portion of the **internal anal sphincter**.
 3. The **deep part of the external anal sphincter**.

- ☹️ **Injury to the anorectal junction** especially to the **puborectalis muscle** or the **deep part of the external anal sphincter**, both of which are under **voluntary control**—can result in **incontinence** (inability to control defecation). In contrast,
- ☹️ **injury to the internal anal sphincter**, which is **involuntary**, does not typically cause incontinence.



16- Anal Canal

The anal canal is **4 cm long**.

➤ Relate to Embryology:

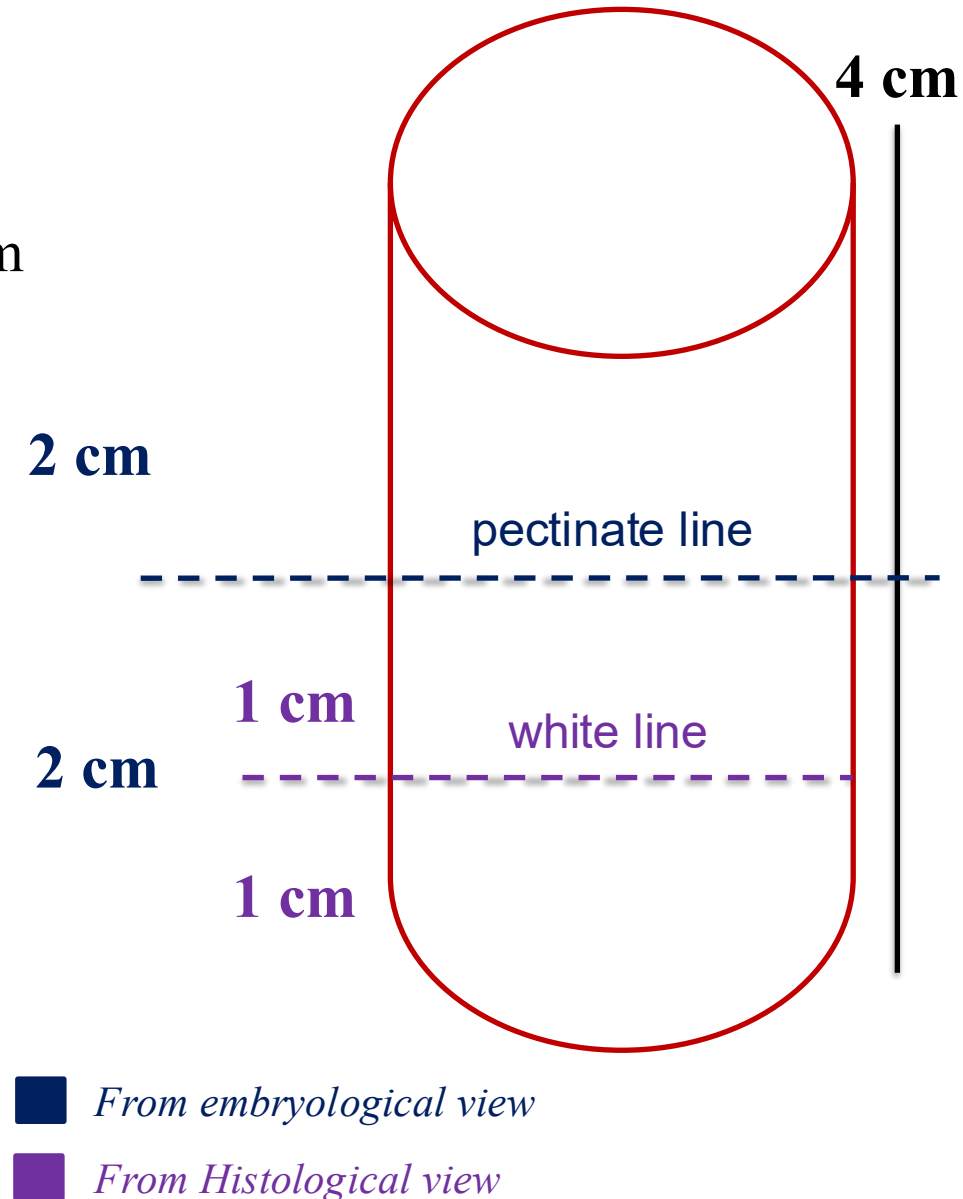
It is divided by the *pectinate line into:

- **Upper 2 cm (endoderm origin)** continuous with the rectum
- **Lower 2 cm (ectoderm origin)**

*The pectinate line is located at the end of the anal sinuses and valves of the anal columns.

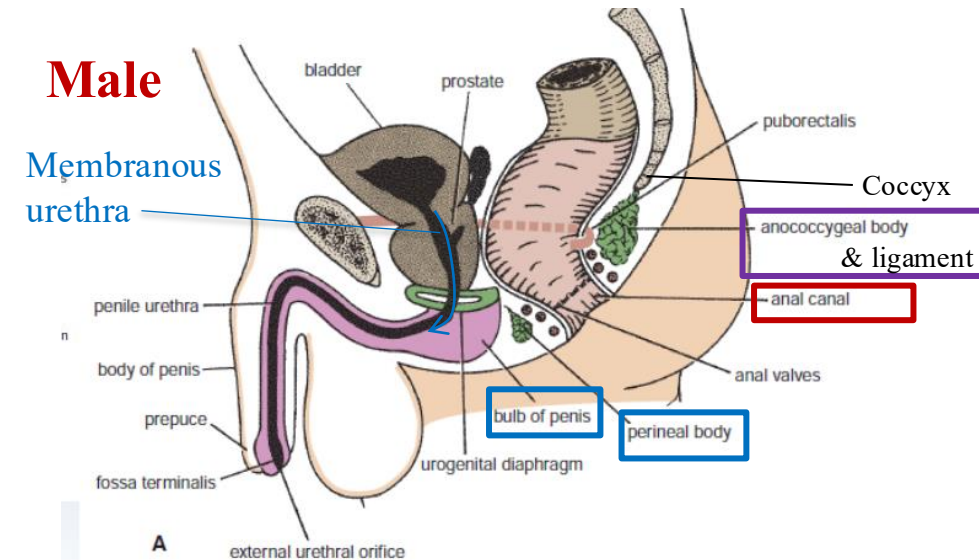
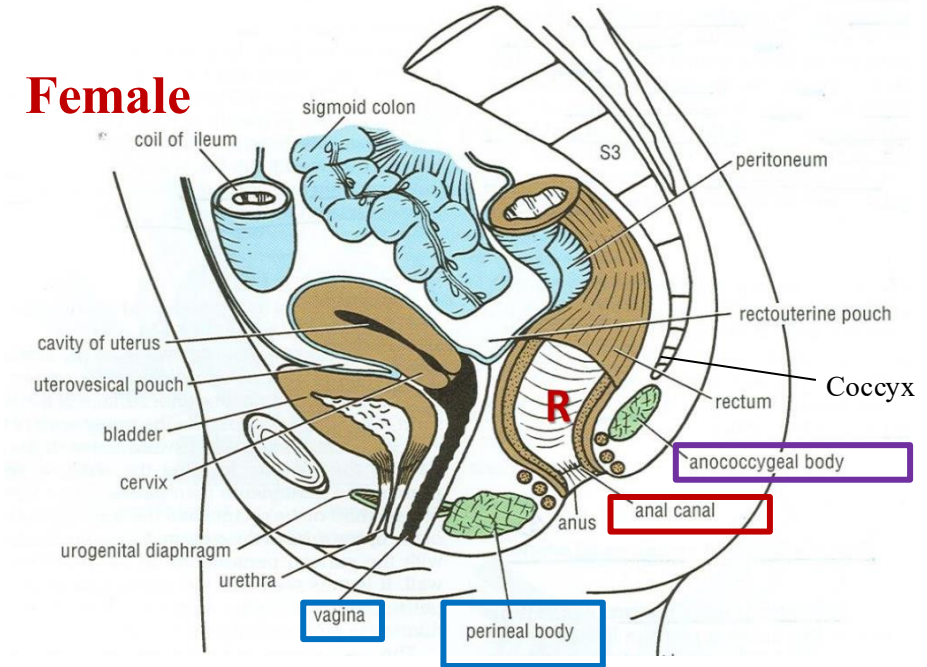
➤ Relate to Histology:

- **Upper 2 cm** is lined by **simple columnar with goblet**.
- **Lower 2 cm** is further divided by the **white line** into:
 - The **upper 1 cm** is lined by stratified squamous **non-keratinized** epithelium,
 - While the **lower 1 cm** is lined by stratified squamous **keratinized** epithelium, which contains hair follicles, sebaceous glands, and sweat glands.

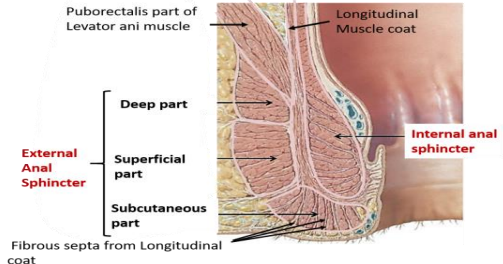


16- Anal Canal Relations

Relation	Structures
*Anteriorly	Male: <ol style="list-style-type: none"> 1. Perineal body, 2. Membranous urethra 3. Bulb of penis
	Female: <ol style="list-style-type: none"> 1. Lower end of the vagina 2. Perineal body
*Posteriorly	<ol style="list-style-type: none"> 1. Anococcygeal ligament 2. Tip of the coccyx
Laterally	<ul style="list-style-type: none"> • Ischiorectal fossae (on both sides)
Surrounding	<ul style="list-style-type: none"> • Voluntary (external) anal sphincter surrounds the anal canal

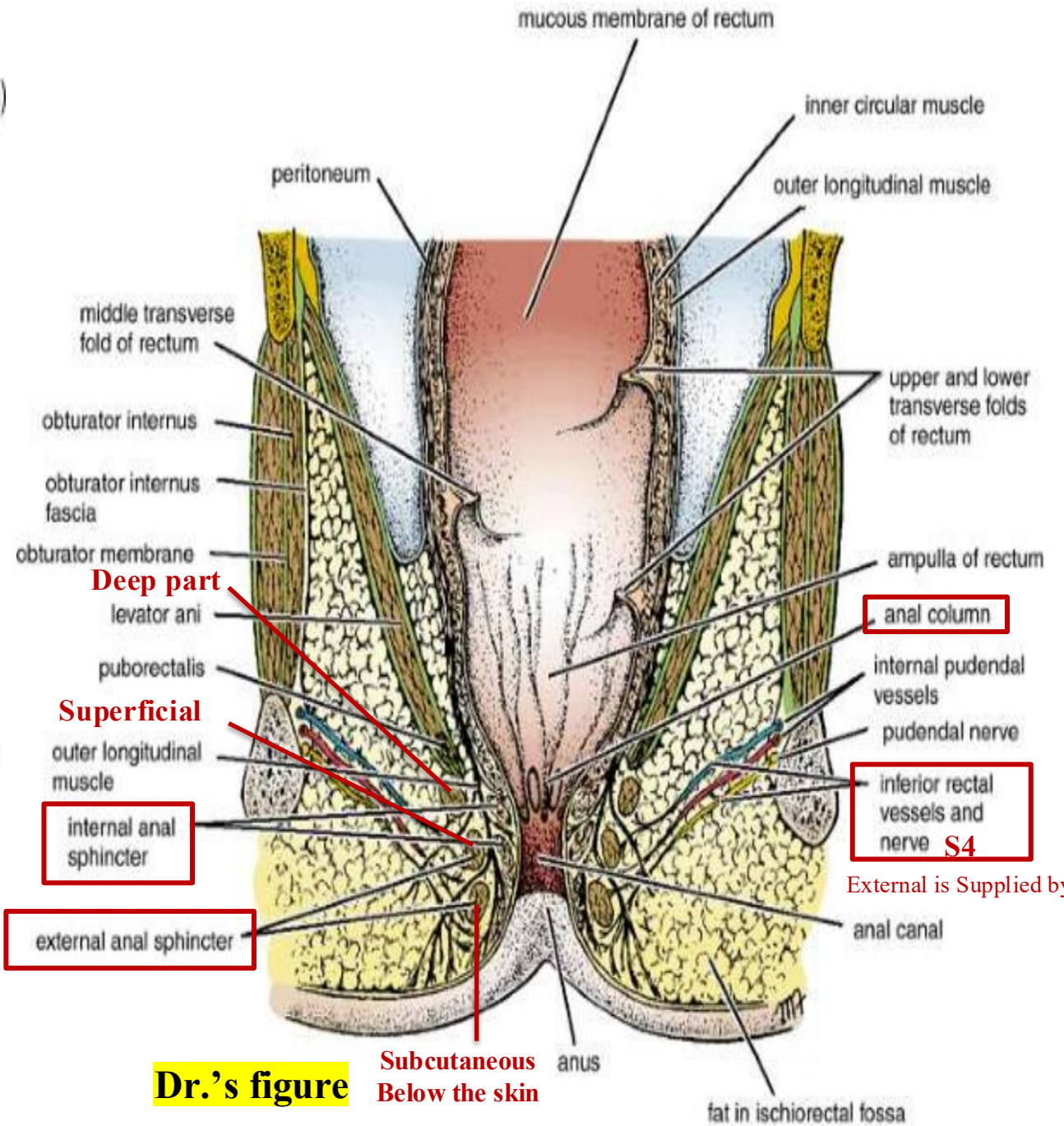
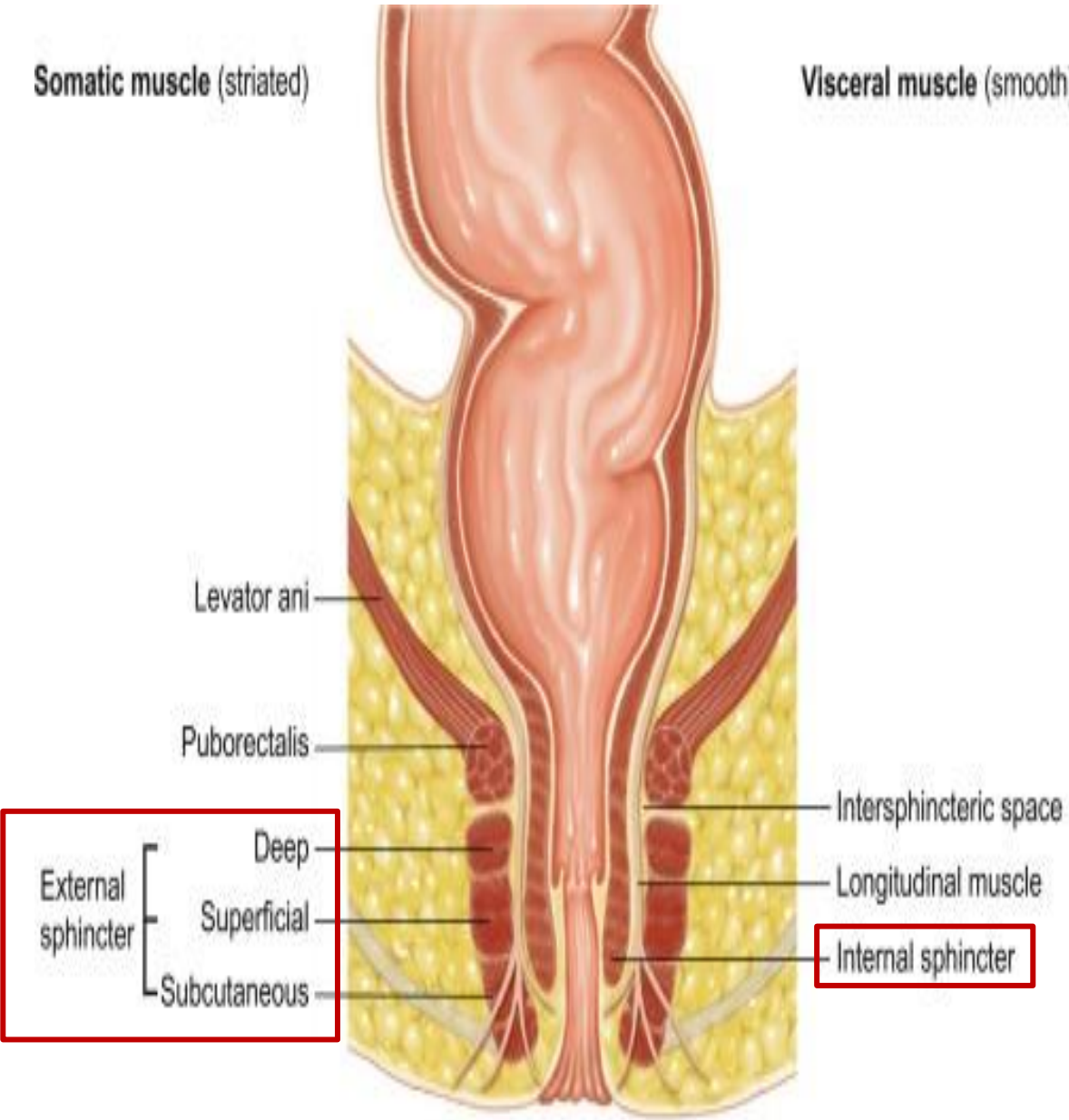


17- Anal sphincters/valves

Attribute	Internal Anal Sphincter	External Anal Sphincter
Type	Involuntary	Voluntary
Location / Parts	Located at the Submucosa	<ol style="list-style-type: none"> 1. Subcutaneous part (no attachment) 2. Superficial part (has attachment) : surround the lower part of internal sphincter (anal canal). 3. Deep part (no attachment) : Surround the upper part of internal sphincter. 
Innervation & vessels	Autonomic: Sympathetic & Parasympathetic	Somatic: Inferior rectal nerve (S4) & Inferior rectal vessels
Notes	Not involved in voluntary defecation control	Controls voluntary defecation, thus ☹️ Injury to S4 → incontinence.

Somatic muscle (striated)

Visceral muscle (smooth)



External is Supplied by:

Dr.'s figure

Subcutaneous Below the skin

18- Anal Canal Supply

- ✓ Rectum and the upper half (upper 2 cm) of the anal canal are similar in (blood supply, lymphatics & Nerve supply), while lower 2 cm of the anal canal differs significantly.

Arterial Supply:

- **Upper half:** Same as the rectum
 - **Lower half:** Supplied by the **middle and inferior rectal arteries** (branches of the internal iliac A.).
- There is an anastomosis between the arteries of the upper and lower halves.

Venous & Lymphatic Drainage

Same as the rectum

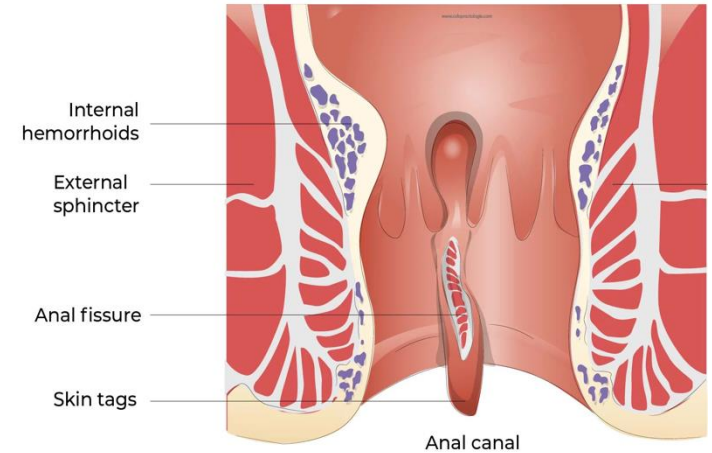
Nerve Supply

- **Upper half:** Same as the rectum
 - **Autonomic nerves** (from inferior hypogastric plexus).
 - Sensitive only to **stretch** (not pain).
- **Lower half:**
 - Supplied by **somatic nerves (S4)**.
 - Sensitive to **pain, temperature, touch, and pressure**.
 - **Voluntary control** (important for defecation).

19- Anal Canal

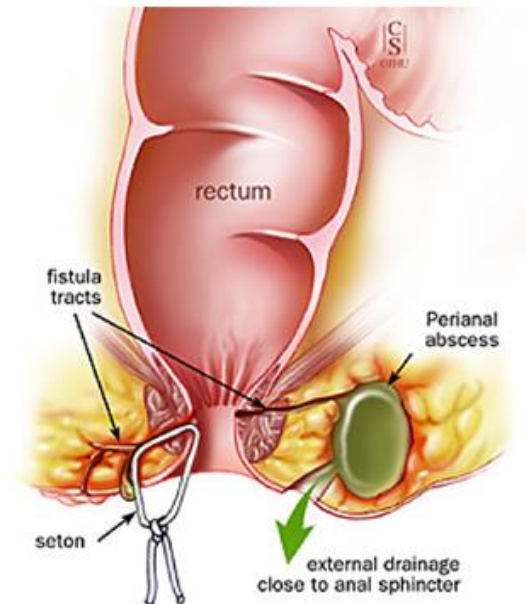
☹️ Anal Fissure

- A longitudinal **ulcer** in the anal canal,
- Caused by trapped hard feces in the anal sinuses and valves, which are located between the anal columns.
- **Very painful**, especially if the fissure extends into the lower part of the anal canal (somatic innervation → S4).
- Usually treated surgically.



☹️ Perianal Abscess

- Occurs in the **ischiorectal fossa** (fat-filled space lateral to the anal canal).
- Caused by bacterial infection → leads to accumulation of pus.
- Treatment is by surgical **drainage**.
- High recurrence rate due to the unclean environment in the perianal region.



20- Summary:

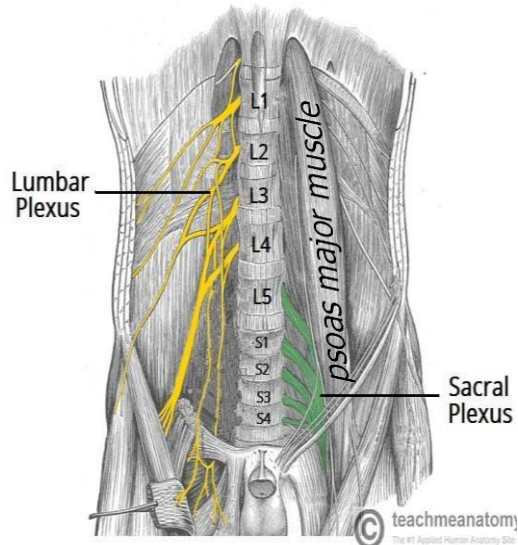
Feature	Sigmoid Colon	Rectum	Anal Canal (Upper 2 cm)	Anal Canal (Lower 2 cm)
Embryo. Origin	Hindgut (Endoderm)			Proctodeum (Ectoderm)
Histological Lining	Simple columnar epithelium with goblet cells			Upper 1cm: Stratified squamous non- keratinized Lower 1cm: Stratified squamous keratinized
Arterial Supply	<ul style="list-style-type: none"> • Left colic artery • Sigmoidal arteries Branches of IMA	<ul style="list-style-type: none"> • Superior rectal (from IMA) • Middle rectal (from internal iliac) • Inferior rectal (from internal pudendal) 		<ul style="list-style-type: none"> • Middle rectal (from internal iliac) • Inferior rectal (from internal pudendal)
Venous Drainage	<ul style="list-style-type: none"> • Inferior mesenteric vein → splenic vein → portal vein 	<ul style="list-style-type: none"> • Superior rectal vein → IMV → portal vein • Middle rectal vein → internal iliac • Inferior rectal vein → pudendal → IVC 		<ul style="list-style-type: none"> • Middle rectal vein → internal iliac • Inferior rectal vein → pudendal → IVC
Lymphatic Drainage	<ul style="list-style-type: none"> • pre-aortic lymph nodes: Inferior mesenteric nodes → Superior mesenteric nodes → Celiac nodes → Thoracic duct. 			<ul style="list-style-type: none"> • Superficial inguinal lymph nodes
Nerve Supply	Inferior hypogastric plexus: <ul style="list-style-type: none"> • Sympathetic: L1–L2 • Parasympathetic: S2–S4 			<ul style="list-style-type: none"> • Somatic (S4 via inferior rectal nerves)

25- Nerves of posterior abdominal wall –overview

**Somatic
Nerves**

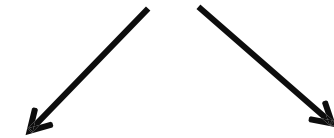


**Lumbar plexus &
Sacral plexus**

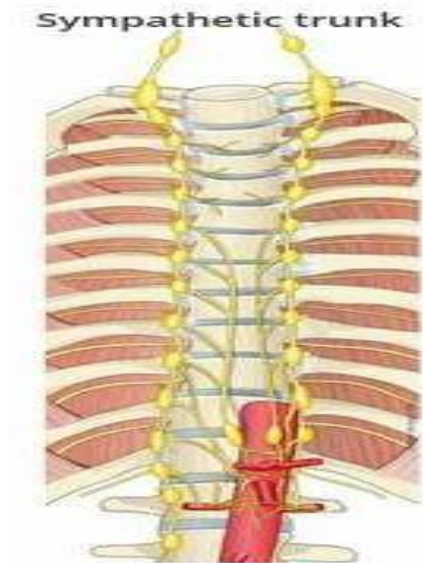


Related to psoas major muscle

**Autonomic
Nerves**



**Sympathetic
chain**



**Autonomic
Plexus
Around
Aorta**


26- Lumbar plexus & Sacral plexus.

1. Lumbar Plexus

- A network of nerve fibers formed by the anterior primary rami of **L1, L2, L3**, and the **upper part of L4**.
- Lies **within the psoas major muscle** in the abdomen.

2. Sacral Plexus

- Fibers coming from **lower part of L4 and L5** and continues with contributions from the **sacral nerves**.
- L4 and L5 together are called **lumbosacral trunk**.



26- Lumbar plexus & Sacral plexus.

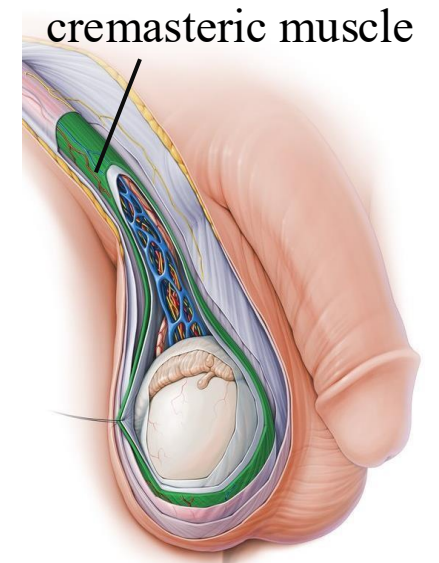
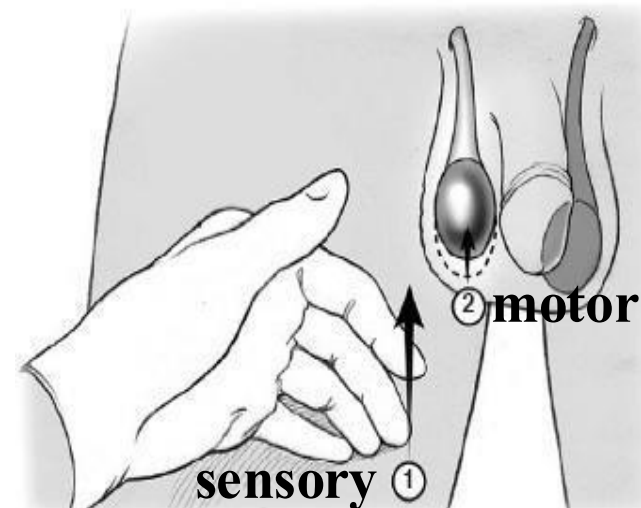
▪ Nerve Relations to the Psoas Major Muscle:

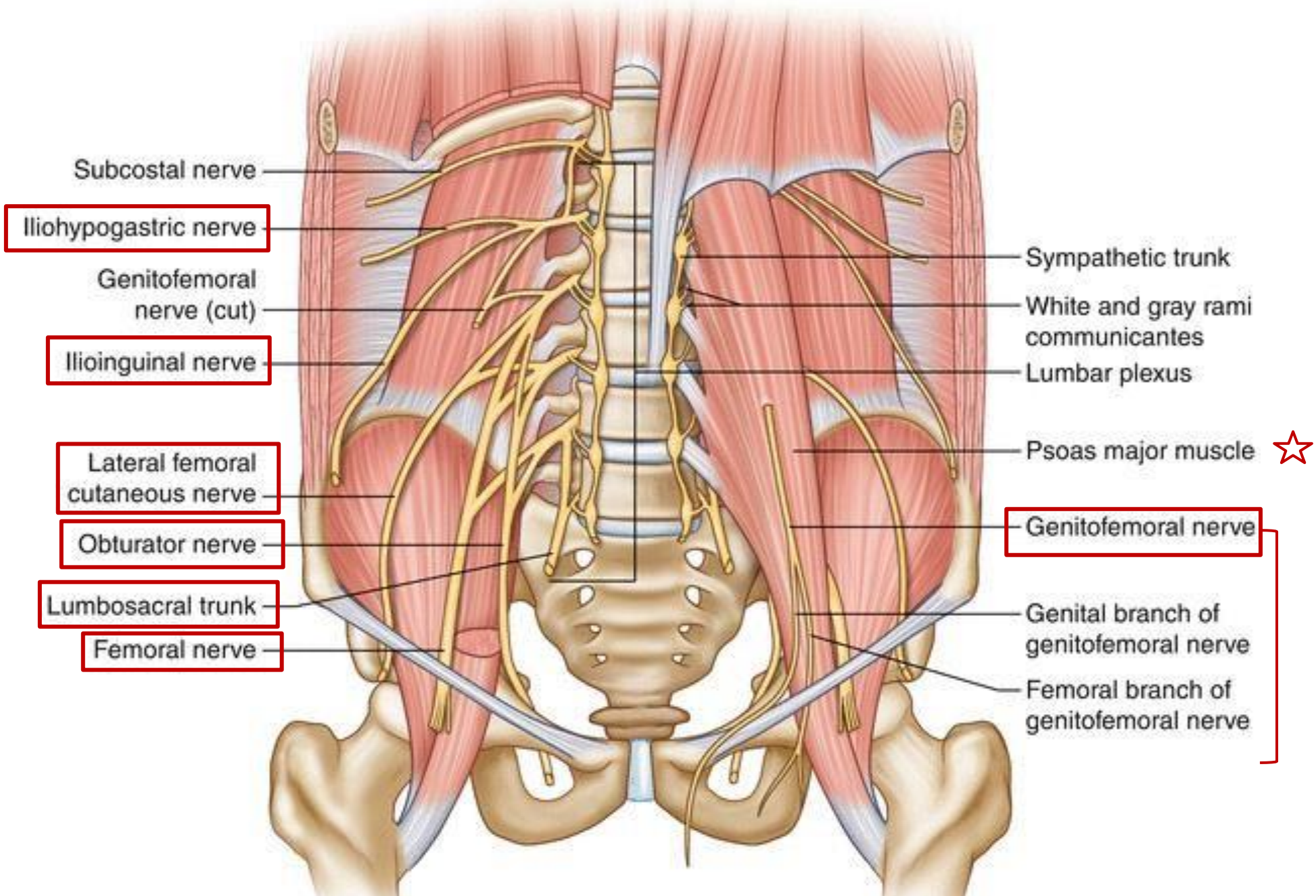
Position Relative to Psoas muscle	Nerve	Spinal Roots	Notes
Lateral	Iliohypogastric nerve	L1	Goes to the skin above the symphysis pubis, supplies lower abdomen
	Ilioinguinal nerve	L1	Sensory to the scrotum
	Lateral cutaneous nerve of thigh	L2, L3	Supplies the skin on the lateral side of the thigh
	Femoral nerve	L2, L3, L4 (posterior division of anterior rami)	Goes to anterior surface of the thigh
Medial	Obturator nerve	L2, L3, L4 (anterior division of anterior rami)	Goes to medial compartment of the thigh
	Lumbosacral trunk	Lower L4, L5	
Pierces through	Genitofemoral nerve	L1, L2	Divides into genital and femoral branches; responsible for *cremasteric reflex 53

"Cremasteric Reflex?"

Recall mid-material:

- The cremasteric muscle contracts in cold weather, pulling the scrotum upwards toward the abdomen. While in warm weather, the muscle relaxes, and the scrotum hangs down.
- This action helps regulate the temperature for sperm production, which requires a temperature 2–3°C below core body temperature.
- Stimulation (Ex: itching) of the upper medial thigh leads to contraction of the cremasteric muscle, this is called the cremasteric reflex. (How?)
 - **Afferent limb (sensory): Femoral branch of the genitofemoral nerve** senses the touch.
 - Signal travels to the spinal cord (L1–L2).
 - **Efferent limb (motor):** Signal returns via the **genital branch of the genitofemoral nerve**, causing the cremasteric muscle to contract.





Iliohypogastric nerve

Ilioinguinal nerve

Lateral femoral cutaneous nerve

Obturator nerve

Lumbosacral trunk

Femoral nerve

Sympathetic trunk

White and gray rami communicantes

Lumbar plexus

Psoas major muscle ☆

Genitofemoral nerve

Genital branch of genitofemoral nerve

Femoral branch of genitofemoral nerve

27- Sympathetic chain – overview

- A series of interconnected ganglia via sympathetic fibers.
- Extends from the **base of the skull (atlas)** to the **coccyx**.
- Originates from the spinal cord, specifically the **thoracolumbar segments T1–L2** which form 14 spinal segments / nuclei.

- **Number of Ganglia by Region:**

	Cervical	Thoracic	Abdominal	Pelvic	Coccygeal	Total
No. of Ganglia	3	10–12	4–5	4–5	1	≈ 26 ganglia

- **Sympathetic Pathways:**

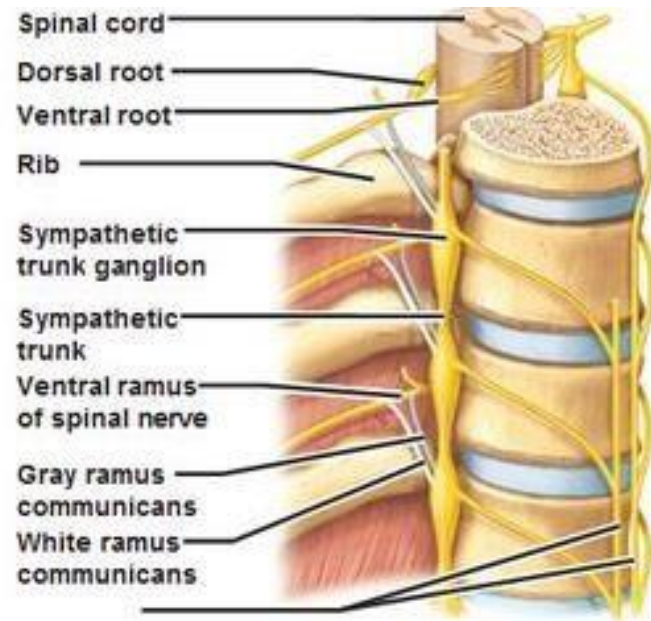
1. **Pre-ganglionic Fibers (White Rami Communicantes)**

- Originate from **lateral horn** → **ventral root** → **spinal nerve** → **white ramus** ⇨ **Different routes**

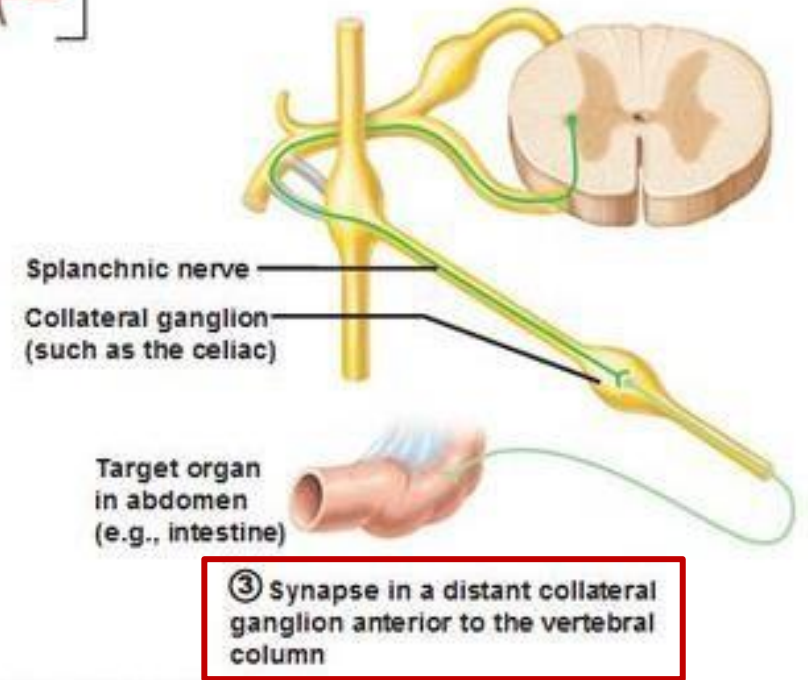
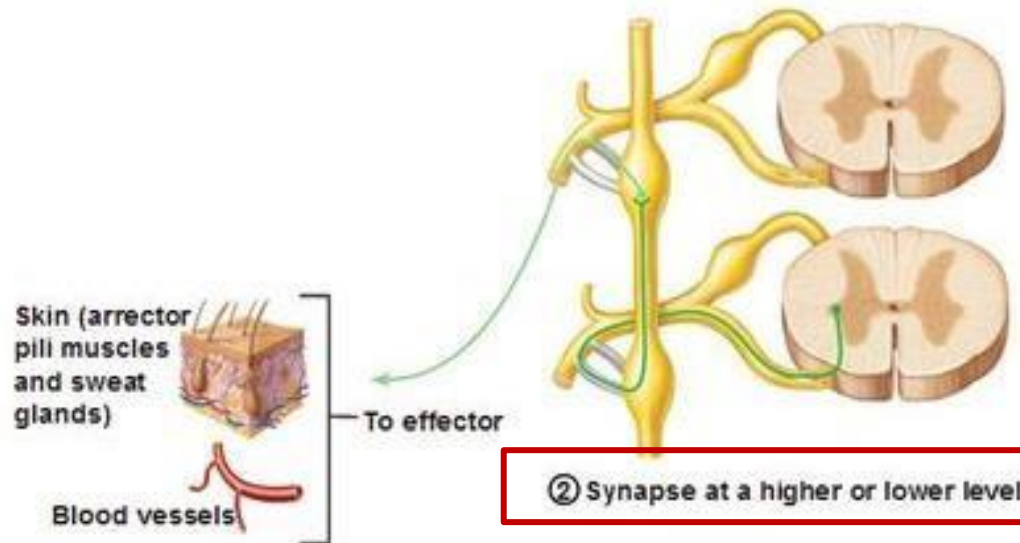
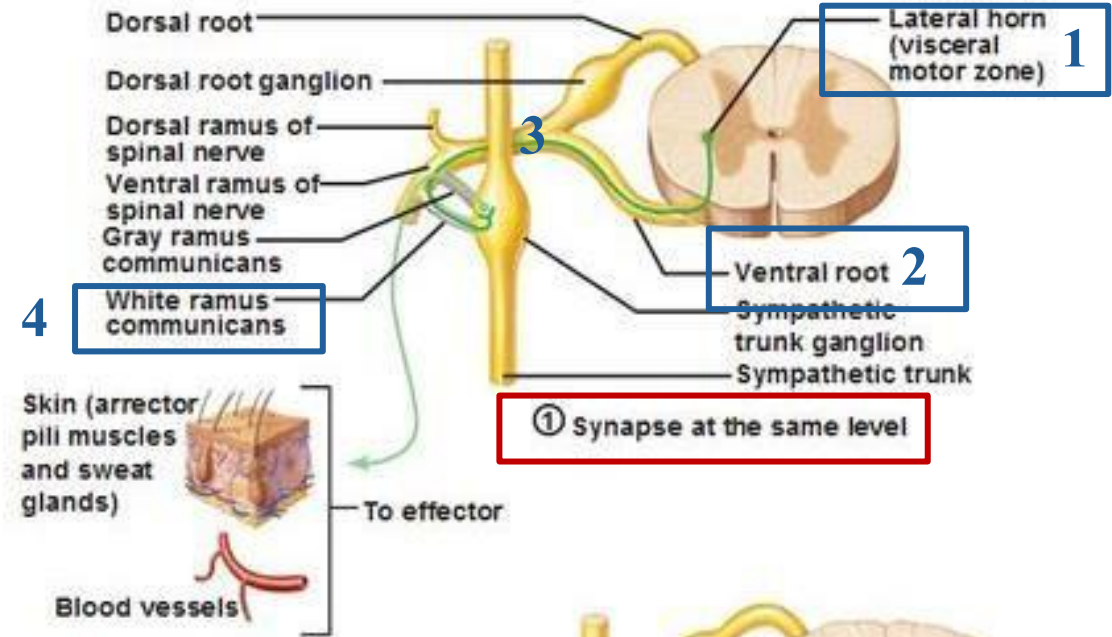
Possible routes:

- **Synapse** in the corresponding ganglion. (*e.g., from T5 into ganglia #5*)
- **Ascend** to cervical ganglia → synapse.
- **Descend** to lumbar or sacral ganglia → synapse.
- Pass without synapsing to **prevertebral ganglia/pre-aortic** (*e.g., celiac, superior mesenteric, inferior mesenteric*) as **splanchnic nerves**

Pathway:



(a) Location of the sympathetic trunk



(b) Three pathways of sympathetic innervation

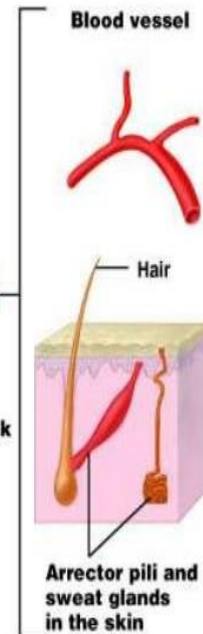
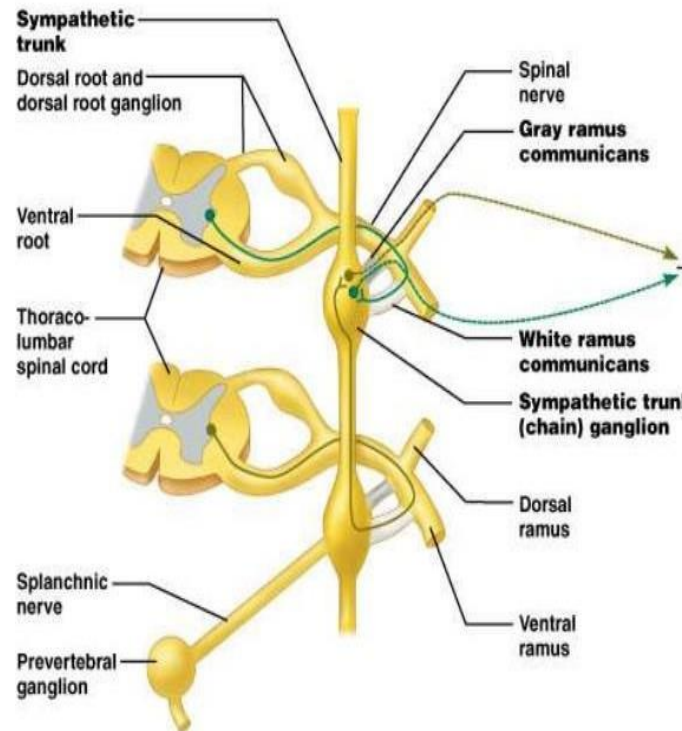
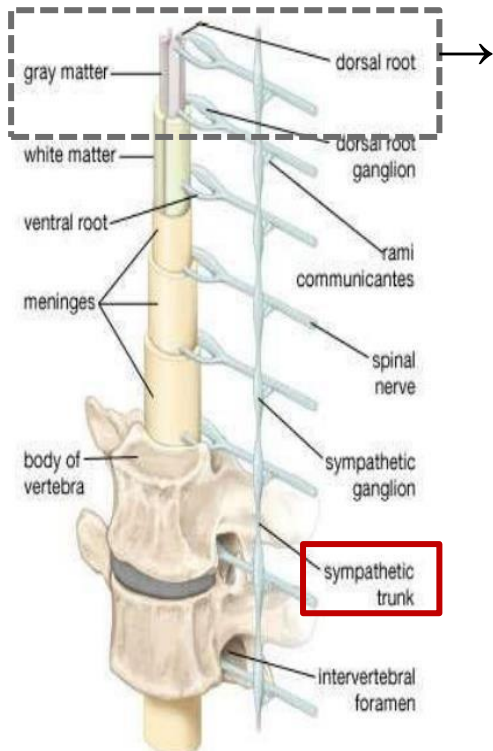
Possible routes:

27- Sympathetic chain – overview

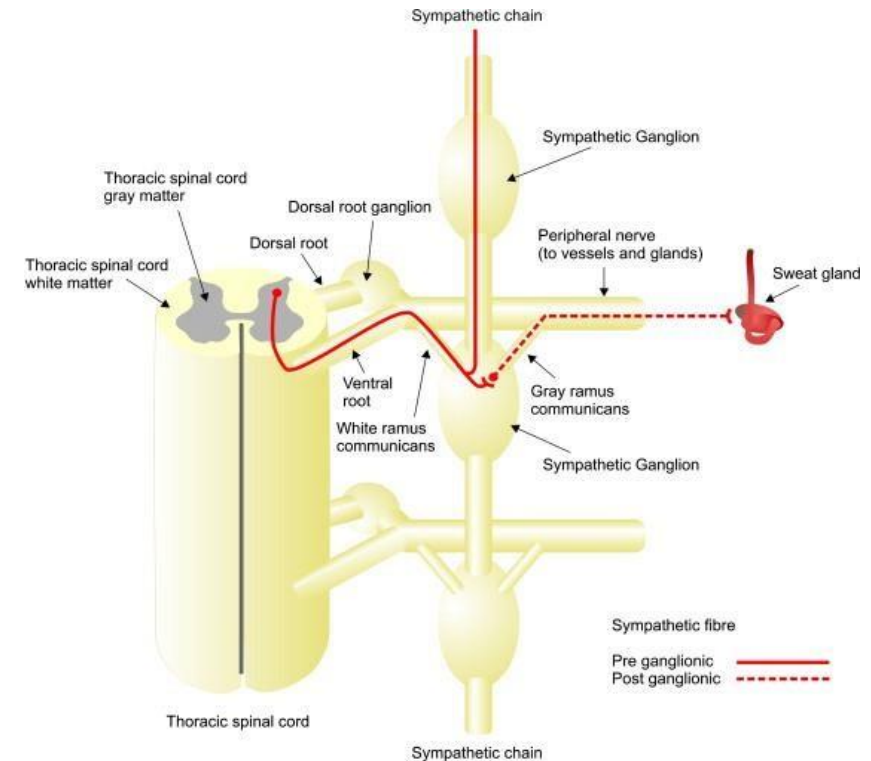
- **Sympathetic Pathways:**

2. Post-ganglionic Fibers (Gray Rami Communicantes)

- From ganglion → **gray ramus** → back to one of the **spinal nerve** → **target structures**.
- Found in **all 31 pairs** of spinal nerves (left and right).
- Target: **blood vessels, sweat glands, erector pili muscles** (mainly in the skin).



Dr.'s figure:



Sum up: very useful!

28- Autonomic innervation of abdominal viscera

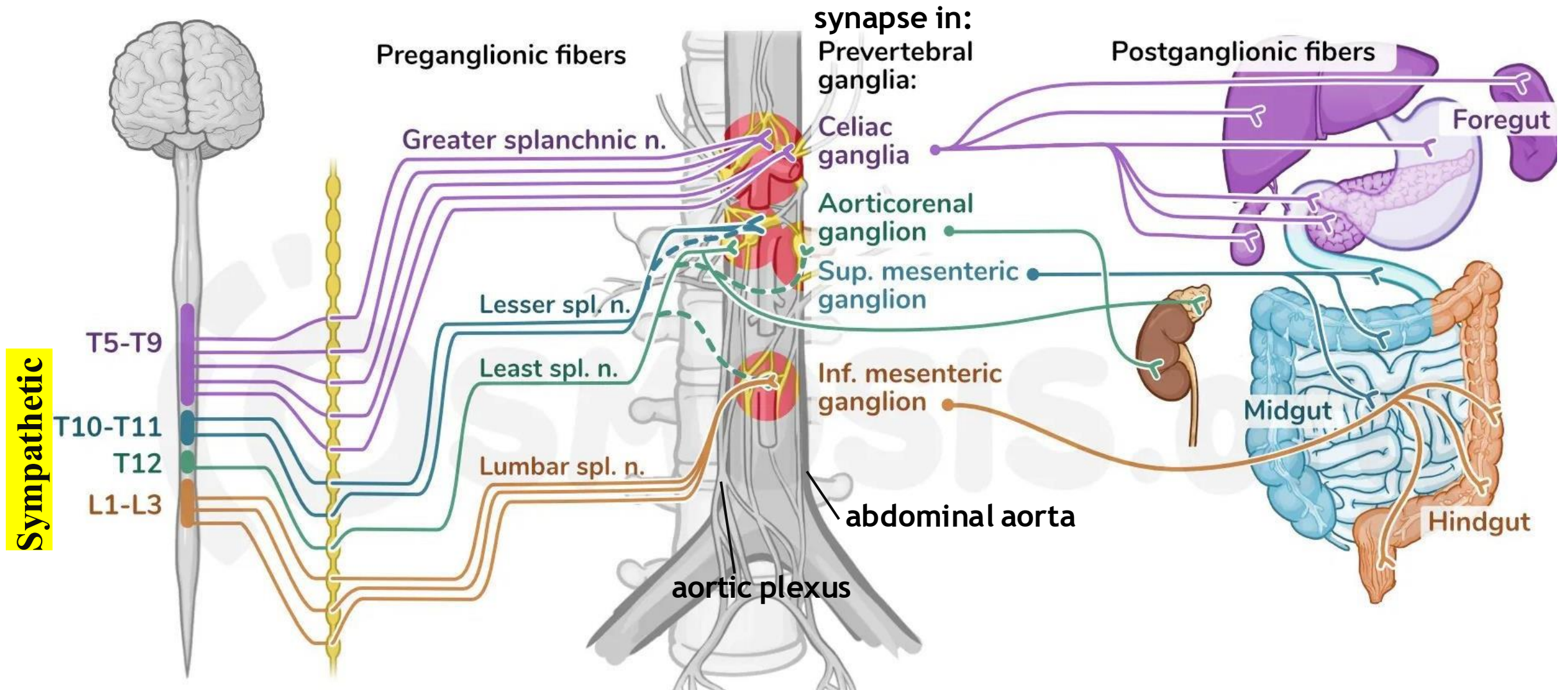
After the general background is covered, we will now focus on the abdominal sympathetic trunk.

- Recall: we have **4- 5 ganglia** in the abdominal region
- These ganglia receive preganglionic fibers, which synapse with postganglionic neurons in the ganglia. The resulting postganglionic fibers form a plexus that follows the blood vessels to reach the target organs. Note that each plexus has both sympathetic and parasympathetic fibers.

Preganglionic nerve	Ganglion (Synapse Site)	Plexus Formed	Organs Supplied
Greater Splanchnic	Celiac ganglion	Celiac plexus	Foregut organs
Lesser Splanchnic	Superior mesenteric ganglion	Superior mesenteric plexus	Midgut organs
Lowest Splanchnic	Renal ganglia	Renal plexus	Kidneys and suprarenal glands
Lumbar Splanchnic	Inferior mesenteric ganglion	Inferior mesenteric plexus	Hindgut organs

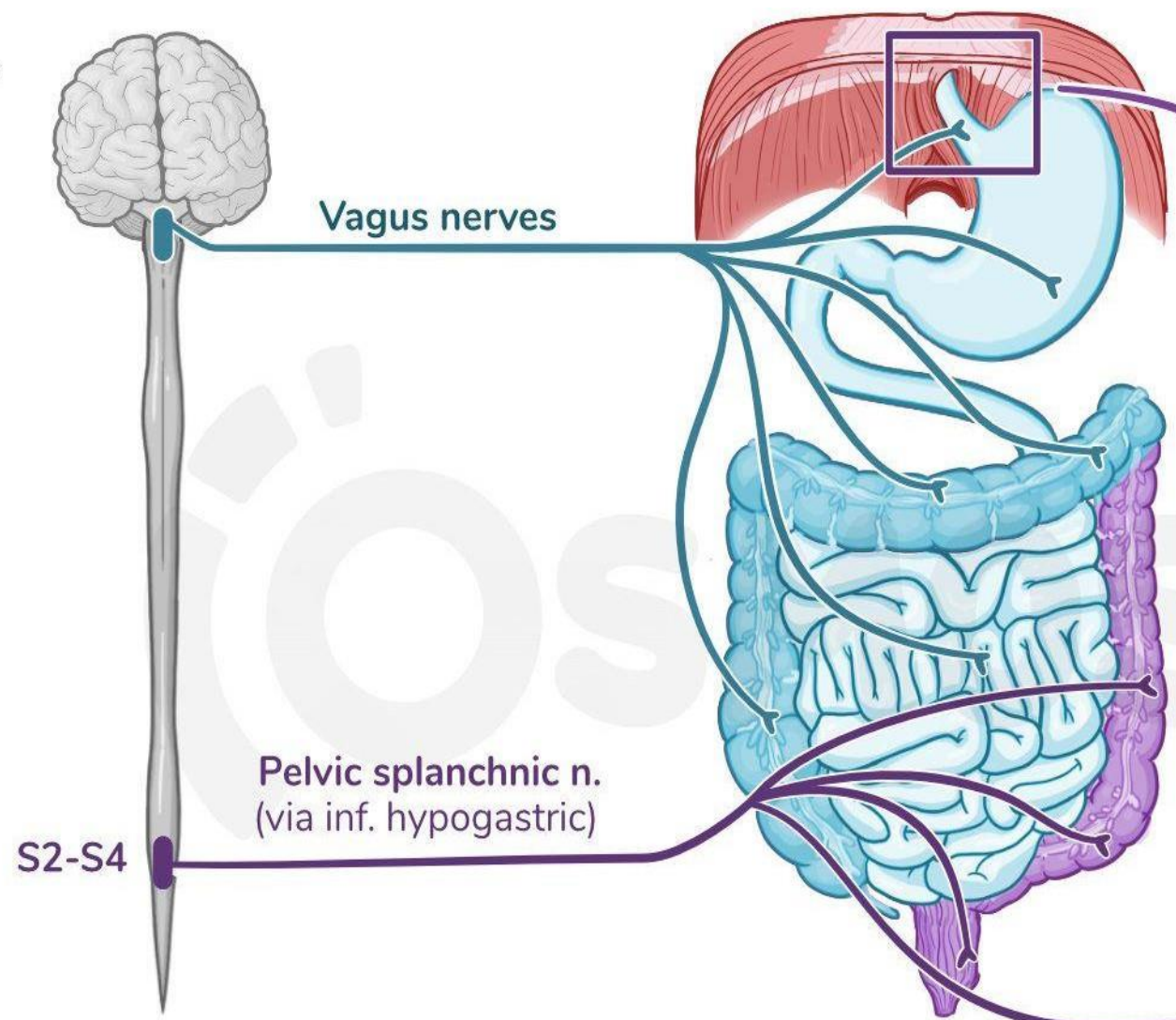
Provided is a summary— each column will be discussed in detail in the upcoming slides.

28- Autonomic innervation of abdominal viscera

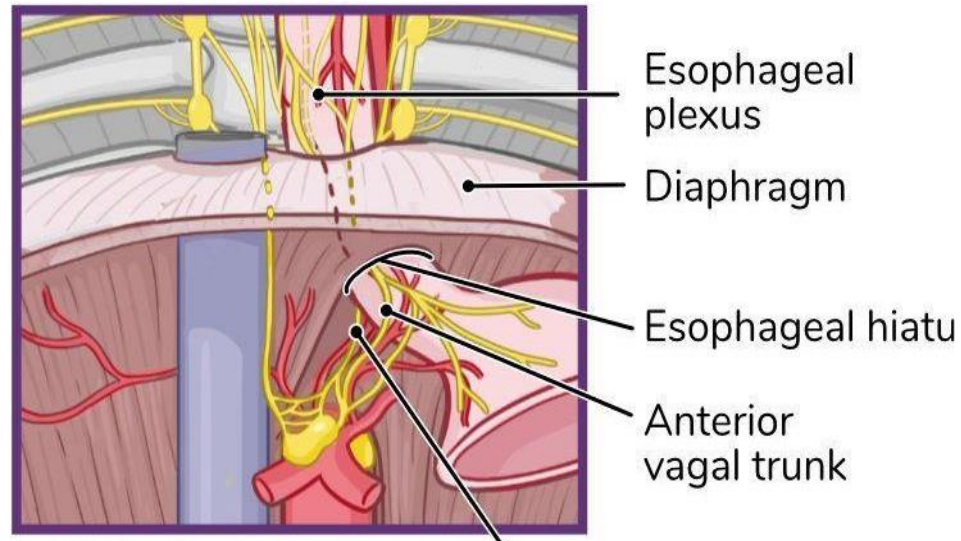


Parasympathetic

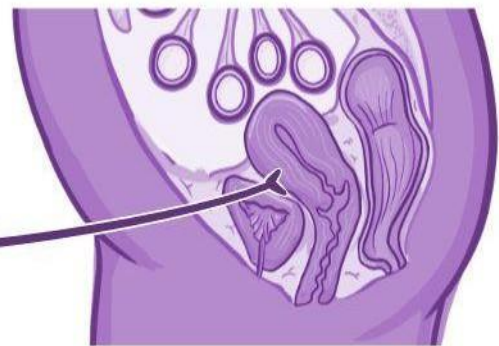
A.



B.



Pelvic organs



28- Autonomic innervation of abdominal viscera

1- Preganglionic fibers: Splanchnic nerves are paired autonomic nerves that carry preganglionic **sympathetic** fibers, but in the case of pelvic splanchnic nerves, it is preganglionic **parasympathetic** fibers.

Nerve	Spinal Level	Common Course	Targeted Ganglia / Ends
Greater Splanchnic	T5–T9	Arises from the thoracic sympathetic ganglia → passes the sympathetic chain without synapsing → Descends into the abdomen → Pierces the diaphragm	Synapses in celiac ganglia
Lesser Splanchnic	T9 - T10*		Synapses in superior mesenteric ganglia
Lowest Splanchnic	T11–T12		Relays with renal plexus at suprarenal gland
Lumbar Splanchnic	L1–L2	From lumbar region → passes through hypogastric plexus	Synapses in inferior mesenteric ganglia

*The doctor said T10-T11 in the lecture (it is preferable to consider what was mentioned in the slides, since it probable that the doctor just make mistake, despite that there are some resources that says T10-T11 is correct).

28- Autonomic innervation of abdominal viscera

2- Ganglion (Synapse Site):

- The major sympathetic ganglia in the abdomen are organized **around the abdominal aorta** and correspond to the origins of major unpaired arterial branches.
- These ganglia serve as synapse points for preganglionic sympathetic fibers and give rise to postganglionic fibers that follow blood vessels to abdominal organs.

1. Celiac Ganglia

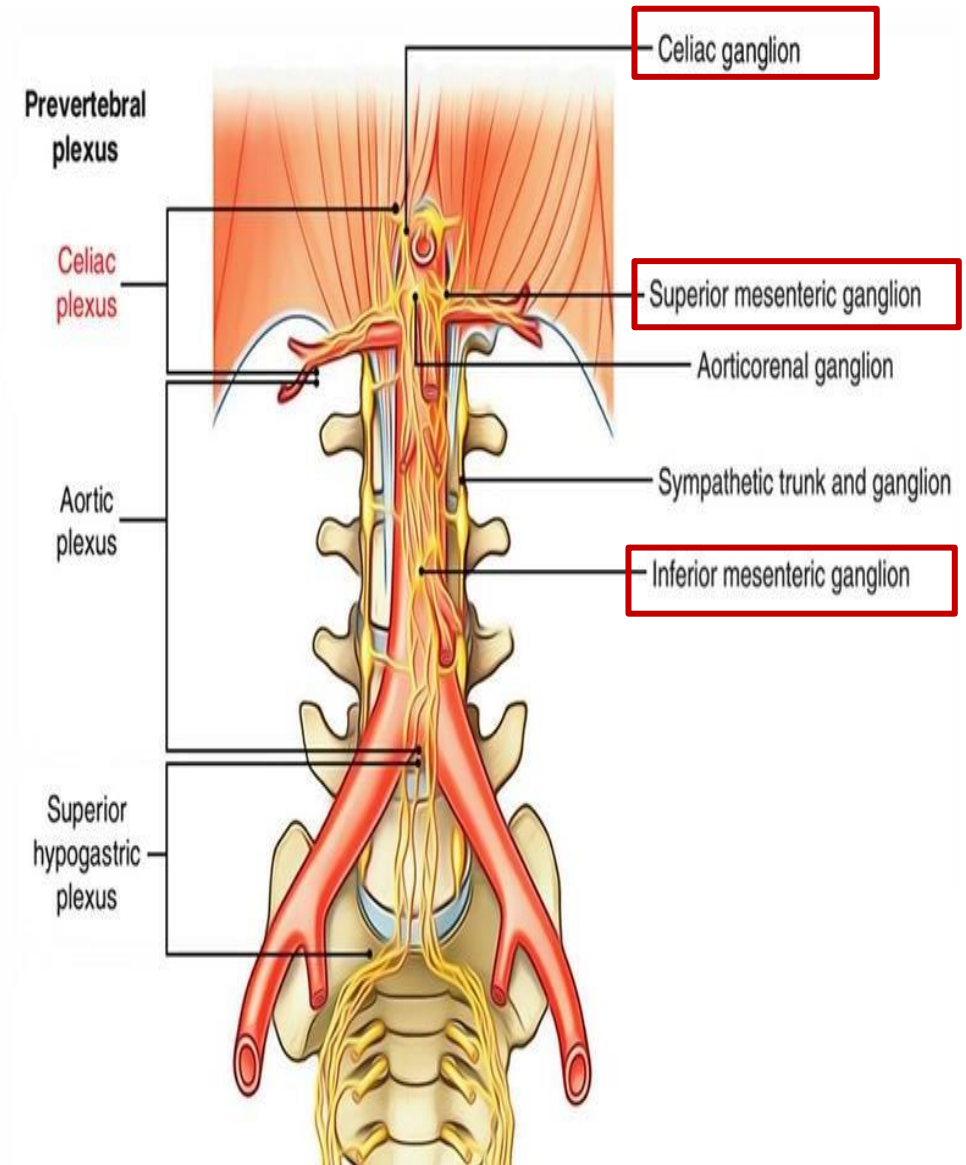
Located at the origin of the **celiac trunk**

2. Superior Mesenteric Ganglia

Found at the origin of the **superior mesenteric artery**.

3. Inferior Mesenteric Ganglia

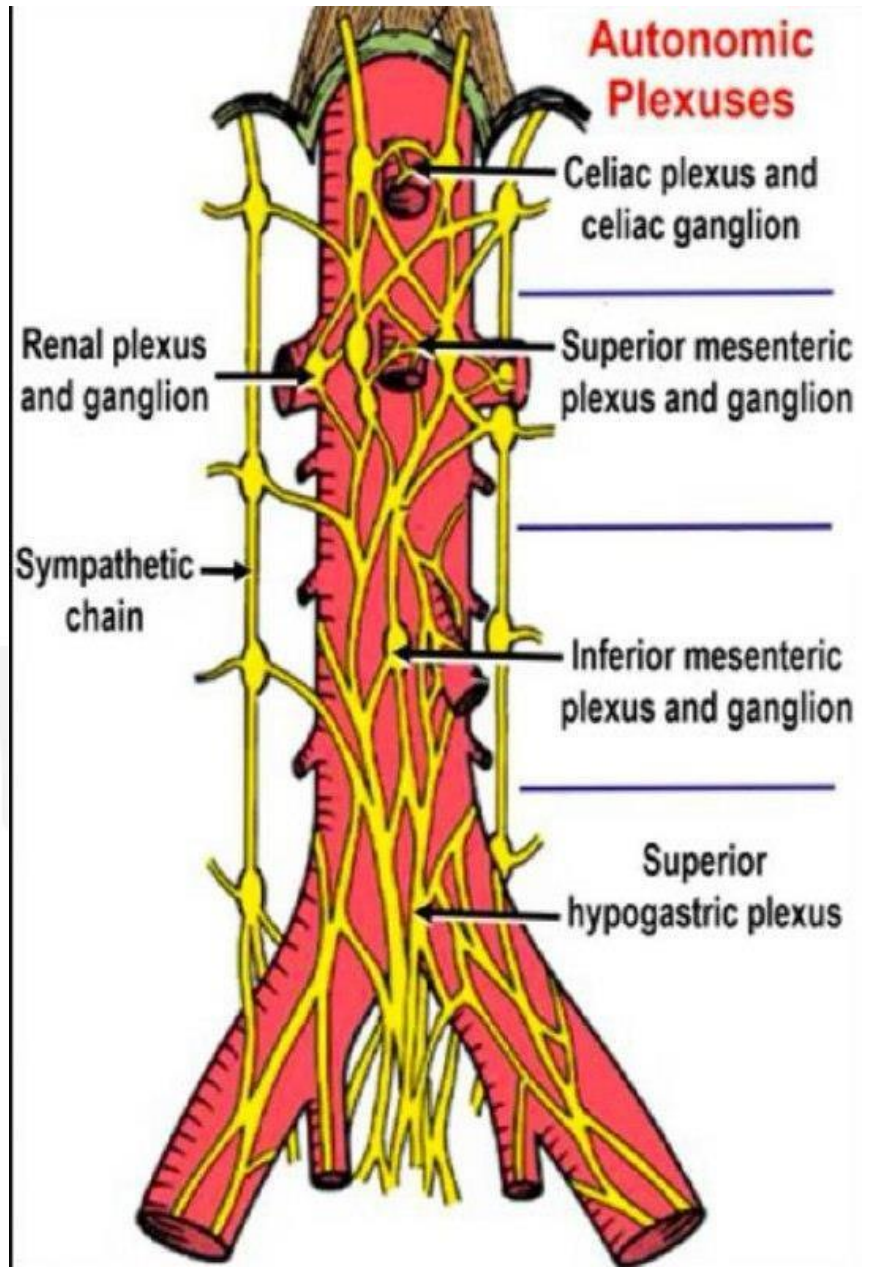
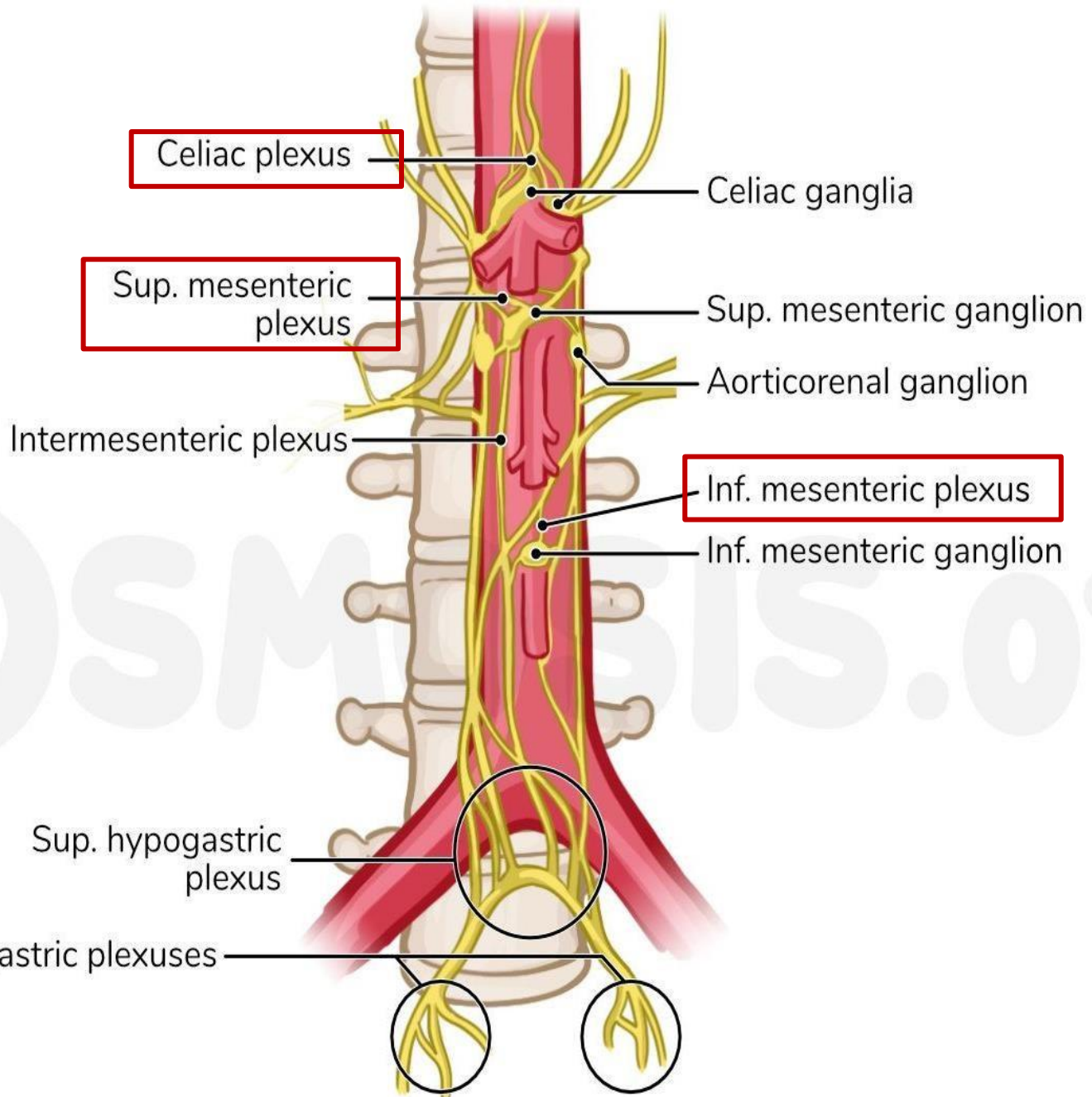
Situated at the origin of the **inferior mesenteric artery**



29- Autonomic (aortic) plexus

3- Plexus formed: plexus contains both sympathetic and parasympathetic fibers.

Plexus Name	Sympathetic Fibers	Parasympathetic Fibers	Organs Innervated
Celiac Plexus	Postganglionic fibers from celiac ganglion	Vagus nerve (CN X)	Foregut (stomach, liver, spleen, pancreas, kidneys)
Superior Mesenteric Plexus	Postganglionic fibers from superior mesenteric ganglion	Vagus nerve (CN X)	Midgut (small intestine to proximal 2/3 of transverse colon)
Inferior Mesenteric Plexus	Postganglionic fibers from inferior mesenteric ganglion + contributions via superior & inferior hypogastric plexuses	Pelvic splanchnic nerves (S2–S4)	Hindgut (distal 1/3 transverse colon to upper rectum)
Renal Plexus	Postganglionic fibers from aorticorenal ganglia (via lowest splanchnic N.)	Vagus nerve (CN X)	Kidneys and suprarenal glands



29- Autonomic (aortic) plexus

4- Organ supplied To sum up!

Why Abdominal Viscera Is Divided into Foregut, Midgut, and Hindgut? (Based on Innervation)

This division is based on the **autonomic (especially sympathetic) postganglionic innervation**:

- **Foregut** organs receive postganglionic sympathetic fibers from the celiac ganglia via the celiac plexus.
 - **Midgut** organs receive postganglionic fibers from the superior mesenteric ganglia, forming the superior mesenteric plexus.
 - **Hindgut** organs are supplied by postganglionic fibers from the inferior mesenteric ganglia, with contributions from the superior and inferior hypogastric plexuses.
- Note that This ganglionic origin and nerve distribution pattern is clinically significant and mirrors the embryological development and vascular supply of these regions.

رسالة من الفريق العلمي:

التفكر في الآخرة جميل ومريح للنفس جدًّا، رغم الخوف الذي يتملّكنا من الموت ويوم القيامة -لثقل هذا اليوم وخشية أن يكون رصيدنا من السيئات أكبر من الحسنات، ولرهبته سؤال الله جلّ وعلا- لكن.. تخيّل أن تلقى الله عزّ وجلّ، وترى وجهه سبحانه، تسمع كلامه، ترى جماله جلّ وعلا، تكتحل عيناك فلا لذة ولا نعيم يعدل لحظة من هذا المشهد. تخيّل أن تلقى رسول الله ﷺ الذي لطالما حفظت حديثه، وبكيت شوقاً له، وحفظت صفاته وأفعاله وحركاته وسكاته، رسول الله الذي تفديه بروحك رغم أنك لم تره رأي العين.. تخيّل أن ترى الملائكة الكرام، والروح القدس أمين الروح سيّدنا جبريل عليه السلام الذي احتضن النبي ﷺ، ونزل بالوحي من فوق سبع سماوات، قرآنا نقرؤه إلى أن يرفعه الله فتطيب به القلوب، وينزل في كلّ عام مرّة في ليلة القدر فتملاً الدنيا السكينة..

تخيّل أن ترى الرسل عليهم السلام، وأولو العزم منهم.. تخيّل أن ترى سيّدنا عيسى عليه السلام وما كان معه من معجزات بأمر الله، وتسمع من سيّدنا نوح عليه السلام مغامرات الطوفان وتقابل أبو الأنبياء القانت المخلص سيّدنا إبراهيم عليه صلوات الله وسلامه.. وترى أبو البشر كلّهم سيّدنا آدم عليه السلام، أن ترى أول خلق الله من البشر! ثم تجلس مع أمّهات المؤمنين رضي الله عنهنّ، أمنا خديجة في قصرها الذي بلا نصب ولا وصب جزاء ما قدمت لنبينا محمّد صلى الله عليه وسلم وأمنا عائشة رضي الله عنها حبّ رسول الله ﷺ، وأعلم نساء الأرض رضي الله عنها، وترى السيدة الشهيدة، بل أول شهيدة في الإسلام سمية رضي الله عنها..

تخيّل أن ترى الصحابة رضوان الله عليهم الذين بايعوا الرسول وقدموا لله أنفسهم وأموالهم واشتروا رضوان الله.. أن ترى أبو بكر خلّ رسول الله ﷺ، وعمر الفاروق القويّ الذي أعزّ الله به الإسلام، وعثمان بن عفان الذي جهّز جيش العسرة، وخالد سيف الله المسلول، رضوان الله عليهم.

أن ترى الشهداء والصالحين والصديقين على سرر متقابلين، لم يلتقوا في زمن واحد، لكن دعاؤهم كان دوماً وألحقتنا بالصالحين، إخوة التوحيد، فمنّ الله عليهم وجمعهم لقاءً أبدياً.

أن تهدأ قدامك من السعي وراء الراحة في الدنيا وهي سراب، فتجدها أوّل شيء في الجنة، لا خوف ولا حزن بعد اليوم..

For any feedback, scan the code or click on it.



Corrections from previous versions:

Versions	Slide # and Place of Error	Before Correction	After Correction
V0 → V1			
V1 → V2			