

بِسْمِ اللّٰهِ الرَّحْمٰنِ الرَّحِیْمِ

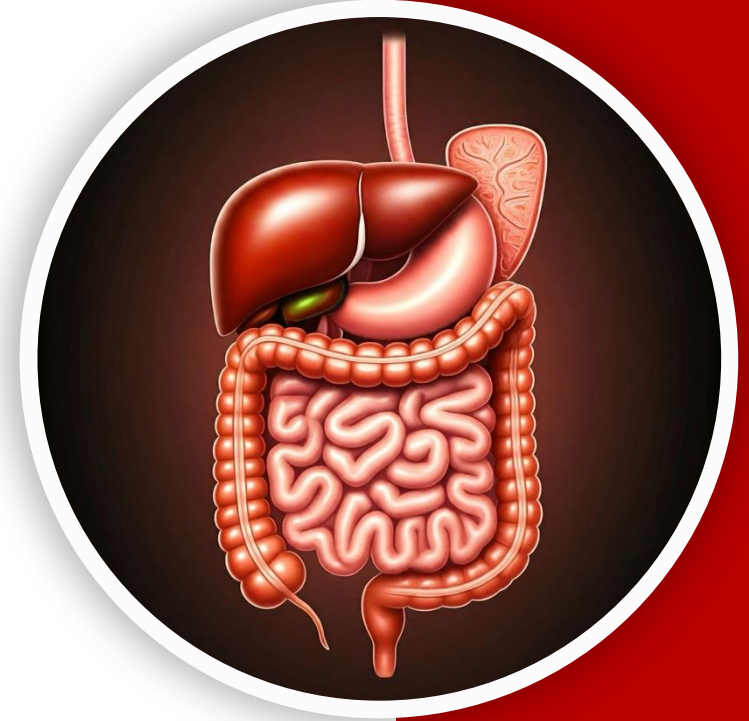
(وَفَوْقَ كُلِّ ذِي عِلْمٍ عَلِيمٌ)



جراح

GIS Anatomy | Final 2

Posterior Abdominal Wall Pt.1



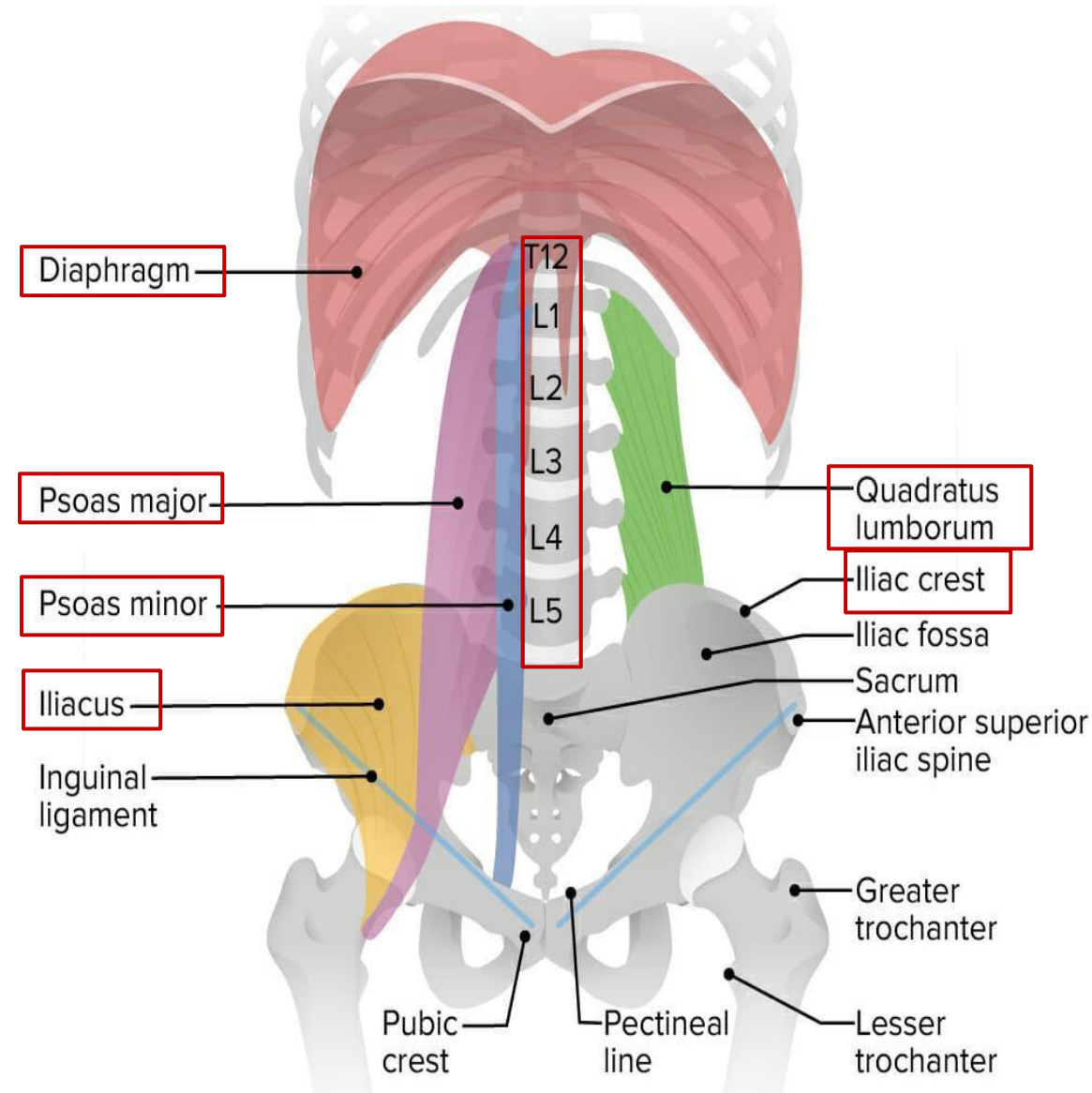
Written by : Sara Al-Khateeb

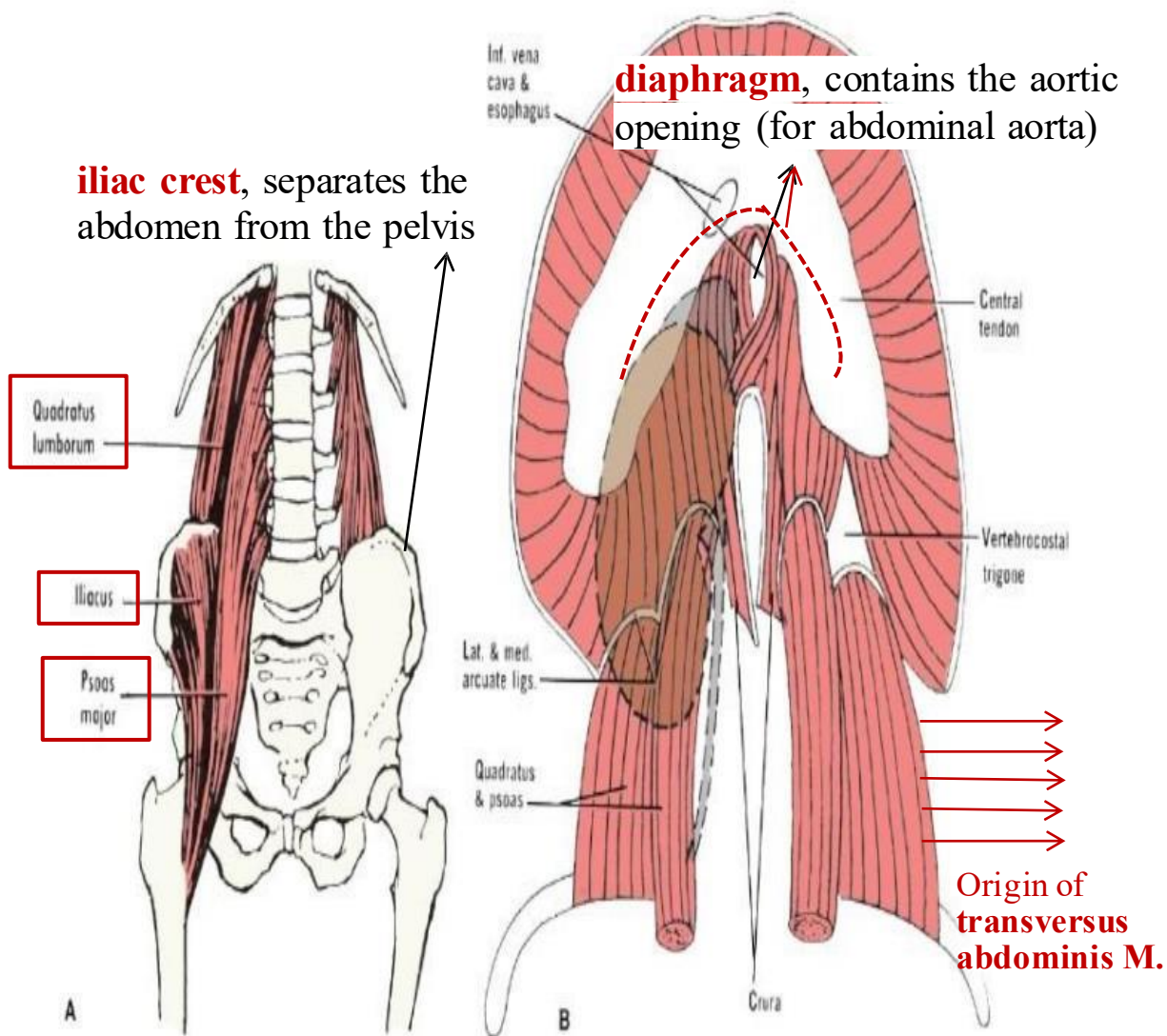
Reviewed by : Sara Al-Khateeb

The Posterior Abdominal wall

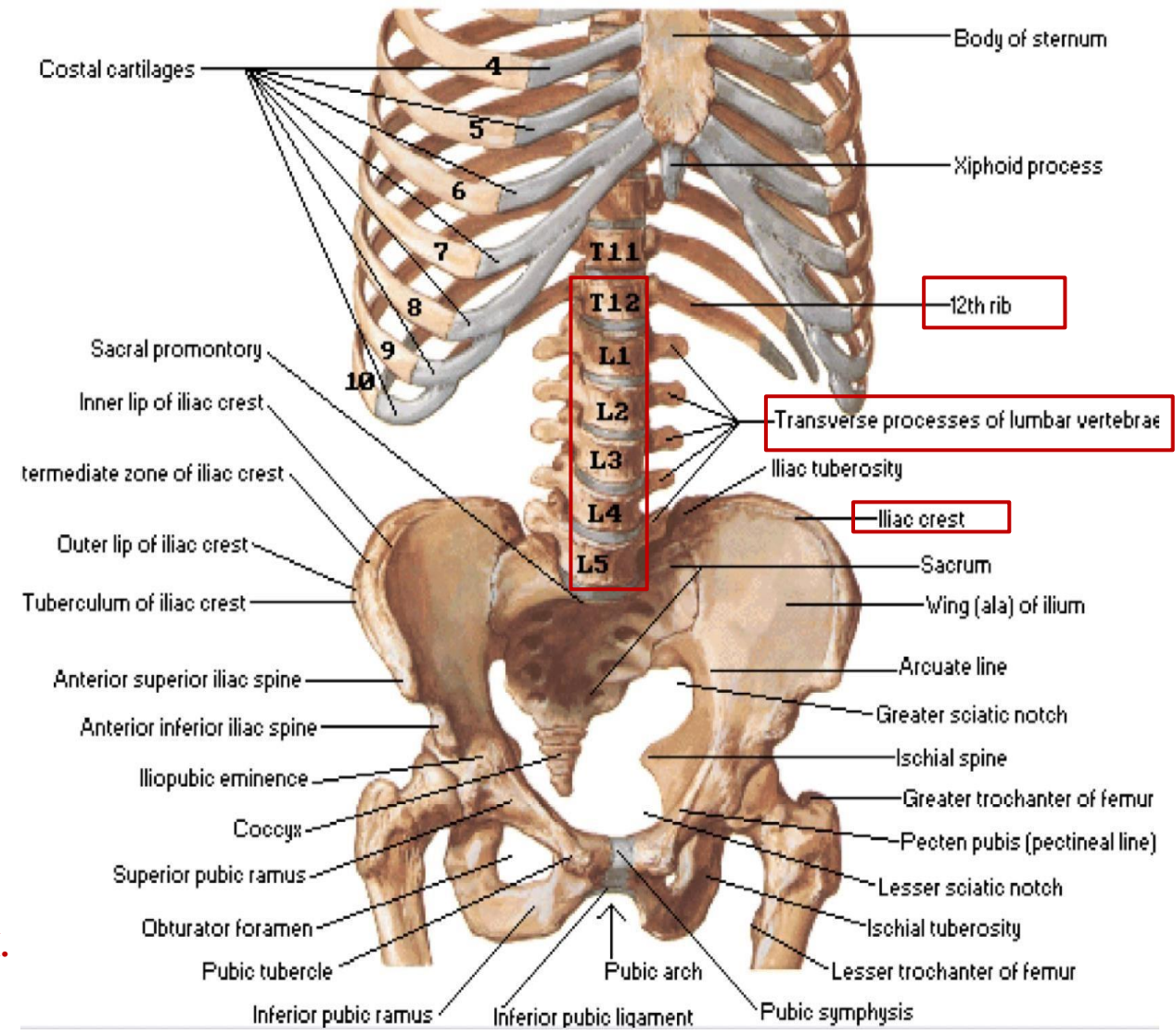
1- Structures of Posterior Abdominal wall

- **The posterior abdominal wall consists of :**
 - The **12th rib - T12** (last rib).
 - The **five lumbar vertebrae** and their **intervertebral discs**.
 - The **upper part of the bony pelvis**, specifically the **iliac crest**.
 - Muscles including:
 1. **Psoas major M.**
 2. **Psoas minor M.** (may be absent, if present it is used in 😊 **reconstructive surgeries**)
 3. **Quadratus lumborum M.**
 4. **Origin of transversus abdominis M.**
 5. **Iliacus M**, lies in the iliac fossa.
 6. **Diaphragm**, which contains the aortic opening (for abdominal aorta)





Dr.'s figure: MUSCLES

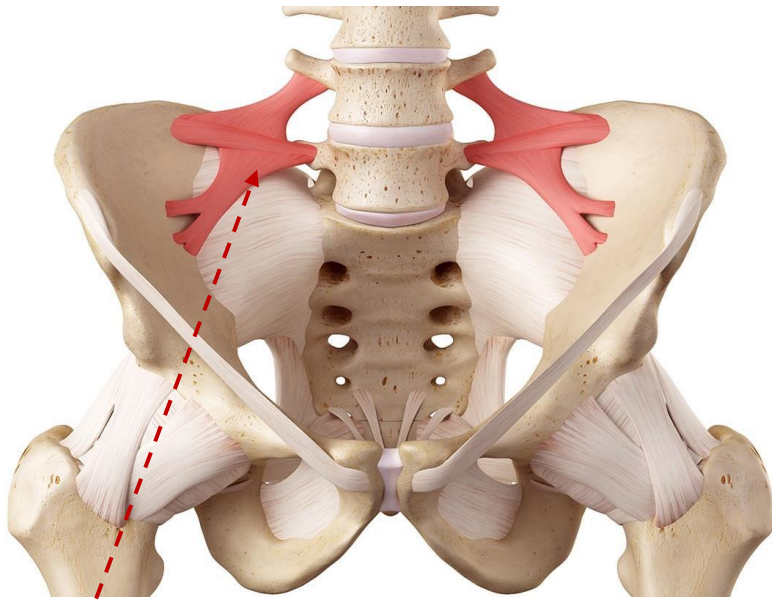


Dr.'s figure: BONES

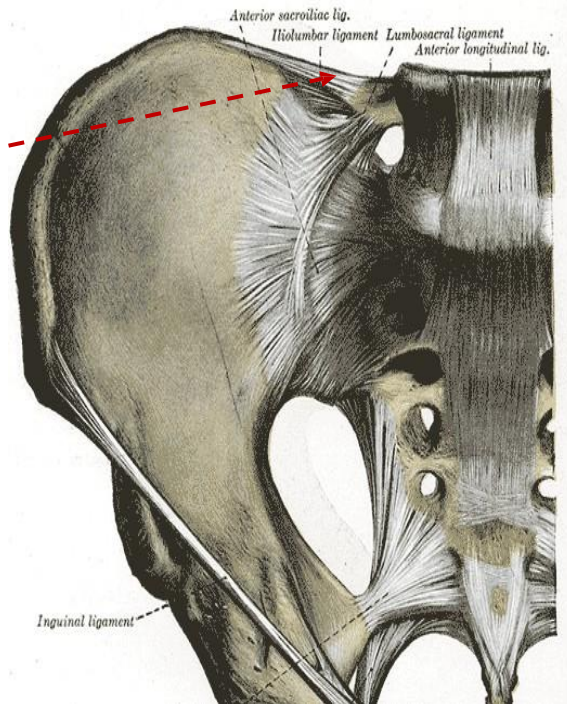
2- Muscles of posterior Abdominal wall

Muscle	Origin	Insertion	Nerve Supply	Action
Psoas Major	Body & transverse processes of lumbar vertebrae & intervertebral disc	Lesser trochanter of the femur	Lumbar plexus (T12, L1–L3)	<ul style="list-style-type: none"> • Both sides: trunk flexion (bending forward) • One side: lateral flexion
Quadratus Lumborum	*Iliolumbar ligament and iliac crest	12th rib		<ul style="list-style-type: none"> • Assists in respiration, (fixation of the last rib & contraction of other muscles) • Lateral flexion of trunk
Iliacus	Iliac fossa	Lesser trochanter of the femur	Femoral nerve	<ul style="list-style-type: none"> • Lateral Flexion of the hip and thigh (especially from lying position)

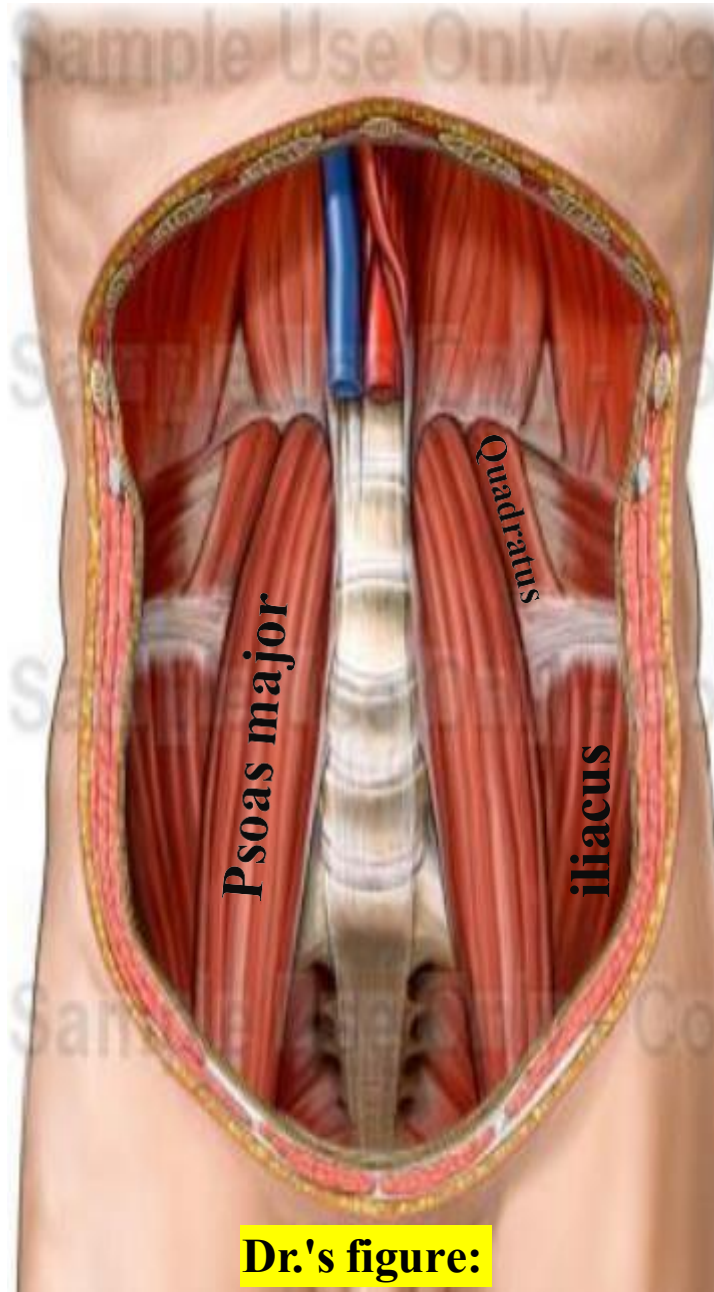
*The **iliolumbar ligament** is a strong ligament, located between the 5th lumbar vertebra to the iliac crest.



**iliolumbar
ligament**

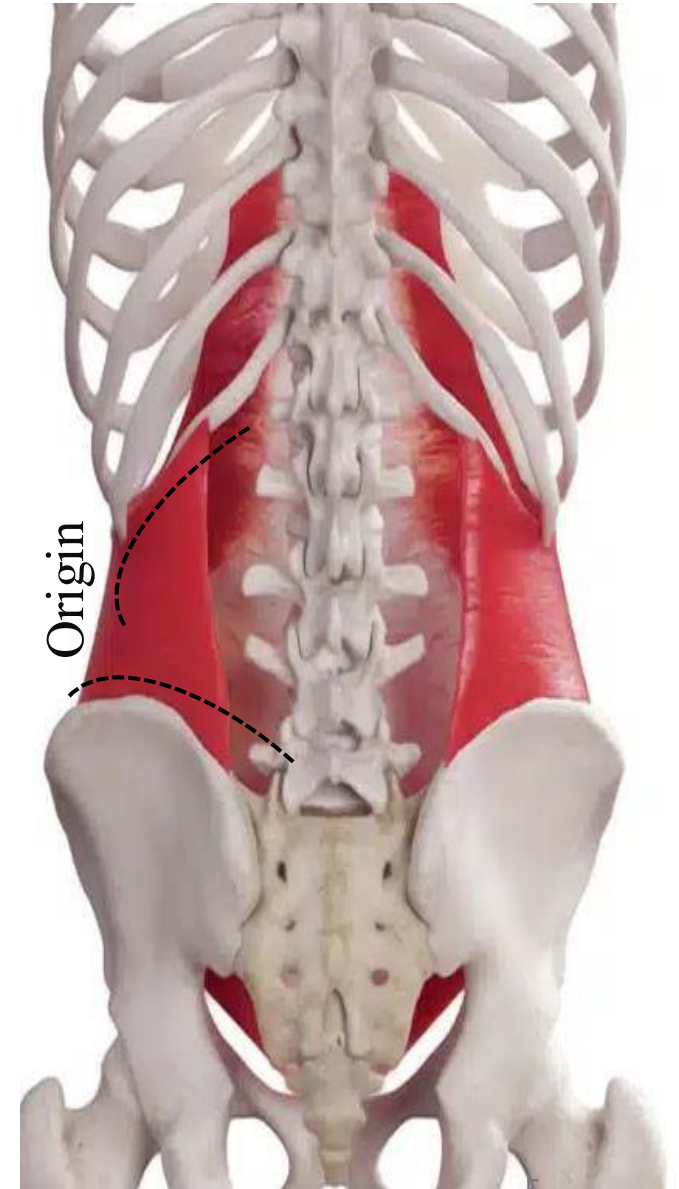


Dr.'s figure:

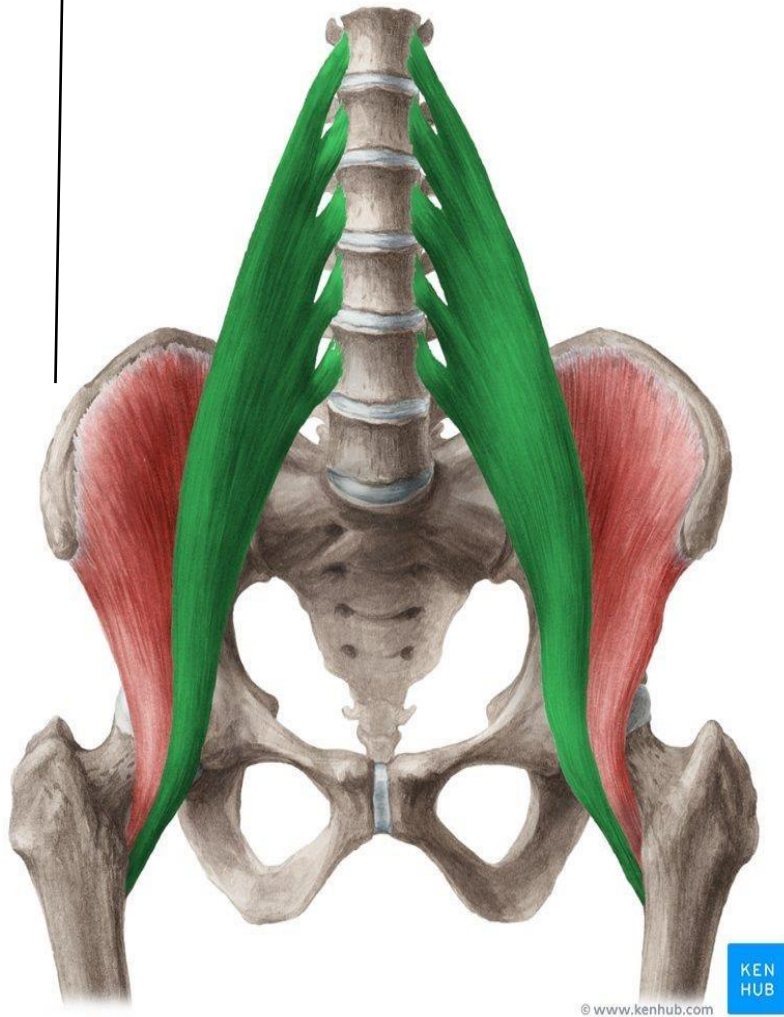


Dr.'s figure:

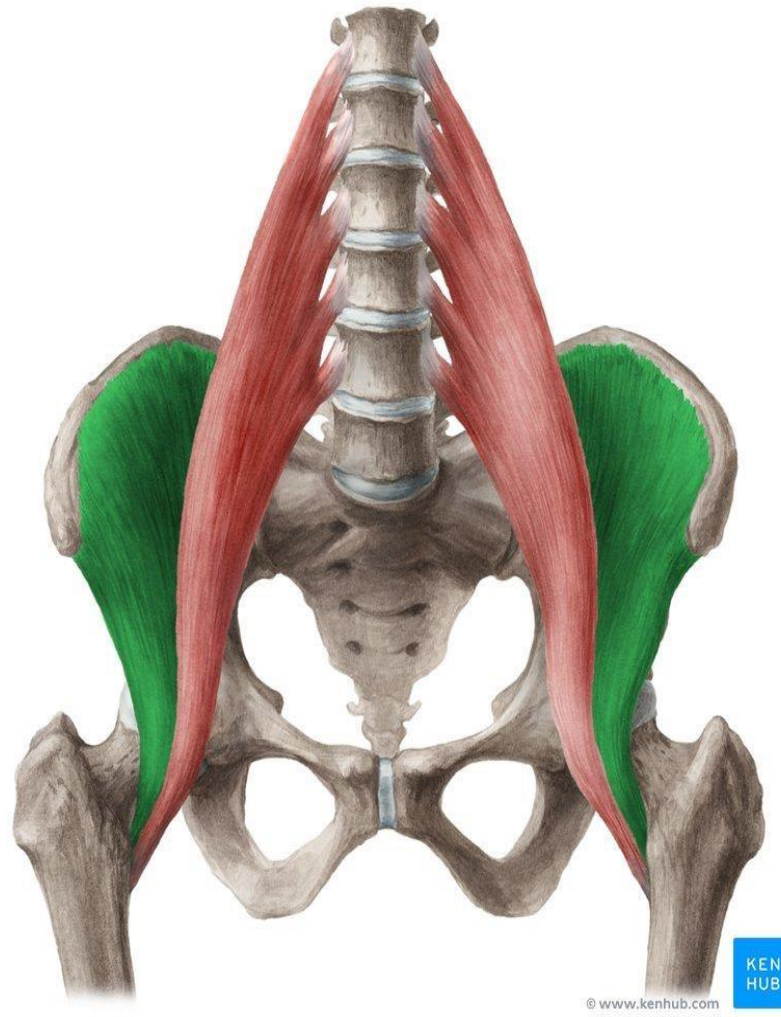
transversus abdominis M.



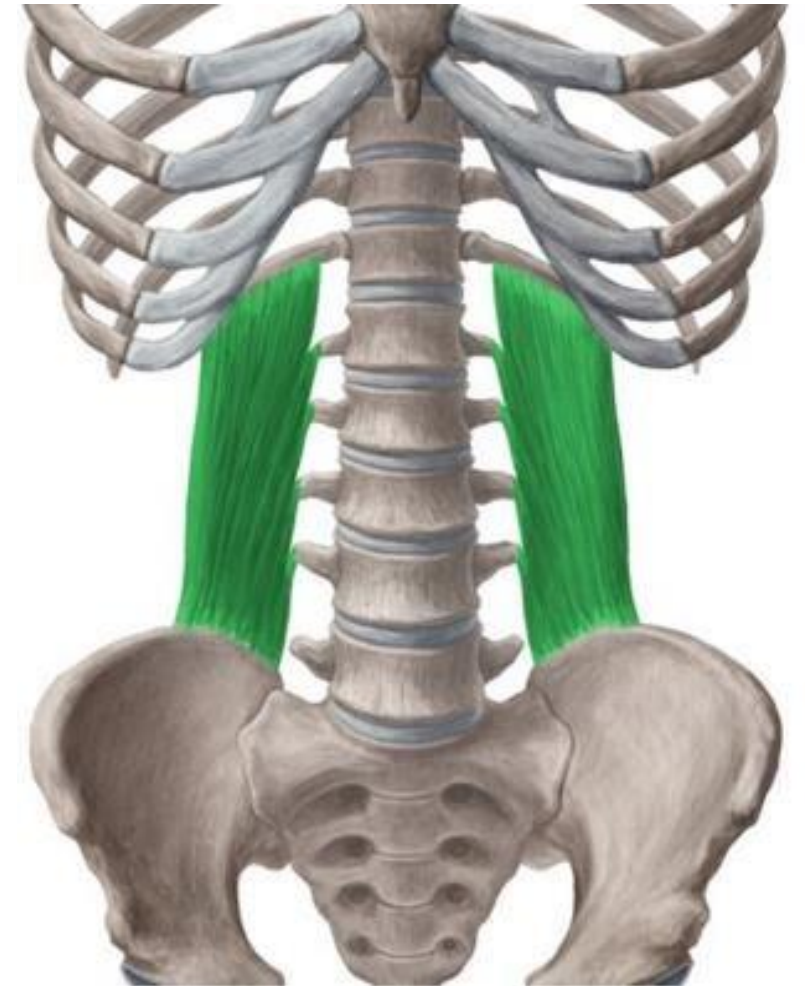
The most important muscle is the **psoas major**, because it is commonly involved in diseases, ☹️ **abscesses** may develop within it and can track downward into the pelvis. Thus, the **psoas fascia** is also clinically important, as it can guide the spread of infections.



Psoas Major



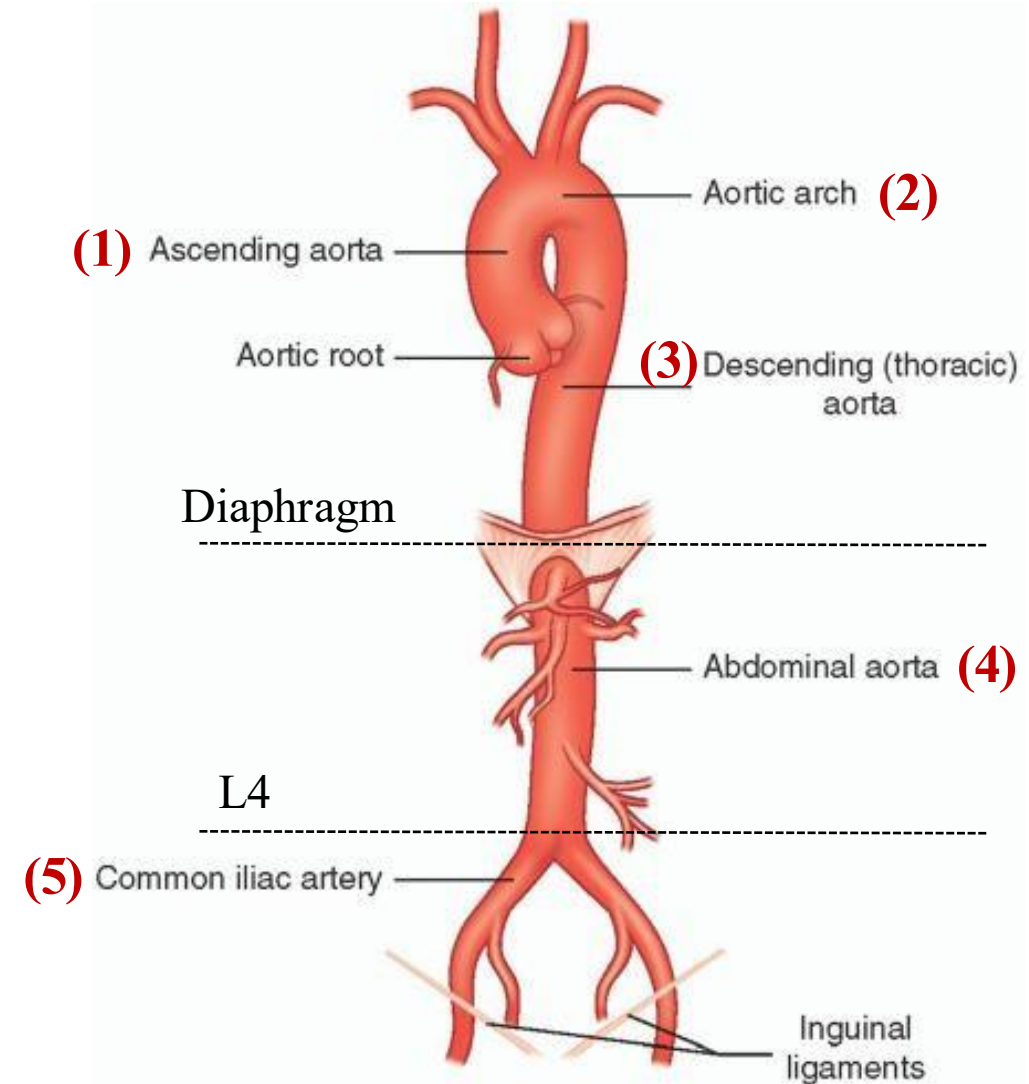
Iliacus



Quadratus Lumborum

3- AORTA – overview

- The heart gives rise to the **ascending aorta**, which continues as the **arch of the aorta**.
- Beyond the arch, it becomes the **descending aorta**, which has two parts:
 1. The **thoracic aorta** (within the chest)
 2. The **abdominal aorta** (after passing through the diaphragm) it ends at the level of **L4** by dividing into the **Right and left Common iliac arteries**.



4- Abdominal Aorta

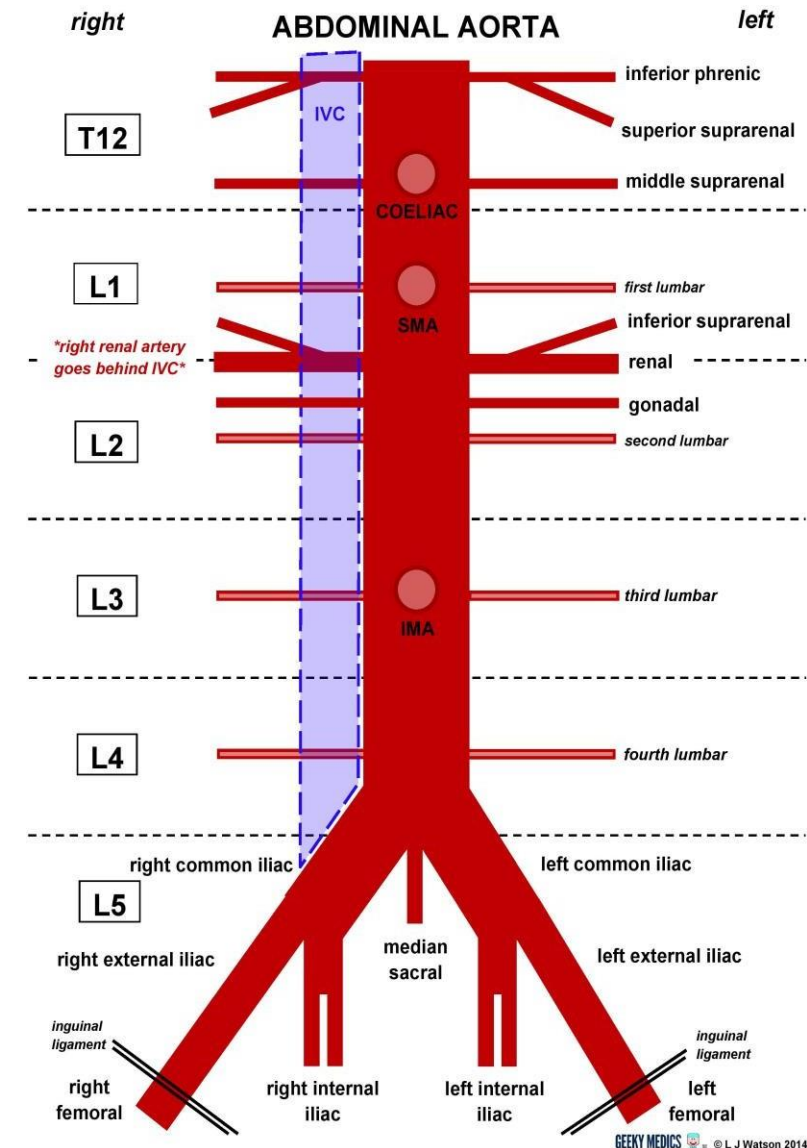
■ Abdominal Aorta Course

- The aorta enters the abdomen through the **aortic opening** of the diaphragm, midline in front of the **12th thoracic vertebra**.
- It descends behind **the peritoneum** (retroperitoneally) on the anterior surface of the bodies of the **lumbar vertebrae**.
- **End:** At the level of the **fourth lumbar vertebra** on the **left** side, it divides into **two common iliac arteries**.

■ Inferior vena cava:

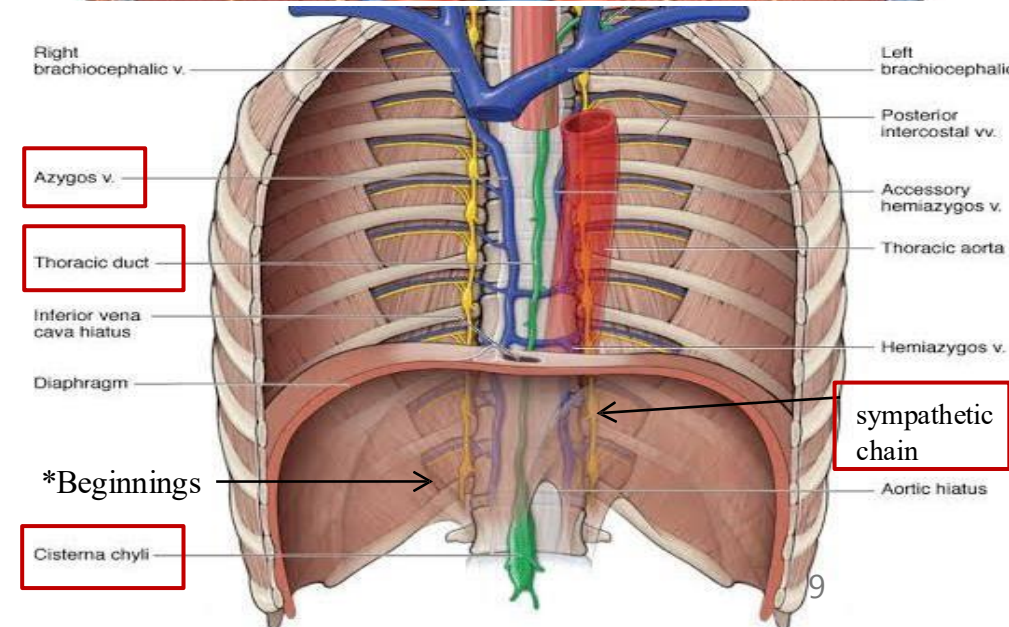
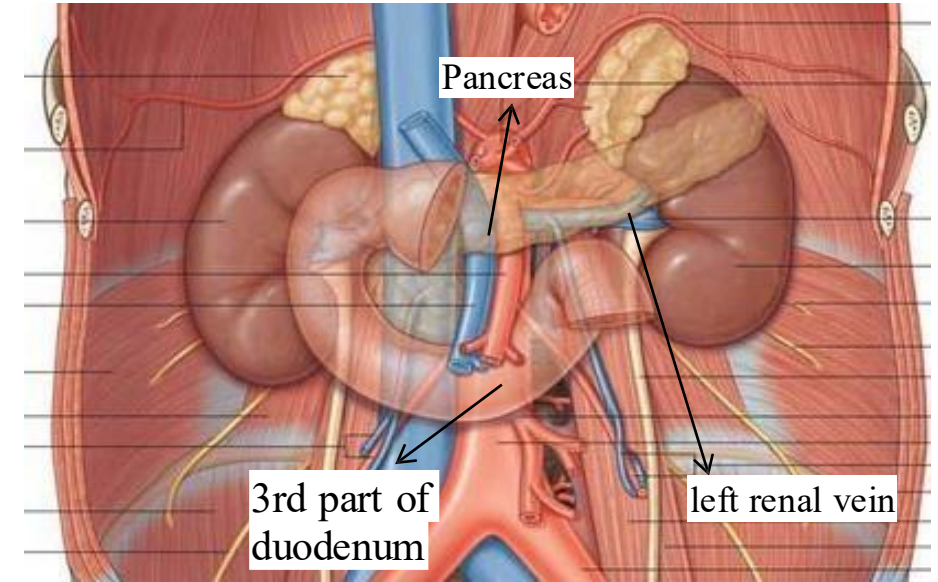
- Opposite to that, the **inferior vena cava (IVC)** begins at the level of the **5th lumbar vertebra**, on the **right** side.

✓ Note: both **IVC & abdominal aorta** are **retroperitoneal** organs.



5- Abdominal Aorta Relations

Surface/Side	Structures Related
Anterior	<ol style="list-style-type: none"> Pancreas 3rd part of the duodenum Coils of the small intestine Crossed by the left renal vein to drain into the IVC in the right side.
Right side	<ol style="list-style-type: none"> Inferior vena cava Cisterna chyli Beginning of the thoracic duct Beginning of the azygos vein
Left side	<ol style="list-style-type: none"> Abdominal sympathetic chain

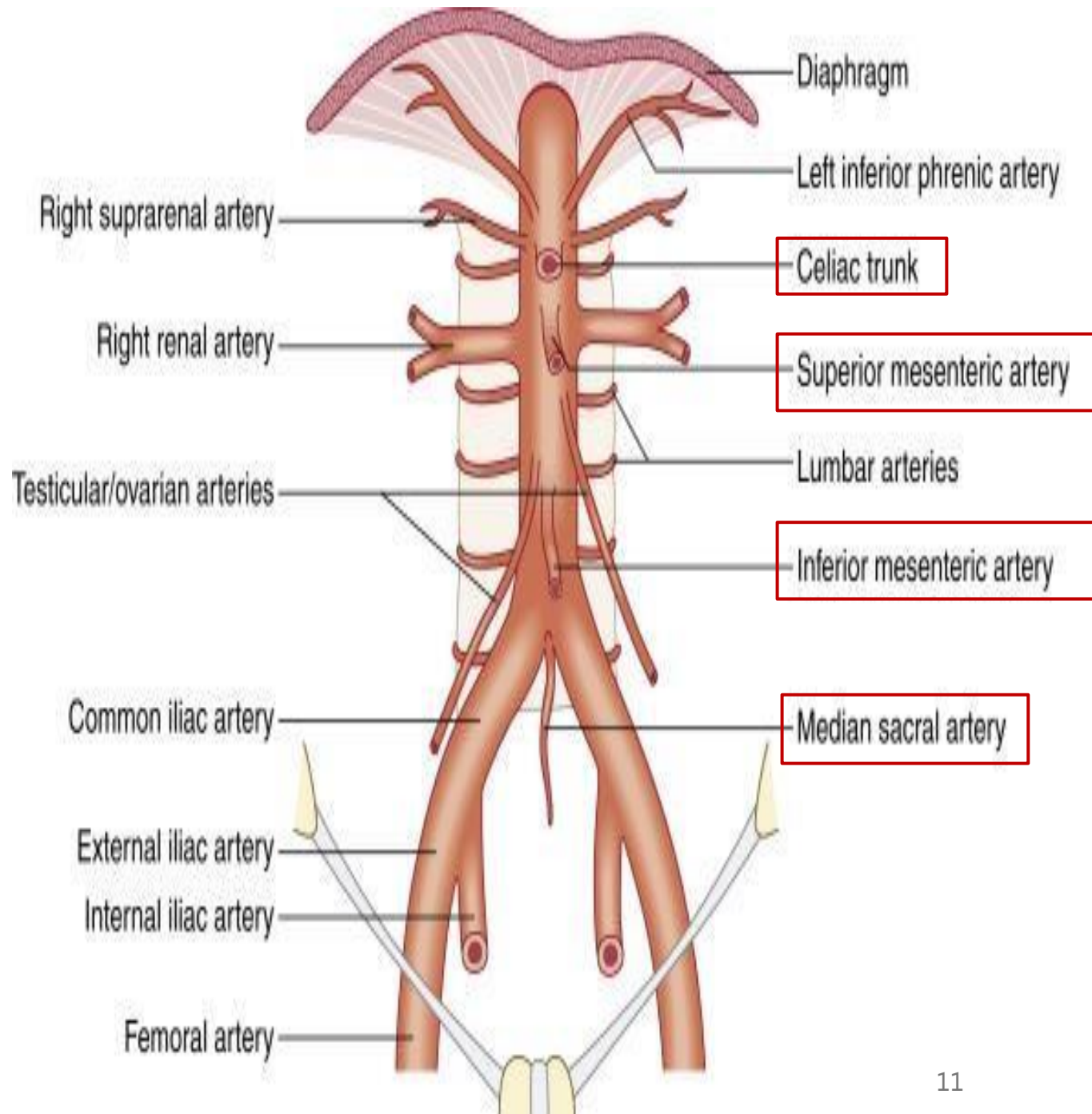
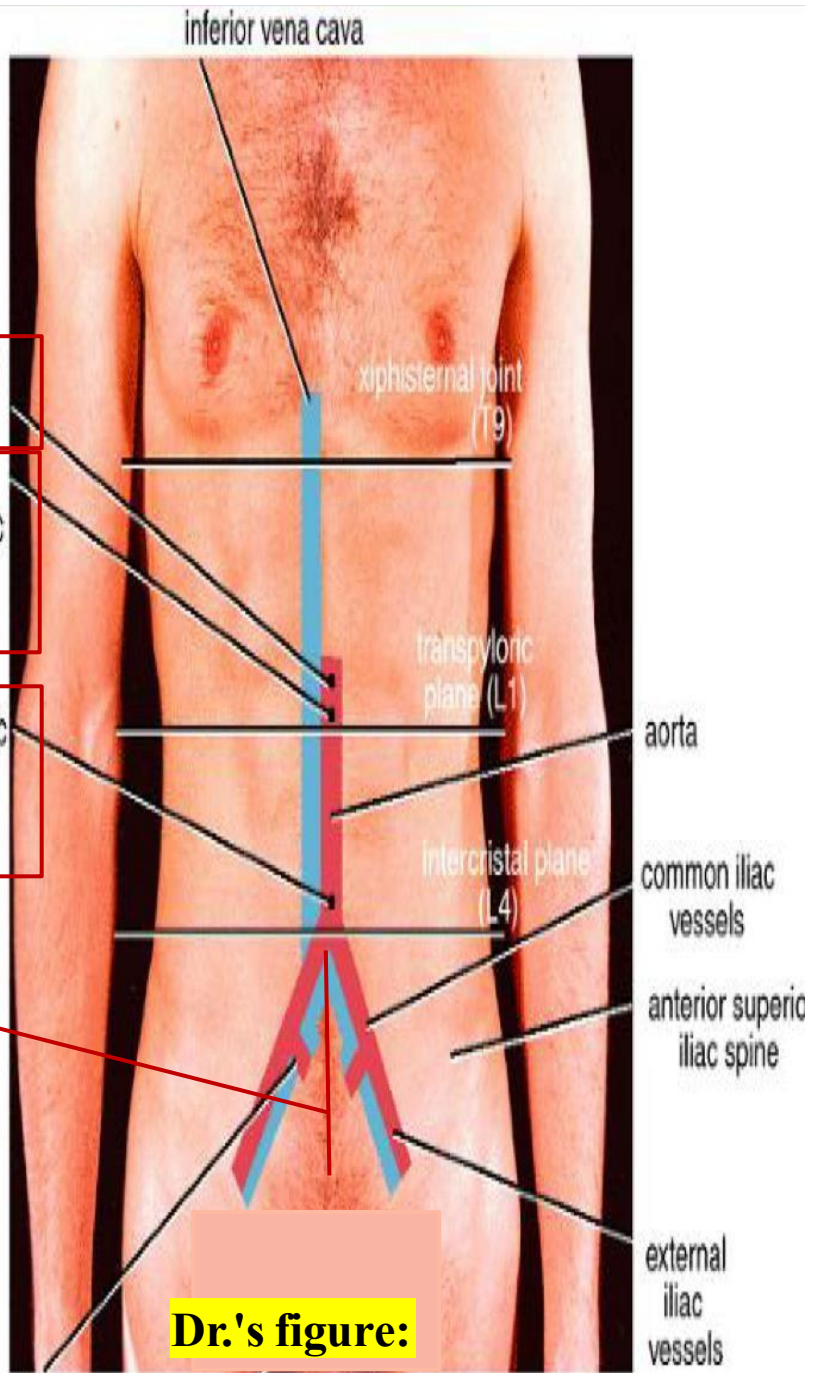


*These relations are very **important** in 😊 **abdominal surgery**, surgeons must be aware of these **relations** to **avoid** 😞 **injury to the aorta**, A mistake in this area can lead to severe **bleeding**.

6- Branches of the Abdominal Aorta

Type	Direction	Branches
Single	# (3) → Anterior (Front)	<ol style="list-style-type: none"> Celiac artery > supplies Foregut Superior mesenteric artery > supplies Midgut Inferior mesenteric artery > supplies Hindgut
	(1) → Posterior (Back)	<ul style="list-style-type: none"> Median sacral artery
Paired	(1) → Anterior (Front)	<ul style="list-style-type: none"> Testicular (male) or Ovarian (female) artery (At the level of L2)
	(4) → Posterior (Back)	<ul style="list-style-type: none"> (4) Lumbar arteries (anterior to lumbar vertebrae)
	(3) → Lateral (Side)	<ol style="list-style-type: none"> Inferior phrenic arteries Middle suprarenal arteries Renal arteries

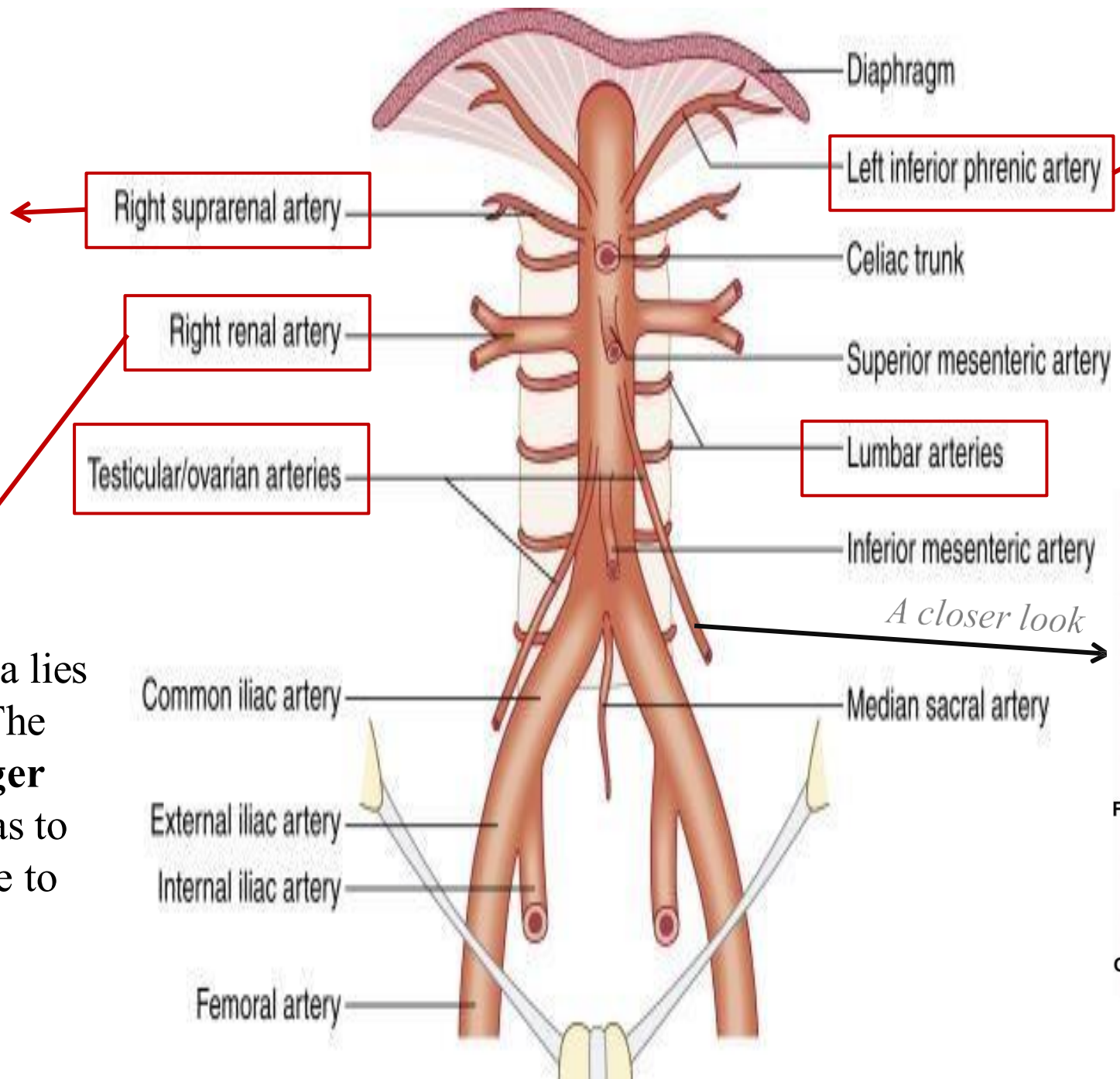
Single:



Paired:

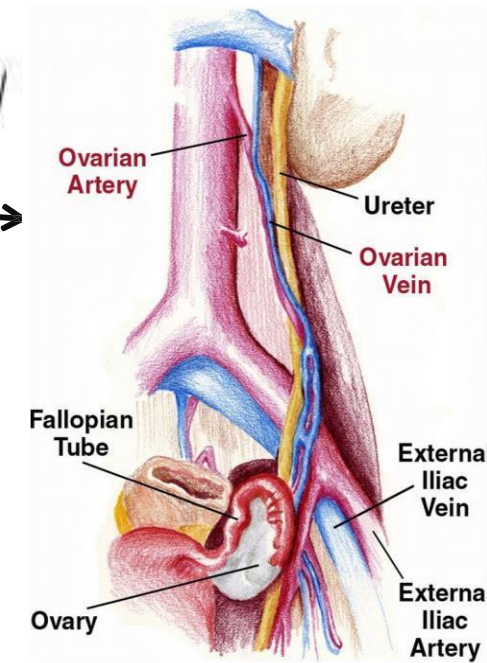
The **middle suprarenal artery** is one of three adrenal arteries (superior, middle, inferior), and it comes directly from the aorta.

Since The abdominal aorta lies closer to the left kidney. The **right renal artery is longer** than the left, because it has to cross over to the right side to reach the right kidney.



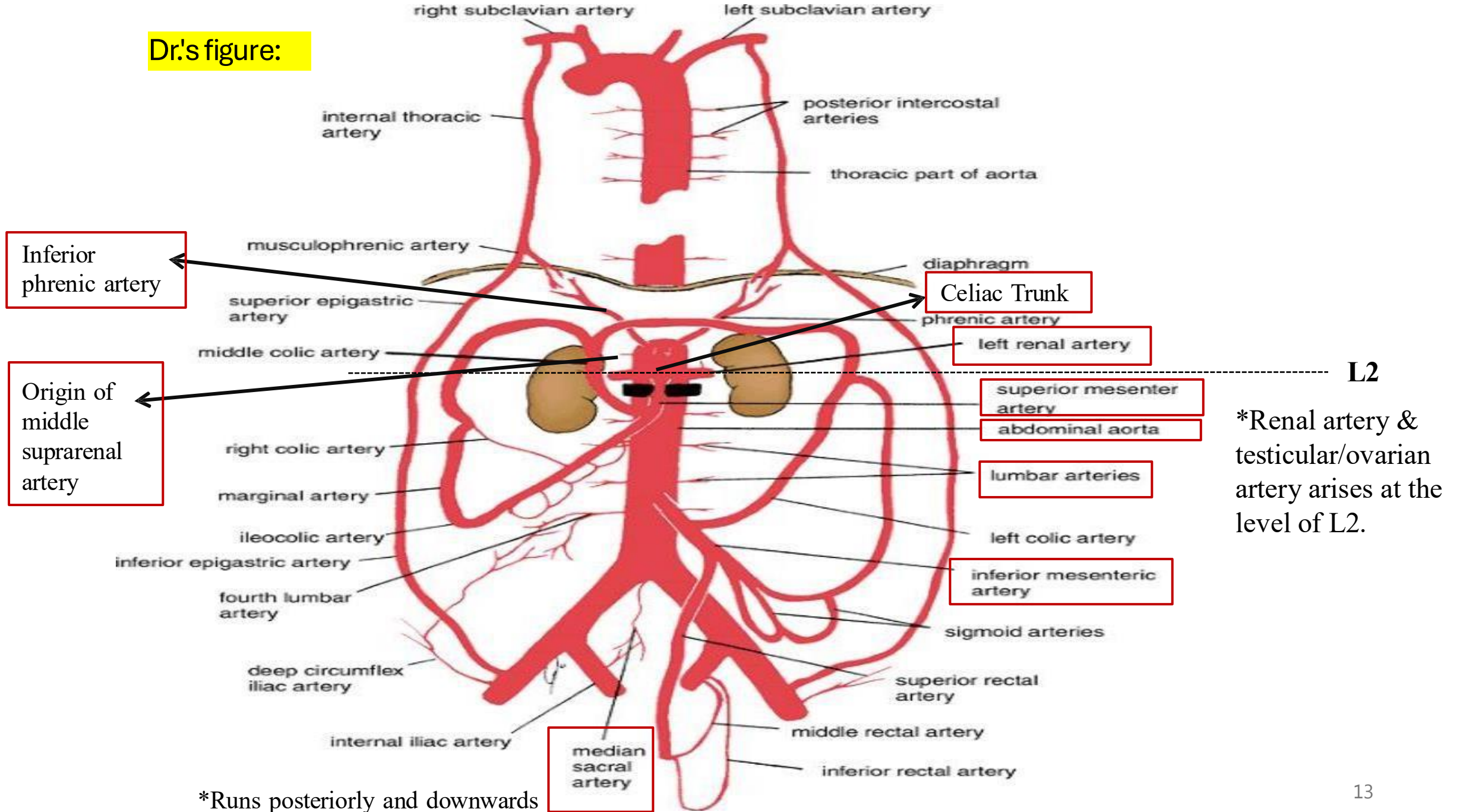
They arise just below the diaphragm, and supply it

A closer look



Dr.'s figure:

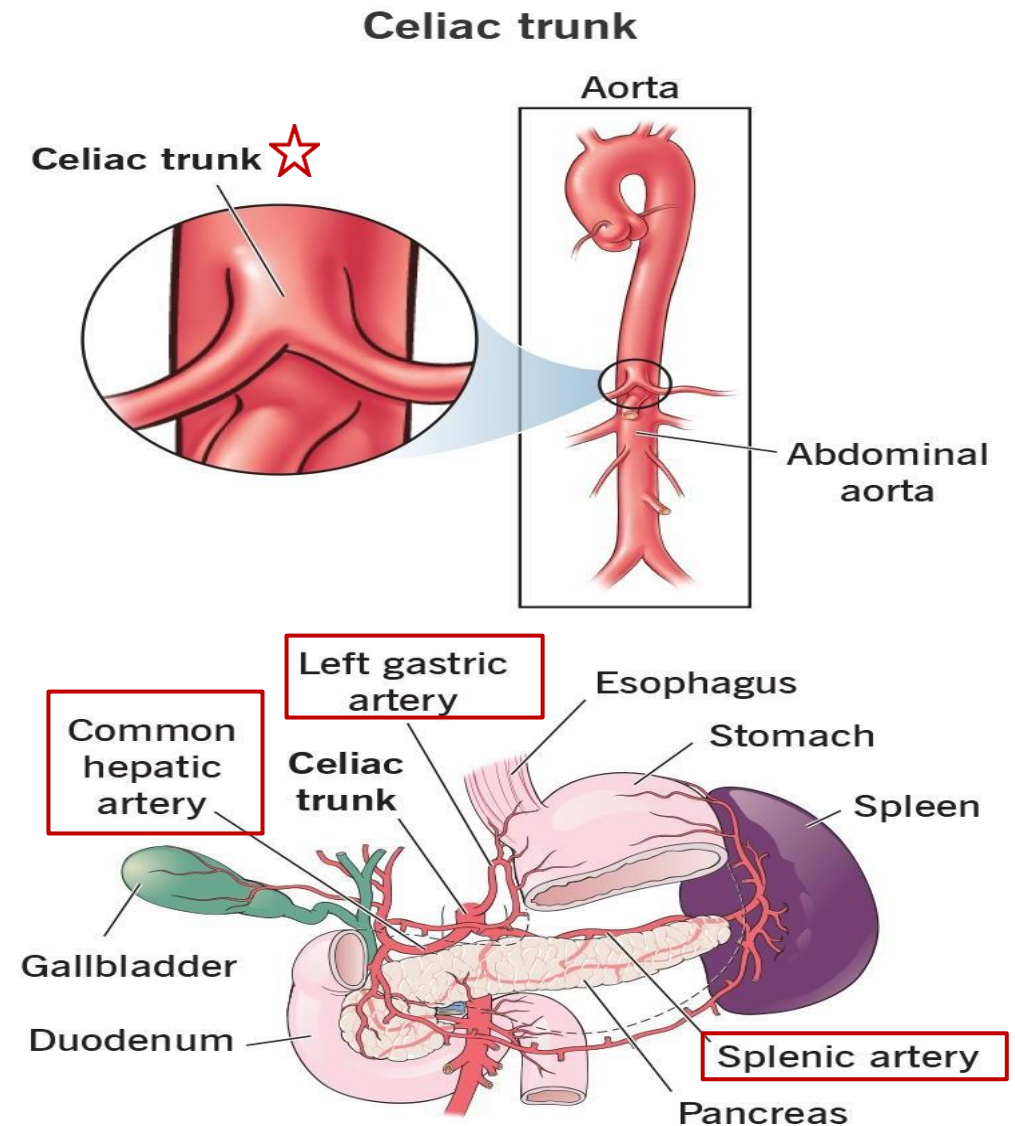
Dr.'s figure:



*Runs posteriorly and downwards

7- Celiac Trunk – overview

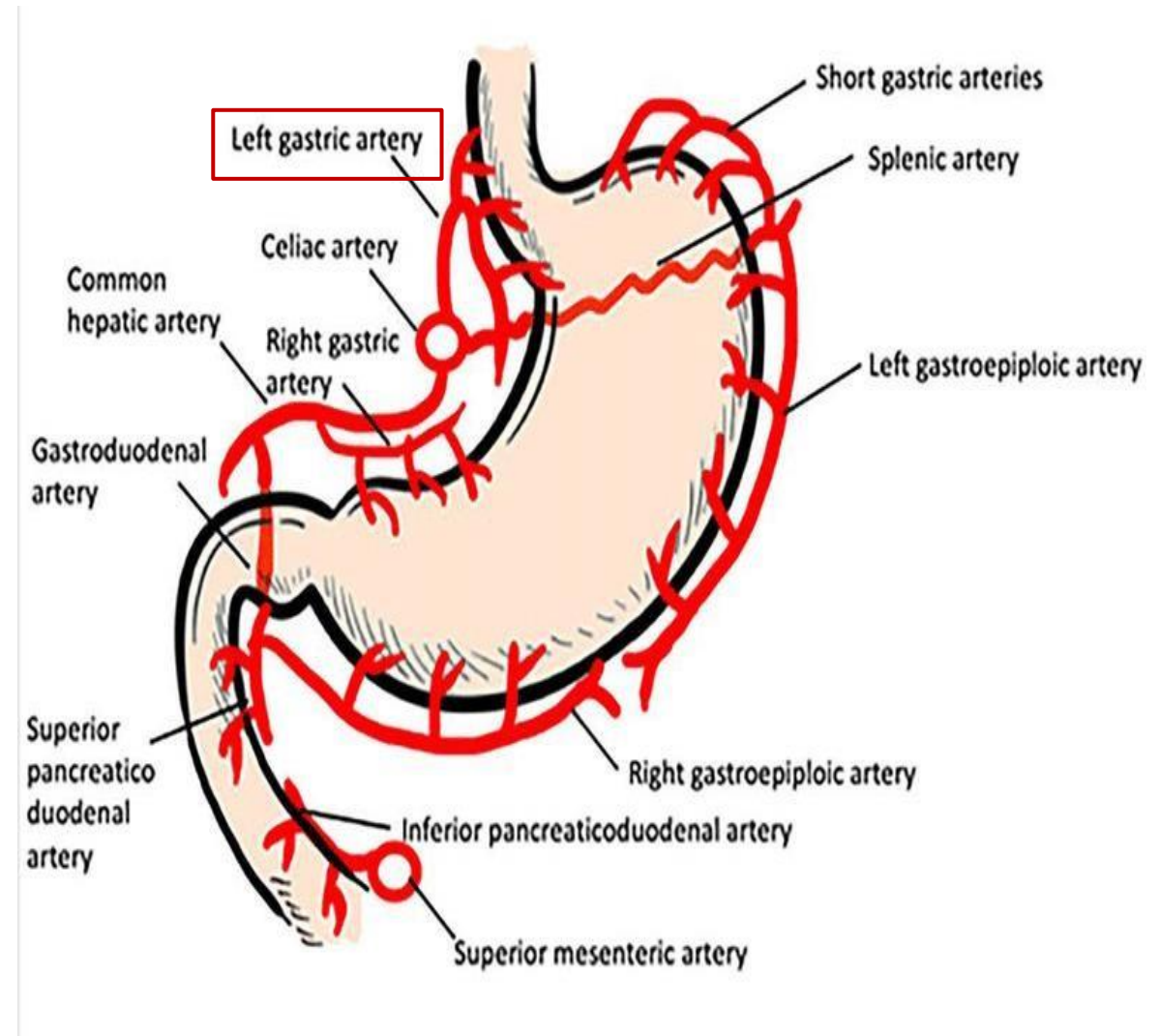
- The **celiac artery** is also known as the **celiac "trunk"** because it is **very short**, measuring approximately **1 cm** in length.
- It Arises from the **abdominal aorta** at the **upper border of L1** (some references may place it at the **lower border of T12**)
- Supplies the **foregut**
- It always gives rise to **three main branches**:
 1. **Left gastric artery**
 2. **Splenic artery**
 3. **Common hepatic artery**



8- Celiac trunk Branches

1. Left Gastric Artery

- Initially supplies the **lower third of the esophagus**. Then it descends along the **lesser curvature of the stomach**.
- It forms an **anastomosis** with the **right gastric artery**.
- Both the left and right gastric arteries are **contents of the lesser omentum**.



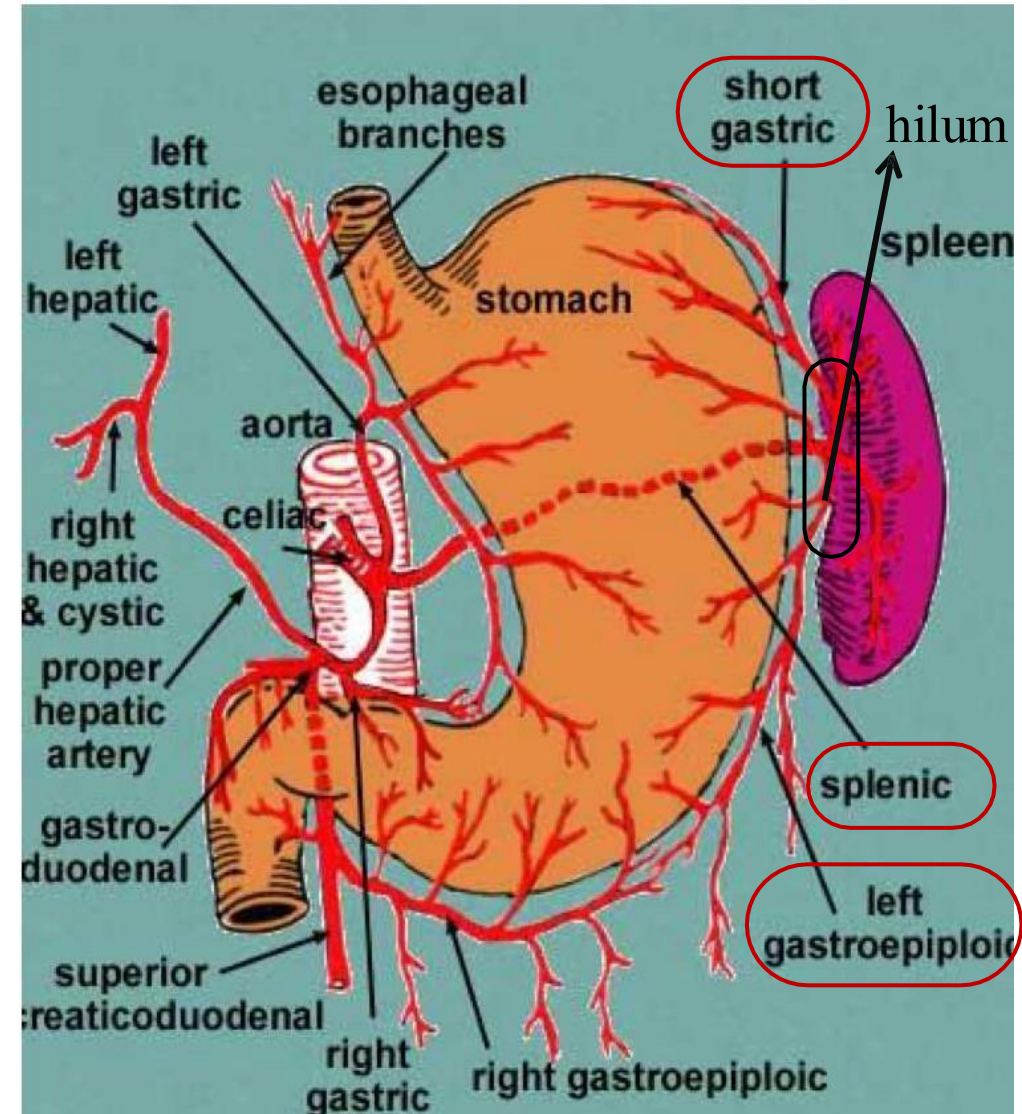
8- Celiac trunk Branches

2. Splenic Artery

- A **tortuous** (twisting) artery
- Runs along the **upper border of the pancreas**
- Ends at the **hilum of the spleen**

Branches of the Splenic Artery:

1. **Pancreatic branches** (anterior and posterior)
 - Supply the **body and tail of the pancreas**
2. **Short gastric arteries**
 - Supply the **fundus of the stomach** via the **gastrosplenic ligament**
3. **Left gastroepiploic artery** (also called **left gastro-omental artery**)
 - Supplies the **greater curvature of the stomach**



Dr.'s figure:

8- Celiac trunk Branches

3. Common Hepatic Artery

Branches of the Common Hepatic Artery:

1. Right Gastric Artery

- Runs along the **lesser curvature of the stomach**.
- Forms an **anastomosis** with the **left gastric artery**.

2. Gastroduodenal Artery

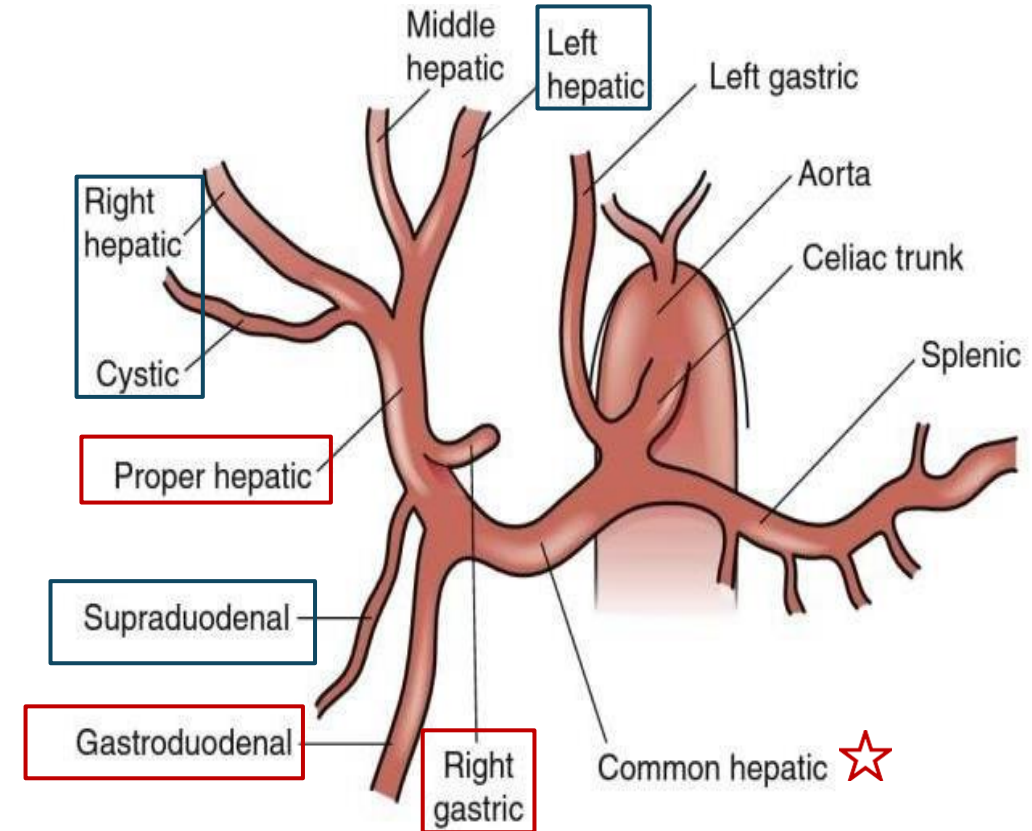
- Arises from the common hepatic artery before it becomes the **proper hepatic artery**. Giving the following branches:

- **Right gastroepiploic (gastro-omental) artery**
- **Superior pancreaticoduodenal artery**
- **Supraduodenal artery**
- **Retroduodenal artery**

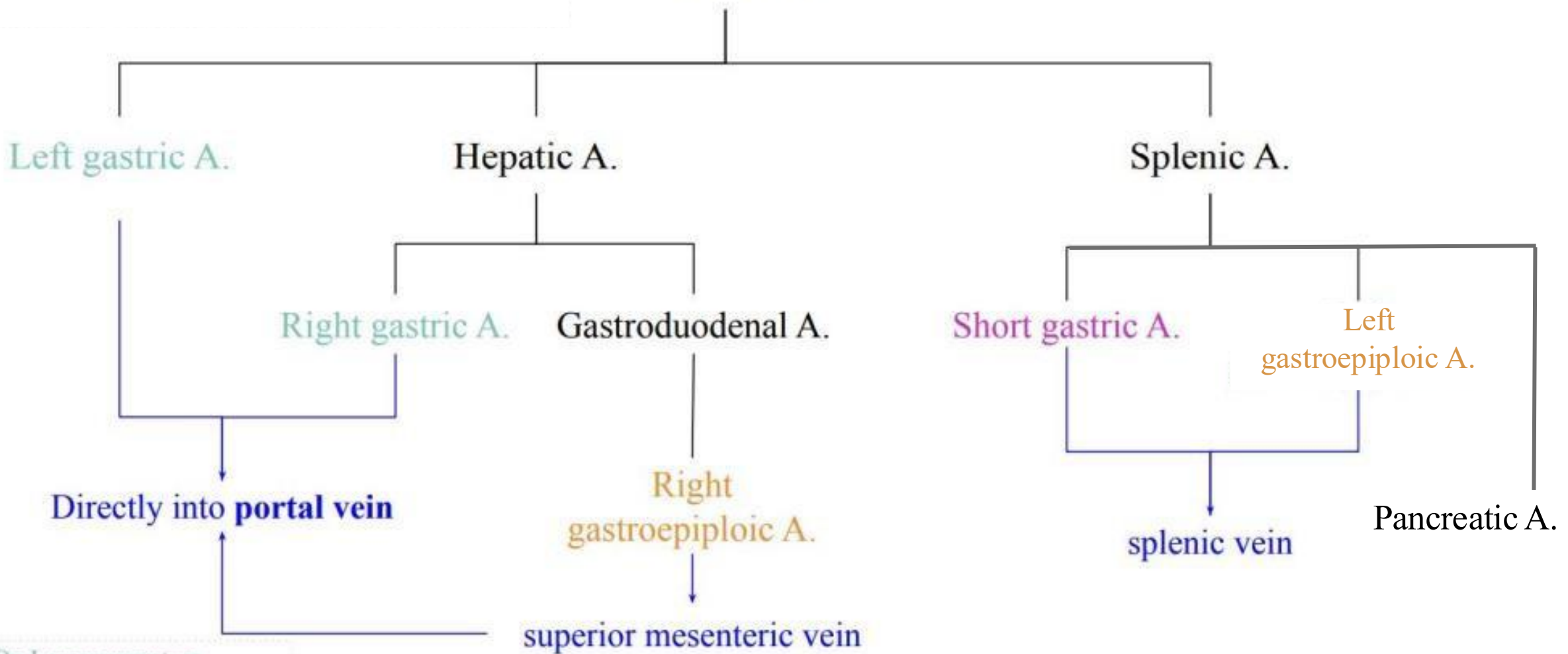
3. Proper Hepatic Artery

- Continuation of the common hepatic artery after the gastroduodenal artery branches off. It enters the **porta hepatis** and divides into:

- **Right hepatic artery** which Gives off the **cystic artery (to the gallbladder)**
- **Left hepatic artery**

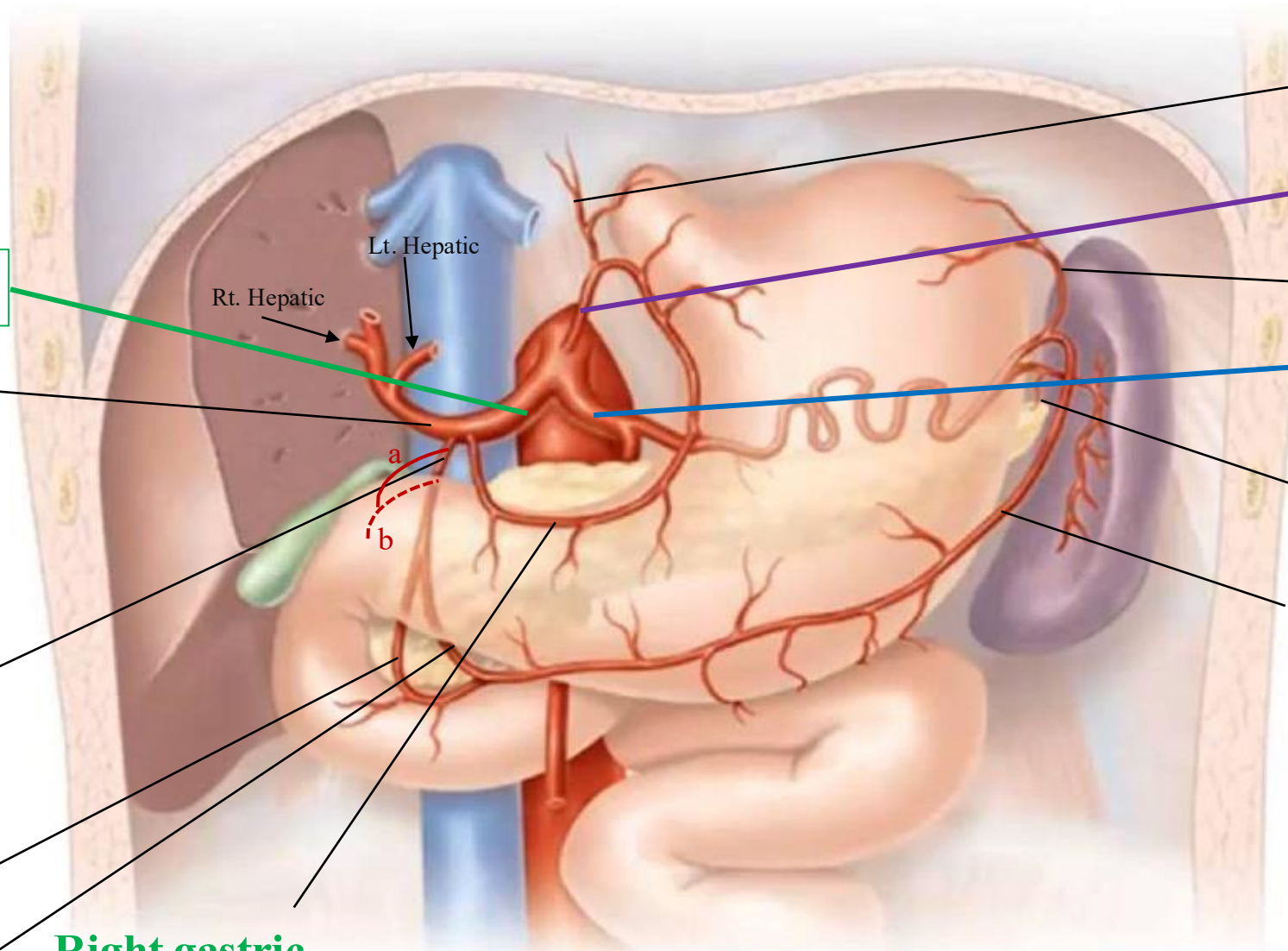


Celiac Trunk !



- On Lesser curvature
- On Greater curvature
- On fundus
- Venous Drainage

Celiac Trunk !



3. Common hepatic

Proper Hepatic

Divides into:

Rt. Hepatic Lt. Hepatic

Cystic artery

Gastroduodenal

- a) Supraduodenal
- b) Retroduodenal
- c) Superior pancreaticoduodenal
- d) Right gastroepiploic

Right gastric

Esophageal branch

1. Left gastric

Short gastric

2. Splenic artery

Pancreatic branches

Right gastroepiploic

Lt. Hepatic

Rt. Hepatic

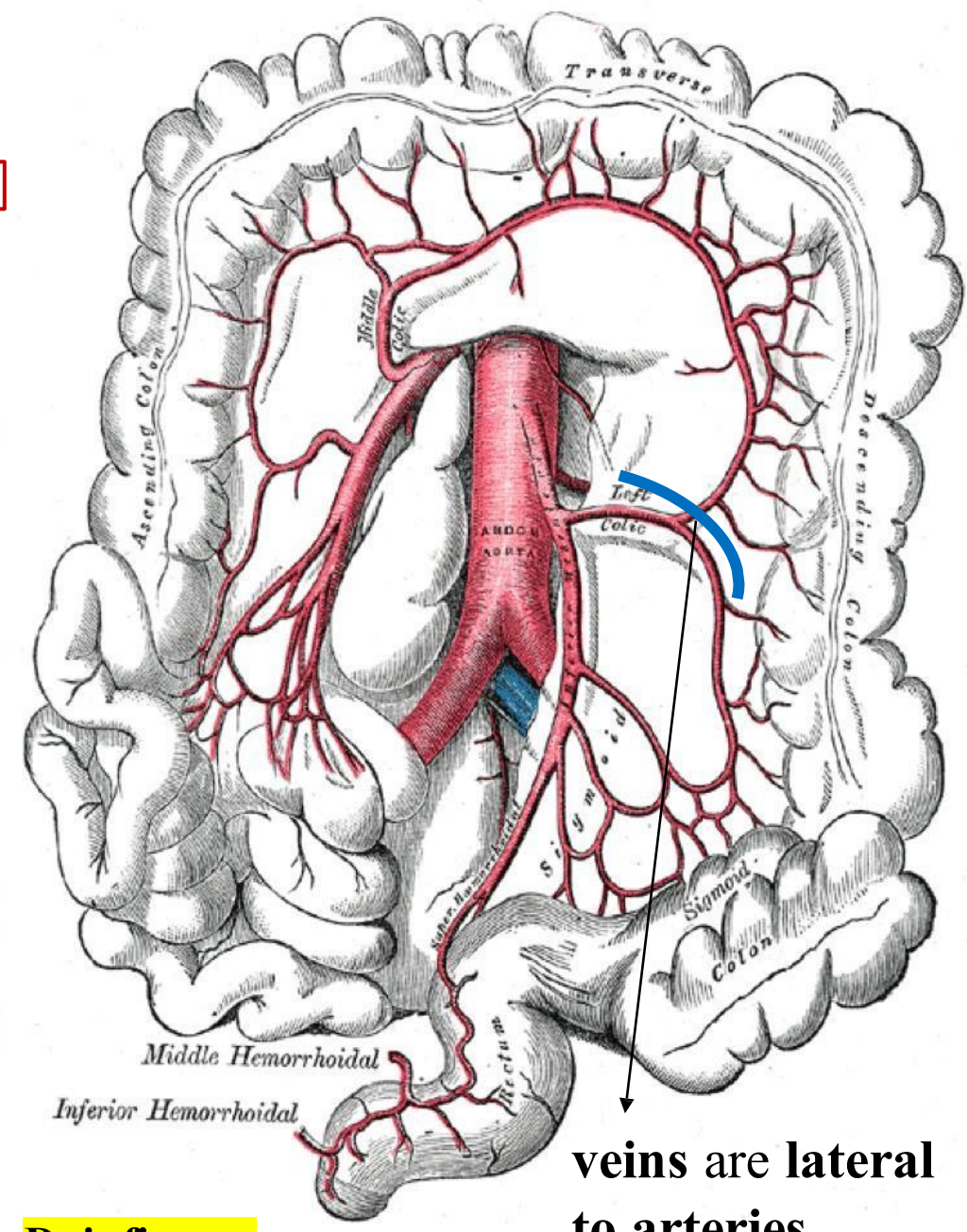
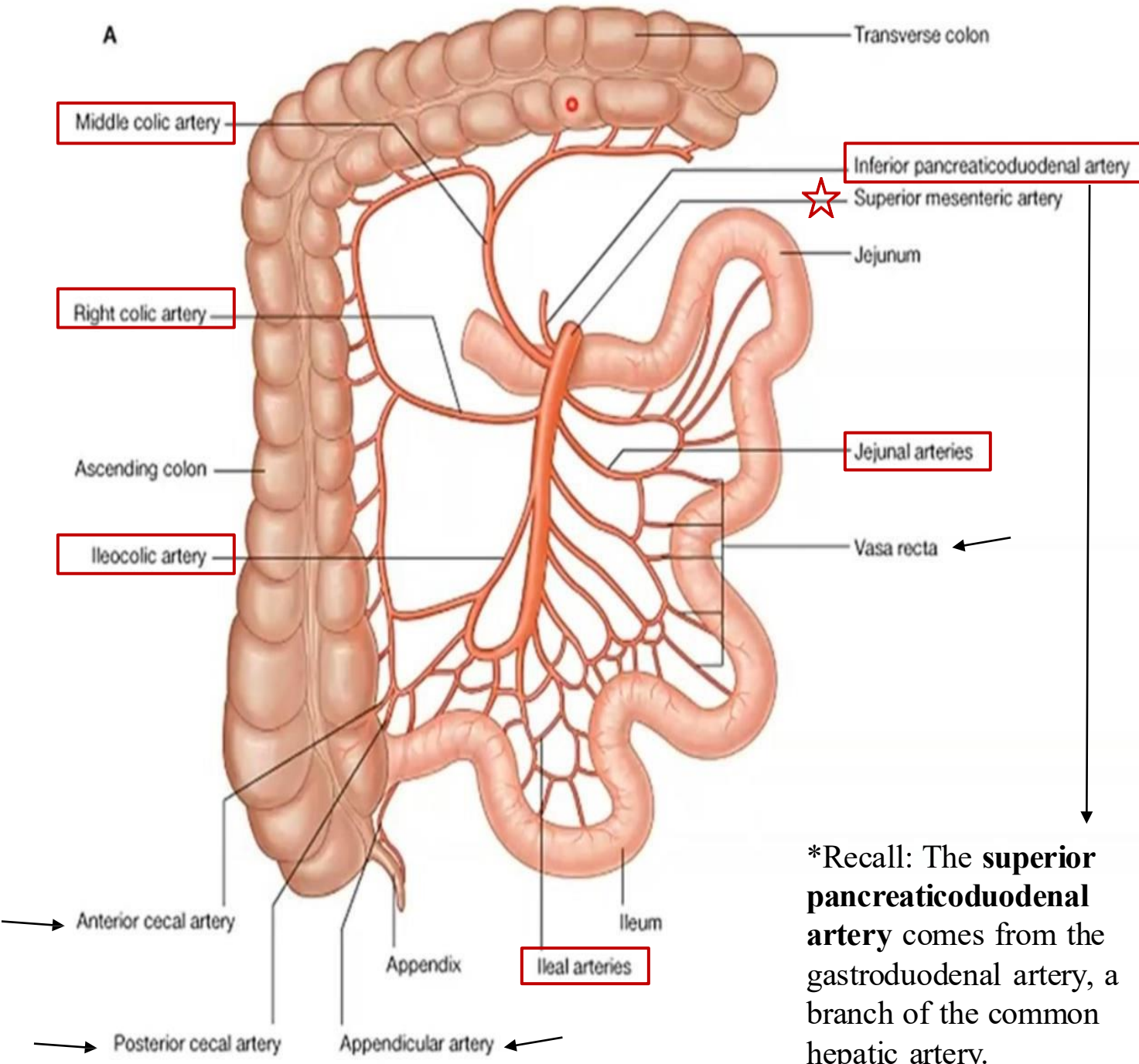
a

b

9 - Superior Mesenteric Artery (SMA)

- **Origin:** At the level of **L2** (lower border of L1 or upper border of L2)
- Supplies the **midgut**, The **superior mesenteric vein** lies to **right (lateral)** to the artery.

Branch	Description (Supply)	Gives Branches
Inferior pancreaticoduodenal artery	Supplies the lower half of the duodenum and pancreas.	—
Middle colic artery	Supplies the transverse colon; also branches to the ascending colon.	—
Right colic artery	Supplies the ascending colon.	—
Ileocolic artery	Supplies the terminal ileum and ascending colon.	Anterior and Posterior cecal arteries (Appendicular artery is a branch of the posterior Cecal artery)
Jejunal and ileal branches	Supply the jejunum and ileum.	Arise from the left side of the SMA, Form arterial arcades and vasa recta within the mesentery



*Recall: The **superior pancreaticoduodenal artery** comes from the gastroduodenal artery, a branch of the common hepatic artery.

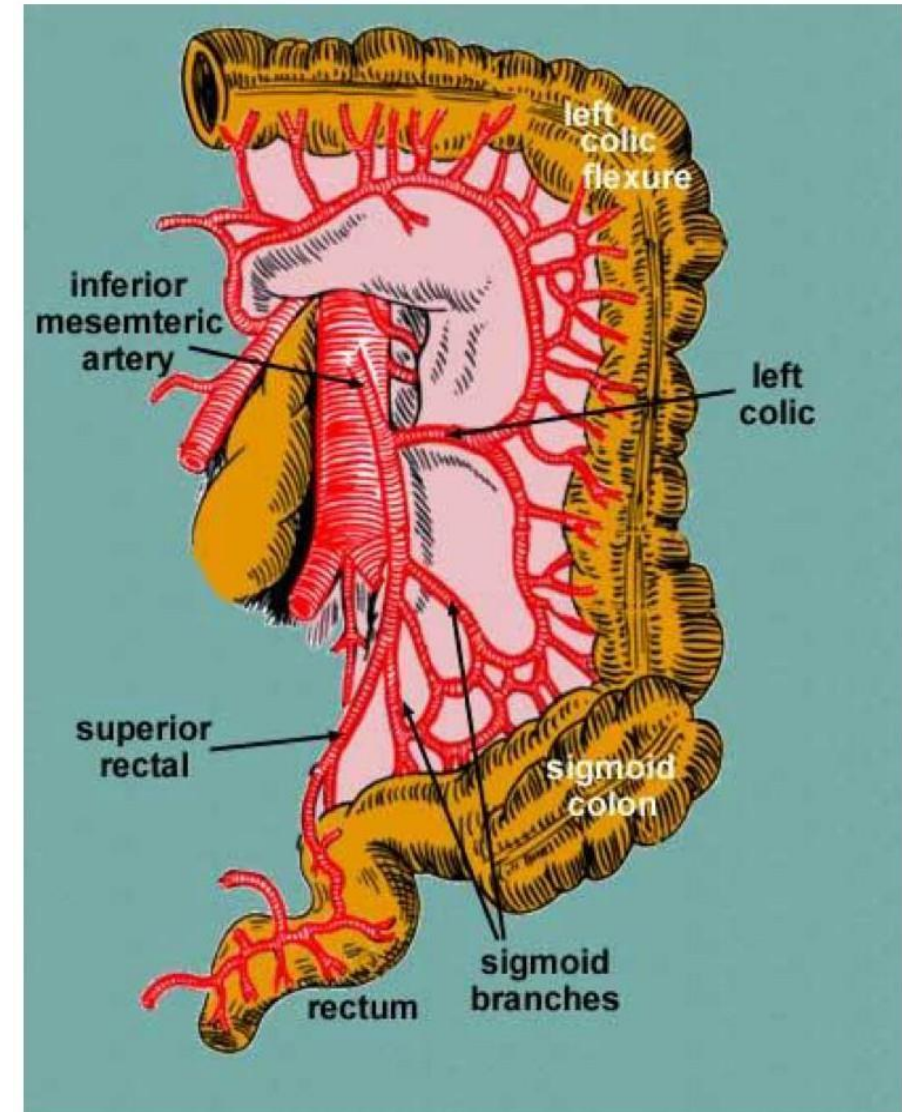
Dr.'s figure:

veins are lateral to arteries.

10- Inferior Mesenteric Artery (IAM)

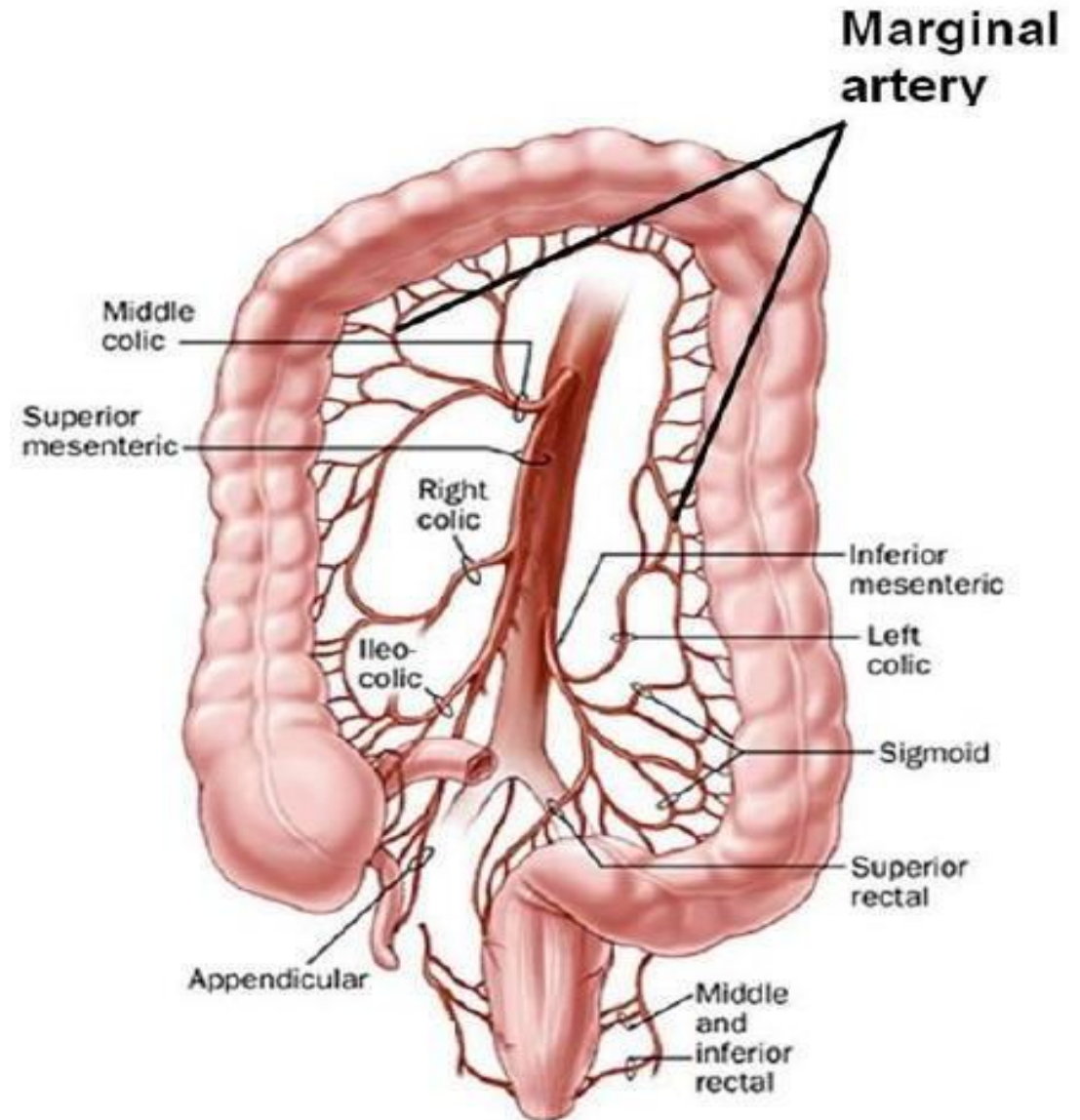
- Origin: At the level of **L3**
- Supplies the **hindgut**

Branch	Description (Supply)
Left colic artery	Supplies the lateral third of the transverse colon and the descending colon .
Sigmoid arteries	Supply the sigmoid colon .
Superior rectal artery	Continuation of the IMA; supplies the rectum and upper half of the anal canal .



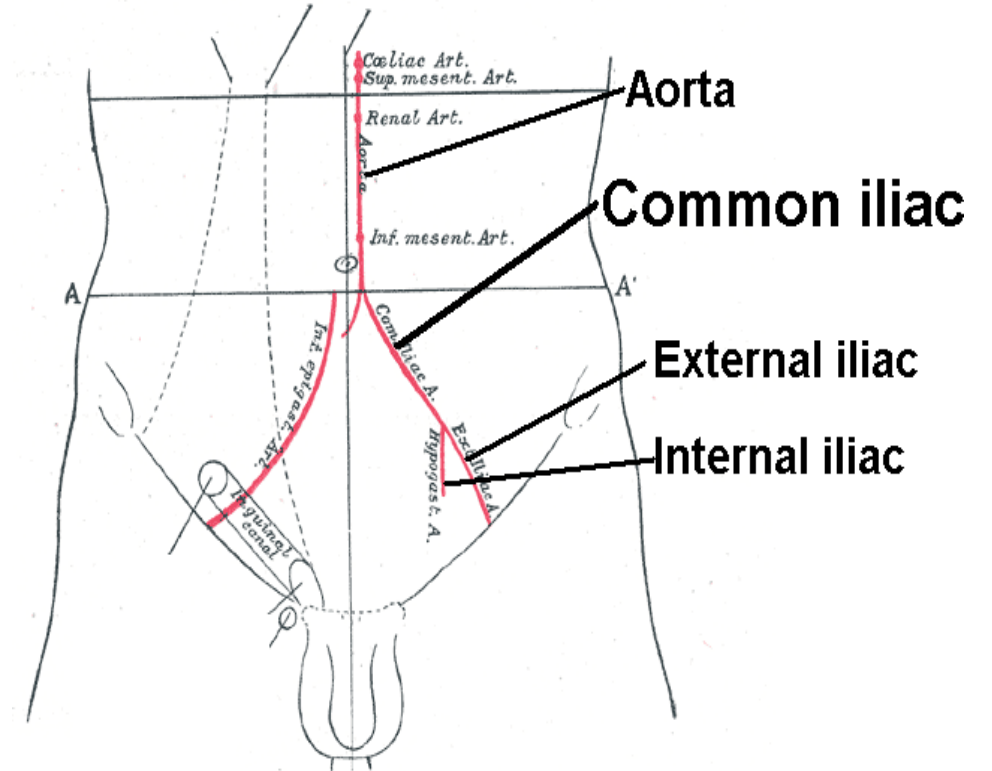
11- Marginal Artery

- **The marginal artery** is formed by the anastomosis of branches that run along the **concavity of the large intestine**.
- These branches include arteries that supply the **ascending colon, transverse colon, descending colon, and sigmoid colon**.
- The marginal artery creates a **continuous arterial arcade**, providing **collateral circulation** in case of 😞 **arterial blockage**. Thus, if a main artery is blocked, the marginal artery can help maintain blood flow



12- Common Iliac Arteries

- The **abdominal aorta ends** at the level of **L4**, slightly on the **left side**, and divides into **Right** and **Left Common Iliac Arteries**.
- Each Common Iliac Artery divides at the **pelvic brim/inlet** into:
 - **External Iliac Artery**
 - **Internal Iliac Artery**



13- External Iliac Artery

1. External Iliac Artery ---> supplies lower limb

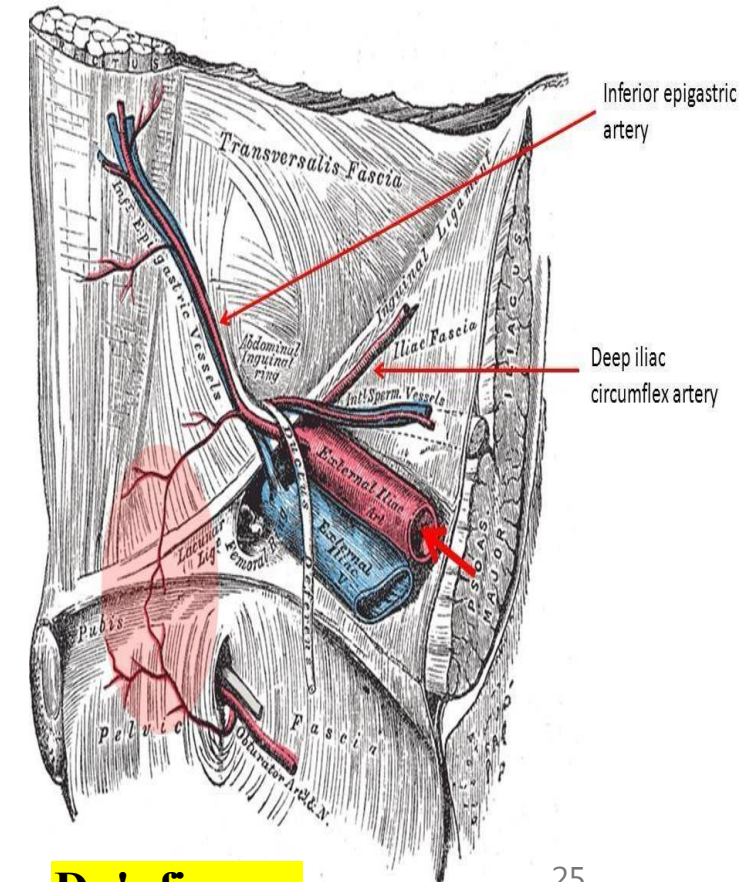
Runs on the medial border of the psoas muscle, reaches the pelvic brim, and gives the **deep circumflex iliac artery & Inferior Epigastric Artery**, the artery then enters the lower limb to become the femoral artery.

• Inferior Epigastric Artery

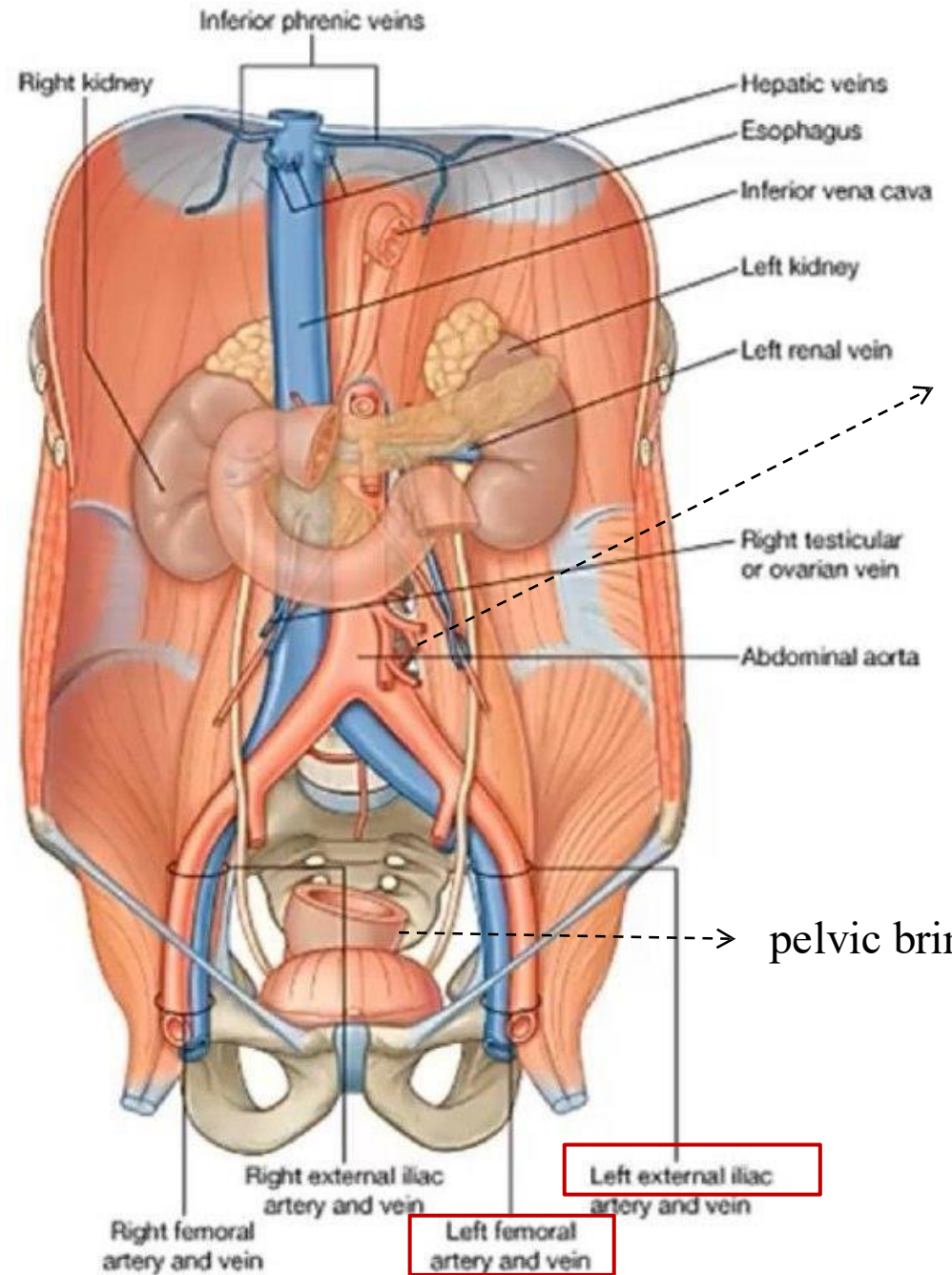
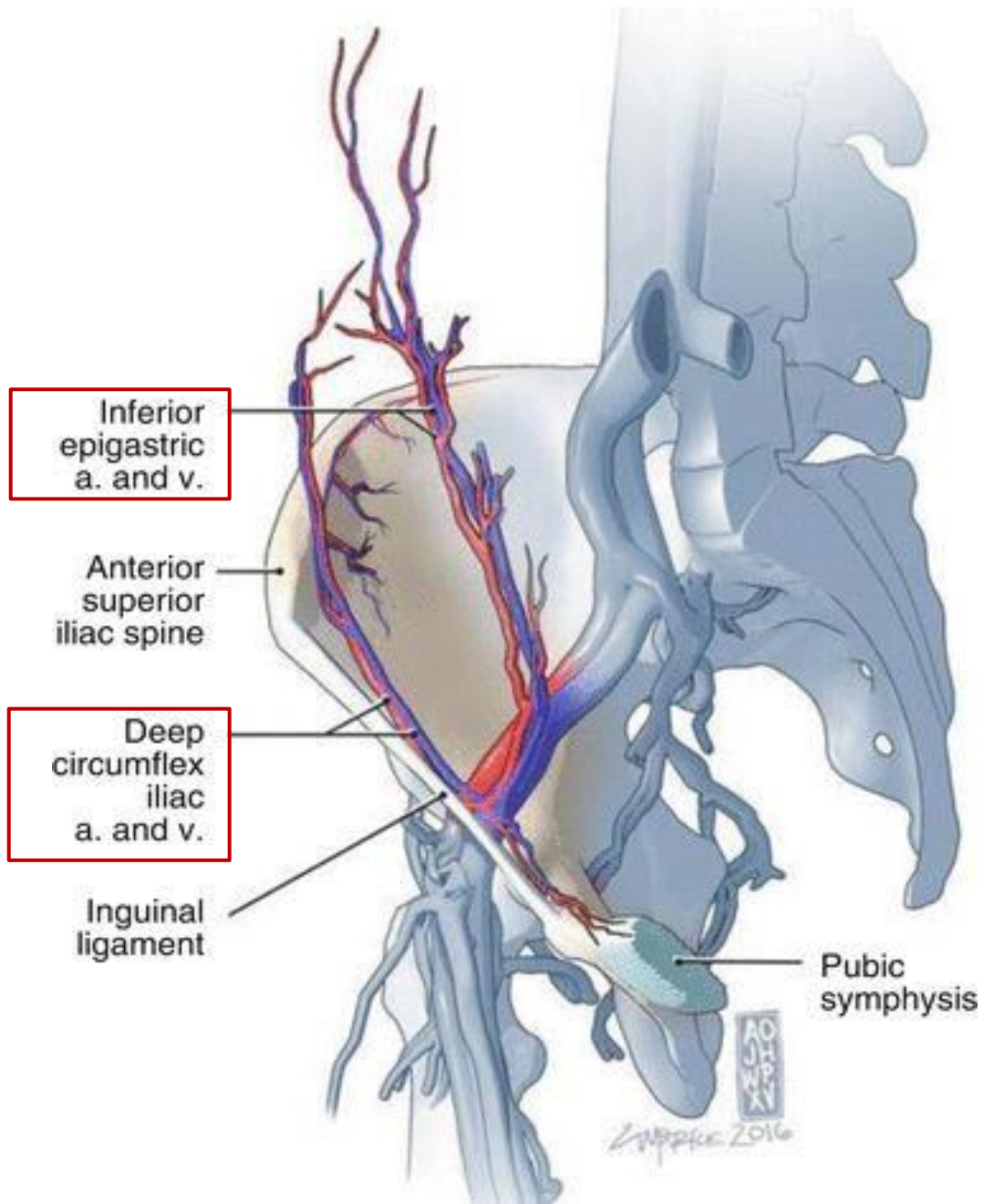
- Arises just above the inguinal ligament. Passes upward and medially along the medial margin of the deep inguinal ring. Then it enters the rectus sheath, deep to the rectus abdominis muscles.
- **Important in distinguishing inguinal hernias:**
 - **Indirect** hernia: **lateral** to the artery.
 - **Direct** hernia: **medial** to the artery.

• Deep Circumflex Iliac Artery

- Arises close to the inferior epigastric artery. It Ascends laterally toward the anterior superior iliac spine (ASIS) and iliac crest.
- Supplies the **muscles of the lower anterior abdominal wall**.



Dr.'s figure:



Medial border of the psoas muscle

14- Internal Iliac Artery

2. Internal Iliac Artery ---> supplies the pelvis

- Located **above** the external iliac artery.
- Supplies the **pelvic viscera**.
- Divides into **two major branches**:
 - **Anterior**
 - **Posterior**

Division	Branch	Course & Supply
Posterior Division	1. Iliolumbar Artery	Ascends upward from the iliolumbar ligament
	2. Lateral Sacral Arteries	Penetrate the sacral foramina; related posteriorly to the rectum and sigmoid colon
	3. Superior Gluteal Artery	Passes through the greater sciatic foramen above the piriformis; supplies the gluteal muscles.

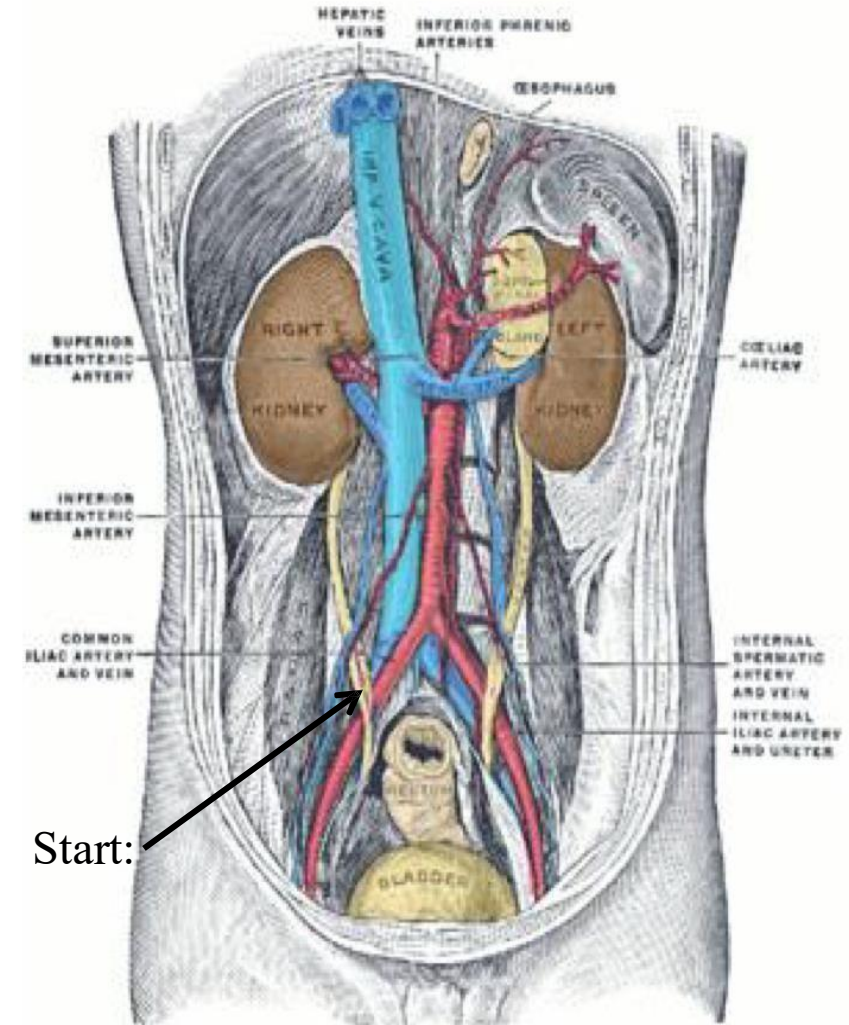
Dr. said ONLY names are required! - will be explained in detail within the UGS

Division	Branch	Course & Supply
Anterior Division	1. Obturator Artery	Passes through obturator foramen with obturator nerve; supplies medial compartment of thigh, crossing obturator canal
	2. Inferior Gluteal Artery	Passes through the greater sciatic foramen below the piriformis; supplies gluteal maximus.
	3. Umbilical Artery	Gives off superior vesical arteries to upper bladder; distal part is obliterated & becomes medial umbilical ligament. Note: Median umbilical ligament = urachus in fetal life
	4. Inferior Vesical Artery	Supplies lower part of the bladder
	5. Uterine artery (♀) & Vaginal Artery (♀)	In ♀: tortuous to accommodate uterine expansion during pregnancy , supplies the uterus & vagina
	6. Deferential artery (♂)	In ♂: goes to the vas deferens
	7. Middle Rectal Artery	Terminal branch in the pelvis; supplies the rectum
	8. Internal Pudendal Artery	Terminal branch ; gives the inferior rectal artery; supplies the rectum

Dr. said **ONLY** names are required!

15- Inferior Vena Cava

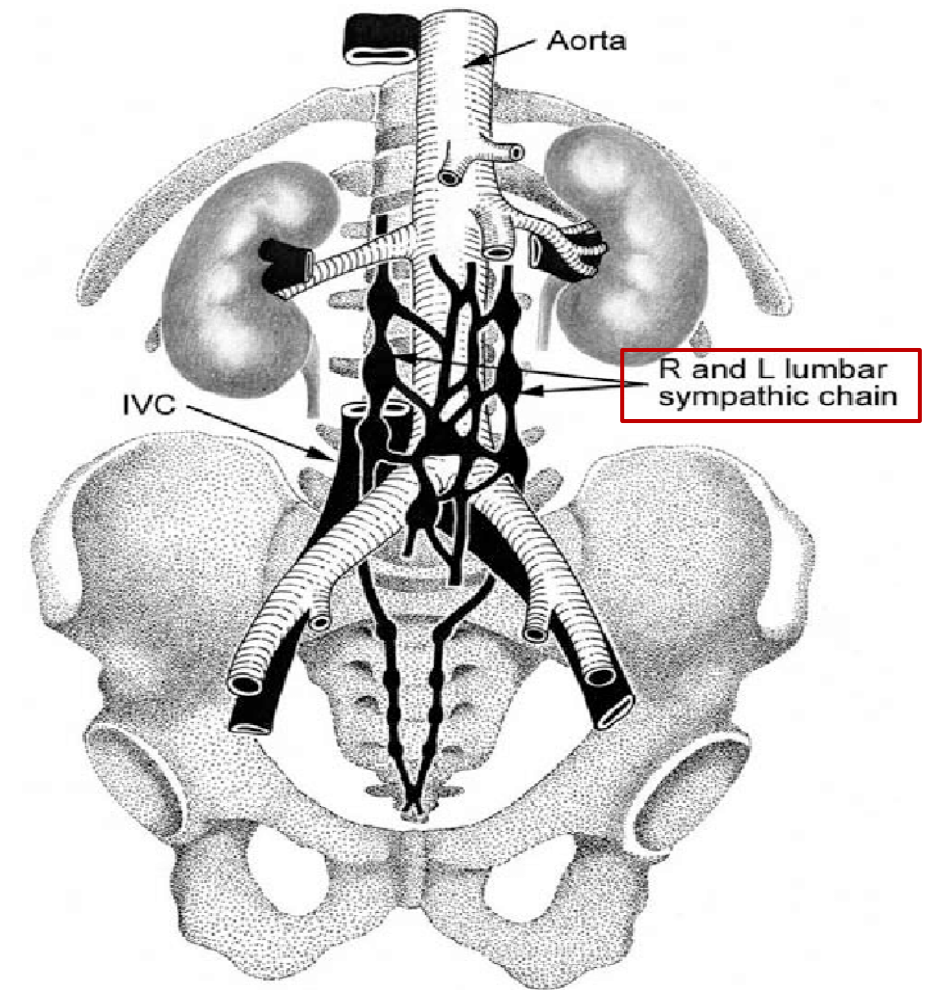
- The inferior vena cava is formed by the **union of the right and left common iliac veins** at the level of the fifth lumbar vertebra (**L5**) on the **right** side of the vertebral column.
- It ascends upward on the right side, piercing the **central tendon of the diaphragm** at the level of the 8th thoracic vertebra (**T8**).
- Ends: in the **right atrium of the heart**.
- In the **pelvis**, the **common iliac vein lies deep to the common iliac artery**. This anatomical arrangement exists because **veins have thinner walls** and are more vulnerable to external pressure, especially from the enlarging uterus during pregnancy. In contrast, **arteries have thicker muscular walls** that can better withstand such pressure. However, despite this 😊 **protective positioning**, 😞 **pelvic varicocele** may still occur in pregnant women.



Dr.'s figure:

16 - Inferior Vena Cava Relations

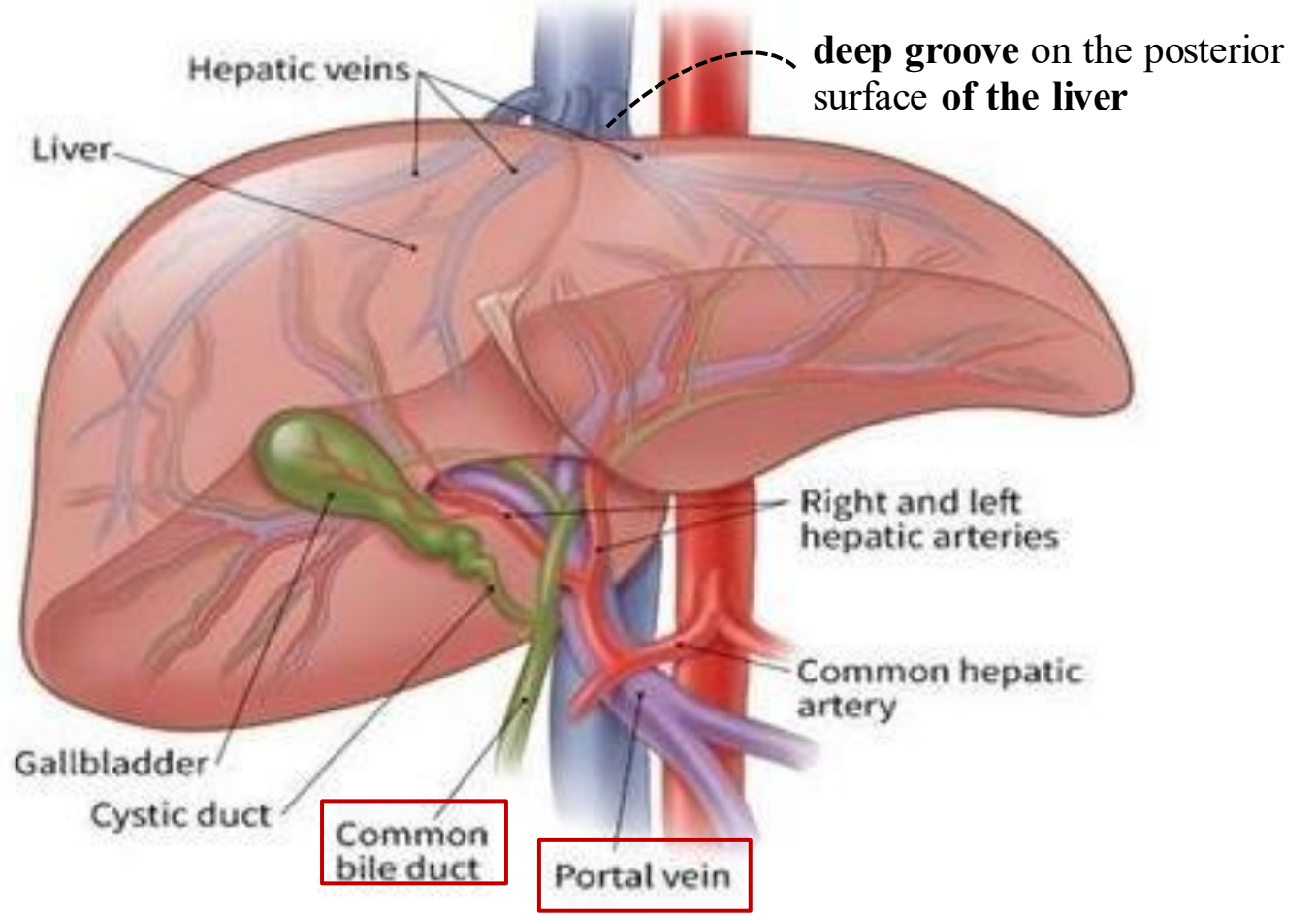
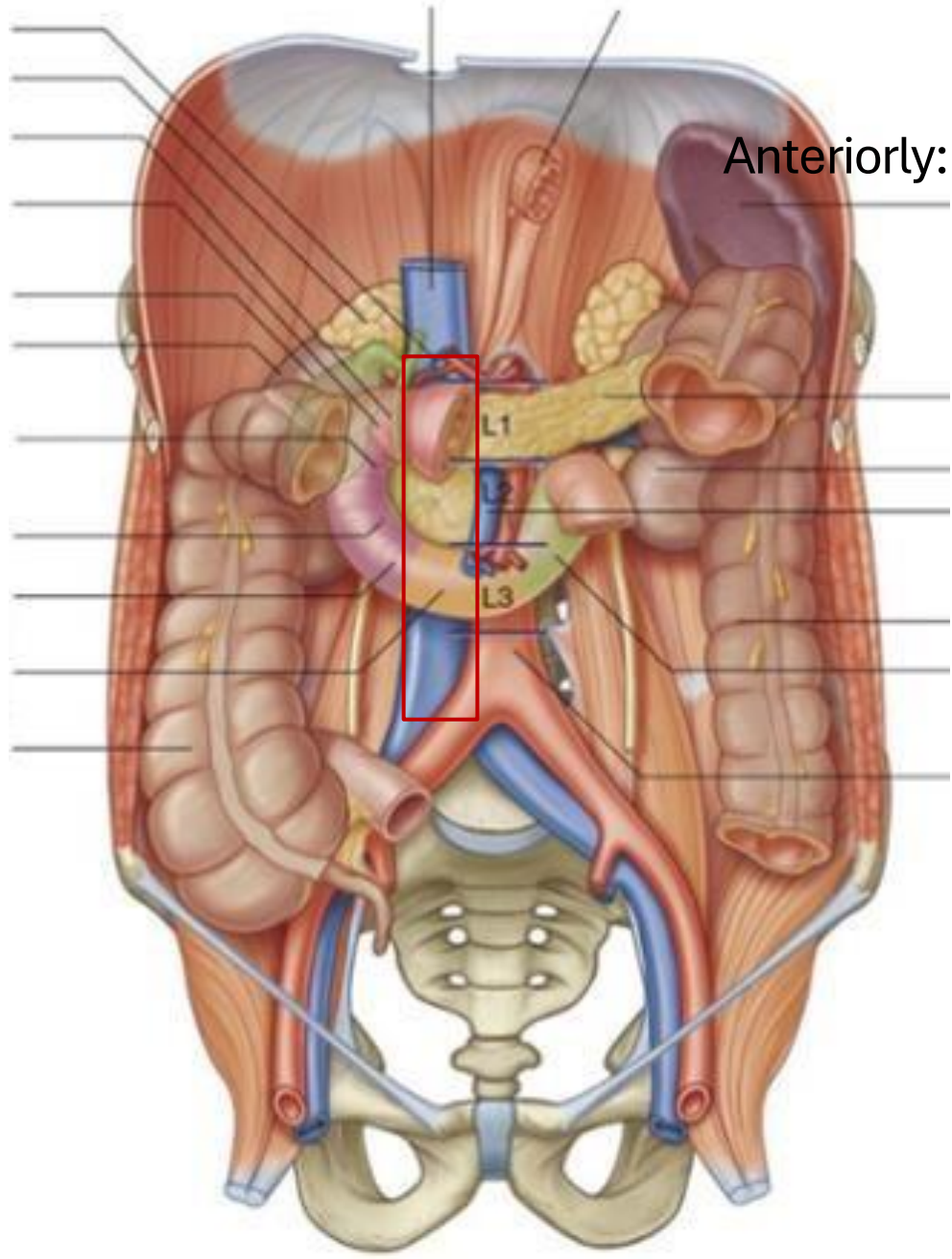
Aspect	Structures Related to IVC
Anterior	<ul style="list-style-type: none"> • Coils of small intestine • 3rd and 1st parts of duodenum • Head of pancreas • Common bile duct • Portal vein • Related to Foramen of Winslow • Lies in a deep groove on the posterior surface of the liver
Posterior	<ul style="list-style-type: none"> • Right sympathetic chain (runs behind the IVC, on the right side)*



*Thus, The **abdominal sympathetic chain** lies **behind the inferior vena cava** on the **right side**, while it is lies adjacent to the **the abdominal aorta on the left side**.

3
2

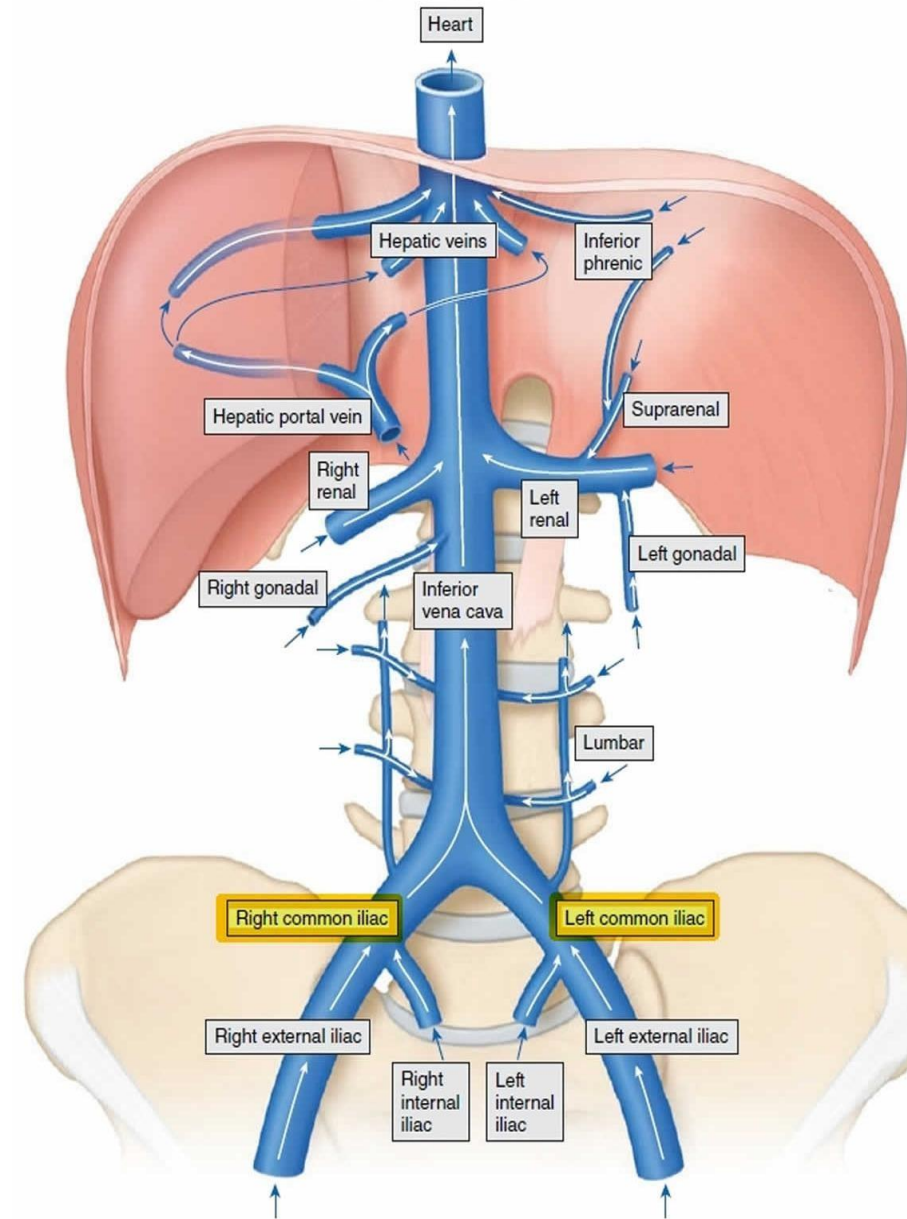
Anteriorly:



17- Inferior Vena Cava Tributaries

1. Anterior Visceral Tributaries

- The anterior visceral tributaries of the inferior vena cava (IVC) are the **hepatic veins**.
- Typically, there are **two main hepatic veins**:
 - **Right hepatic vein** draining the **right lobe of the liver**.
 - **Left hepatic vein** draining the **left lobe of the liver**.
 - However, a third vein the **middle hepatic vein** is often present as well. It usually drains blood from the **central regions of the liver, including the caudate and quadrate lobes**.
- They drain **directly into the IVC**.



17- Inferior Vena Cava Tributaries

2. Lateral Visceral Tributaries

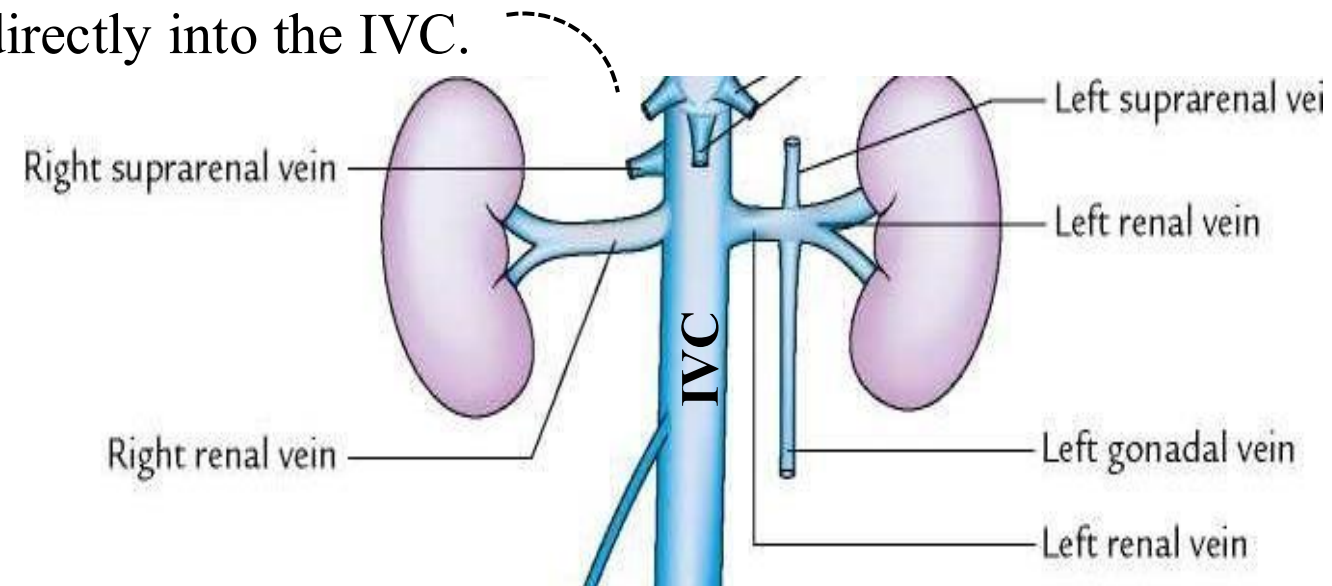
- The **right suprarenal** and **right testicular/ovarian veins** drain **directly into the IVC**.
- However, **left suprarenal** and **left testicular/ovarian veins** first drain into the **left renal vein**, which then drains into the IVC. This anatomical arrangement explains why ☹️ **varicocele** is **more common on the left** and why the left testis hangs lower than the right.
- Both **renal veins (right and left)** drain directly into the IVC.

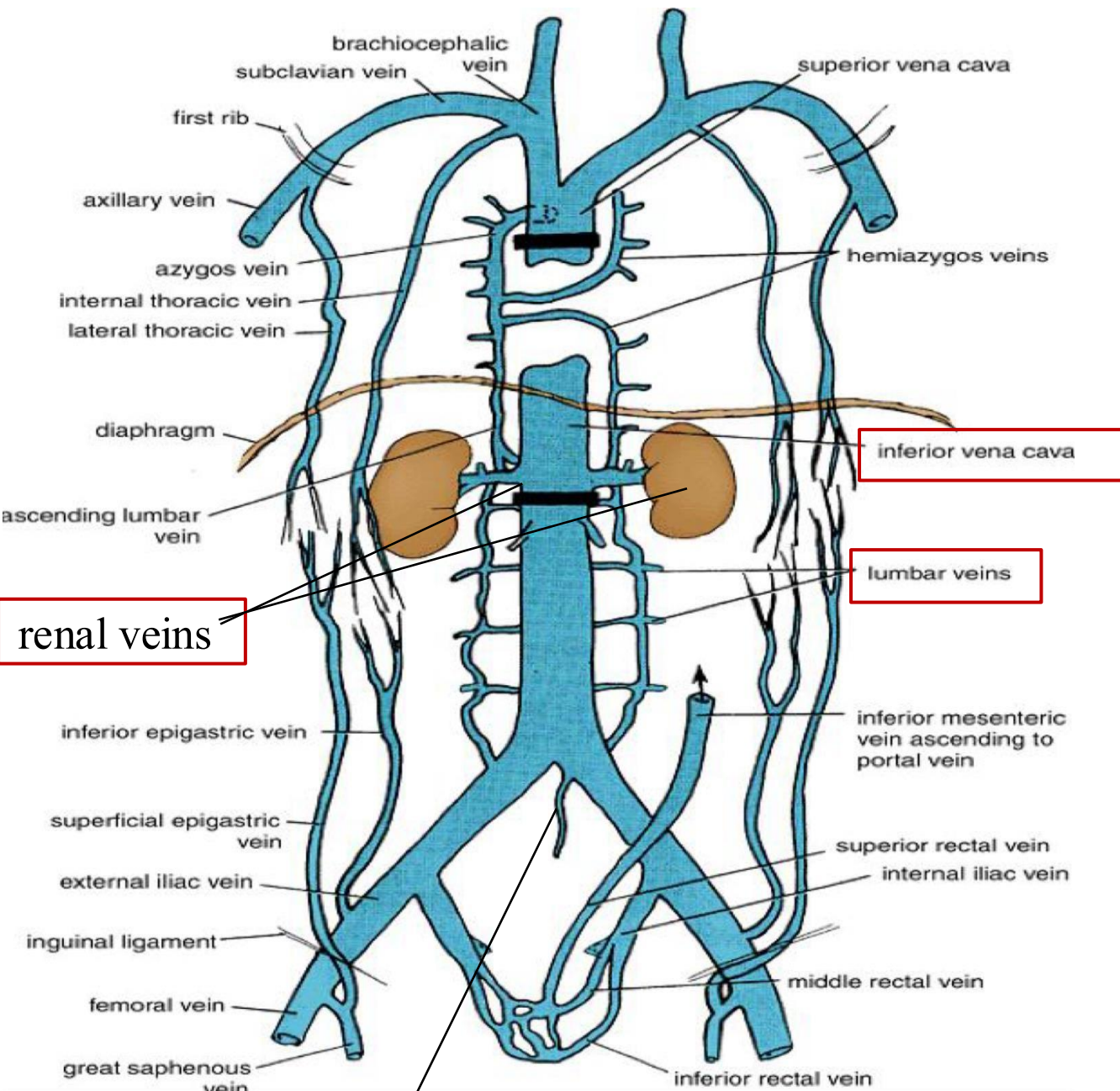
3. Lateral Abdominal Wall Tributaries

- **Inferior Phrenic Veins**
- **Four Lumbar Veins**

4. Veins of Origin of IVC

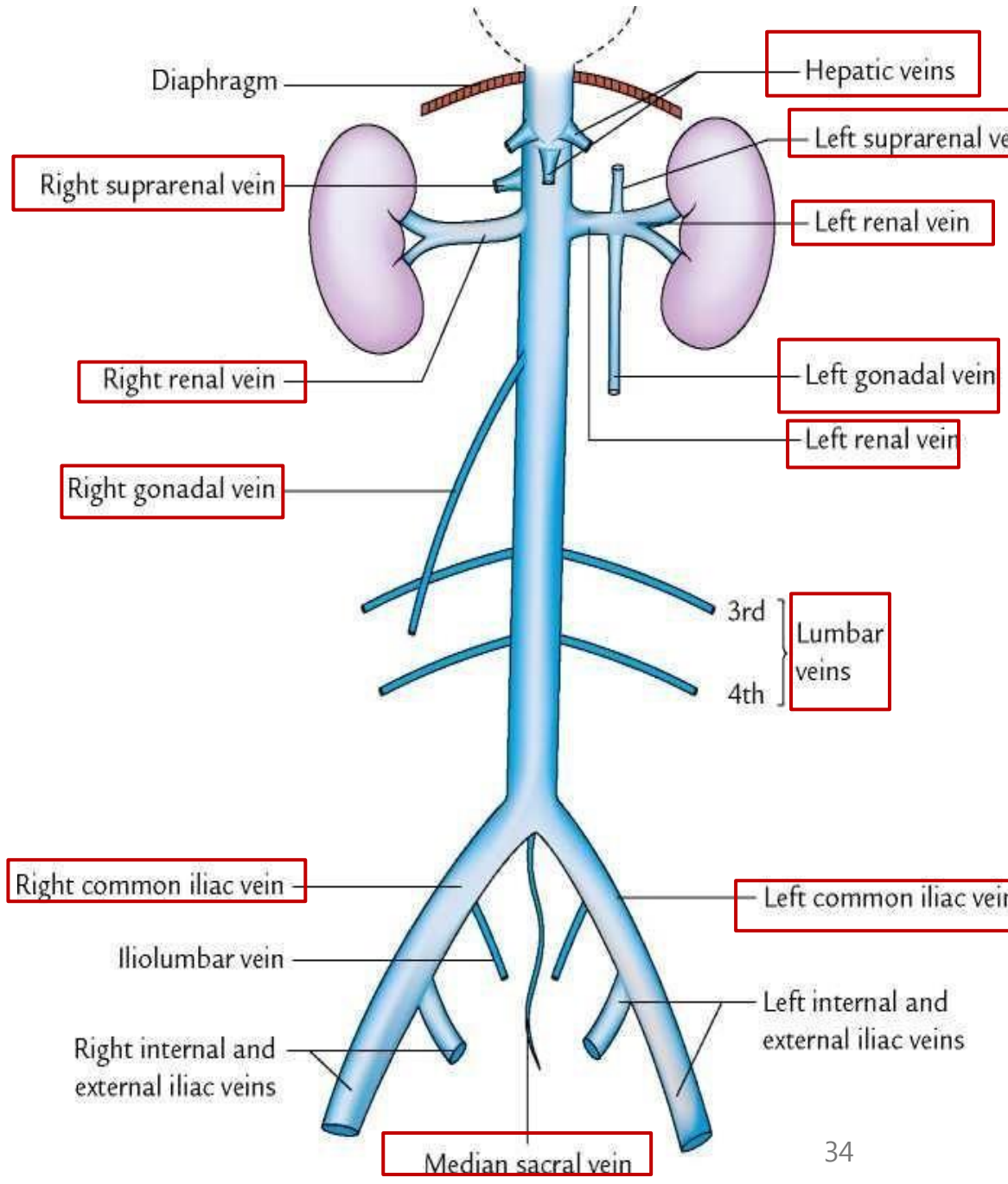
- **Two Common Iliac Veins**
- **One Median Sacral Vein**





renal veins

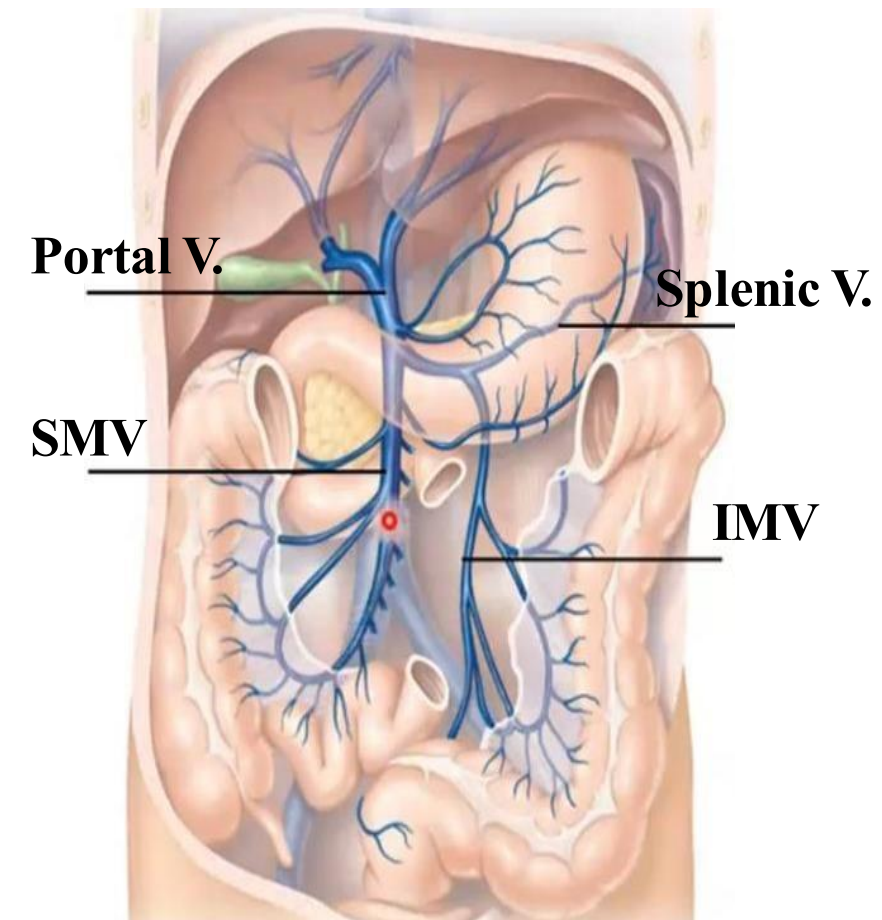
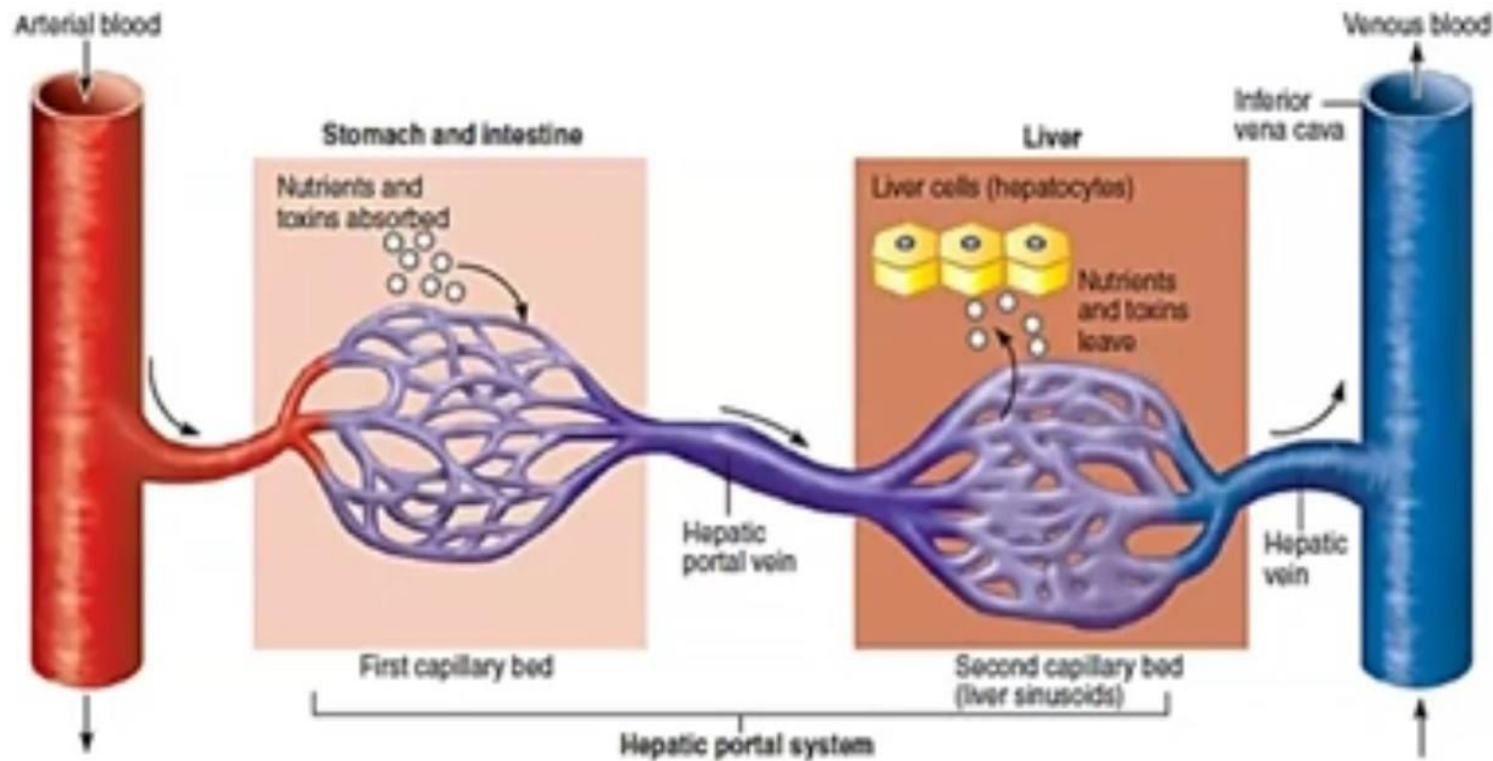
Median sacral V. Dr.'s figure:



Median sacral vein

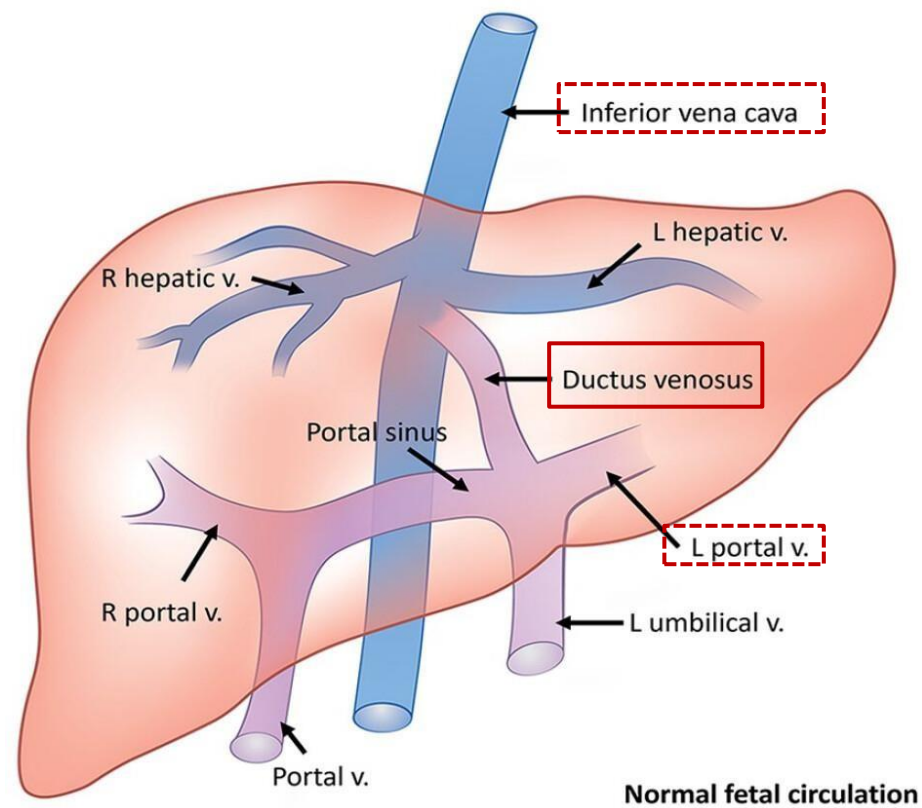
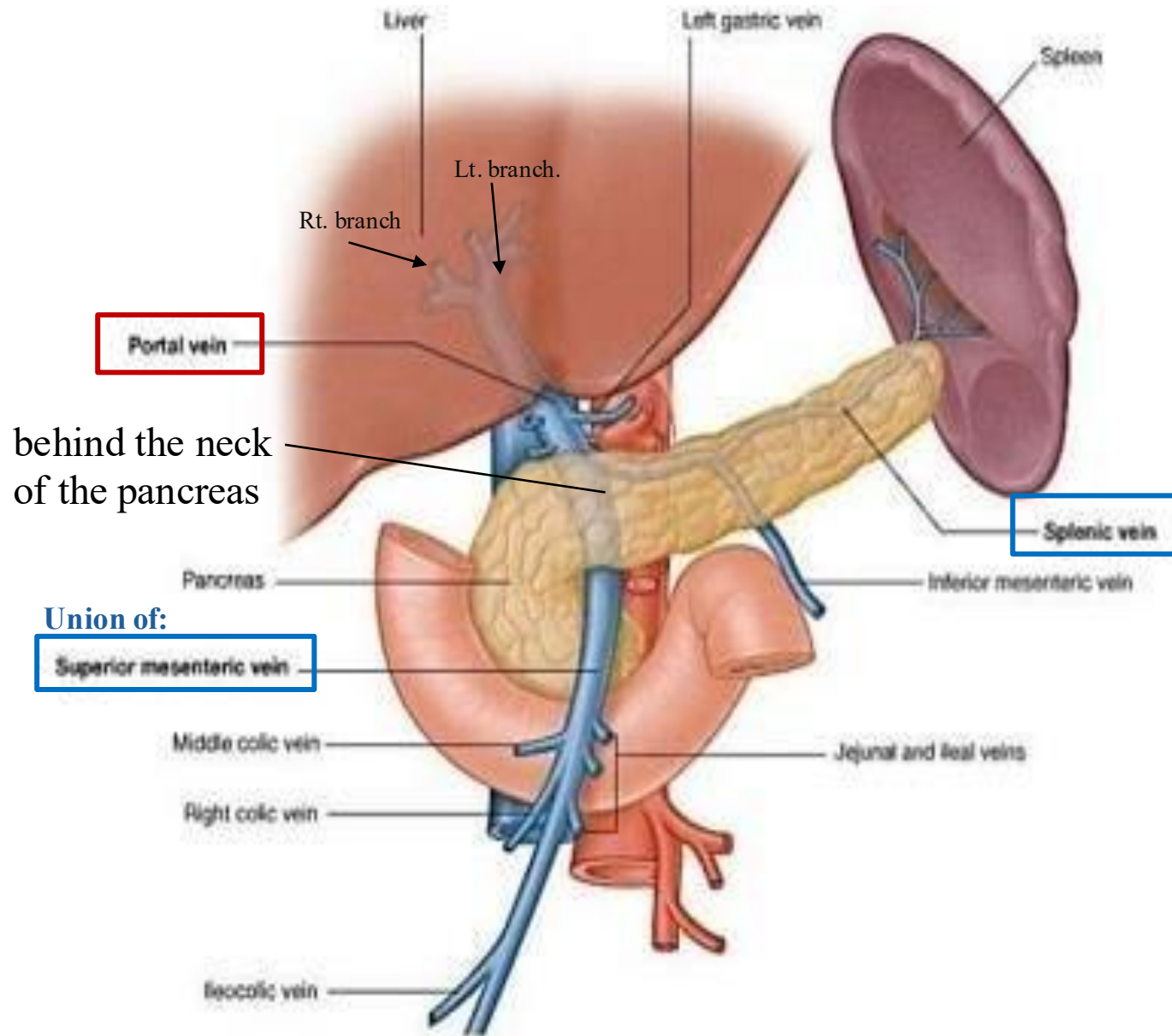
18 - Portal venous system - Overview

The portal venous system collects blood from the **abdominal gastrointestinal tract** and delivers it to the **liver** via the **portal vein**. Within the liver, blood passes through **hepatic sinusoids** for processing. It then drains into the **hepatic veins**, which empty into the **inferior vena cava (IVC)**.

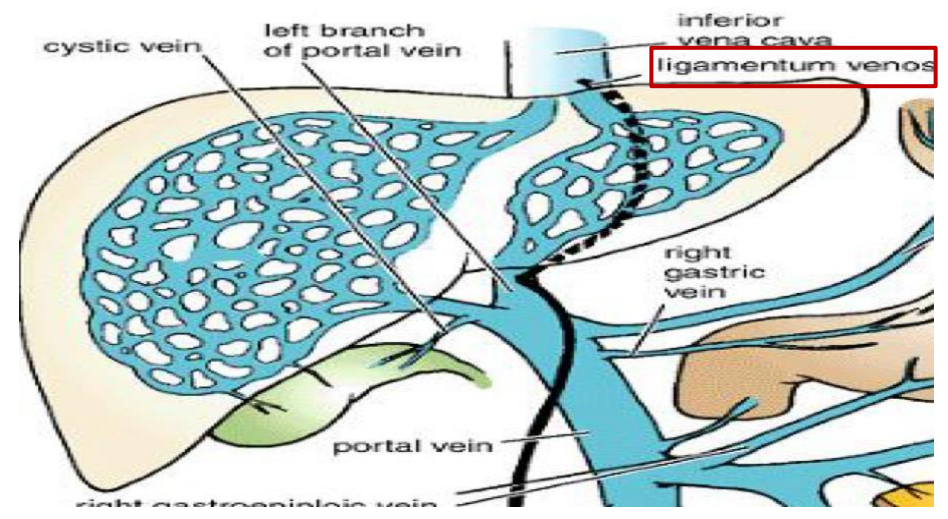


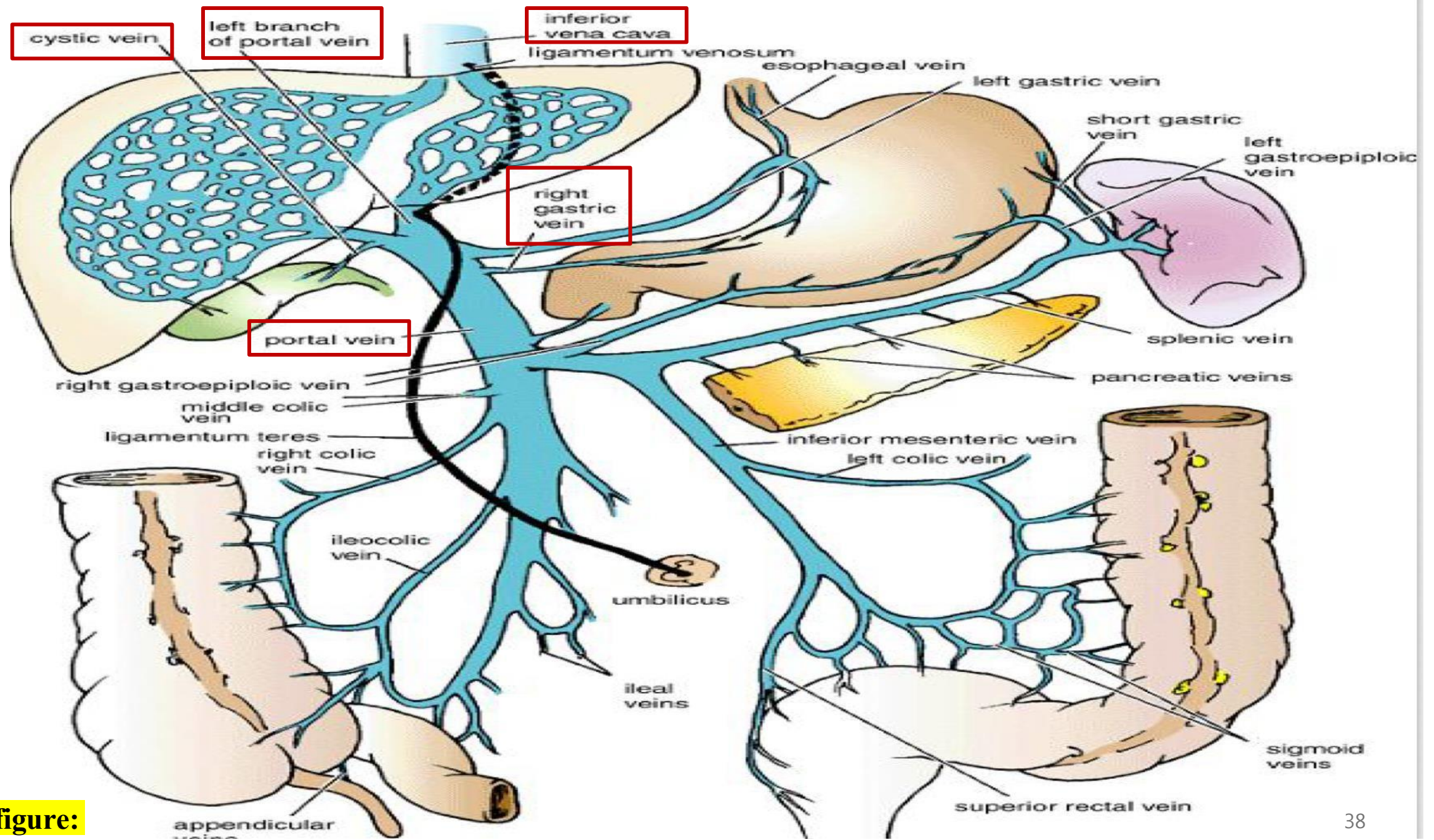
19- Portal Vein

- The portal vein is approximately **2 inches** (5 cm) in length.
 - **Origin:** Formed behind the **neck** of the **pancreas** by the union of the **splenic vein** and **superior mesenteric vein**
 - **Termination:** Divides into **right and left branches** at the **porta hepatis within the liver.**
 - The portal vein drains blood from the **lower third of the esophagus** to **halfway down the anal canal**, as well as from the **spleen, pancreas, and gallbladder.**
- **Relate to embryology:**
- **Ductus venosus** is a ductal canal that connects left portal vein to IVC in fetus; it then undergoes obliteration & becomes **ligamentum venosum** after birth
 - The **umbilical vein** Carries oxygenated blood from placenta to fetus; it also undergoes obliteration & becomes **ligamentum teres** (round ligament of liver) after birth



Normal fetal circulation





Dr.'s figure:

20- Portal Vein Tributaries

1. **Left gastric vein**

2. **Right gastric vein**

3. **Superior pancreaticoduodenal**

4. **Superior mesenteric vein**

- Joins **splenic vein** behind the neck of the pancreas to form portal vein.
- Drains **midgut**

5. **Inferior mesenteric vein**

- Joins the **splenic vein**, which eventually drains into the portal vein.
- Drains **hindgut**

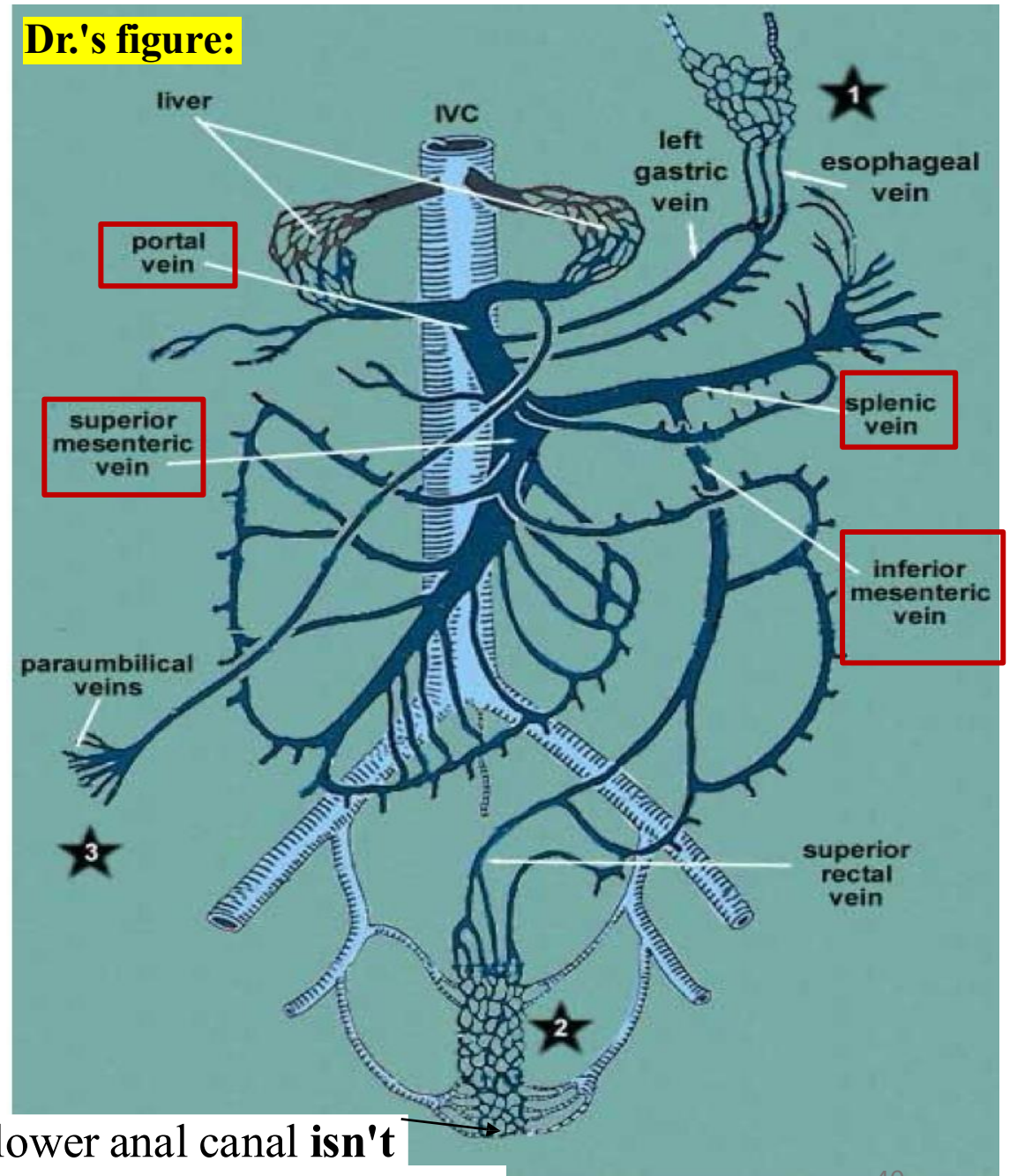
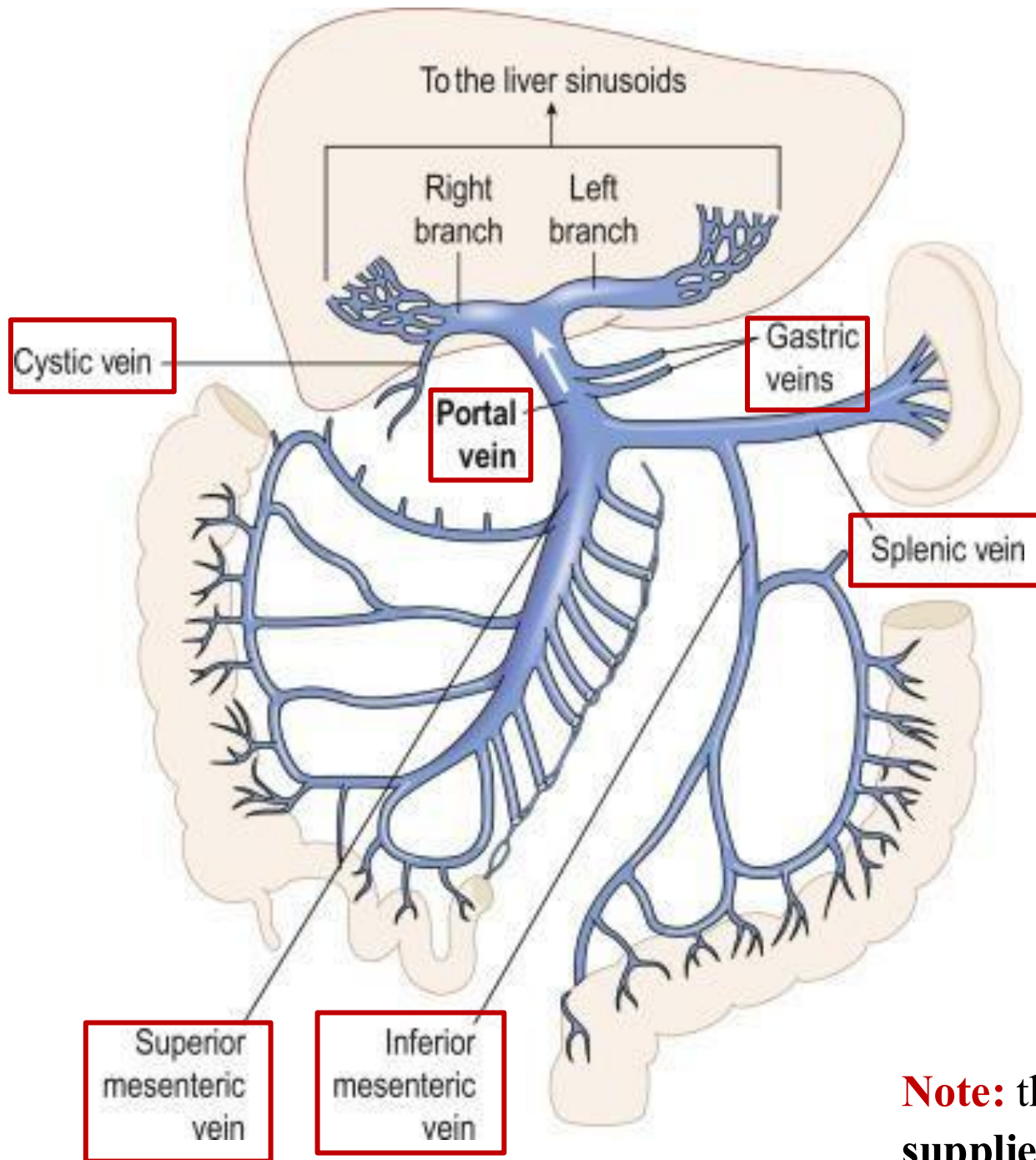
6. **Splenic vein**

7. **The cystic vein**

- which drains into the **right portal vein** or directly to liver.



Branches of celiac trunk, Drains **foregut**



Note: the lower anal canal **isn't** supplied by the portal venous system

21- Portosystemic Anastomosis

➤ Relate to Pathology

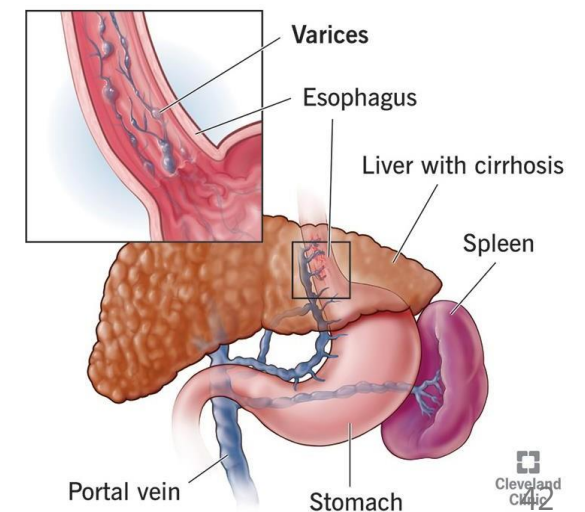
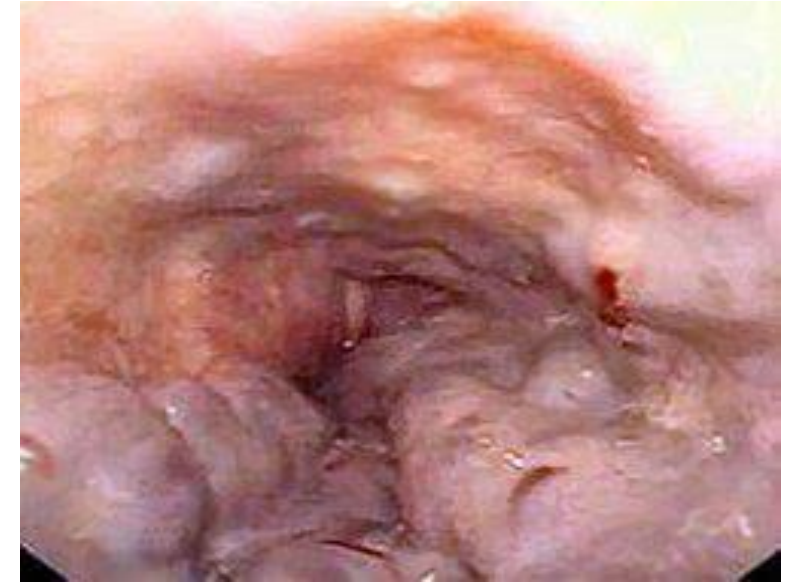- In conditions such as liver cirrhosis, fibrosis, or obstruction of the portal vein, the normal flow of blood through the liver becomes **restricted**. This leads to a buildup of pressure within the portal venous system, a condition known as 😞 **portal hypertension**.
- The primary **causes** of portal hypertension include:
 - chronic liver diseases like **cirrhosis and fibrosis**,
 - **valvular heart disease** that affects venous return,
 - congenital abnormalities such as a ***patent ductus venosus**.
- As the pressure within the portal system increases, blood is forced to find alternate pathways to return to the heart. This is achieved through **portosystemic anastomoses**, where **blood is diverted from the portal circulation into the systemic venous system**.

**Ductus venosus fails to close after birth, leading to a persistent abnormal communication between the portal vein and inferior vena cava (IVC).*

21- Portosystemic Anastomosis

➤ Relate to Pathology

- One of the most clinically significant sites of portosystemic anastomosis is the **lower end of the esophagus**, where 😞 **esophageal varices** can form due to portal hypertension. These dilated veins are prone to **rupture and massive bleeding**, making this a serious and life-threatening complication.
- In the past, such bleeding often led to death due to a lack of effective treatment. However, modern medicine has improved outcomes significantly. Using 😊 **gastroscopy**, doctors can now directly visualize and treat varices by injecting **sclerosing agents**, applying **vasoconstrictive drugs**, to help control bleeding and promote healing.



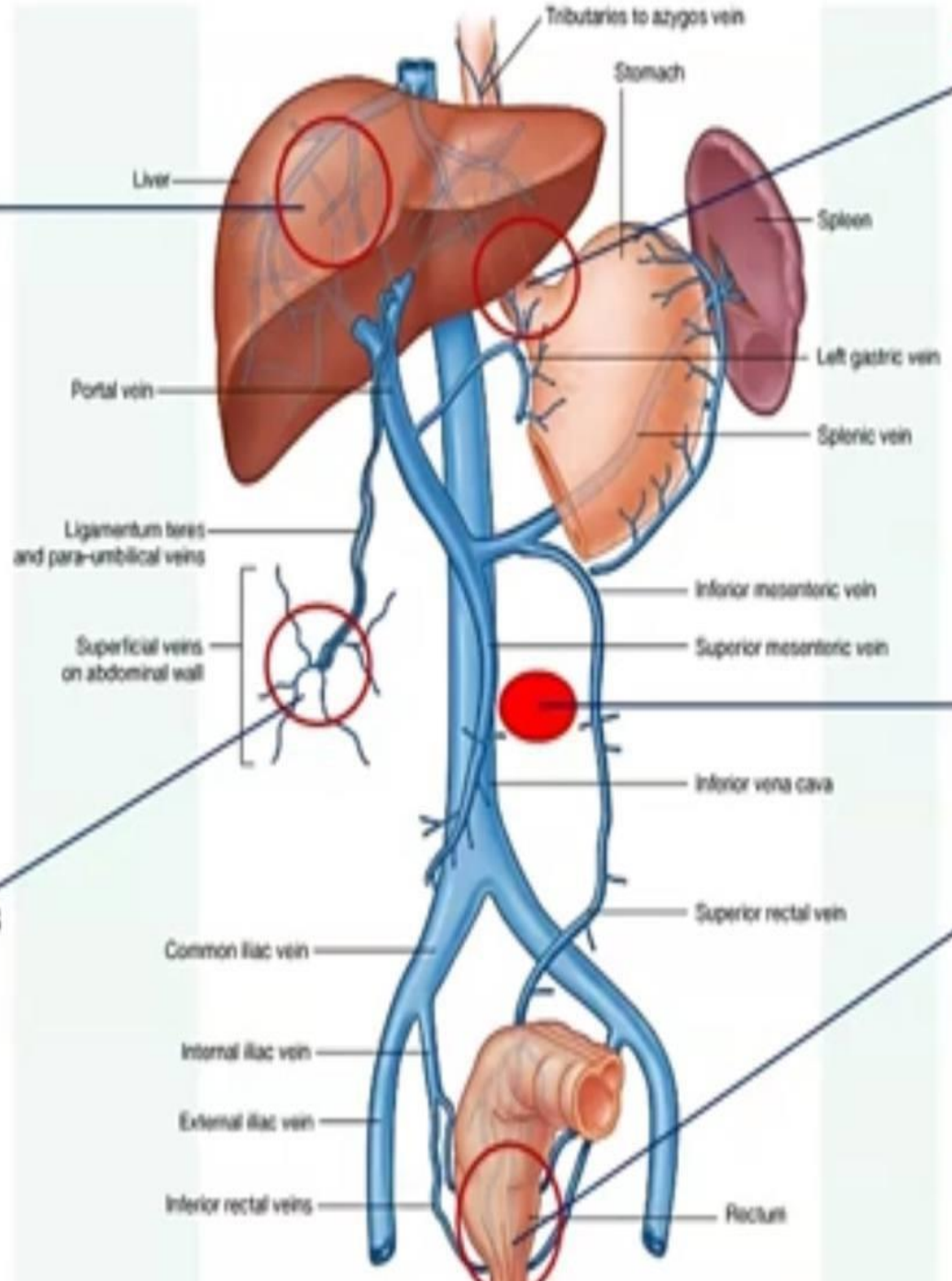
22- Portosystemic Anastomosis Sites

- ✓ These sites are crucial because they can become dilated and engorged, which may lead to **Hematemesis** (vomiting of blood)

Region	Clinical Condition	Portal Circulation	Systemic Circulation
Esophageal	Esophageal varices	Esophageal branch of the left gastric vein	Esophageal branches of the azygos vein
Rectal	Internal Hemorrhoids	Superior rectal vein	Middle and inferior rectal veins
Paraumbilical	Caput medusae (as ☆)	Paraumbilical veins	Superficial epigastric veins
Retroperitoneal	(No specific clinical name)	Right, middle, and left colic veins	Renal, suprarenal, paravertebral, and gonadal veins
Intrahepatic	Patent ductus venosus	Left branch of the portal vein	Inferior vena cava

4) Bare area of the liver and inside the liver

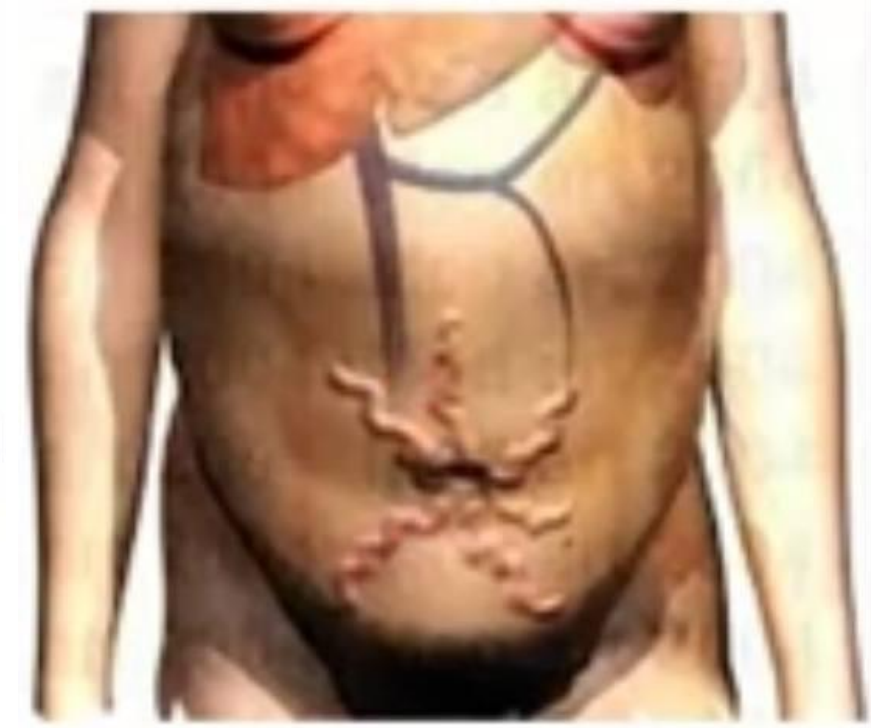1) Abdominal esophagus



3) Umbilicus

5) Posterior abdominal wall

2) Rectum



Caput medusae

23- Lymphatics on posterior abdominal wall

The lymph nodes are closely related to the aorta and form a **preaortic** and a right and left **lateral aortic (Para-aortic or lumbar) chain**.

1. **The preaortic lymph nodes: (Infront of the aorta)**

- Lie around the origins of the celiac, superior mesenteric, and inferior mesenteric arteries and are referred to as the celiac, superior mesenteric, and inferior mesenteric lymph nodes, respectively.
- They drain the lymph from the gastrointestinal tube, extending from the **lower one third of the esophagus to halfway down the upper half of anal canal, and from the spleen, pancreas, gallbladder, and *greater part of the liver.**

*The greater part of the liver drains preaortic. while a smaller part, especially from the upper surface, drains through right thoracic duct.

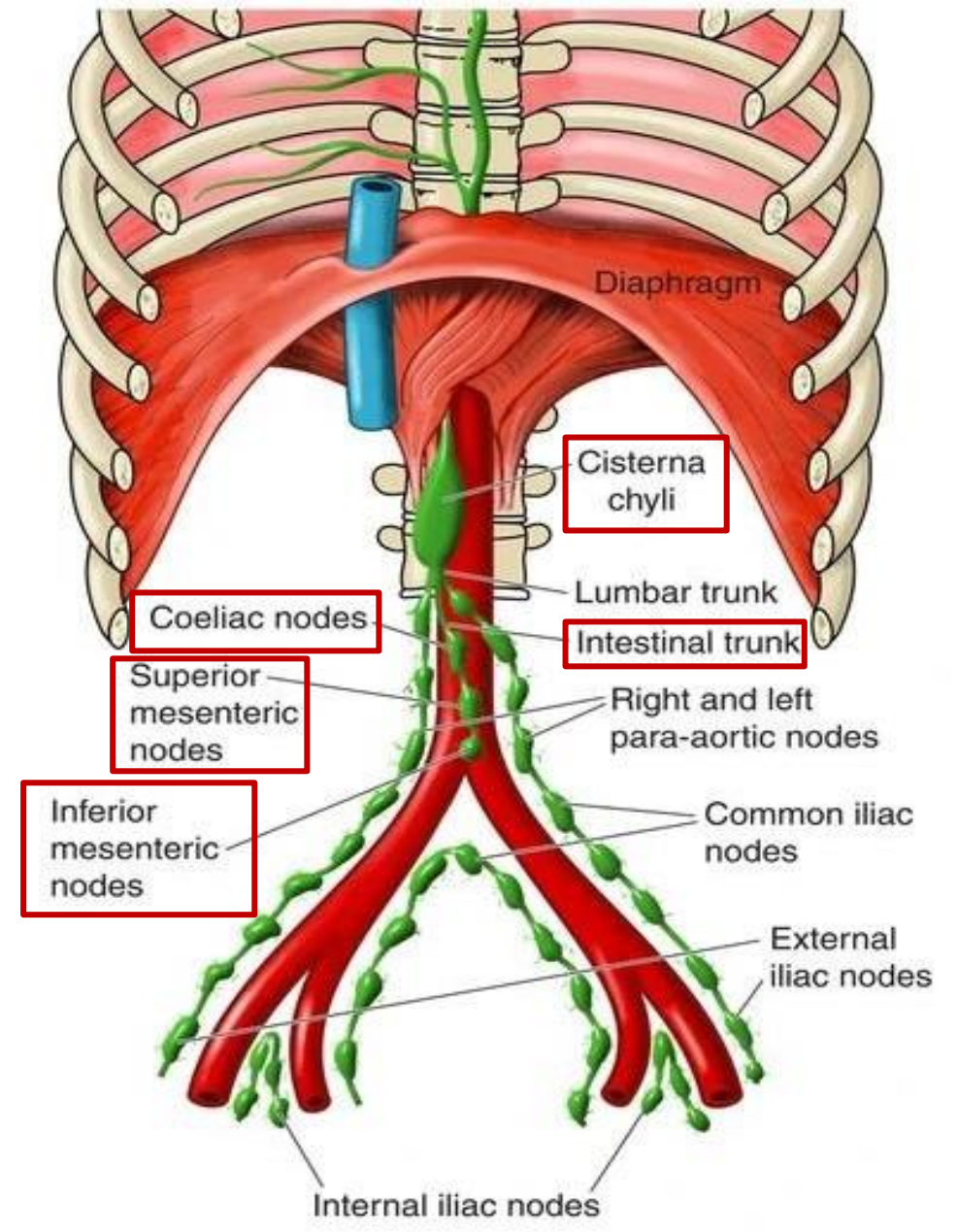
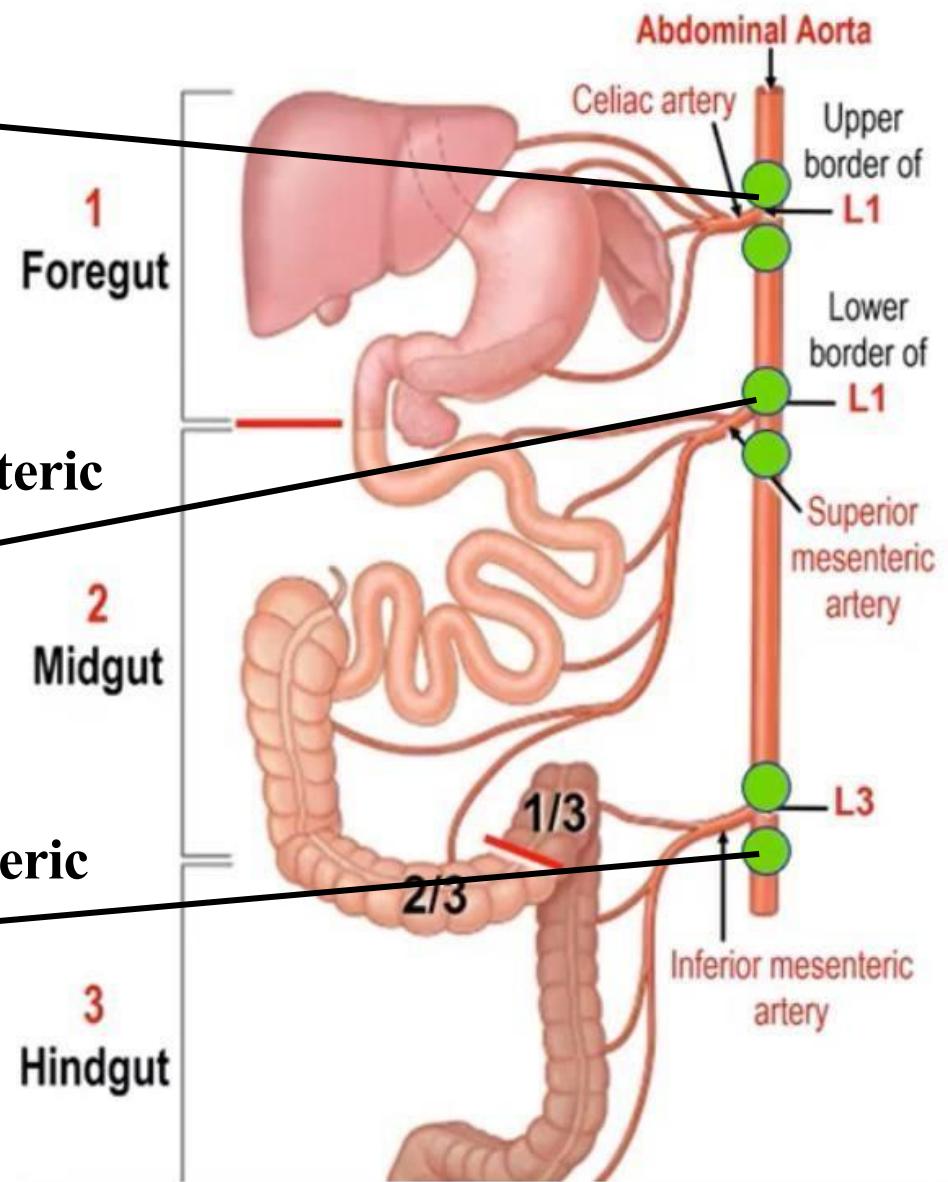
- The efferent lymph vessels from the celiac, superior mesenteric, and inferior mesenteric lymph nodes form **intestinal lymphatic trunks**. These trunks converge and ultimately drain into the **cisterna chyli**.

Rule: lymphatics run along the arteries, thus;

Celiac lymph nodes

superior mesenteric lymph nodes

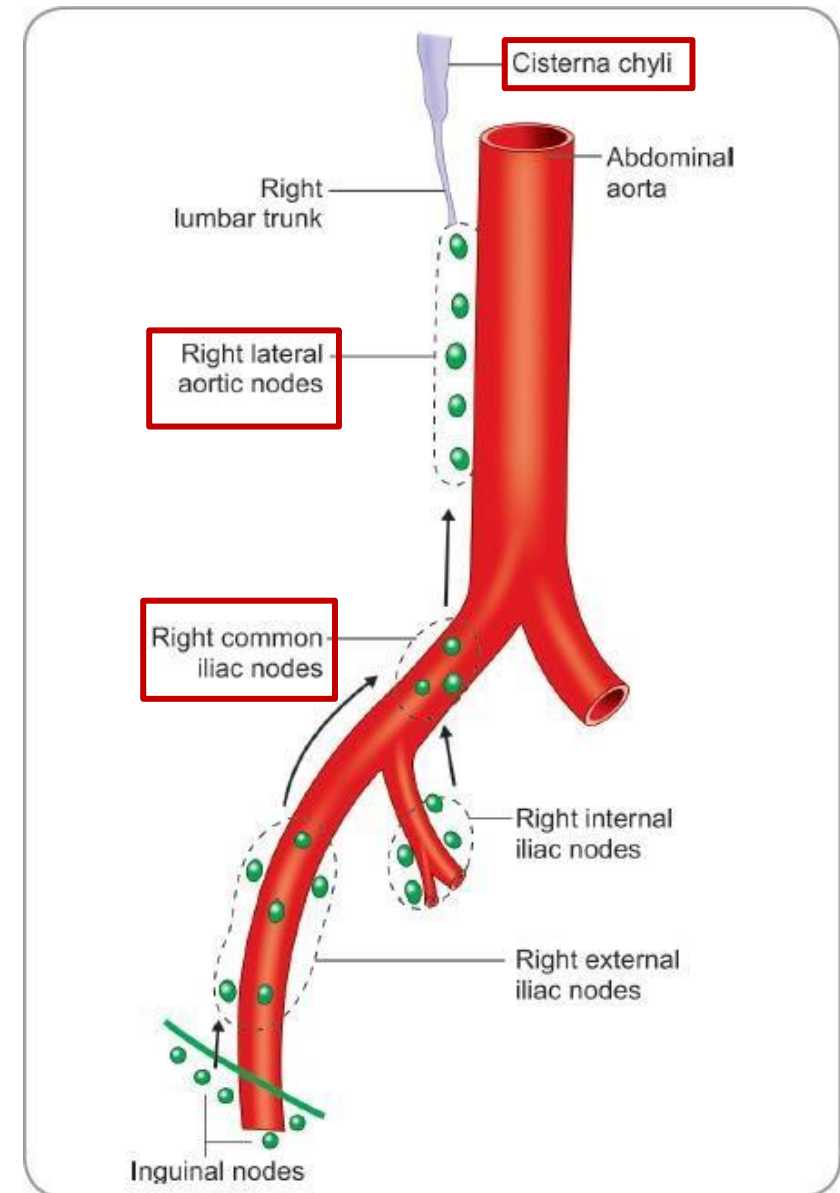
inferior mesenteric lymph nodes

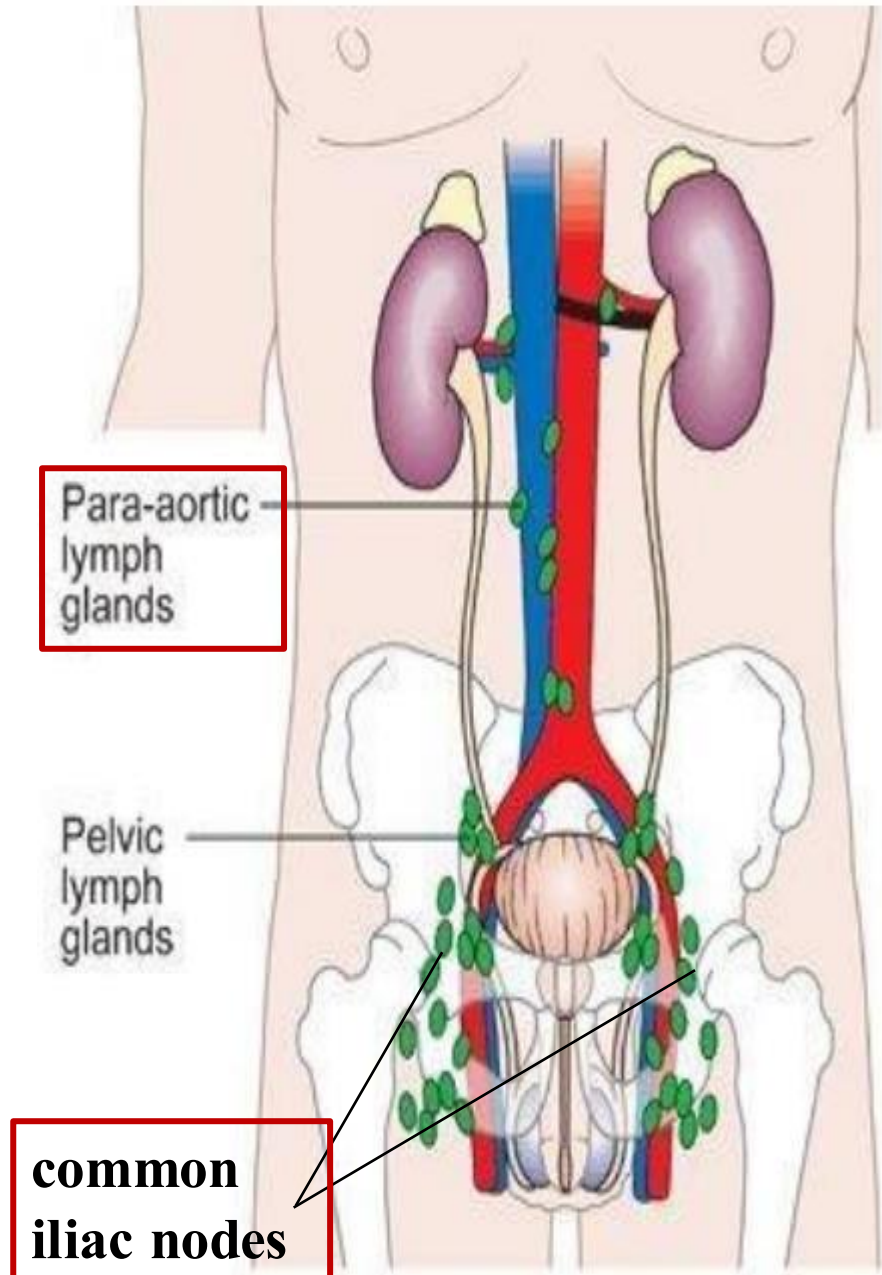


23- Lymphatics on posterior abdominal wall

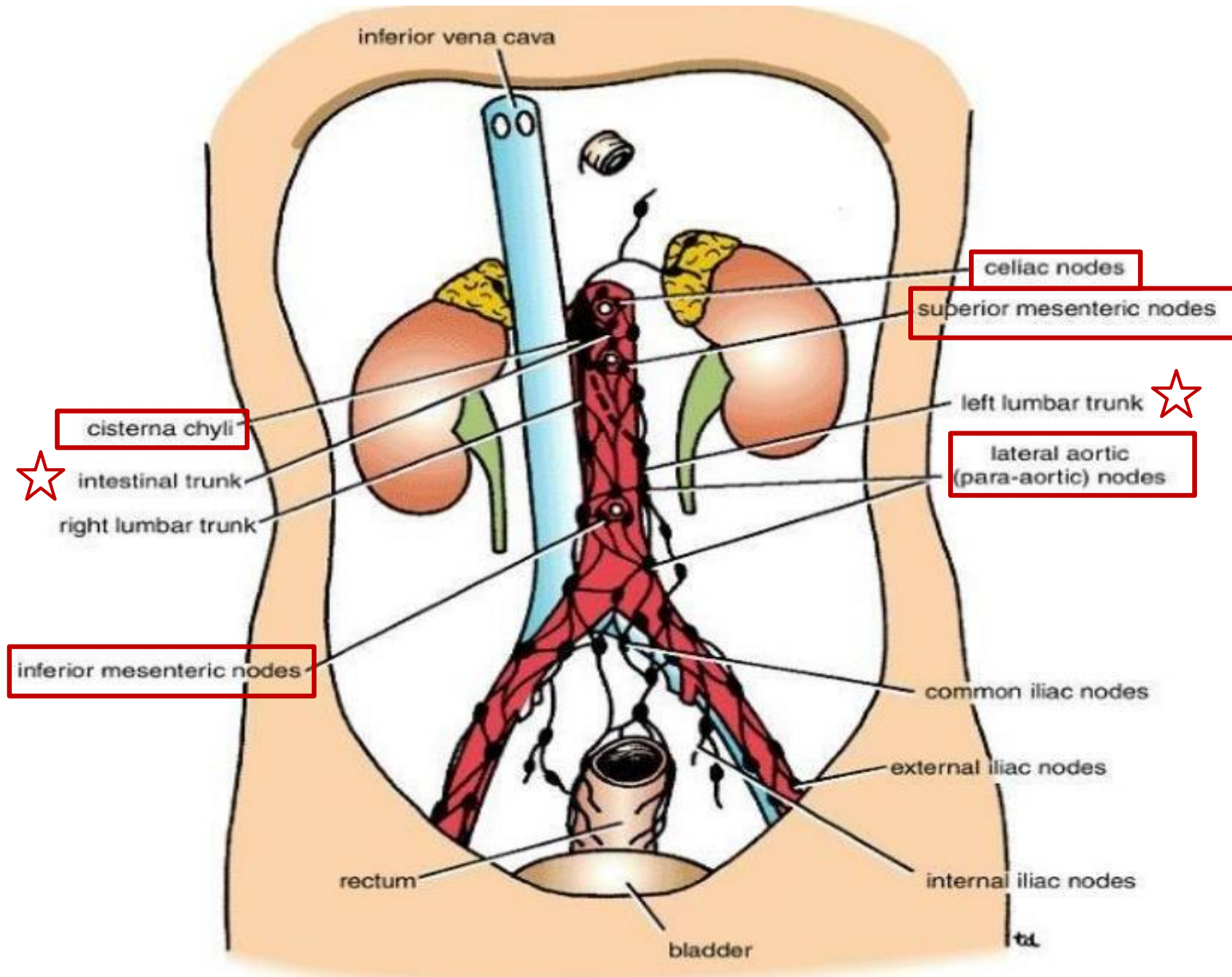
2. The lateral aortic (para-aortic or lumbar) lymph nodes:

- **Located on the two sides of aorta, at the lumbar region**
 - Drain lymph from the **kidneys and suprarenals**; from the **testes in the male and from the ovaries, uterine tubes, and fundus of the uterus in the female**; from the deep lymph vessels of the abdominal walls; and from the ***common iliac nodes**.
 - ***receives lymph from pelvic viscera and lower limbs.**
 - The efferent lymph vessels form the **right and left lumbar trunk**, into the **cisterna chyli**.
- ✓ Recall: Lymphatics are clinically important because they play a key role in the spread 😞 (**metastasis**) of cancer.





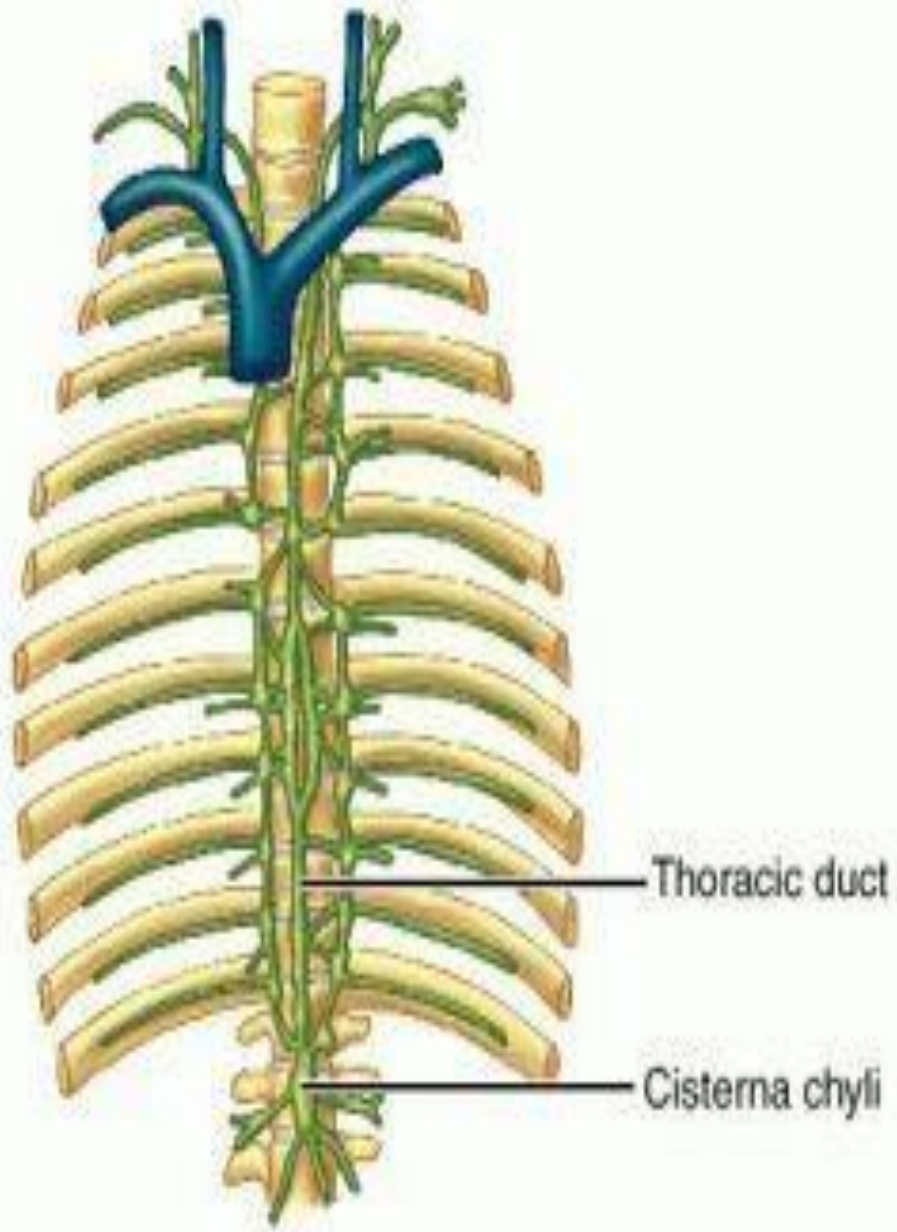
Dr.'s figure:



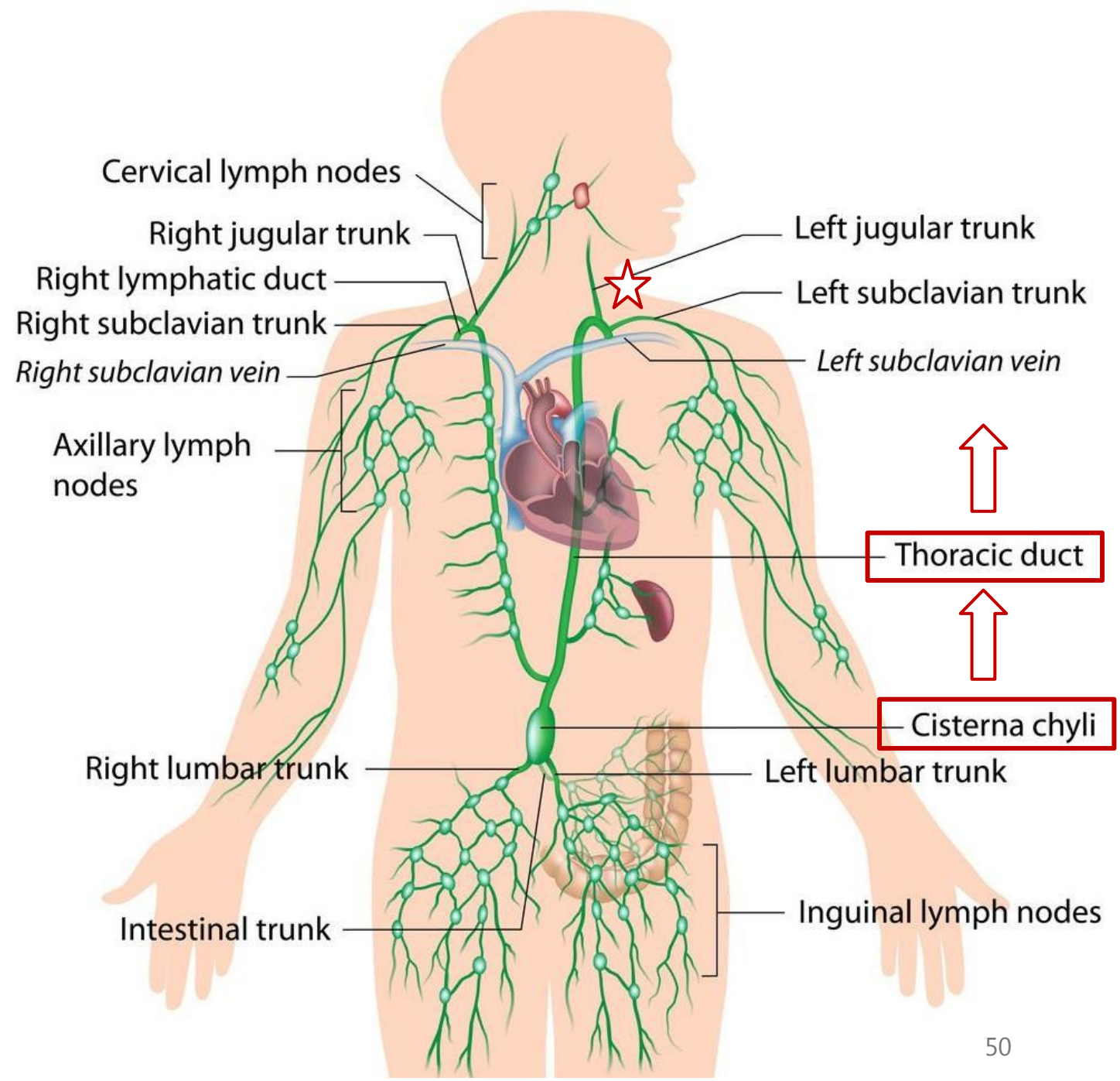
Dr.'s figure:

24- The cisterna chyli

- The **thoracic duct** begins in the abdomen at the **aortic orifice** of the diaphragm as an elongated lymphatic sac called the **cisterna chyli**.
- **Cisterna chyli** is situated just **below the diaphragm, anterior to the first and second lumbar vertebrae (L1–L2)**, and on the **right side of the abdominal aorta**. Even further to the right, the **azygos vein** originates.
- **The cisterna chyli receives lymph from:**
 - The intestinal trunk
 - The right and left vessels from lower thorax
 - Small lymphatic vessels that descend from the lower thorax.
- From the cisterna chyli, the **thoracic duct ascends through the thorax**, passing through the posterior mediastinum. At the **root of the neck**, it **crosses to the left side** and terminates at the point where the **left internal jugular vein** joins the **left subclavian vein** forming the **left brachiocephalic vein**. This is where the lymph collected from most of the body is returned to the venous circulation. - *next slide*



Dr.'s figure:



رسالة من الفريق العلمي:

تدبر الآية :

كلما تأملت في جمال الطبيعة فبعثت في قلبك الفرح والبهجة فتذكر أنها إبداع مولاك الخلاق جلّ جلاله، واشكره ملء نفسك التي استمتعت بذلك الجمال الأنيق.

إذا نظر المؤمن إلى أسباب وجود الأشياء في هذه الحياة فإنها لا تصرفه عن مسببها جل وعلا، فالشجر ينبت بالماء، والله خلق السبب والمسبب كليهما، وجعل للسبب تأثيرًا بمشيئته وحده.

الله هو الخالق لأصول النعم وفروعها، فكيف تحسن عبادة ما لا منفعة منه البتة على الحقيقة؟ ثمّة أقوام لا يقلعون عن شركهم، ولا يرعون عن تسويتهم خالق العالمين بما سواه من المخلوقين، وإن تتالت عليهم الدلائل والبراهين.

سُورَةُ النَّبَاتِ

بِسْمِ اللَّهِ الرَّحْمَنِ الرَّحِيمِ

أَمَّنْ خَلَقَ السَّمَوَاتِ وَالْأَرْضَ وَأَنْزَلَ لَكُمْ مِنَ
السَّمَاءِ مَاءً فَأَنْبَتْنَا بِهِ حَدَائِقَ ذَاتَ بَهْجَةٍ مَا
كَانَ لَكُمْ أَنْ تُنبِتُوا شَجَرَهَا أَإِلَهُ مَعَ اللَّهِ
بَلْ هُمْ قَوْمٌ يَعْدِلُونَ ﴿٦﴾

For any feedback, scan the code or click on it.



Corrections from previous versions:

Versions	Slide # and Place of Error	Before Correction	After Correction
V0 → V1			
V1 → V2			