

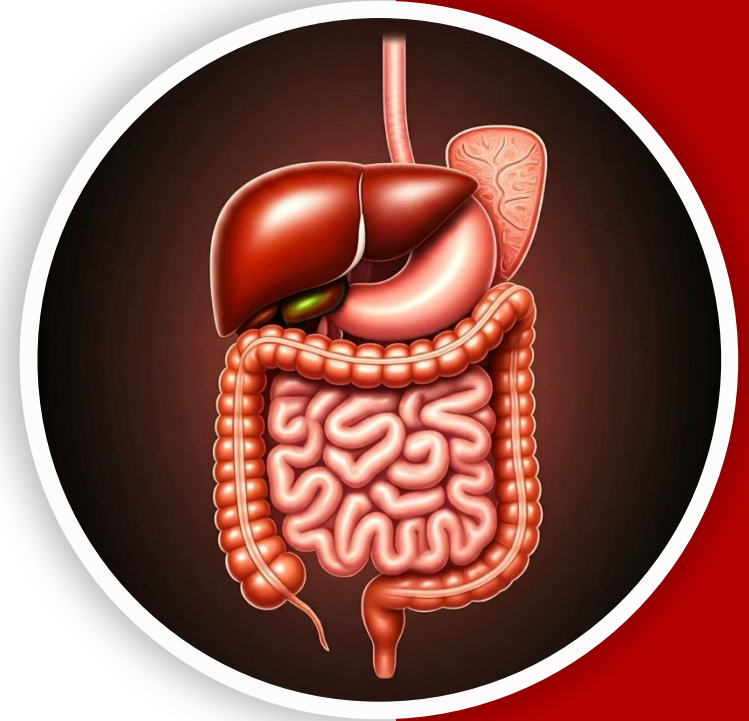
بِسْمِ اللّٰهِ الرَّحْمٰنِ الرَّحِیْمِ
(وَفَوْقَ كُلِّ ذِي عِلْمٍ عَلِيمٌ)



جراح

GIS Anatomy | Final 1

Liver, spleen & pancreas



Written by : Sara Alkhateeb

Reviewed by : Rawan Okour

1- The liver

- The **liver** is the **largest gland** in the body.
- It **weighs** about **1-1.5 kg**;
 - \approx 1/50th of adult body weight. *thus, to calculate it, use (body weight \div 50).*
 - \approx 1/20th of infant body weight. *thus, to calculate it, use (body weight \div 20).*

The liver is relatively larger in infants because of their higher metabolic demands and activity; therefore, it represents a greater proportion of total body weight.

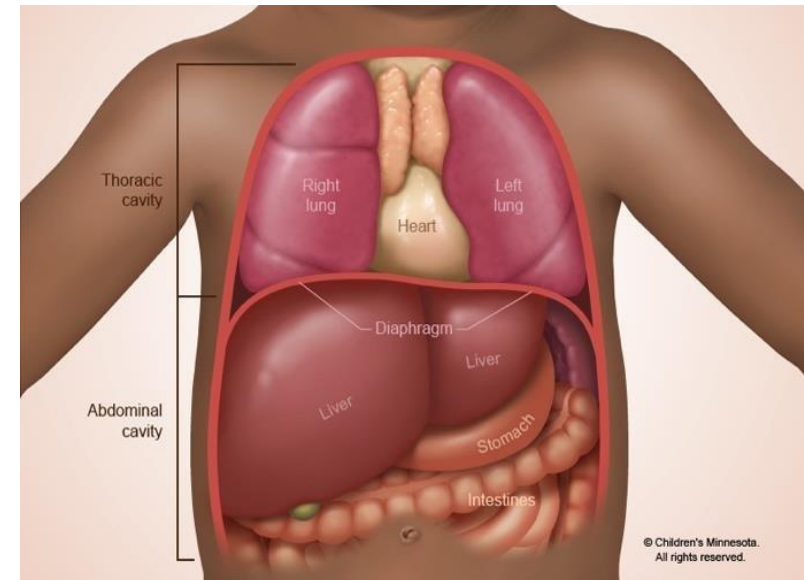
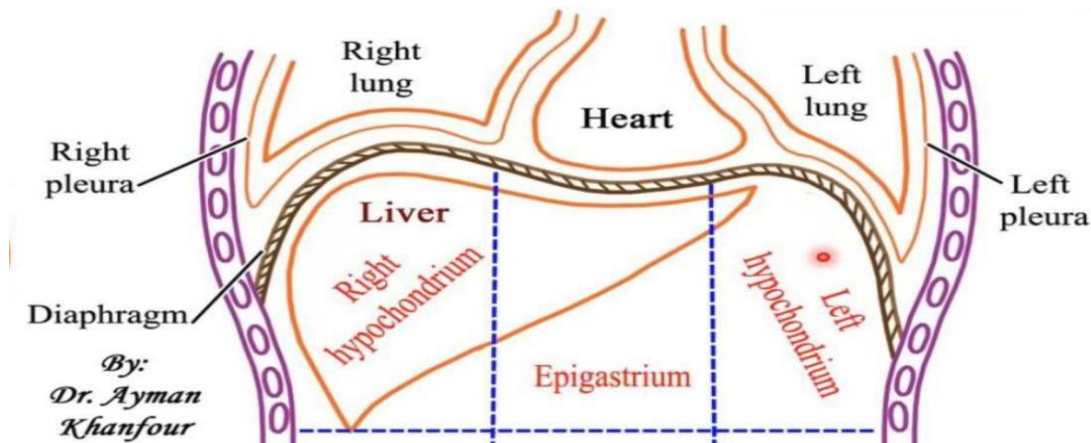
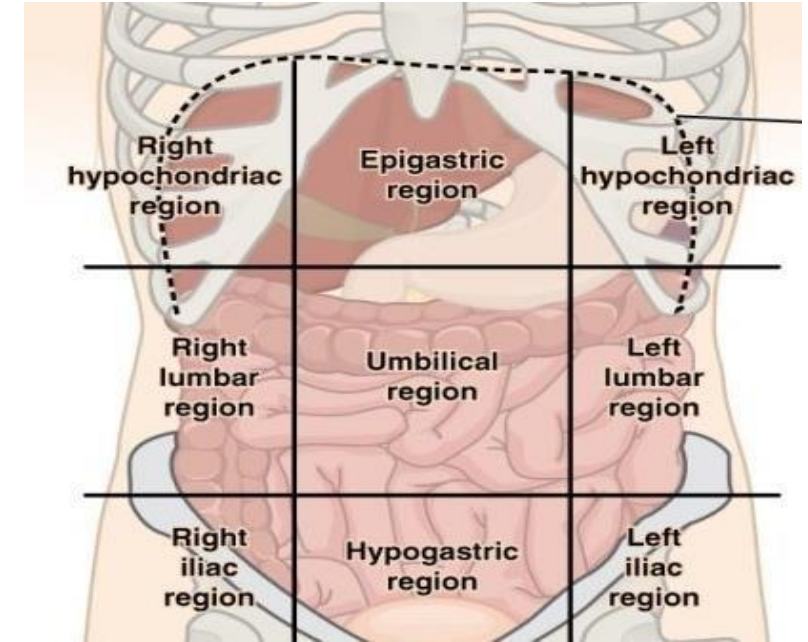
- It is classified as a **mixed gland**:
 - **Exocrine**: secretes bile and bile salts.
 - **Endocrine**: secretes *albumin, *thrombin, *prothrombin, *fibrinogen, (*all are plasma proteins with different functions*) heparin(anticoagulant), coagulants, enzymes, and hormones.
- The liver is a **vital** organ with **multiple essential functions**:
 - Metabolizes carbohydrates, fats, and proteins transported via portal vein after GI absorption.
 - Formation of heparin (anticoagulant).
 - Detoxification of drugs (mainly liver, also kidney).
 - Glycogen (energy reservoir) & vitamin storage(Vit. K).
 - Activation of vitamin D.

2- The Liver Location

- **Liver Position in the Abdomen**

Occupies three of the nine abdominal regions:

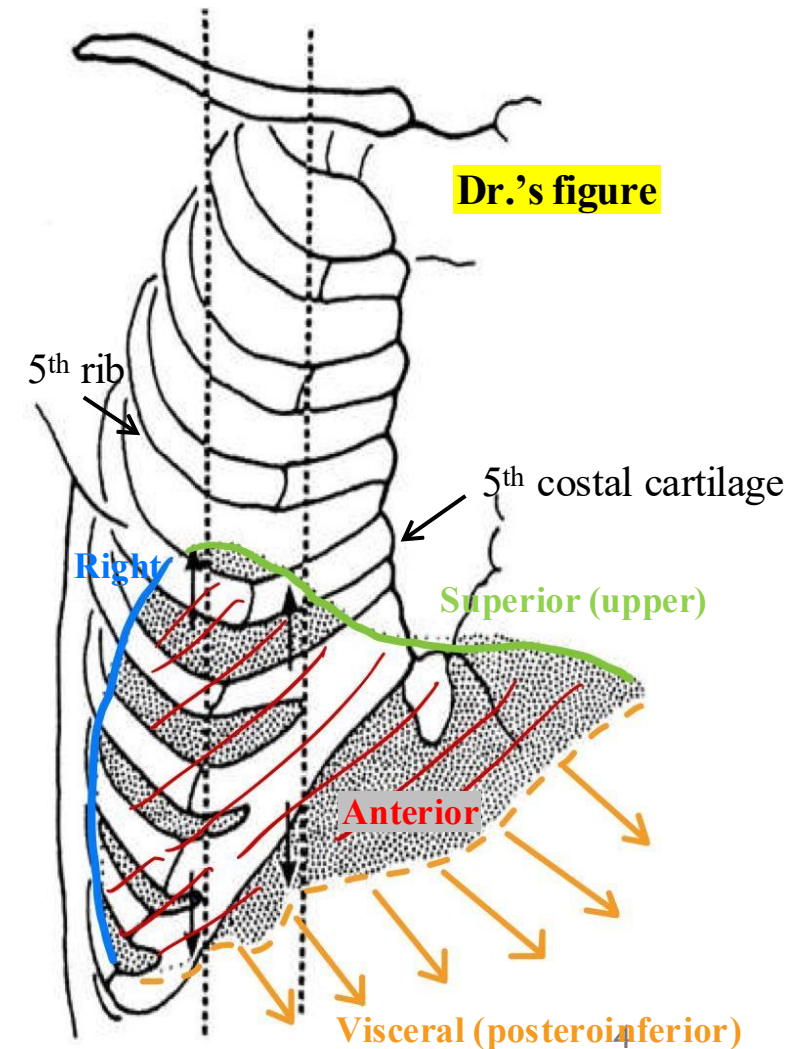
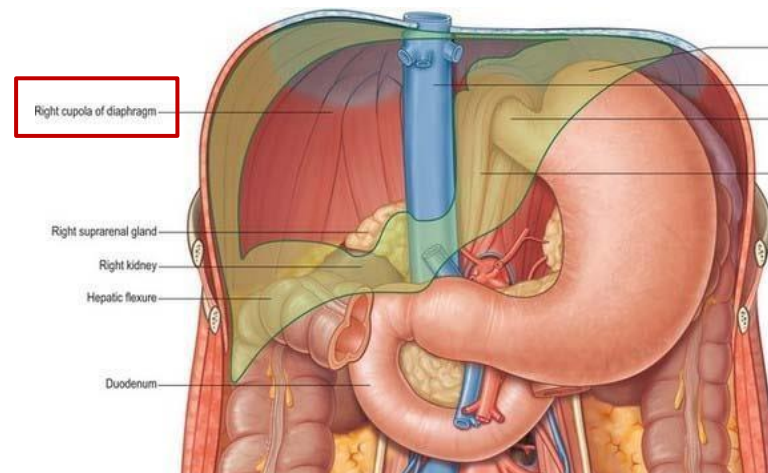
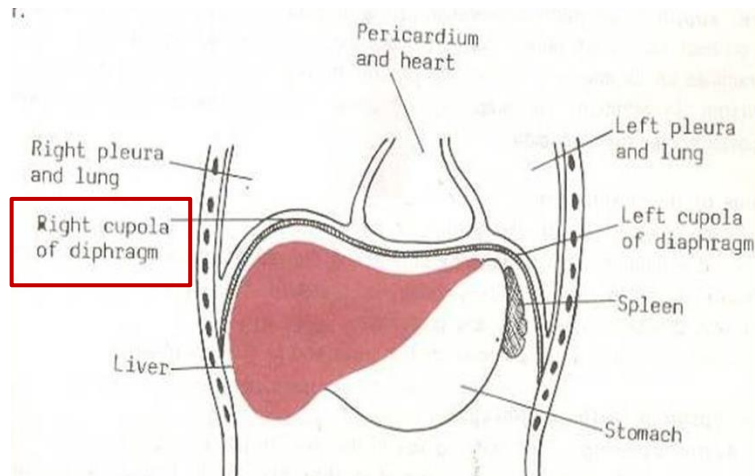
- **Right hypochondriac region** (right lobe)
 - **Epigastric region** (left lobe)
 - **Left hypochondriac region** (left lobe extension)
-
- The diaphragm separates the liver superiorly from the **right pleura and right lung on the right side**, and from the **pericardium and heart centrally** and the **left lung and pleura on the left side**.



3- The liver surfaces

- The liver has **5 surfaces**: anterior, right, superior, posterior and visceral (posteroinferior).
- The right cupola of the diaphragm overlies the upper surface of the liver, forming a **dome** that **covers four of the liver's surfaces**: the **anterior, superior, posterior, and right surfaces**. ONLY the superior surface is covered completely, while the three other surfaces are only covered partially.

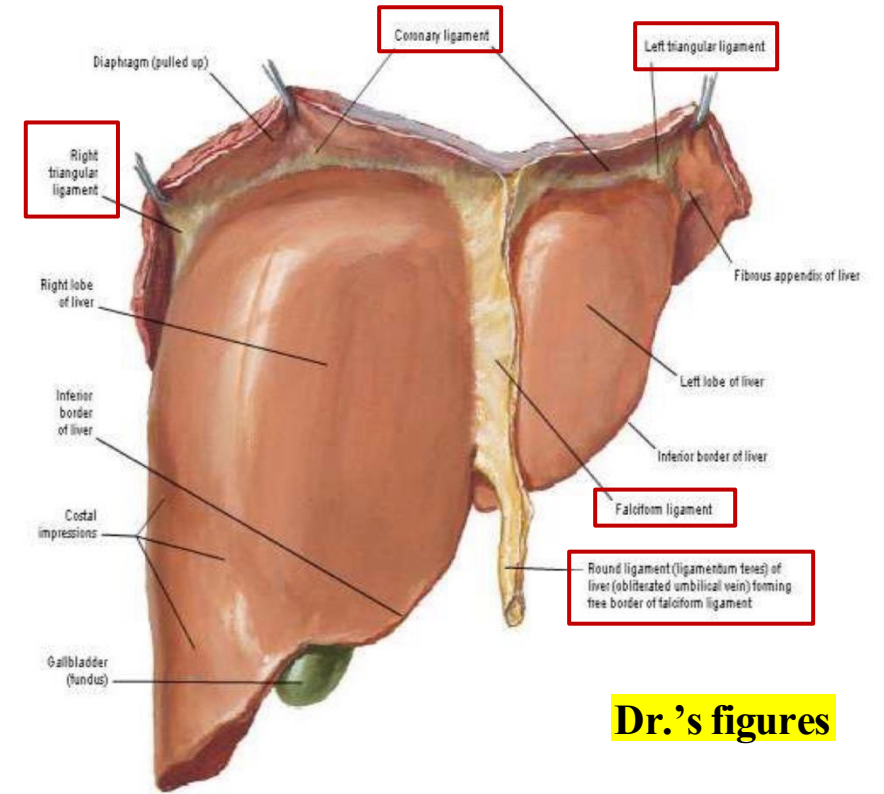
1. The upper (superior) surface is associated with the right costal cartilage, pushing the diaphragm upwards into the chest and reaching the 5th right costal cartilage and 5th right rib.



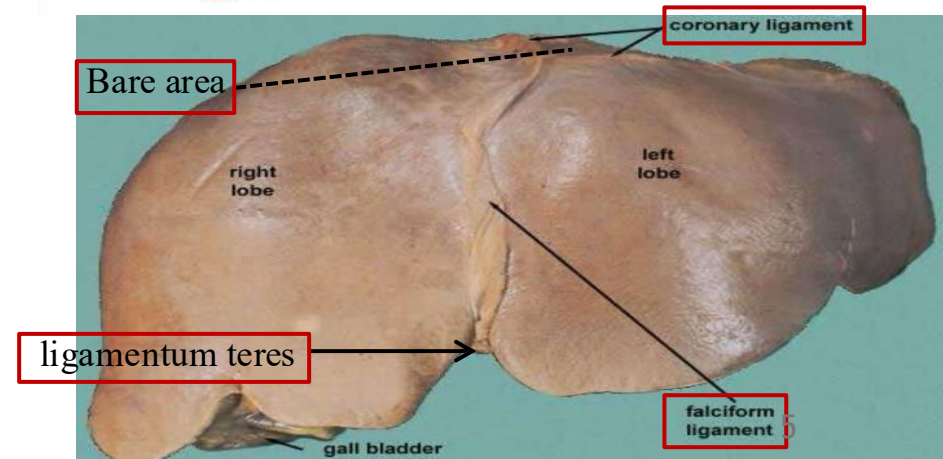
3- The liver surfaces

On anterior view, the **superior surface of the liver** shows:

1. The **bare area**, an area enclosed by the **coronary ligament** and lying directly beneath the **diaphragm**; it is termed 'bare' because it is the **ONLY** part not covered by peritoneum.
2. The **coronary ligament** has anterior and posterior lips whose lateral union forms the **right and left triangular ligaments**.
3. The **falciform ligament**, made of two layers of peritoneum, separates the right and left lobes, attaches to the anterior abdominal wall and diaphragm, and ends as the **round ligament (ligamentum teres)** > a remnant of the obliterated umbilical vein.

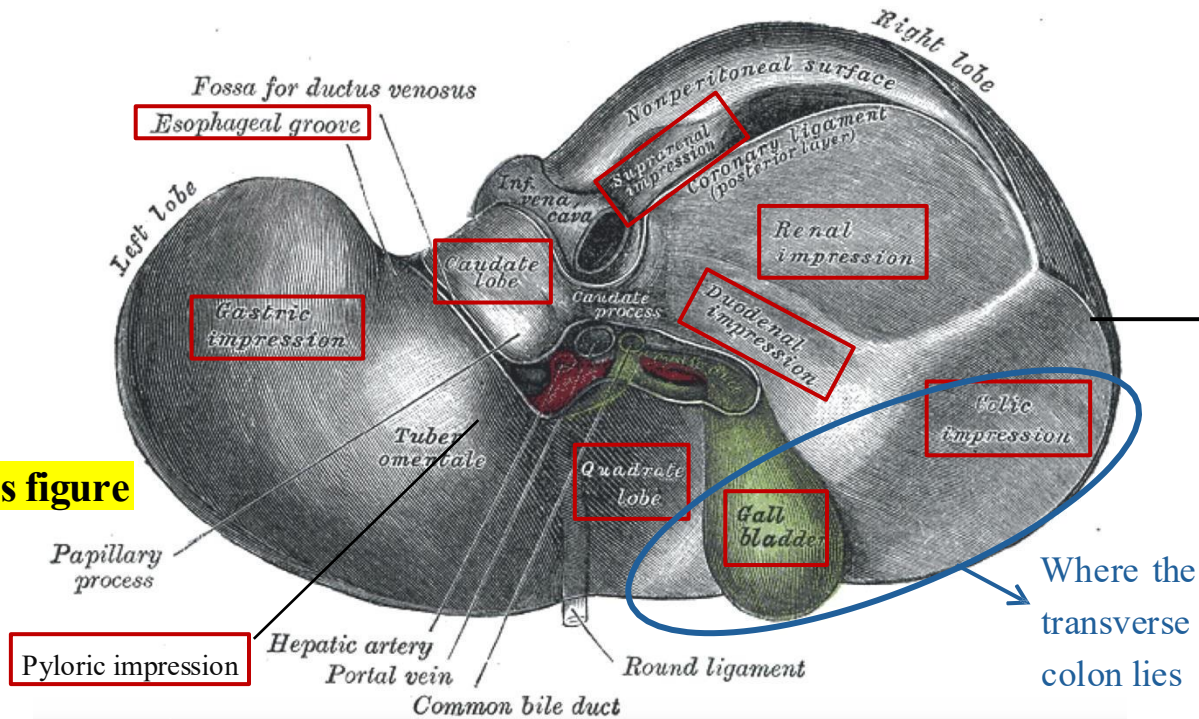


Dr.'s figures

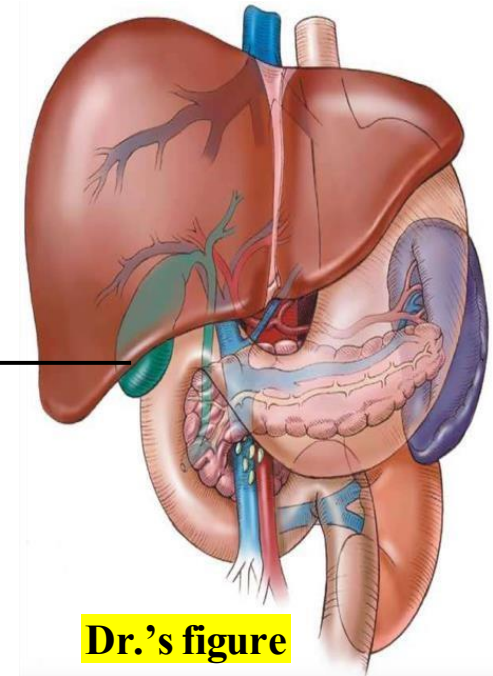


3- The liver surfaces

- 2. The visceral surface** contains **impressions** (slight depressions) formed by organs surrounds the liver.
- The **left lobe** contains depressions formed by the **esophagus, stomach, and pylorus**.
 - The **right lobe** contains depressions formed by **right kidney, right suprarenal gland, right colic flexure, transverse colon, and duodenum**.



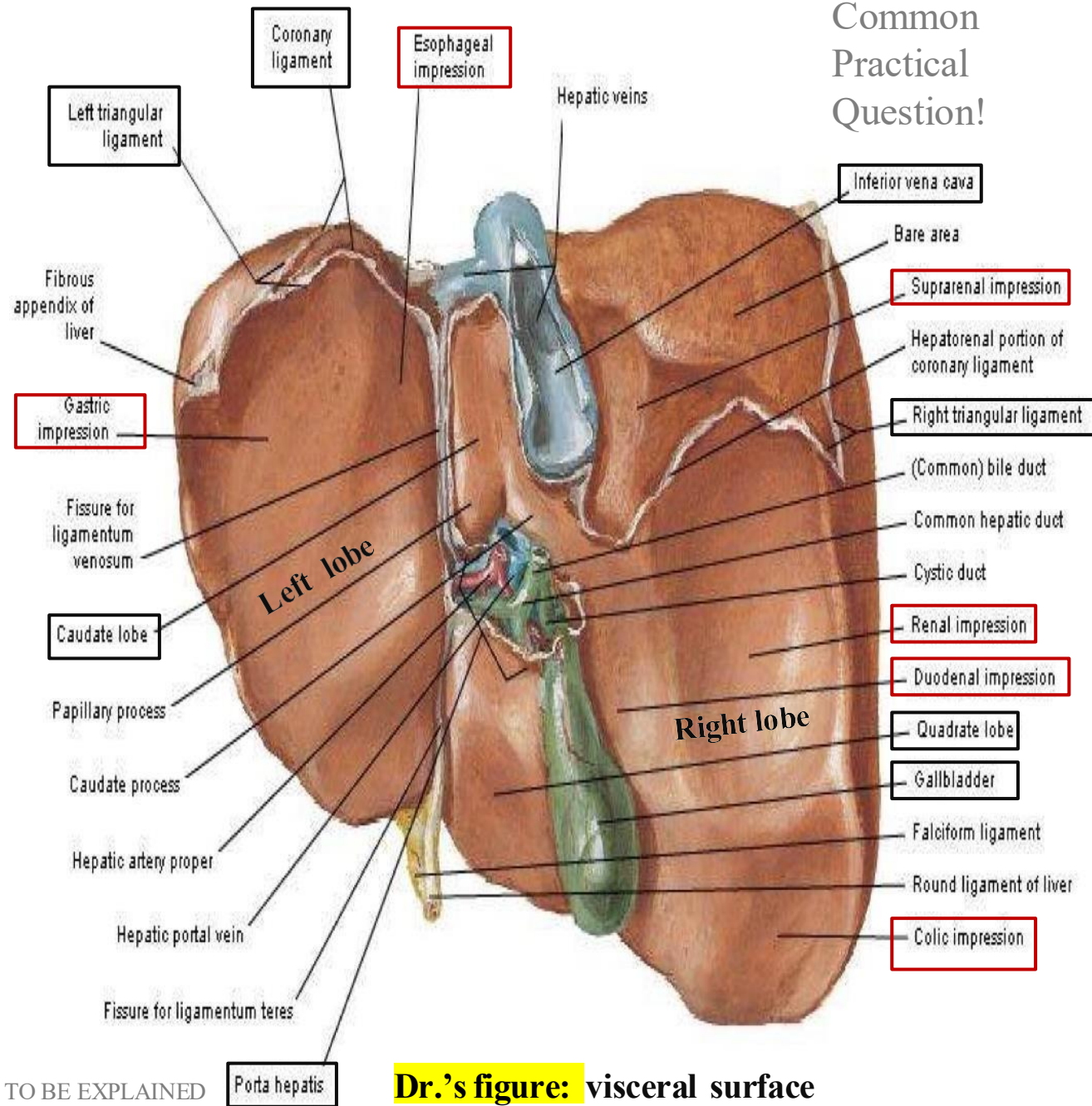
The inferior border of the liver is sharp and related to the right **9th costal cartilage**. It may be 😊 **palpated** when the patient takes a deep breath, and this becomes more evident in cases of ☹ **hepatomegaly**



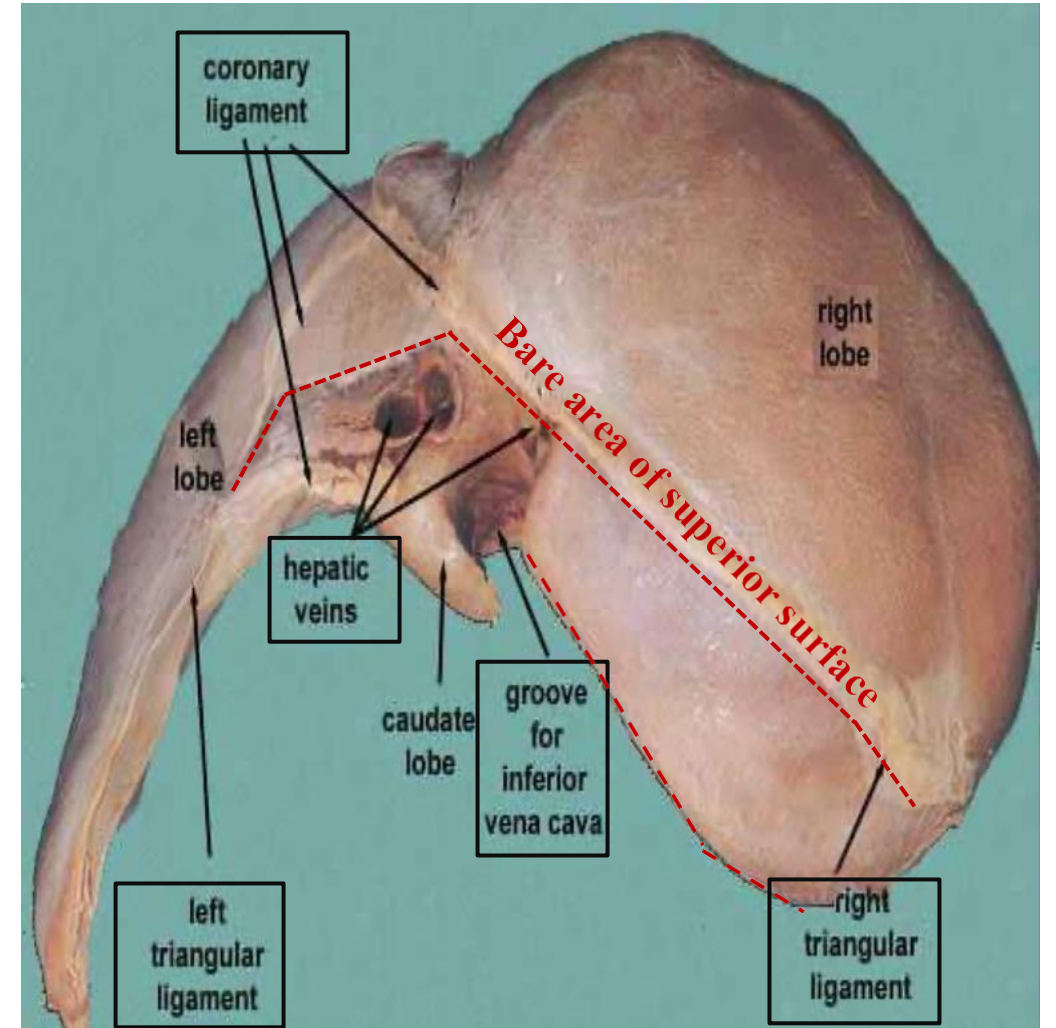
Dr.'s figure

*When viewing the anterior surface, the right of the diagram represents the viewer's left, and vice versa. However, when viewing the visceral surface, the right of the diagram corresponds to the actual right side, and the left to the actual left.

Common Practical Question!



Dr.'s figure: visceral surface

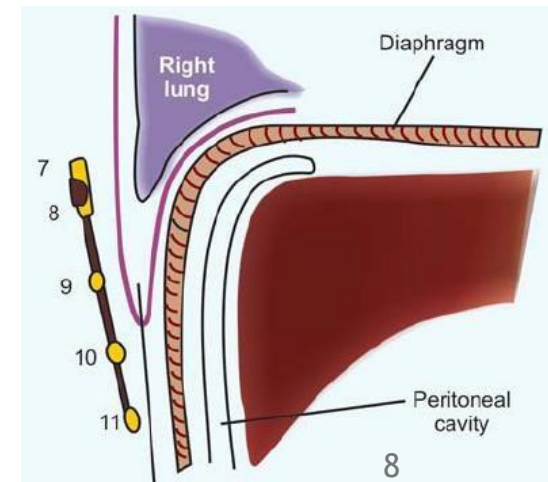
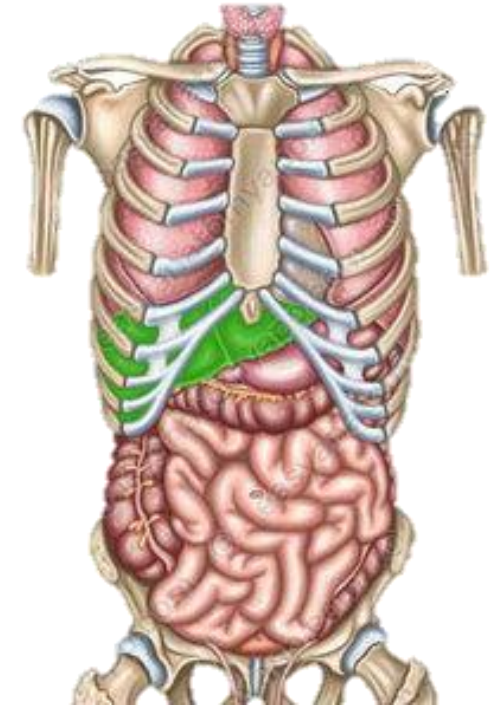


Dr.'s figure: superior surface

4- The liver relations

Surface	Structures Related
Superior	<ul style="list-style-type: none"> • Diaphragm
Anterior	<ul style="list-style-type: none"> • Diaphragm • Right pleura & right lung • Xiphoid process • Costal cartilages (7th-9th) • Anterior abdominal wall (😊 palpation)
Posterior & Visceral (Posteroinferior)	<ul style="list-style-type: none"> • Part of the Diaphragm • Right kidney • Right suprarenal gland • Transverse colon • Duodenum • Gallbladder • Inferior vena cava • Esophagus • Stomach

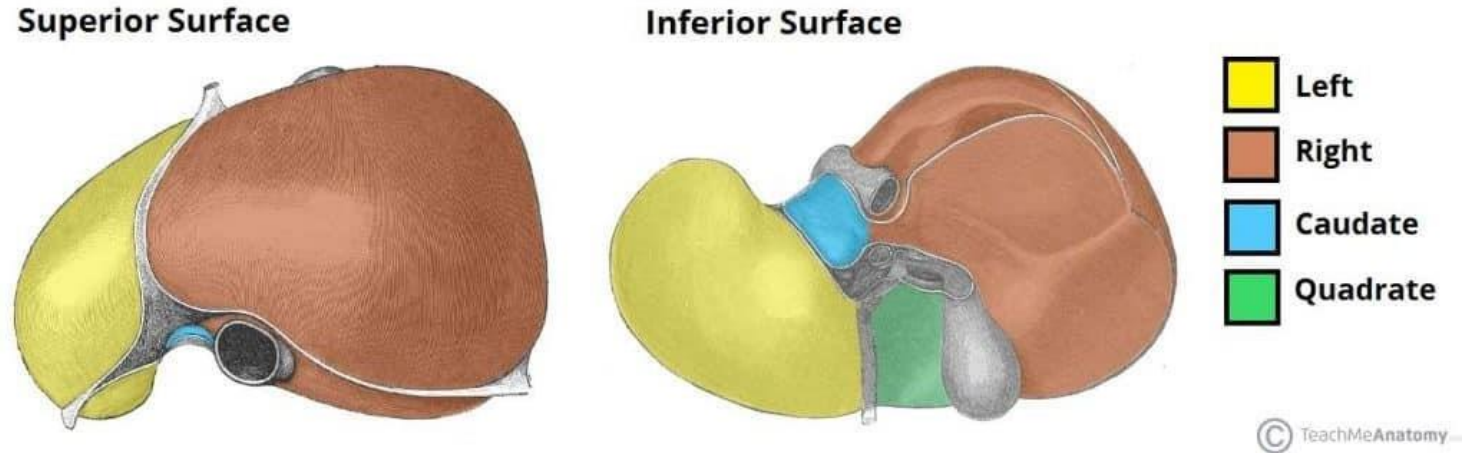
All can be seen as impressions



5- The liver lobes

- **Anatomical Lobes:**

- Right lobe
- Left lobe
- Caudate lobe
- Quadrate lobe



- **Functional Lobes:**

- **Right lobe** is a separate functional unit
- **Caudate and quadrate lobes** are functionally(physiologically) part of the **left lobe**

The reason for the **functional** division is that the caudate and quadrate lobes share their **arterial** supply and their main **secretory duct** with the left lobe. – *next slide*

“Functional Division?”

- To be explained in a better sequence -

Arterial Supply:

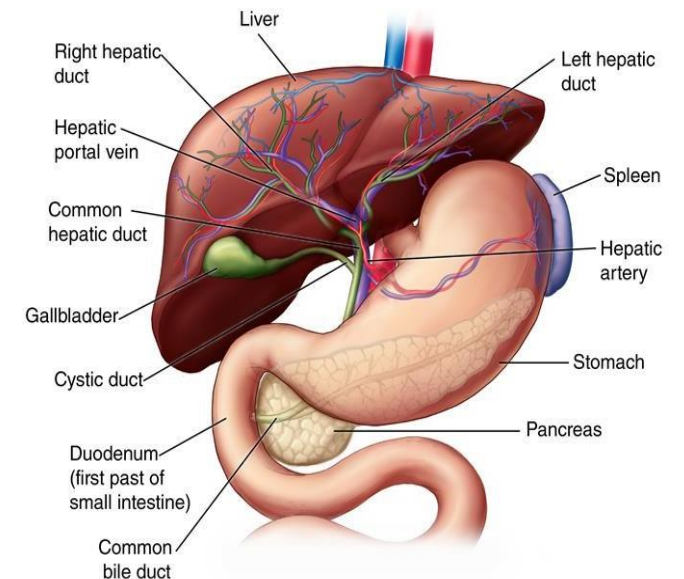
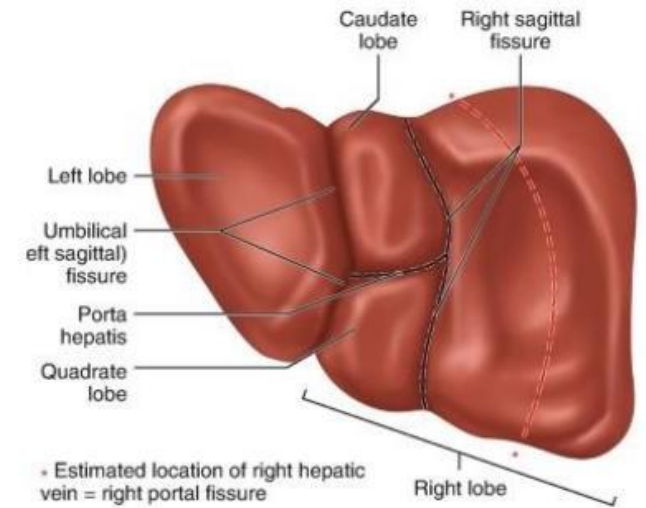
- At the porta hepatis, the hepatic artery divides into:
 - **Right branch** supplies the **right lobe** and gives off the **cystic artery** to the **gallbladder**.
 - **Left branch** supplies the **left, caudate, and quadrate lobes**.

Bile Secretion:

- The **right lobe** drains bile into the **right hepatic duct**.
- The **left hepatic duct** drains bile from the **left, caudate, and quadrate lobes**.

Venous Drainage:

- Not precisely opposite of the arterial supply.
- Three separate hepatic veins drain directly into the inferior vena cava:
 - **Right hepatic vein** → from the **right lobe**.
 - **Left hepatic vein** → from the **left lobe**.
 - **Central hepatic vein** → from the **caudate and quadrate lobes**.

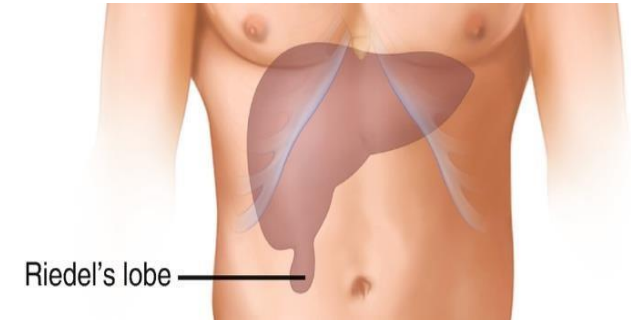


5- The liver lobes

1. Right lobe of the liver:

- **Larger**
- Found in the **right hypochondriac region**.
- An inferior extension, known as ***Reidel's lobe**, reaches the iliac crest.

**Reidel's lobe is an anatomical variant. It is not a pathological condition*

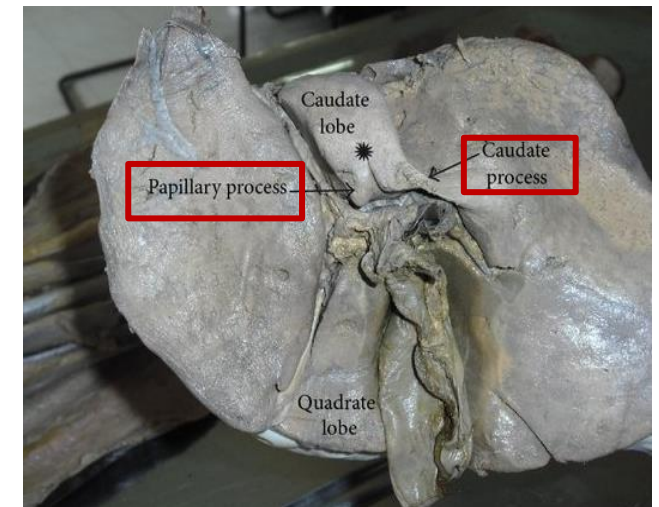


2. Left lobe of the liver:

- **Smaller.**
- Found in the **left hypochondriac and epigastric regions**.

3. Caudate lobe of the liver:

- Lies between the ligamentum venosum and the inferior vena cava, and provides two processes:
 - **Caudate process**
 - **Papillary process.**



4. Quadrate lobe of the liver:

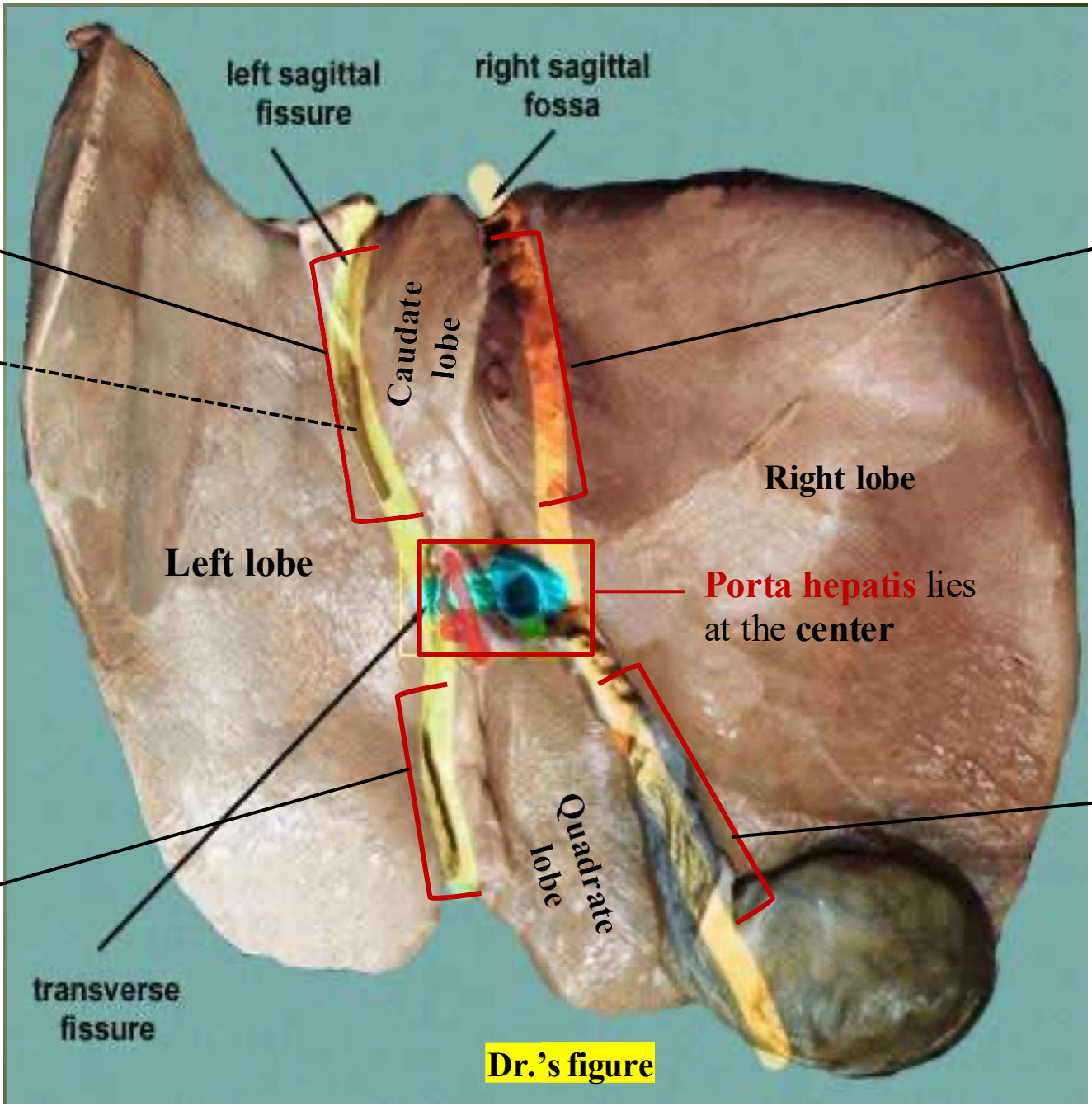
- Lies to the side of the gallbladder.
- It is related to the **anterior margin of the liver anteriorly**, the **porta hepatis superiorly**, the **fossa for the gallbladder on the right**, and the **fossa for the ligamentum teres on the left**.

Ligamentum venosum

Fissure

ligamentum venosum and the ligamentum teres form a line that separates the left lobe from the other lobes.

Ligamentum teres



left sagittal fissure

right sagittal fossa

Caudate lobe

Left lobe

Right lobe

Porta hepatis lies at the center

Quadrate lobe

transverse fissure

Dr.'s figure

Inferior vena cava

The inferior vena cava and gallbladder form a line that separates the right lobe from the other lobes

Gallbladder

6- The Porta Hepatis

Porta Hepatis (Hilum of the Liver)

- The porta hepatis is the hilum of the liver, *an indentation where major structures enter or leave the liver.*
- Located on the visceral surface of the liver.
- Surrounded by the peritoneum of the lesser omentum, which connects the liver to the stomach.

Contents of the Porta Hepatis:

1. Hepatic Artery

Divides into **right** and **left** hepatic arteries

2. Portal Vein

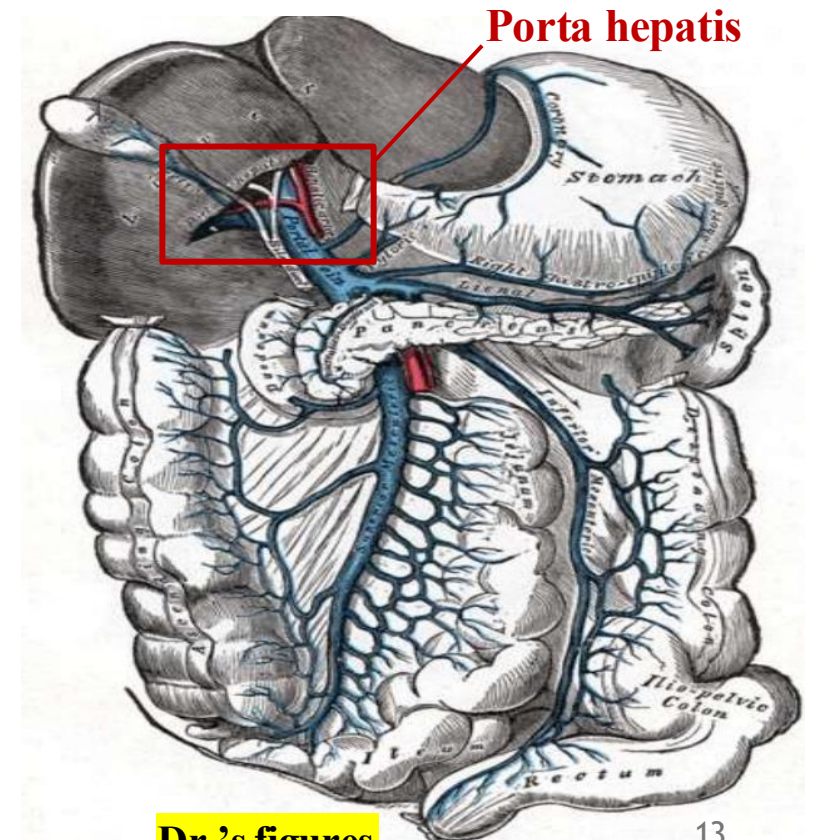
Main vein bringing nutrient-rich blood from the GI tract
Divides into **right** and **left** branches (tributaries)

3. Common Bile Duct

Formed by the union of **hepatic duct** and **cystic duct**
(It Passes behind the first part of the duodenum, & the head of the pancreas, Opens into the second part of the duodenum)

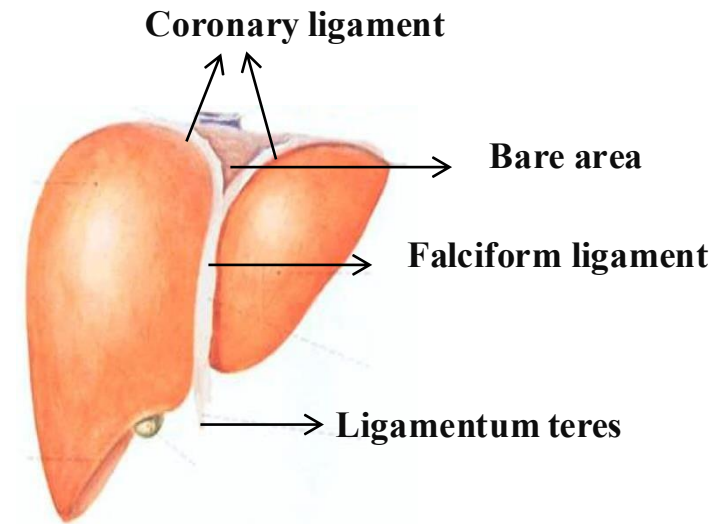
4. Hepatic Lymph Nodes

5. Sympathetic and parasympathetic Nerves fibers



7- Peritoneal Covering of the Liver

- The entire liver is covered by peritoneum, except for the bare area.
- The bare area is:
 - Located on the superior surface of the liver, Lies directly beneath the diaphragm. Enclosed by the coronary ligament.
 - Not covered by peritoneum, so appears dull (unlike the shiny peritoneal surface).



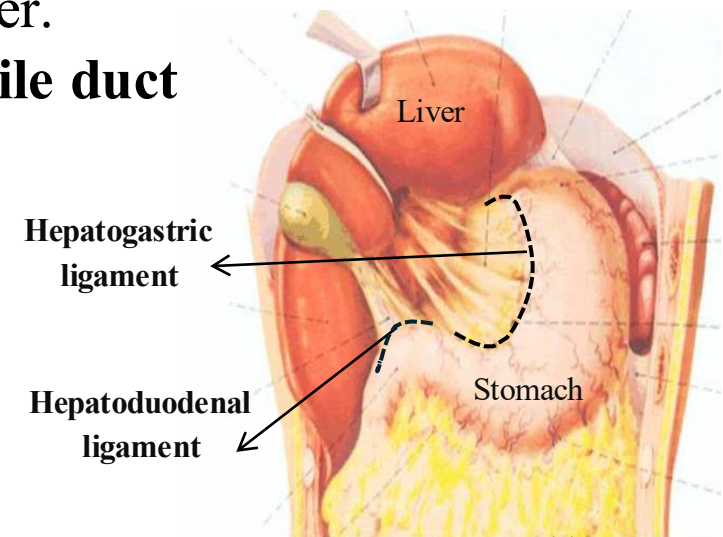
Lesser Omentum

- A double layer of peritoneum extending between the stomach and liver.
 - Its free edge contains: *Hepatic artery, *Portal vein & *Common bile duct
- These structures are the same as those found in the porta hepatis.

Subdivisions of the Lesser Omentum:

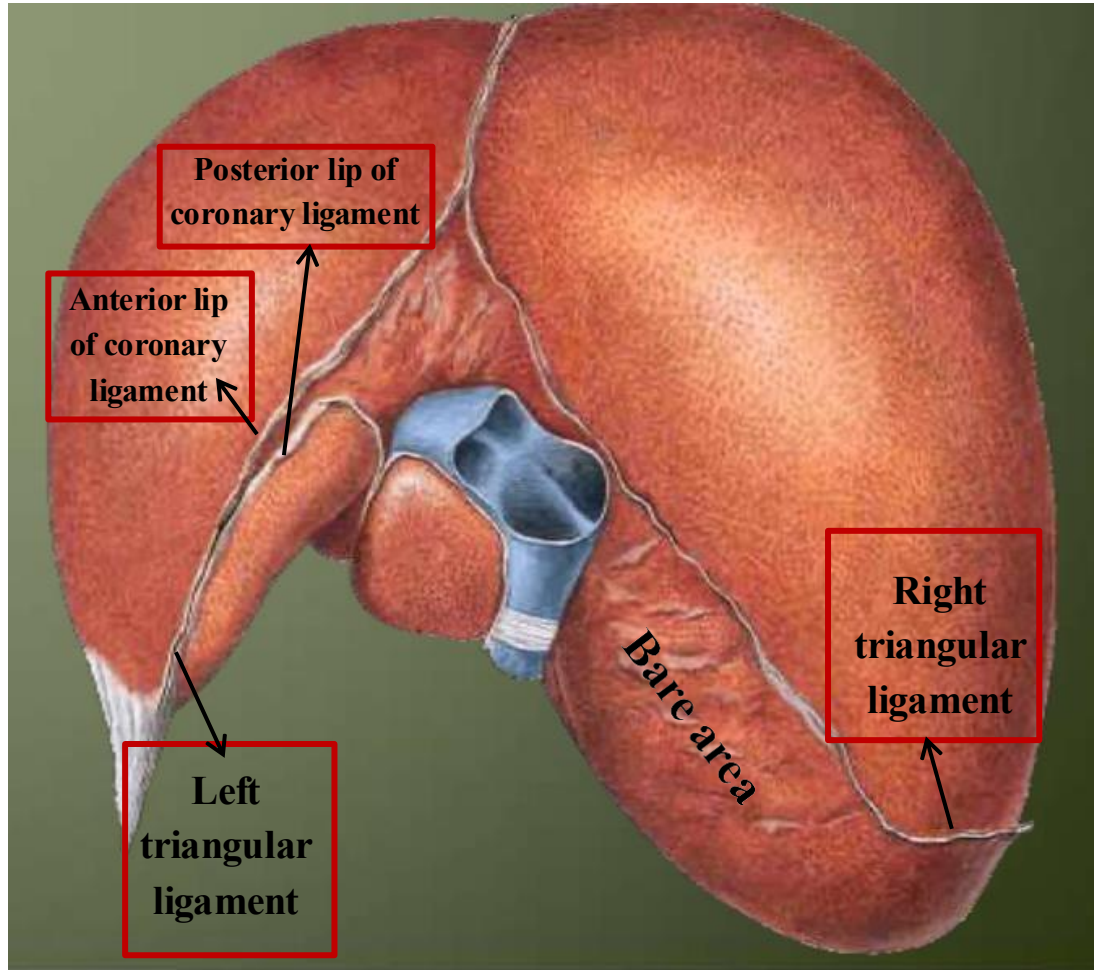
- **Hepatogastric ligament** – between the liver and stomach
 - **Hepatoduodenal ligament** – between the liver and duodenum
- Together, they form the lesser omentum.

Dr.'s figures

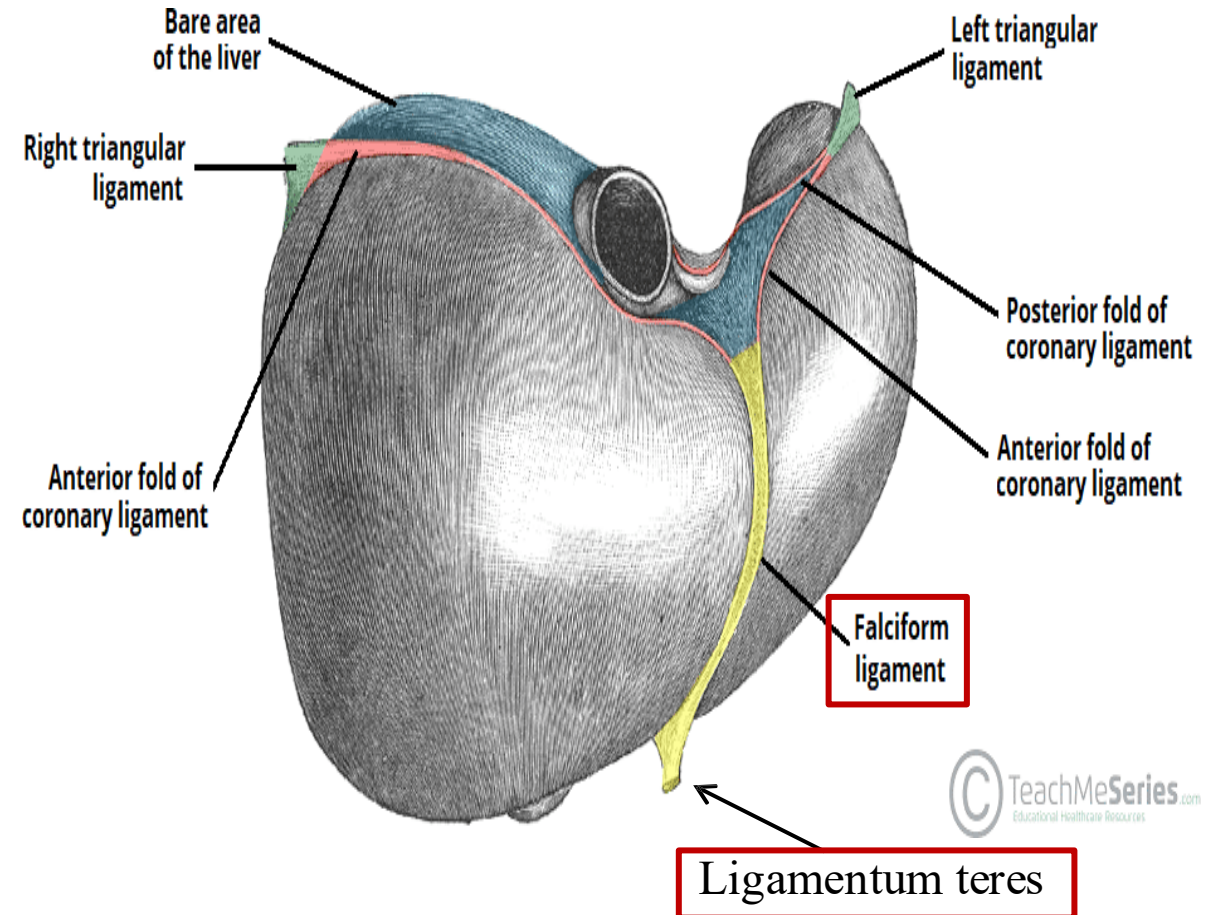


8- The liver ligaments

Ligament	Description
Falciform ligament	Sickle-shaped; separates right and left lobes; attaches to anterior abdominal wall and diaphragm upwards.
Ligamentum teres	Obliterated umbilical vein ; found at lower end of the falciform ligament; free (not attached to another structure).
Coronary ligament	Surrounds the bare area of the liver (superior surface); peritoneal covering ends here.
Right triangular ligament	Formed by the right edge of the coronary ligament.
Left triangular ligament	Formed by the left edge of the coronary ligament.
Hepatogastric ligament	Part of the lesser omentum ; connects liver to stomach.
Hepatoduodenal ligament	Part of the lesser omentum ; connects liver to duodenum.
Ligamentum venosum	Obliterated ductus venosus (fetal vessel found between IVC and portal vein) lies between the caudate and left lobes in the fissure of the ligamentum venosum.



Dr.'s figure



9- The Portal Vein

Formation of the Portal Vein

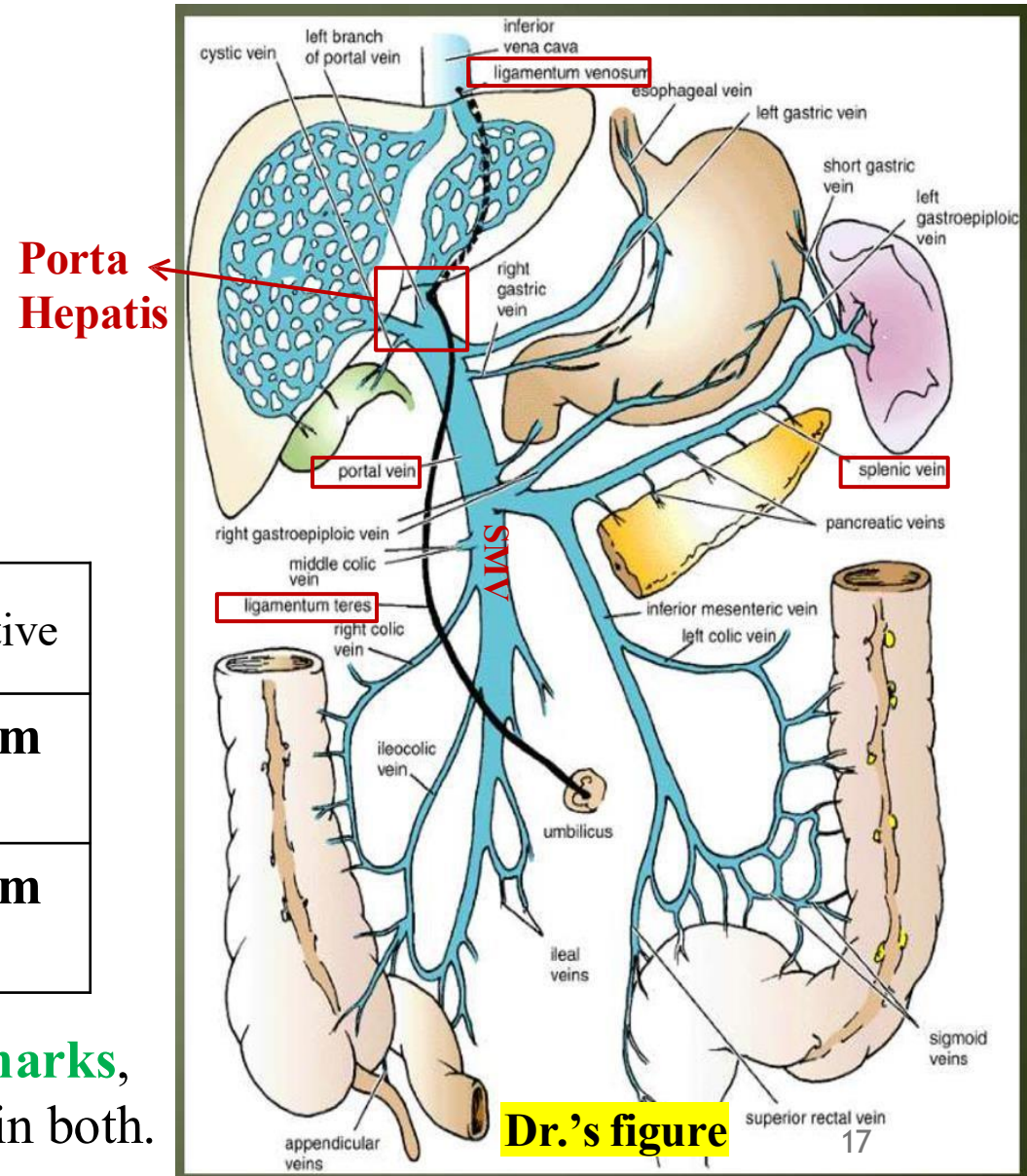
- The portal vein is formed by the union of the **splenic vein** and the **superior mesenteric vein (SMV)**, behind the neck of the pancreas.

Division at the Porta Hepatis

- At the porta hepatis, the portal vein divides into:
 - Right portal vein**
 - Left portal vein** (clinically important)

Embryonic Structure	Location (in embryo)	Adult Derivative
Ductus venosus	Between the inferior vena cava and left portal vein	Ligamentum venosum
Umbilical vein	Between the umbilicus and left portal vein	Ligamentum teres

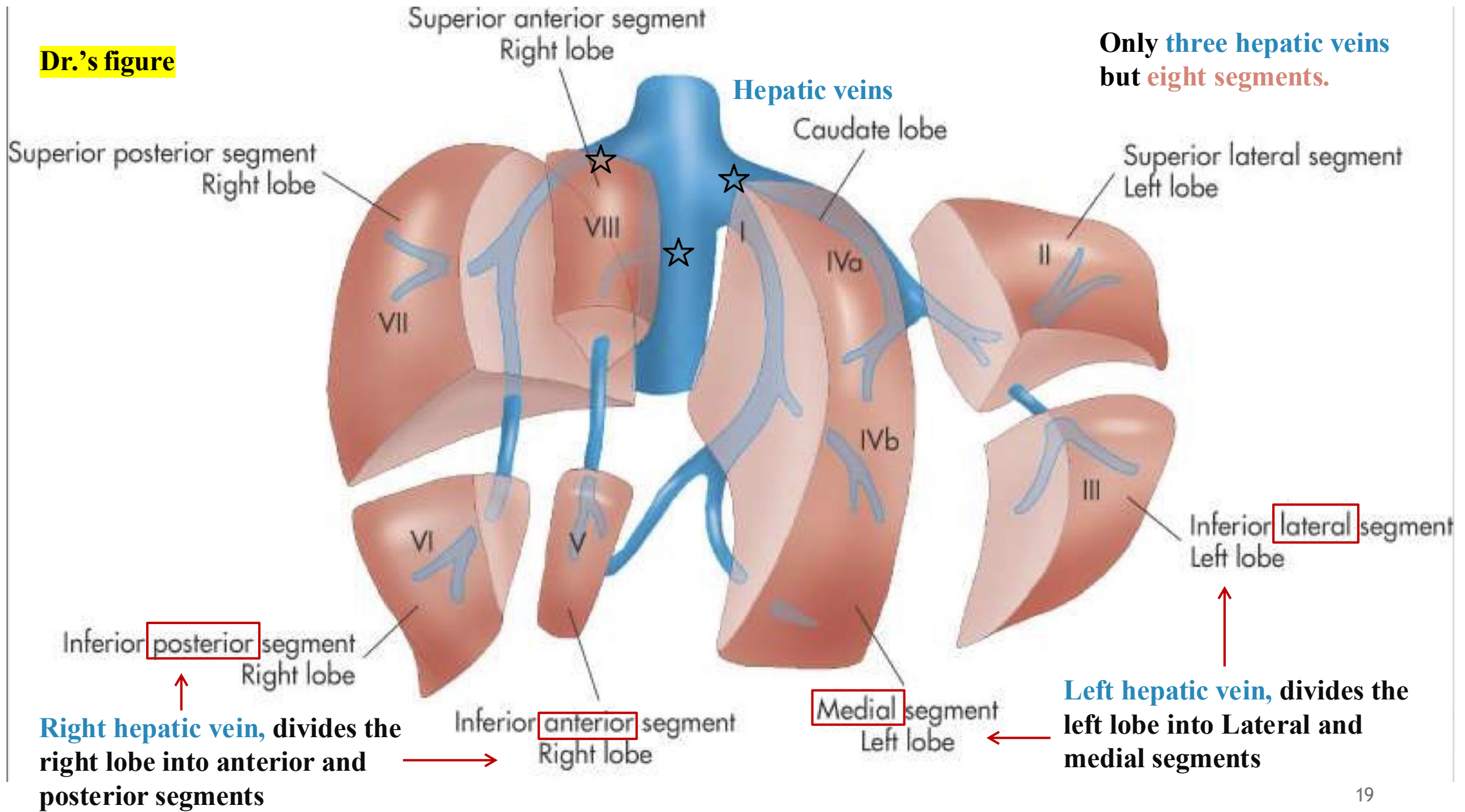
- These obliterated vessels are used as 😊 **anatomical landmarks**, especially the **left portal vein** which is centrally involved in both.



10- Segmental Anatomy of the Liver

- Only **1/8th of the liver** is sufficient to maintain full body function.
- ☹ **Diseases** like infections, **fibrosis**, or **cirrhosis** can rapidly spread across the liver once any segment is affected. If **complete liver failure** occurs, a 😊 **liver transplant** is required.
- **Liver transplants** involve transferring a segment of the liver from donor to patient. This segment is not chosen randomly; the liver has eight designated segments, **each of which has its own blood supply, venous drainage, innervation, and lymphatics**. One of these segments is chosen rather than transferring a large chunk of the liver.
- There are **only three hepatic veins** but eight segments.
- Of the eight segments, **segment IV consists of two parts: IVa and IVb**. Only one is required in a transplant. The two parts have the same blood supply.
- Currently, 😊 **stem cells** are increasingly used as an alternative to segmental transplant. When exposed to specific proteins, stem cells differentiate into hepatocytes (liver cells). These hepatocytes are then injected into the liver, where they proliferate via mitosis and help restore liver function.

Dr.'s figure



11- Liver Blood Supply

- The liver is supplied with blood by the **portal vein** and the **hepatic artery**

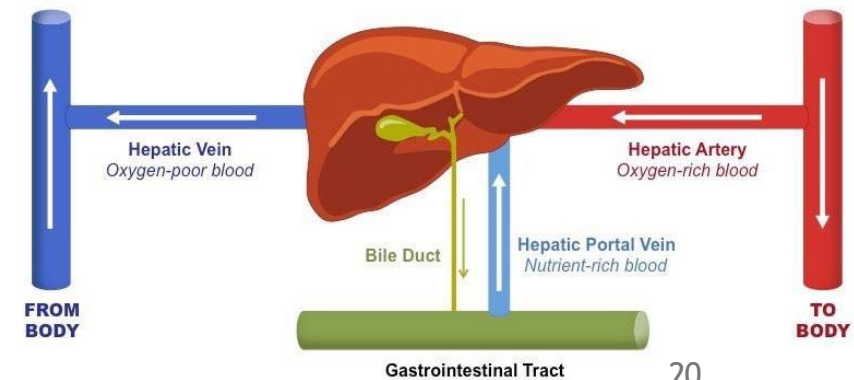
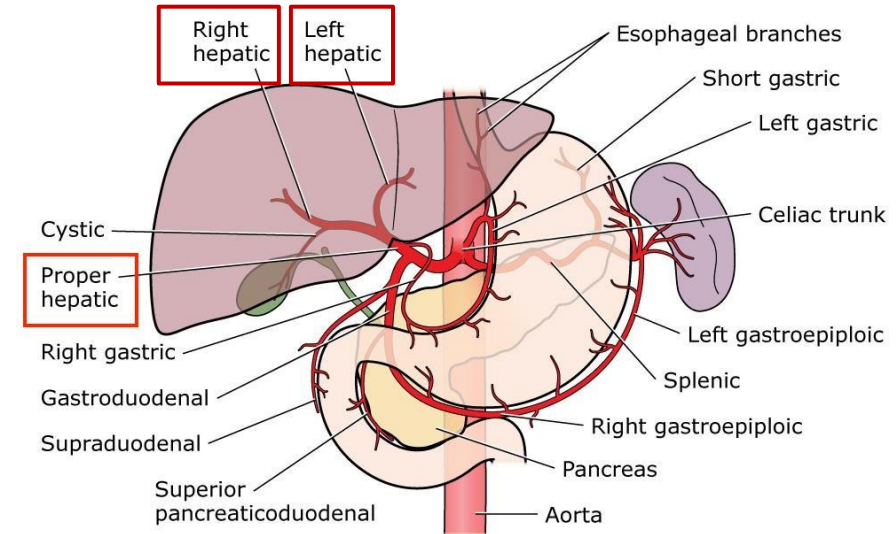
- **Hepatic artery** (branch of the *celiac trunk*):

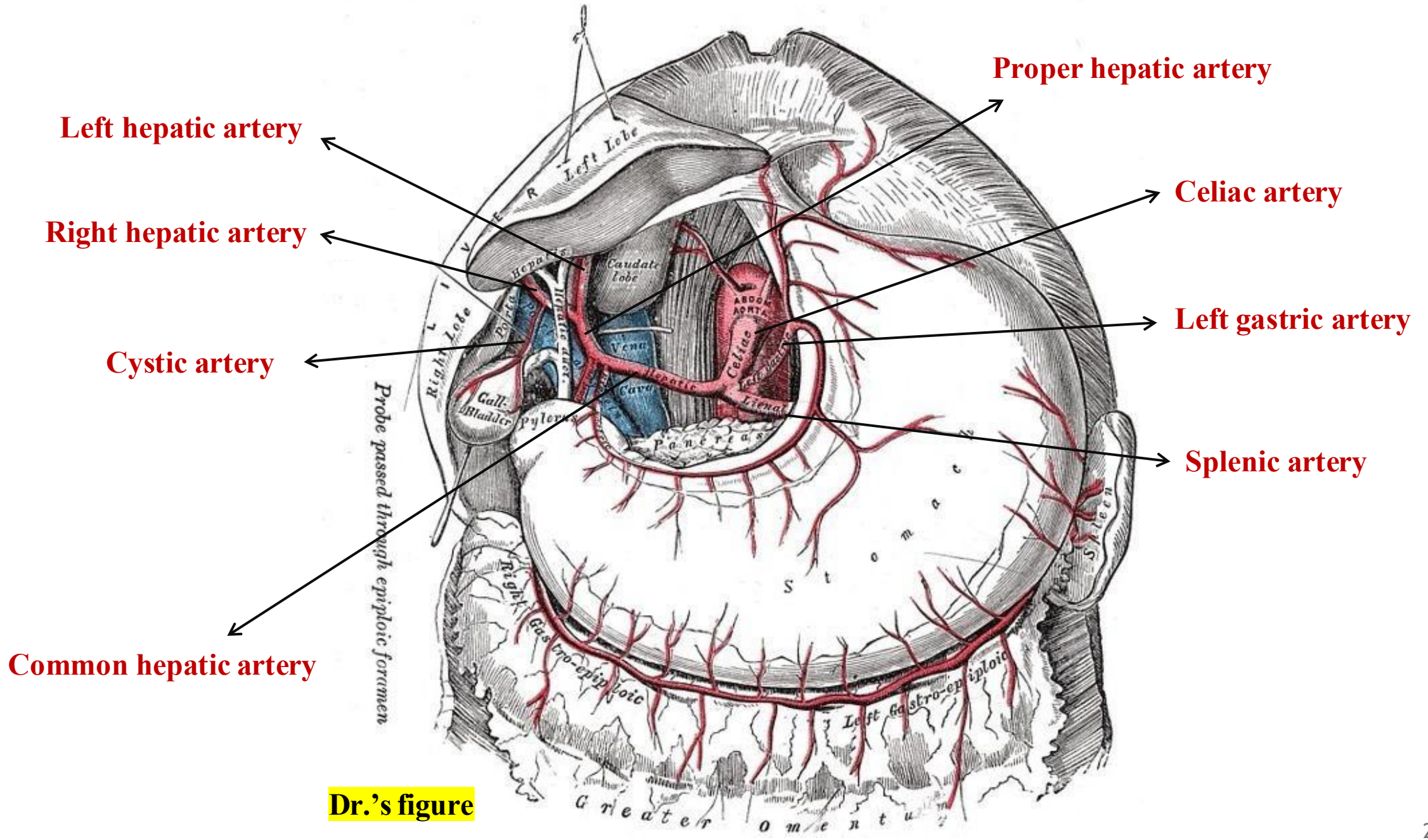
- Carries **oxygenated blood**.
- Supplies **20–25%** of the liver's total blood.
- Divides at the **porta hepatis** into:
 - **Right hepatic artery** which supplies the **right lobe**, it gives a **cystic artery** that supplies the **gallbladder**.
 - **Left hepatic artery** which supplies the **left, caudate, quadrate lobes**.

*thus, explain the functional division of the of liver lobes.

- **Portal vein:**

- Carries **nutrient-rich but oxygen-poor blood** from the absorbed nutritive materials of GIT.
- Responsible for **75–80%** of the liver's total blood supply.



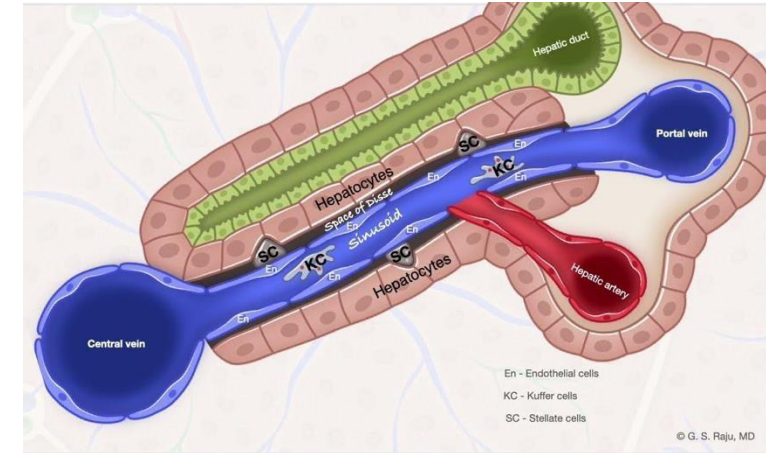


Dr.'s figure

11- Liver Blood Supply

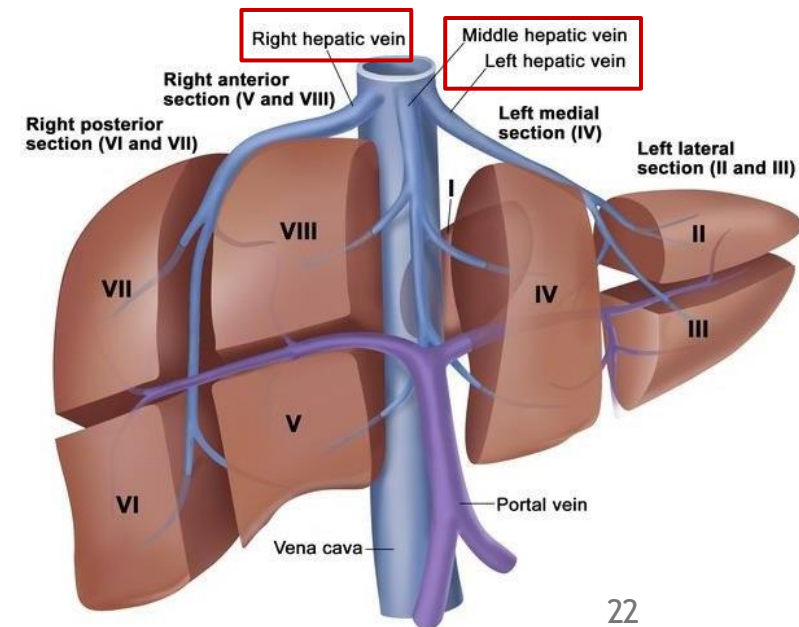
Blood Flow Inside the Liver

- Blood from **both sources** (hepatic artery and portal vein) enters **hepatic sinusoids** (pockets of blood).
- Sinusoids vary:
 - Some are **oxygen-rich** (from hepatic artery).
 - Others are **nutrient-rich** (from portal vein).
- **Hepatocytes** absorb **oxygen and nutrients** from different sinusoids as needed.



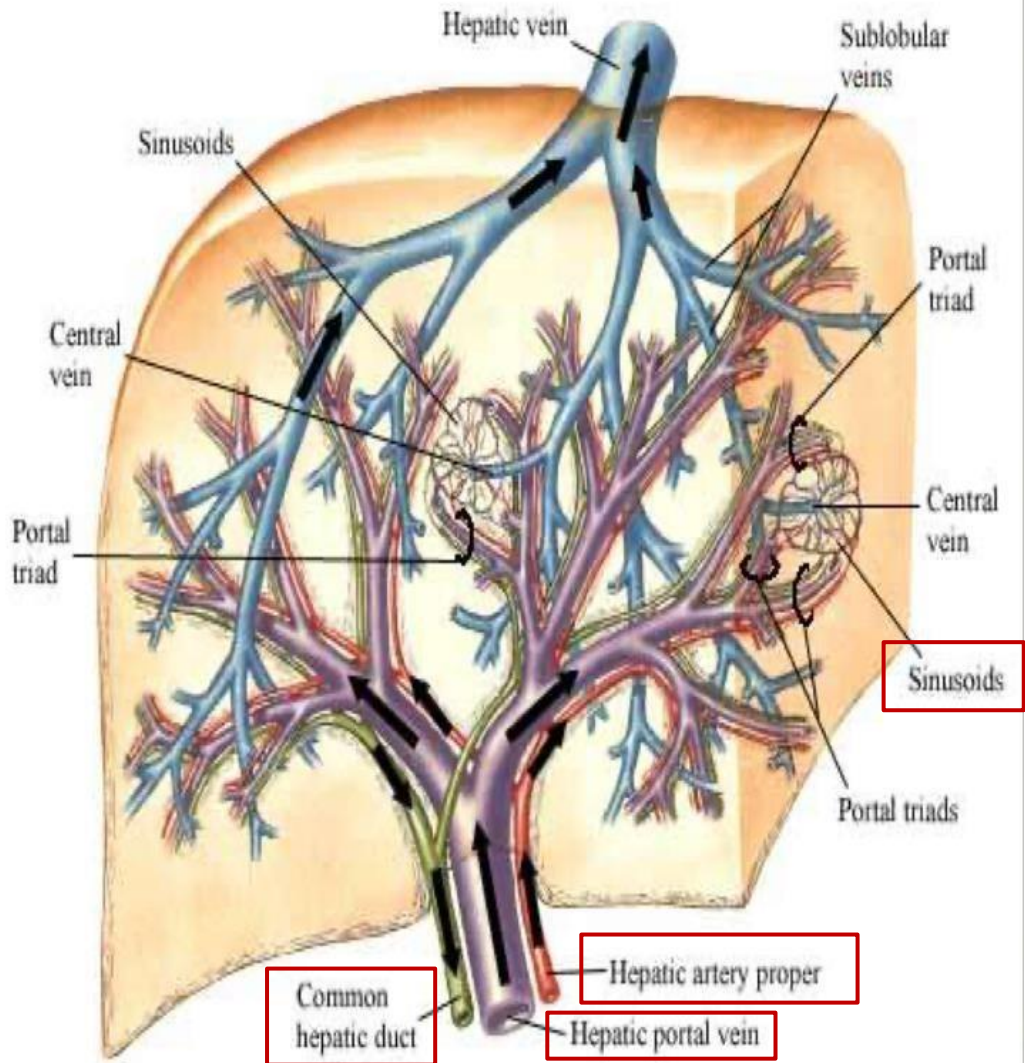
Venous Drainage

- Blood from sinusoids drains into:
- **Three hepatic veins:**
 - **Right hepatic vein** (from right lobe)
 - **Left hepatic vein** (from left lobe)
 - **Middle/central hepatic vein** (from caudate and quadrate lobes)
- These veins drain **directly into the inferior vena cava**, which then sends blood to the **right atrium** of the heart and then to the **lungs** for oxygenation.

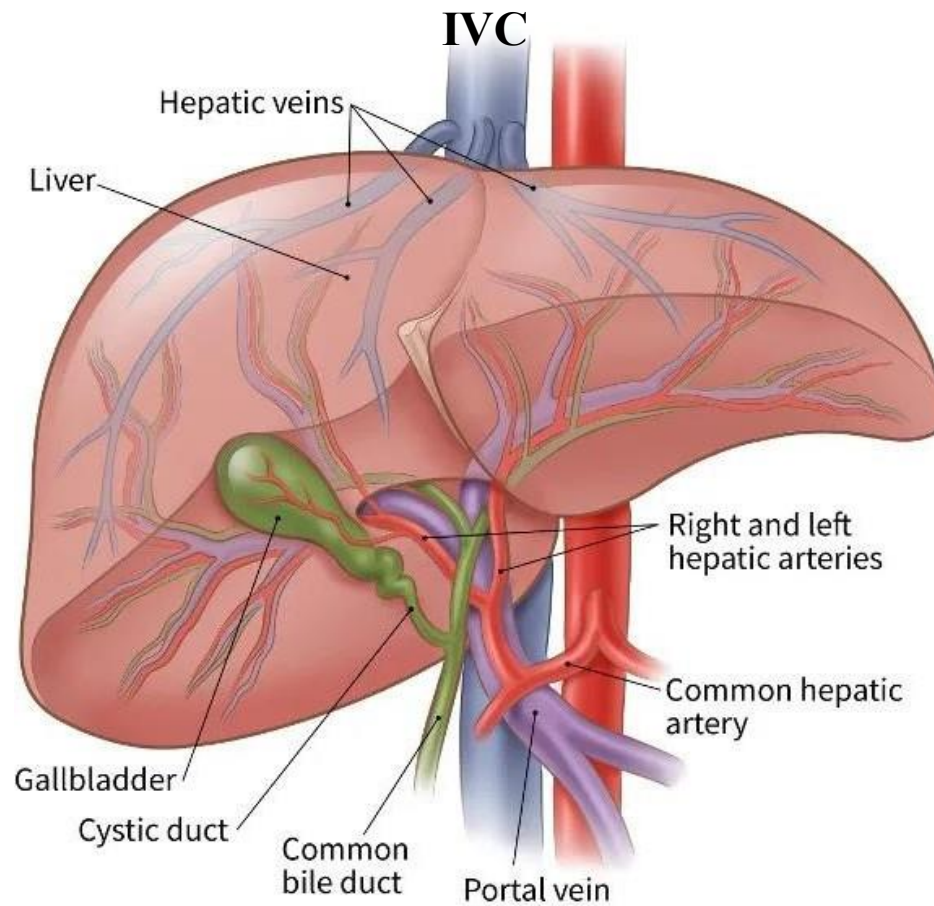


Intrahepatic Vascular and Duct Systems

Schema



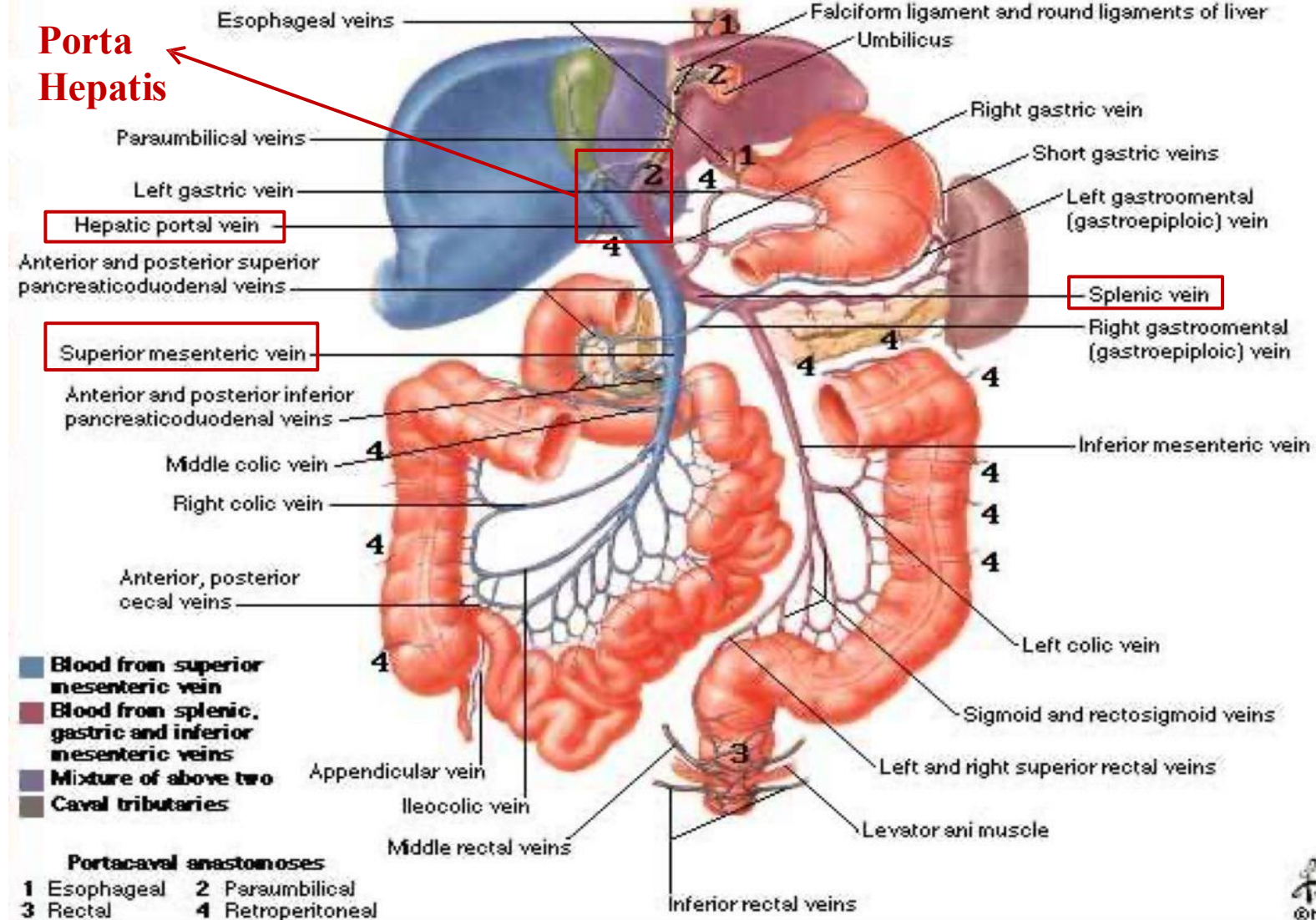
Dr.'s figure



To sum up: The portal vein and the hepatic artery terminate in the liver's blood sinusoids, which supply hepatocytes. Veins then carry the blood away and join up into the three main hepatic veins (right, left, and central), which drain into the inferior vena cava.

Hepatic Portal Vein Tributaries

Portocaval Anastomoses



Dr.'s figure

12- Liver secretory ducts

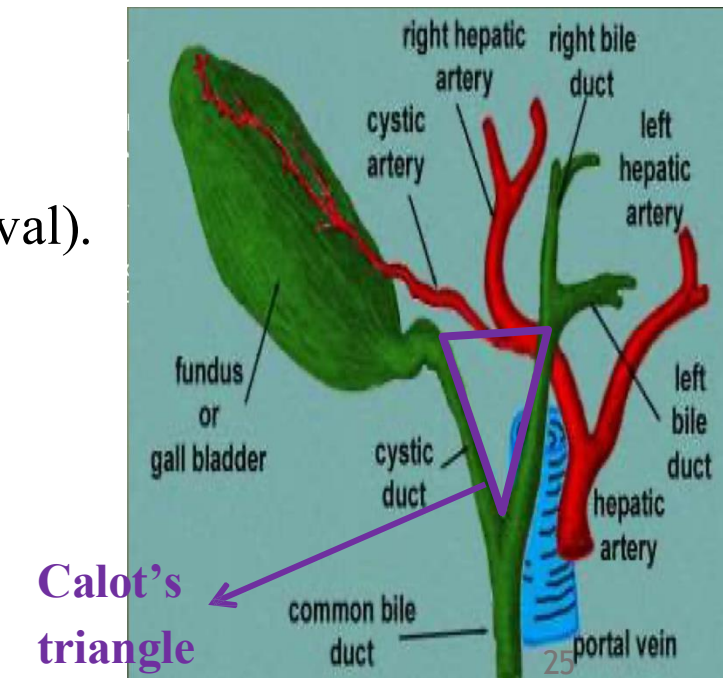
■ Liver synthesizes bile.

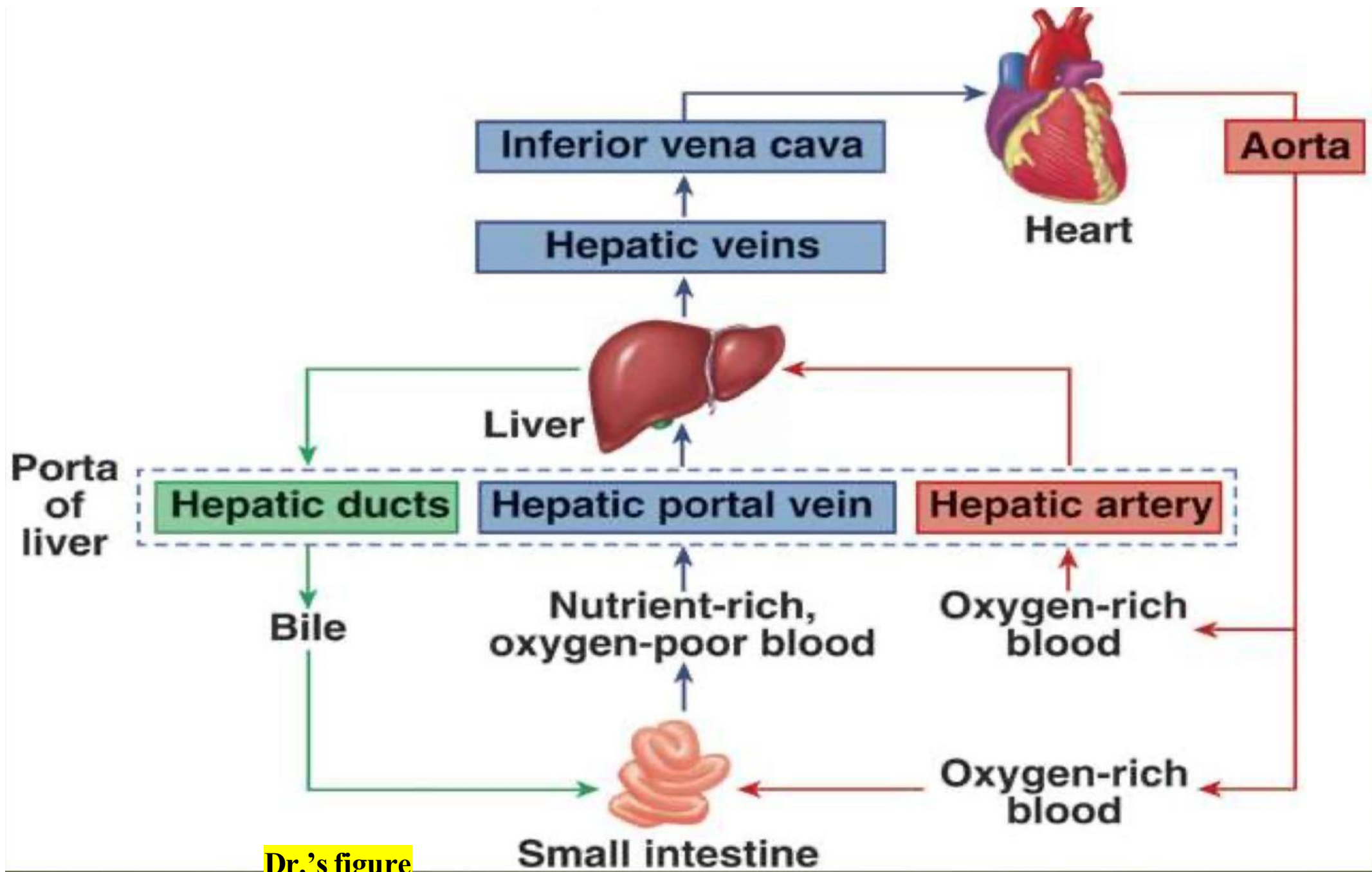
- Bile is transported via:
 - The **right** hepatic duct drains bile from the right lobe, while the **left** hepatic duct carries bile from the left, caudate, and quadrate lobes.
 - **Right and left hepatic ducts** → form the **common hepatic duct**.
 - Common hepatic duct + **cystic duct** → form the **common bile duct**.
- Common bile duct passes:
 - **Behind the first part of the duodenum and head of the pancreas.**
 - Opens into the **second part of the duodenum.**

Boundaries of calots triangle

■ Calot's Triangle:

- 😊 **Surgical landmark** used in 😞 **cholecystectomy** (gallbladder removal).
- **Surgical notes:**
 - Cystic duct is **ligated in two places** and cut in between.
 - Then **cystic artery and vein** are ligated and cut.
- **Anatomical variation:**
 - In **80%** of people: vessels lie **posterior** to the duct.
 - In **20%**: vessels lie **anterior** to the duct.





Dr.'s figure

13- Lymphatic Drainage of the Liver

Main Pathway (Majority of Liver)

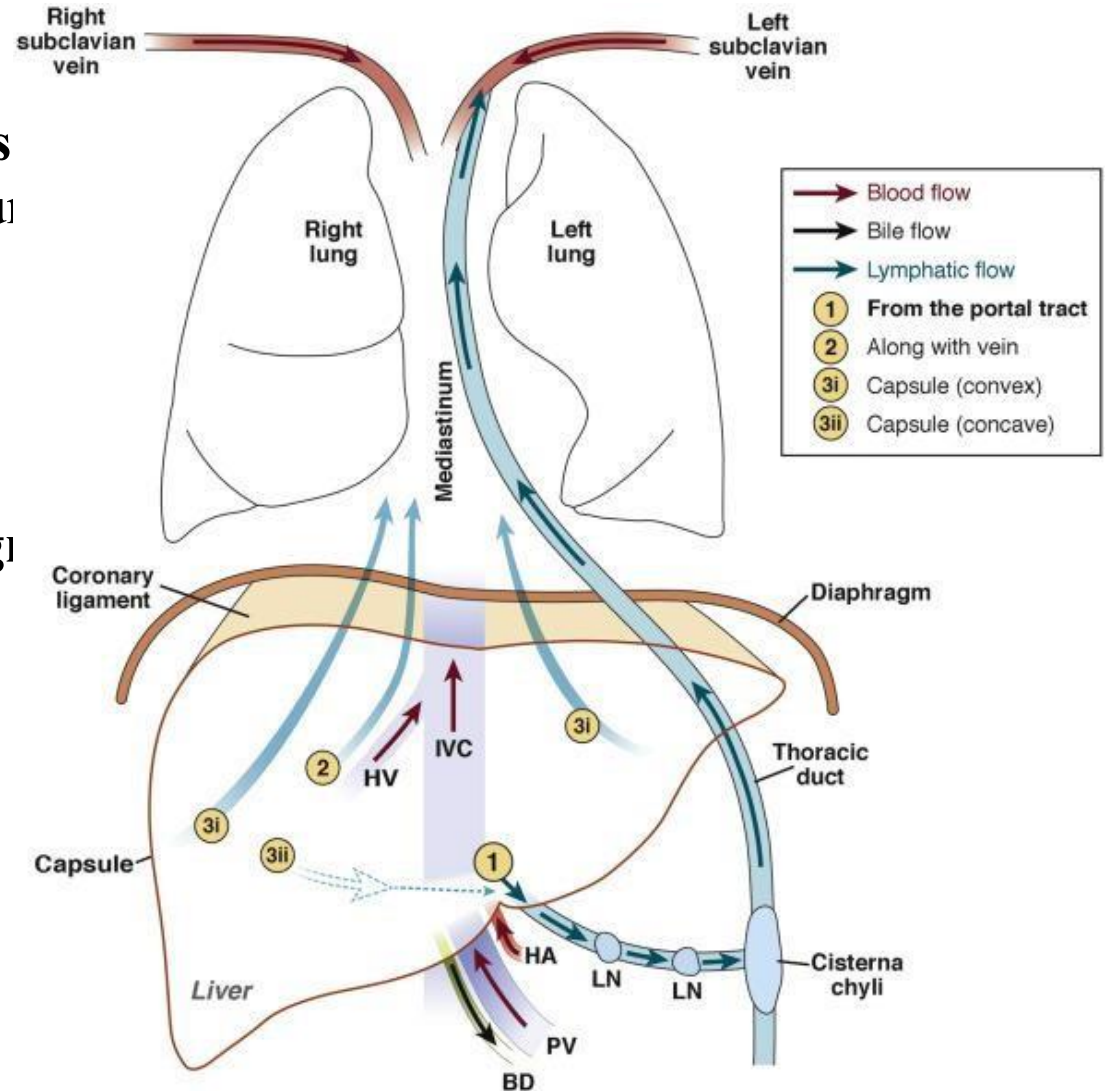
- Drains via the **porta hepatis** to the **hepatic lymph nodes** then to the **celiac lymph nodes** surrounding the celiac trunk and then to the **cisterna chyli** (at the opening of the abdominal aorta) and the **thoracic duct**.

Alternate Pathway (Bare Area of Liver)

- Drains via a few vessels that **pass through the diaphragm** and then to the **right lymphatic duct**

Nerve supply

- Sympathetic → hepatic plexus >>> celiac plexuses → thoracic ganglion chain T1- T12
- Parasympathetic → vagous nerve(anterior part)
- Sympathetic and parasympathetic nerves form the celiac plexus.



14- (ERCP) Procedure

- ☺ **Endoscopic Retrograde Cholangiopancreatography Procedure**

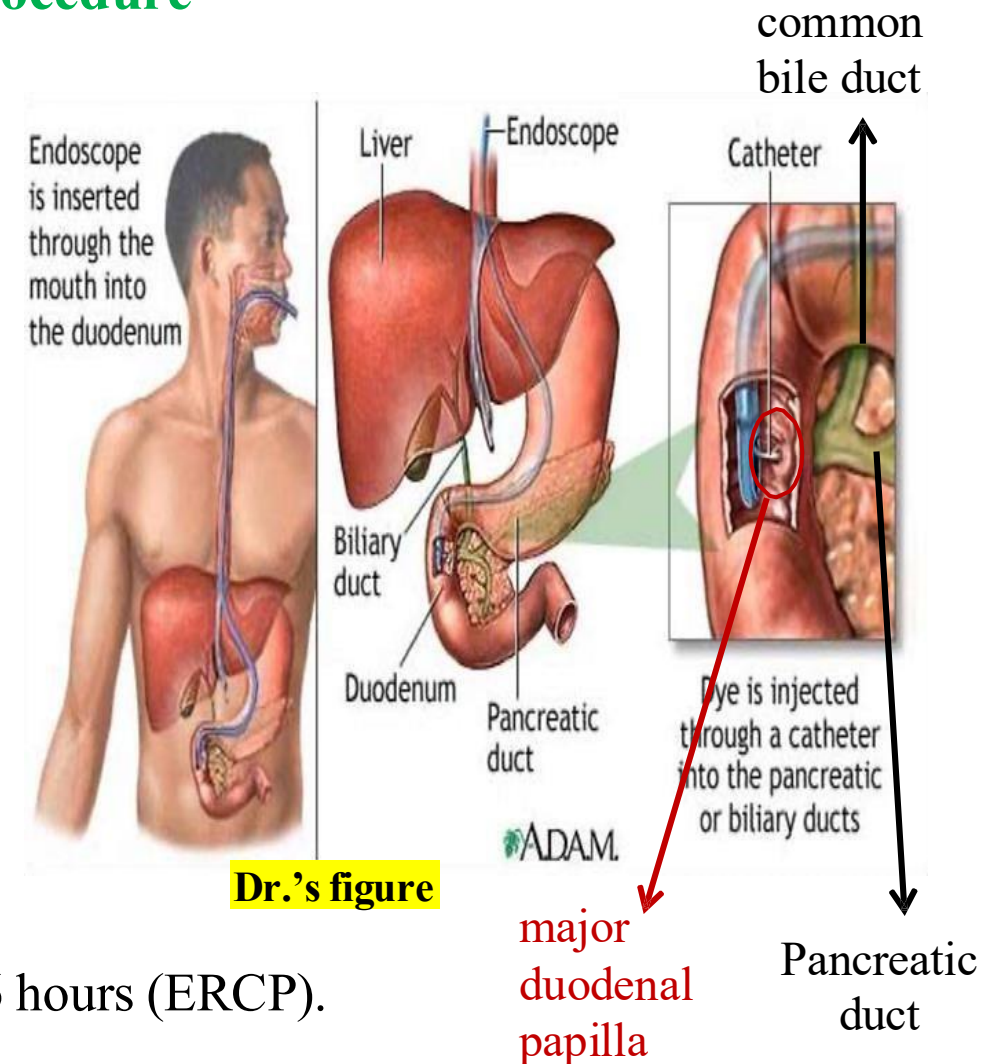
- An endoscope is inserted through the oral cavity, passed through the esophagus and stomach into the duodenum.
- Access is gained via the major duodenal papilla → Sphincter of Oddi → into the common bile duct and Pancreatic duct.

- **Clinical Use**

- Used to remove stones or obstructions in the bile ducts.
- Especially beneficial in ☹ **obstructive jaundice** *(a condition where bile flow is blocked from the liver to the small intestine)*

- **Advantages**

- Minimally invasive.
- Reduces recovery time from 10 days (open heart surgery) to 6 hours (ERCP).
- Now standard hospital practice for appropriate cases.



15- Liver Cirrhosis and Fibrosis

➤ Relate to pathology

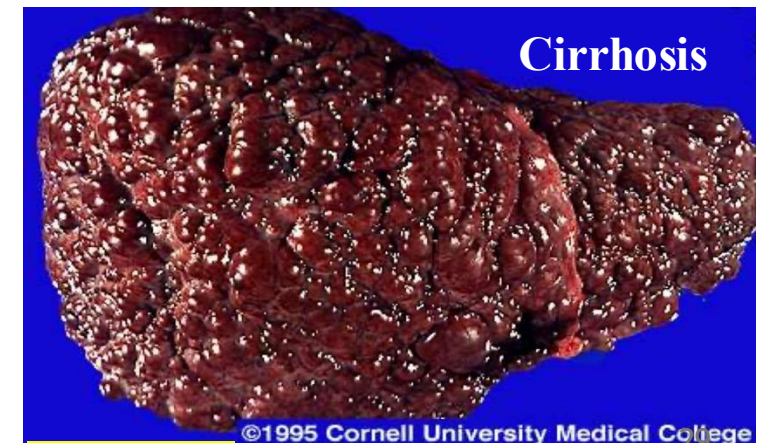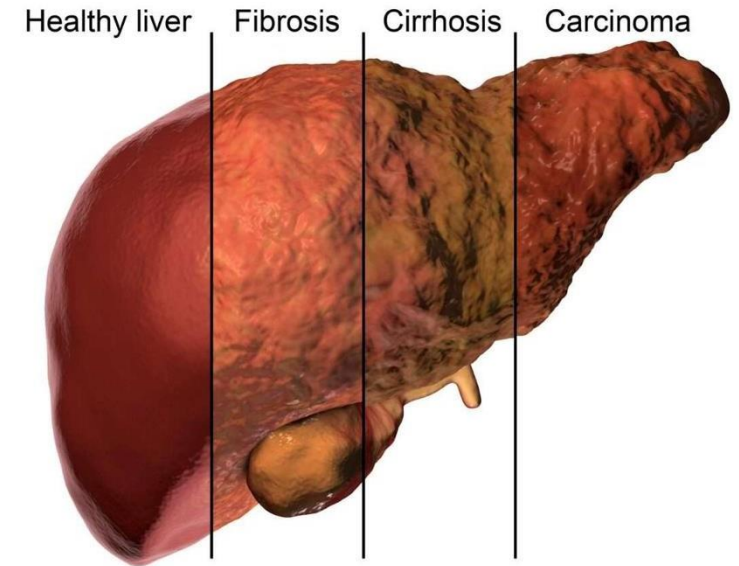
- **Liver diseases spread rapidly** throughout the organ due to its interconnected structure.

1. **Liver Fibrosis (تليف)**

- *Accumulation of scar tissue in the liver due to chronic inflammation or injury.*
- **Cause:**
 - **Schistosomiasis (bilharzia) is a common cause in Egypt.**

2. **Liver Cirrhosis (تشمع)**

- *The end-stage of chronic liver fibrosis.*
- **Cause:**
 - Primarily due to **excessive alcohol consumption** (common in addicts).
- **Liver transplant** may be needed in advanced cirrhosis.




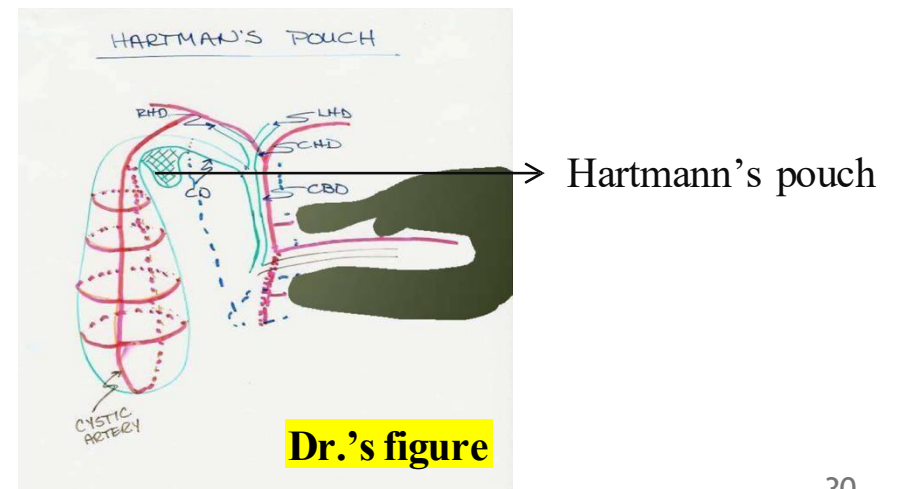
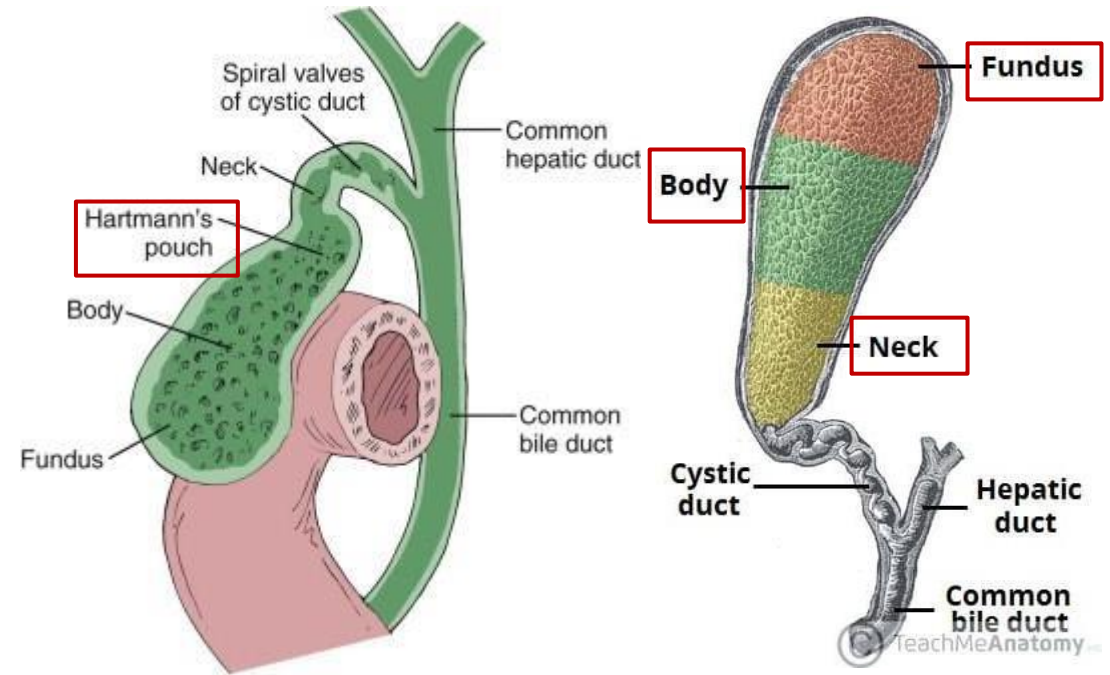
16- The Gallbladder

- **The gallbladder consists of:**

- **Fundus**
- **Body**
- **Neck**
- **Hartmann's pouch**

- **Hartmann's pouch:**

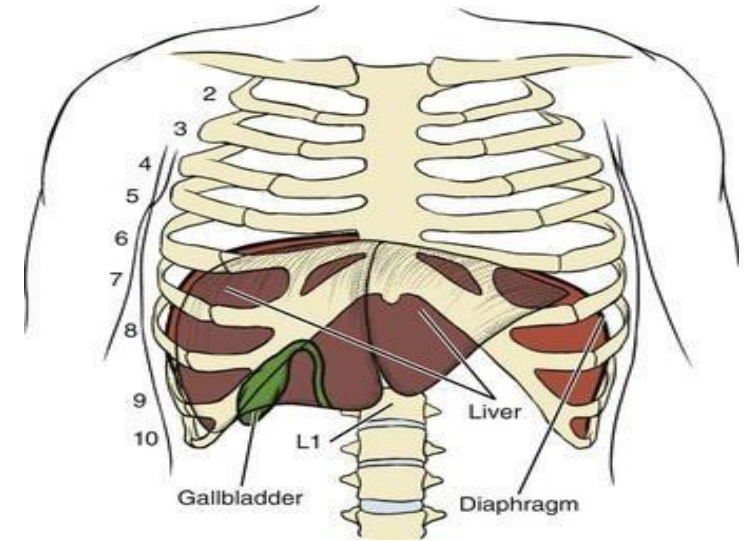
- A small outpouching or depression at the junction of the neck of the gallbladder and the cystic duct.
- Resembles a cupped hand. 
- This area promotes **stasis of bile**, leading to the formation of a ☹️ **single gallstone**, which may obstruct the cystic duct. Often requires surgical removal of the gallbladder 😊 (**cholecystectomy**).



16- The Gallbladder

Anatomical Position

- Located on the **visceral surface of the liver**, where it forms a distinct **gallbladder impression**.
- The **fundus** lies at the level of the **9th right costal cartilage**.
- **Gallbladder Capacity**: Approximately **40–60 cm³**



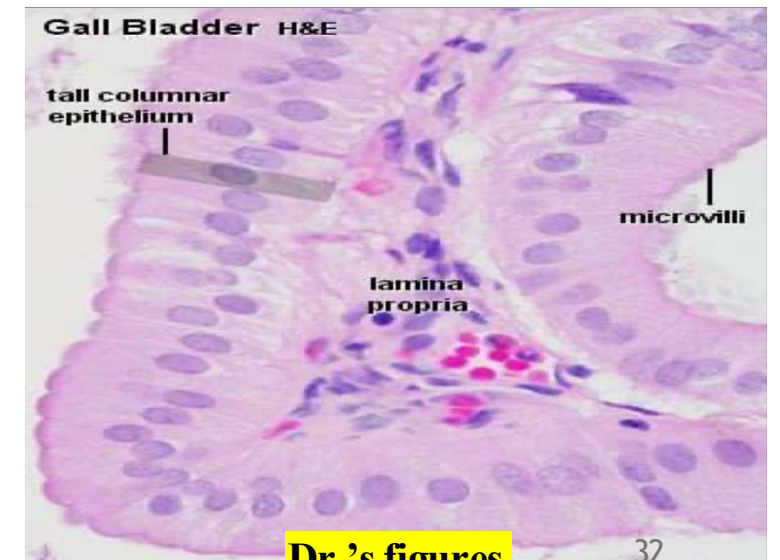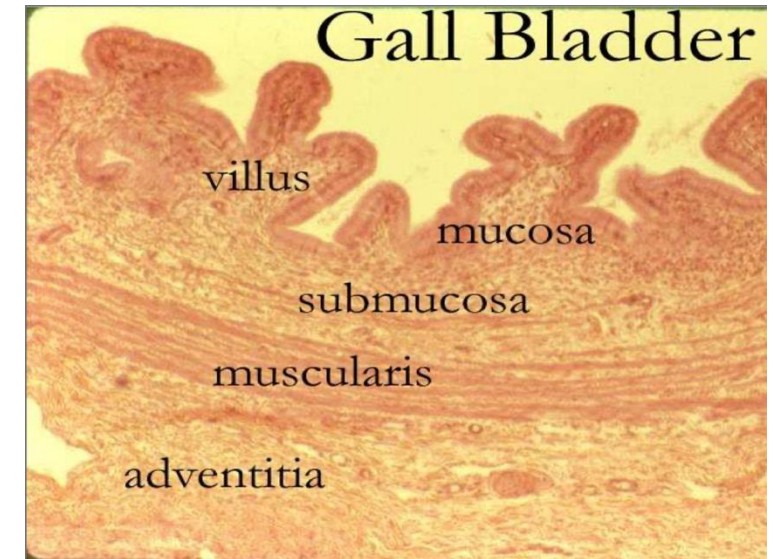
Function

- The primary function of the gallbladder is to **concentrate bile** by absorbing water, increasing its concentration by up to **20 times**. This occurs because the **sphincter of Oddi** remains **contracted**, diverting bile from the liver into the gallbladder for storage.
- Upon the entry of **fatty food into the duodenum**, the hormone **cholecystikin (CCK)** is released, triggering **gallbladder contraction** and **relaxation of the sphincter of Oddi**, allowing the release of concentrated bile into the duodenum. This mechanism efficiently reduces the volume of bile released from **about 20 liters from the liver** to **just 1–2 ml from the gallbladder**.

17- The Gallbladder Histology

➤ Relate to Histology:

- **Mucosa:**
 - Simple columnar epithelium, no goblet cells.
 - Characterized by numerous mucosal folds.
- **Lamina propria:**
 - Contains few glands (limited need for secretion).
- **Submucosa:**
 - Poorly defined.
- **Muscularis externa:**
 - Irregular layers: oblique, circular, and longitudinal muscle fibers. instead of having the usual inner circular and outer longitudinal layers.
- **External covering:**
 - Surface in contact with the liver: covered by adventitia.
 - Anterior/free surface: covered by serosa.



18- The Gallbladder Blood Supply

- **Cystic Duct:**

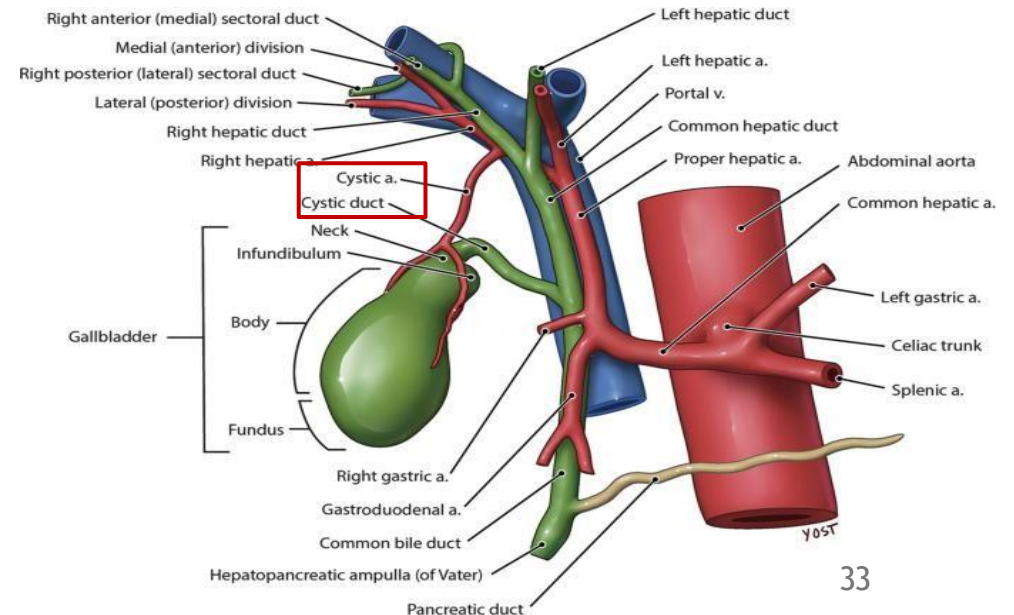
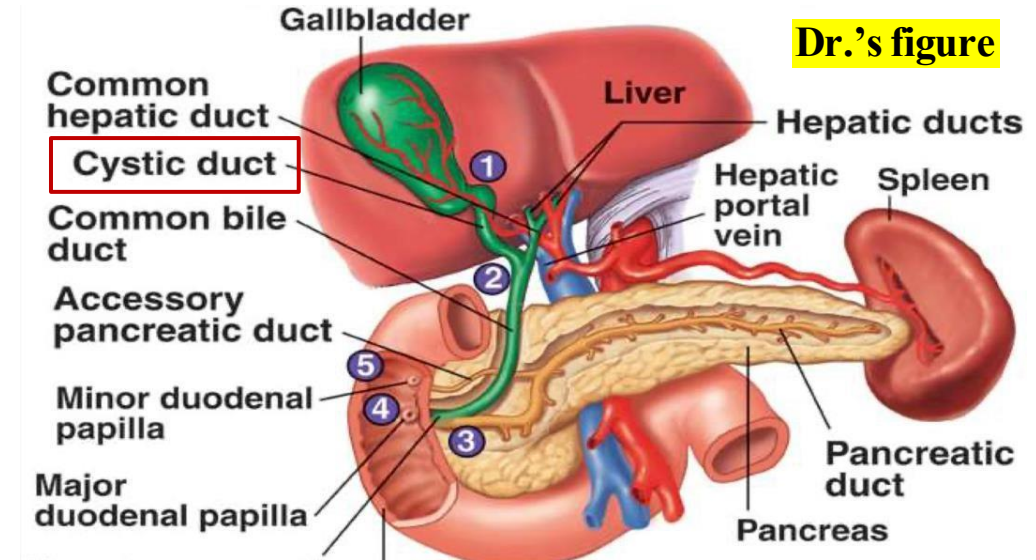
- Approximately 4 cm long.
- Joins the **common hepatic duct** to form the **common bile duct**, which opens into the **second part of the duodenum**.

- **Arterial Supply:**

- The **gallbladder** is supplied by the **cystic artery**.
- The **cystic artery** arises from the **right hepatic artery** which is a branch of the **common hepatic artery**. The **common hepatic artery** is one of the **three branches of the celiac trunk**.

- **Venous Drainage:**

- The **cystic vein** drains blood from the gallbladder.
- It empties into the **right branch of the portal vein**.

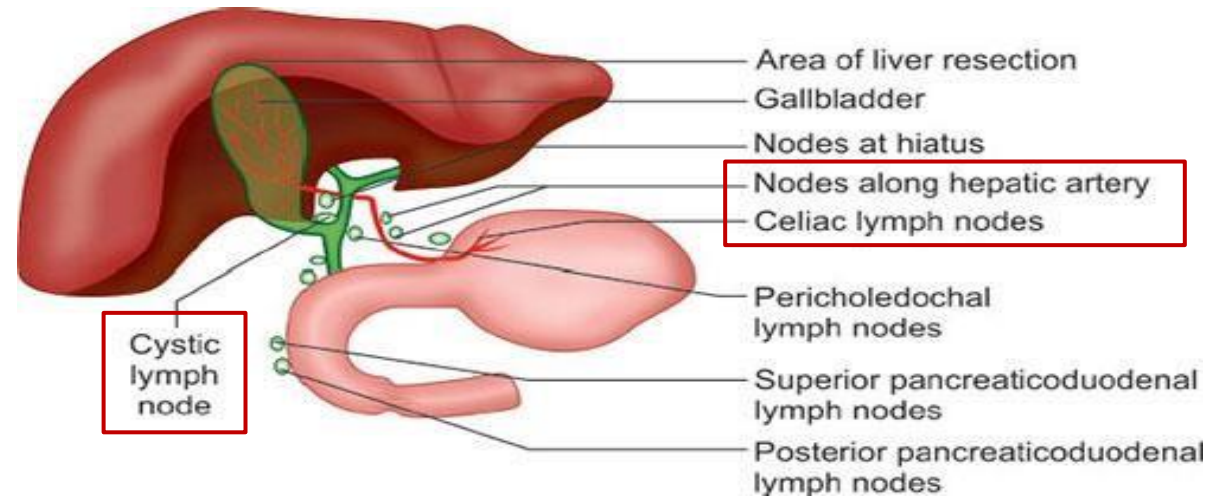


19- The Gallbladder lymphatics & innervation

Lymphatic Drainage:

- Lymph from the gallbladder drains into:

Cystic lymph nodes → Hepatic lymph nodes → Celiac lymph nodes → finally into the cisterna chyli



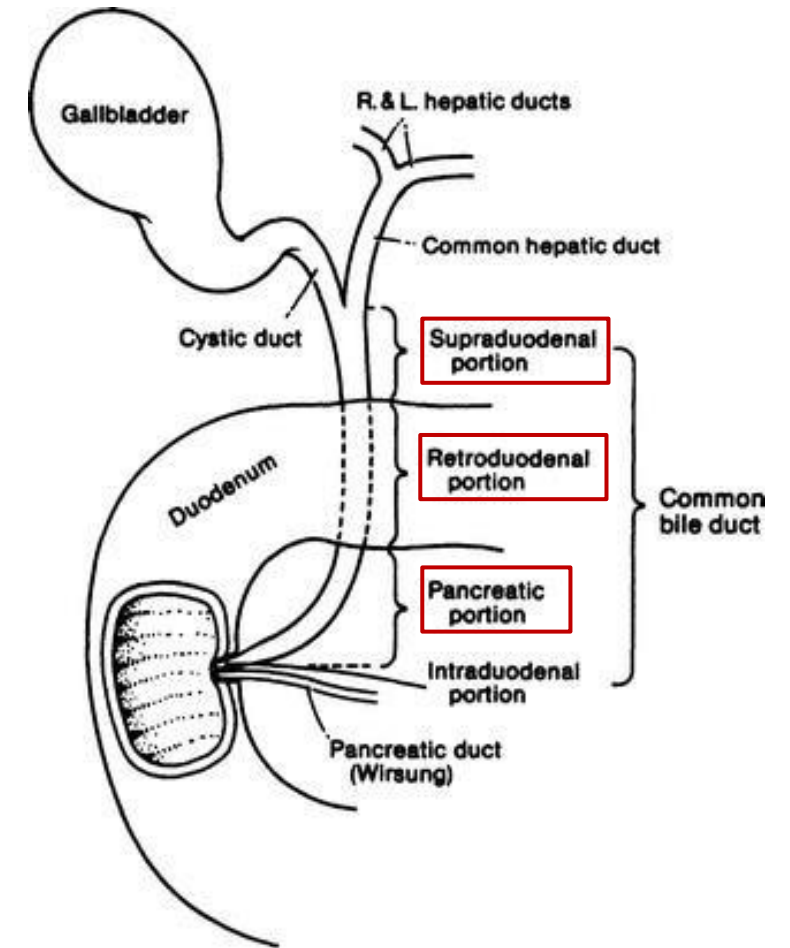
Nerve Supply:

- **Sympathetic and parasympathetic innervation.**
- **Hormonal regulation by cholecystikinin (CCK):**
 - Released from the **duodenum** in response to fatty chyme.
 - Causes **gallbladder contraction** and **sphincter of Oddi relaxation**

20- The Common bile duct

Common bile duct

- **Length:** ~10 cm (≈3 inches).
- **Divided into 3 parts:**
 - **Supraduodenal part:** lies in the free edge of the lesser omentum.
 - **Retroduodenal part:** located behind the first part of the duodenum.
 - **Retropancreatic part:** passes through the head of the pancreas and opens into the major duodenal papilla.
- **Blood Supply:**
 - **Cystic artery**
 - **Superior pancreaticoduodenal artery**



(Dr. said; read this
by yourself)

21- The Bile

➤ Relate to biochemistry

Composition

- Components: Water, ions, bile acids, cholesterol, phospholipids, bilirubin.

Function

- Acids and salts emulsify fats for absorption across wall of small intestines into lacteal lymph capillaries.
- Excretes waste products from RBC breakdown and other metabolic processing (color of feces from bilirubin in bile).
- Ions buffer chyme from stomach.

Note: Gallstones are primarily composed of cholesterol.

22- The Gallbladder conditions

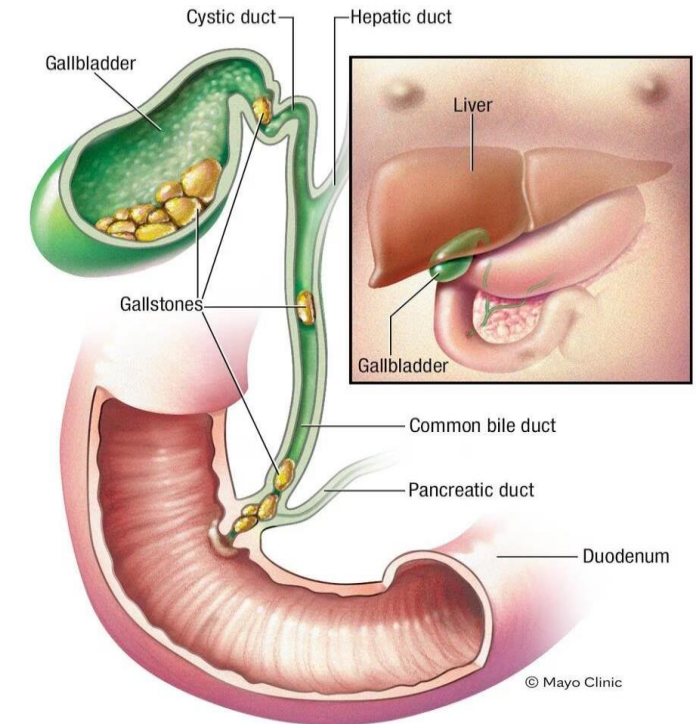
➤ Relate to pathology

Cholelithiasis

- **Gallstones** within the gallbladder.
- Immediate 😊 **cholecystectomy** is advised, as stones may become malignant parts.
- **Complications:**
 - May obstruct the common bile duct, leading to 😞 **obstructive jaundice**.
- **Comparison with Appendix:**
 - Gangrene is rare in the gallbladder (due to dual blood supply: cystic artery + hepatic surface).
 - Gangrene is common in the appendix (single supply from the appendicular artery).

Cholecystitis

- **Inflammation of the gallbladder.**
- Also treated with 😊 **cholecystectomy**.



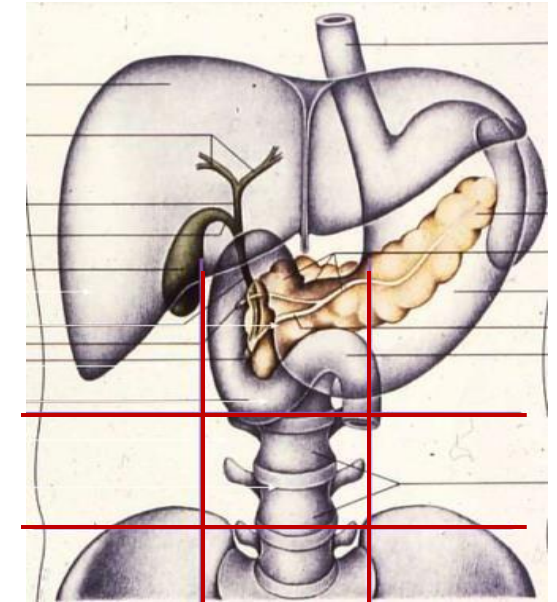
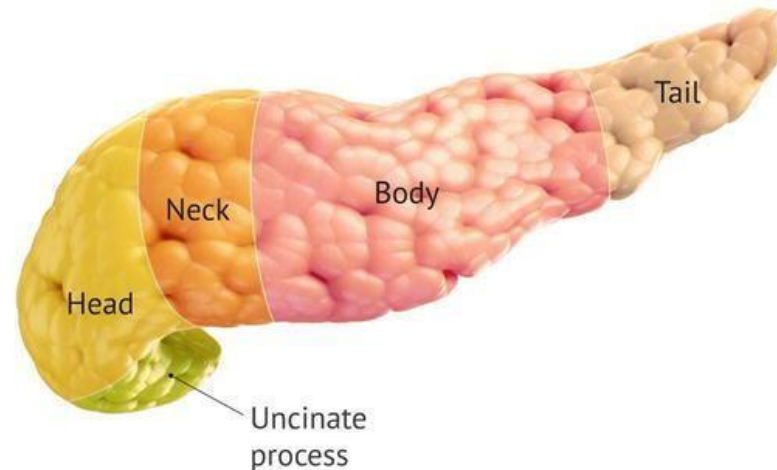
Gangrene of gall bladder rare, as it has double blood supply from cystic artery and direct blood supply from liver

23- The pancreas

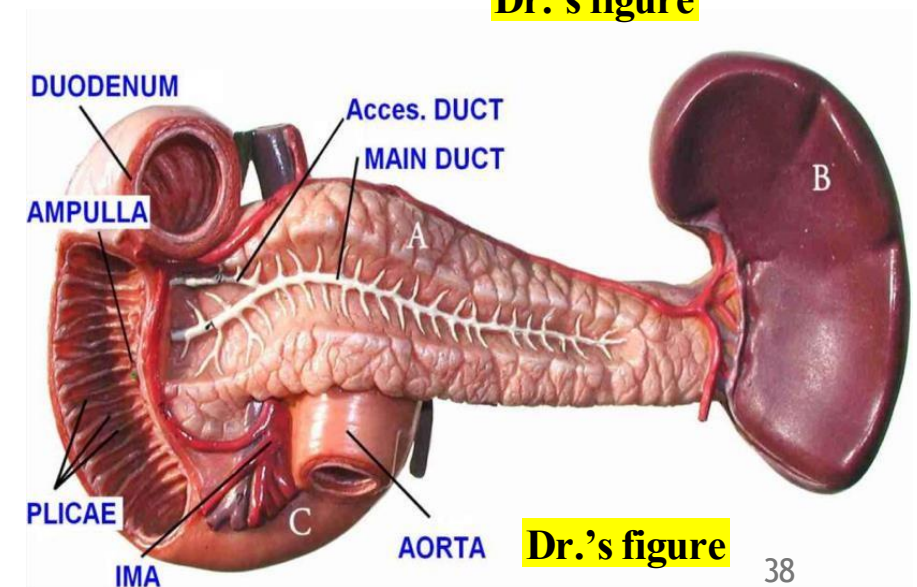
- The pancreas is found in **the epigastric and left hypochondriac**.
- Lies retroperitoneally on the posterior abdominal wall.

Parts of the Pancreas

- **Tail:** touches the **spleen**, forming an impression.
- **Body.** – *to be explained*
- **Neck:** **portal vein forms** behind it.
- **Head:** sits in the **duodenal concavity**, Gives rise to the **uncinate process**, which extends medially and posteriorly.



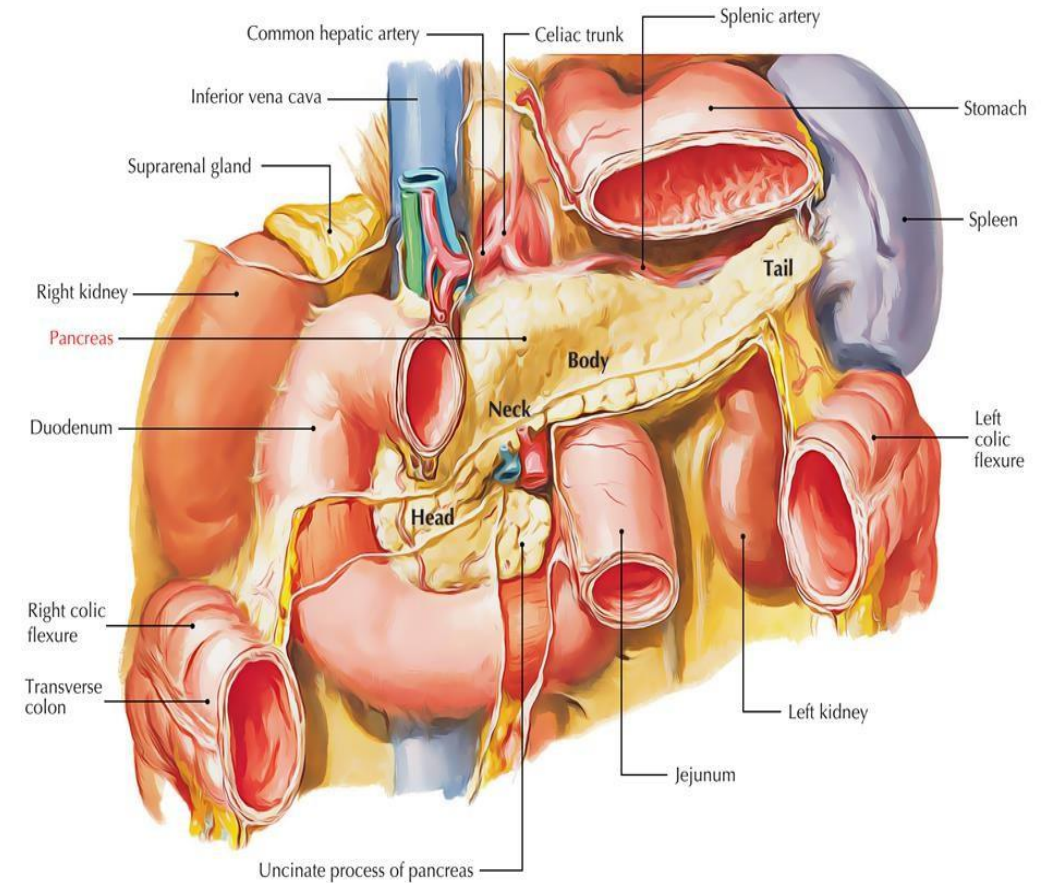
Dr.'s figure



Dr.'s figure

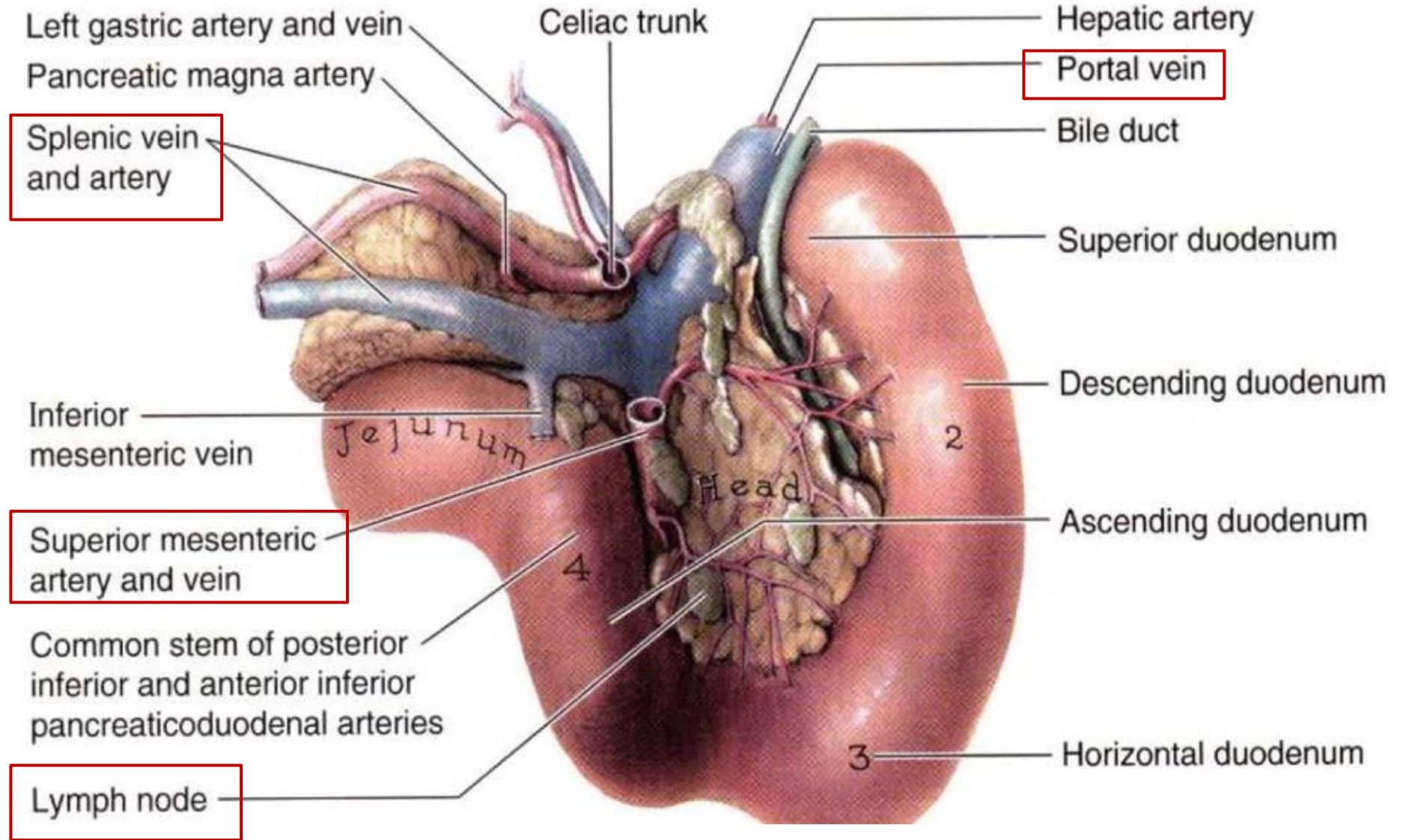
24- The pancreas relations

Aspect	Structures Related
Anterior	<ul style="list-style-type: none"> • Stomach • Lesser sac • Transverse mesocolon • Transverse colon
Posterior	<ul style="list-style-type: none"> • Inferior vena cava (IVC) • Abdominal aorta • Left kidney • Left suprarenal gland



*The **splenic vein** (running along the posterior surface of the pancreas) joins the **superior mesenteric vein** behind the **neck of the pancreas** to form the **portal vein**.

***Pancreatic lymph nodes** are located on the **posterior surface** of the pancreas and drain lymph from the pancreatic tissue.



Dr.'s figure: posterior view of the pancreas

25- The pancreas Histology

➤ Relate to Histology:

The **pancreas** is a **mixed gland**:

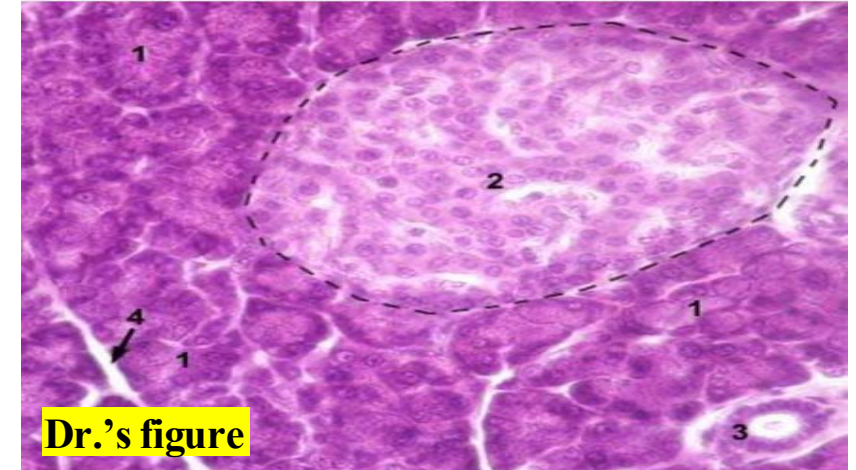
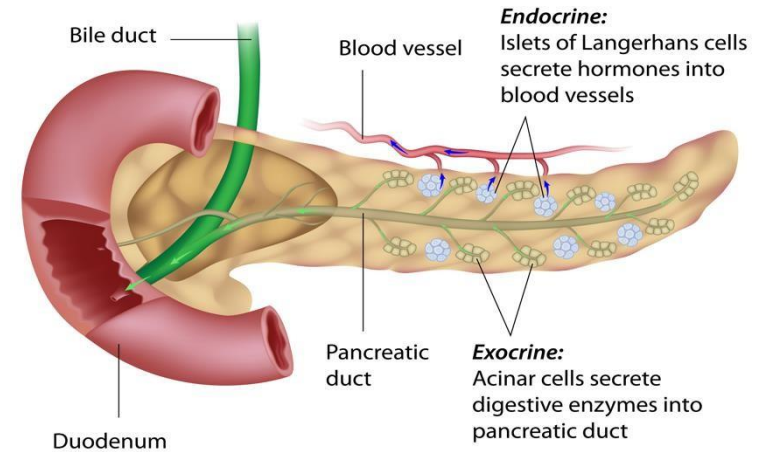
- **Exocrine:**

- consists of **pancreatic acini**, which secrete the **enzymes** of the pancreas. It has its own duct: the **pancreatic duct**.

- **Endocrine:**

- consists of the **islets of Langerhans**, containing **α cells** and **β cells**. **α cells** secrete **glucagon** which increase glucose levels in blood.
 β cells secrete **insulin**, and their failure to do so causes ☹ **diabetes mellitus**.

Also,

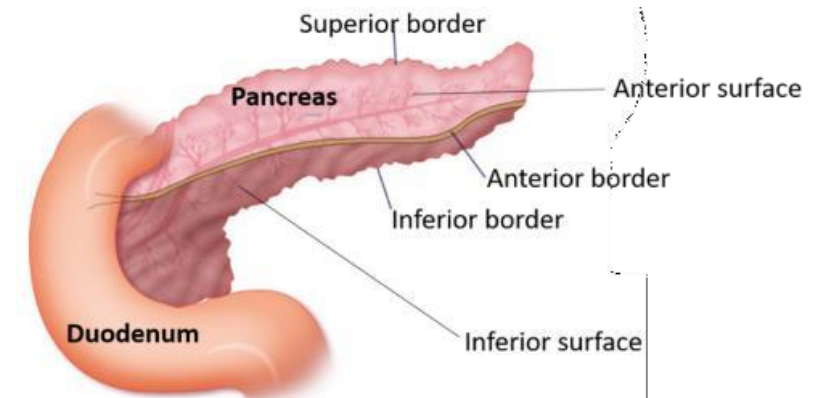


1. exocrine part (pancreatic acini)
2. endocrine part (islets of Langerhans)

26- Body of the pancreas

Body of the Pancreas

- **Direction:** Runs **upward and to the left** across the midline
- **Shape:** **Triangular** in cross section
- **Surfaces:** Anterior, Posterior, Inferior
- **Borders:** Superior, Anterior, Inferior



Structure	Relation
Posterior surface	Lies on the posterior abdominal wall ; retroperitoneal
Upper border	Related to the celiac trunk and splenic artery
Anterior border	Attached to the transverse mesocolon

*These are what the doctor mentioned, but he emphasized that it's important to know the rest (you will find them in the next slides).

Explanatory video: click [here](#) (credits to Joud Alzubaidi <3)

26- Body of the pancreas

Surface	Details / Relations
Anterior Surface	<ul style="list-style-type: none"> - Covered by peritoneum of the posterior wall of the lesser sac - Tubercle of omentum (tuber omentale) at the junction with the neck
Posterior Surface	<ul style="list-style-type: none"> - Devoid of peritoneum <ul style="list-style-type: none"> • Aorta • Splenic vein • Left kidney and vessels • Left suprarenal gland • Origin of superior mesenteric artery • Crura of diaphragm
Inferior Surface	<ul style="list-style-type: none"> - Narrow on right, broader on left - Covered by peritoneum of greater omentum - Lies on: <ul style="list-style-type: none"> ○ Duodenojejunal flexure ○ Coils of jejunum ○ Left extremity rests on left colic flexure

26- Body of the pancreas

Borders	Details / Relations
Superior border	<ul style="list-style-type: none"> - Blunt & flat (right) - narrow & sharp (left near tail) - Starts at tuber omentale - Related to: <ul style="list-style-type: none"> • Celiac artery • Hepatic artery • Splenic artery (runs in a groove towards left)
Anterior border	<ul style="list-style-type: none"> - Separates anterior and inferior surfaces - Transverse mesocolon attaches here (its two layers diverge: one upward, one backward)
Inferior border	<ul style="list-style-type: none"> - Separates posterior and inferior surfaces - Superior mesenteric vessels emerge beneath its right end

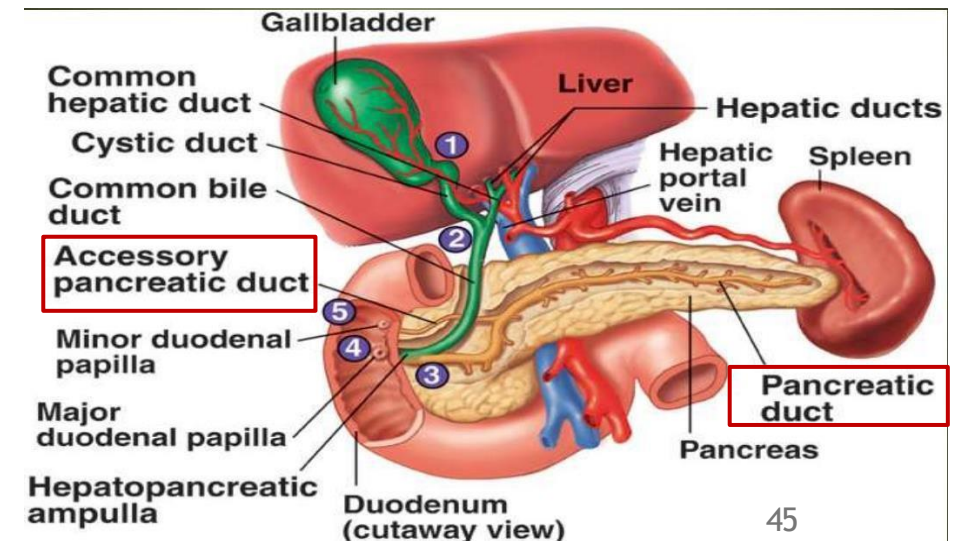
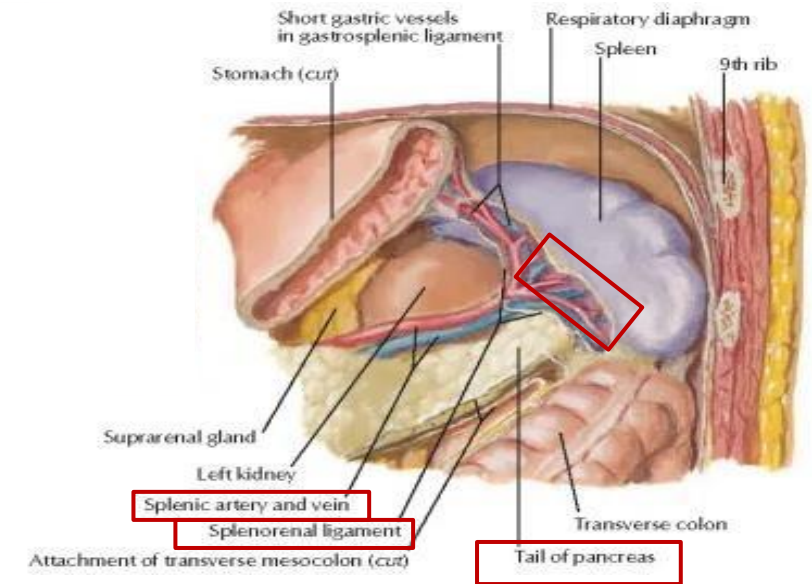
27- Other parts of pancreas

Tail of the Pancreas

- Forms an **impression on the spleen**.
- Passes **forward in the lienorenal (splenorenal) ligament**.
- Accompanied by the **splenic vessels**.

Pancreatic Ducts:

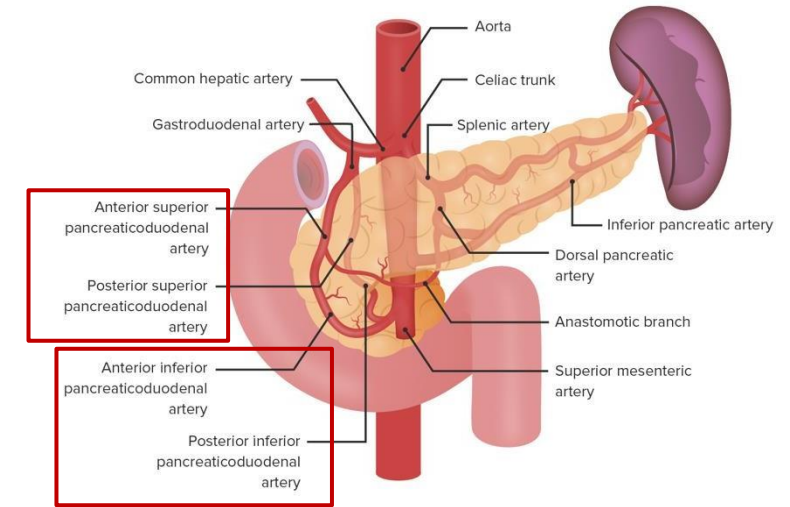
- **Main pancreatic duct:**
 - Opens into the **second part of the duodenum**.
- **Accessory pancreatic duct:**
 - Opens about **1 inch above** the main duct opening.



28- Pancreas Supply

Blood Supply of the Pancreas

- Similar to the duodenum, the pancreas receives its blood supply from the **superior and inferior pancreaticoduodenal arteries**.

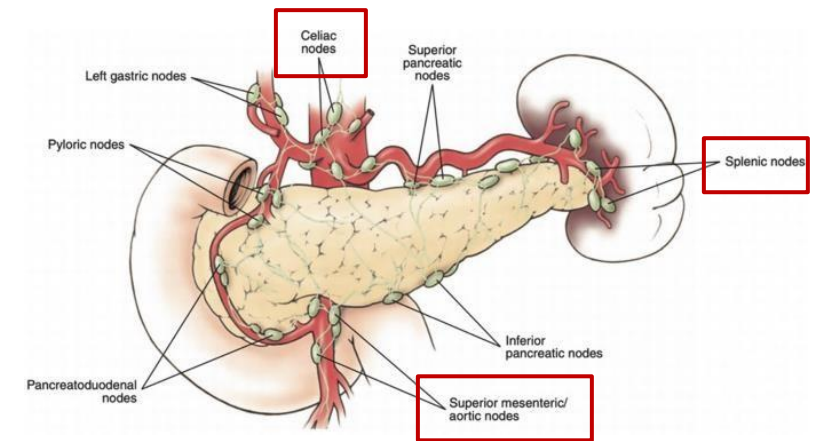


Venous drainage

The corresponding veins drain into the portal venous system: the inferior veins drain into the superior mesenteric vein, while the superior veins drain into the portal veins

Lymphatic Drainage of the Pancreas

- Lymph from the pancreas drains first into the **splenic lymph nodes**, which then drain into the **superior mesenteric** and **celiac lymph nodes**.



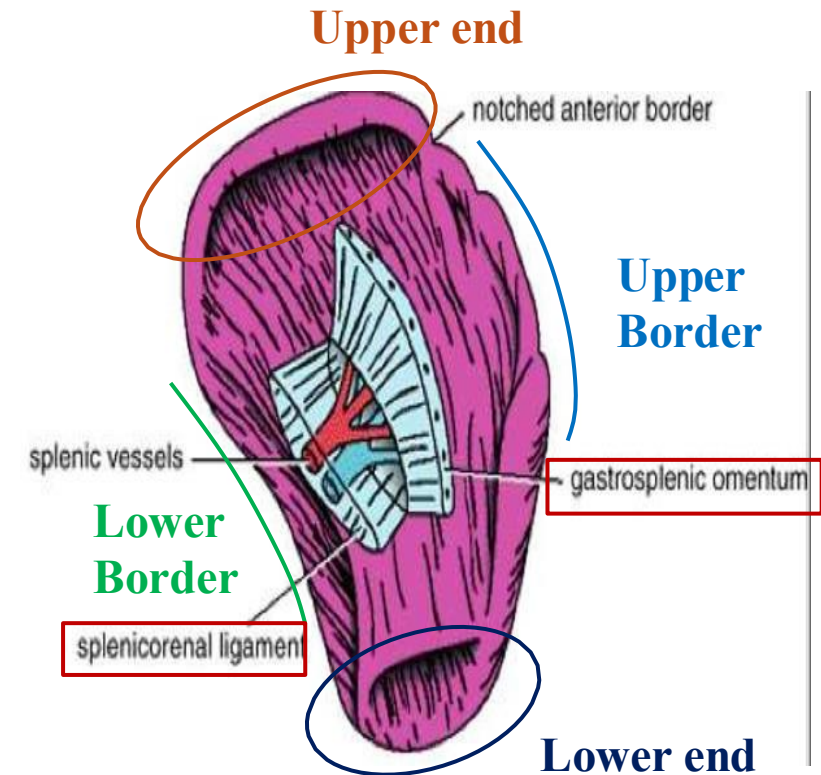
Clinical Notes

- **Cancer of the head of the pancreas** can cause ☹ **obstructive jaundice**.
- **Cancer of the body of the pancreas** creates pressure on the inferior vena

29- The Spleen

- The **spleen** is a **lymphatic organ** and a **blood reservoir**.

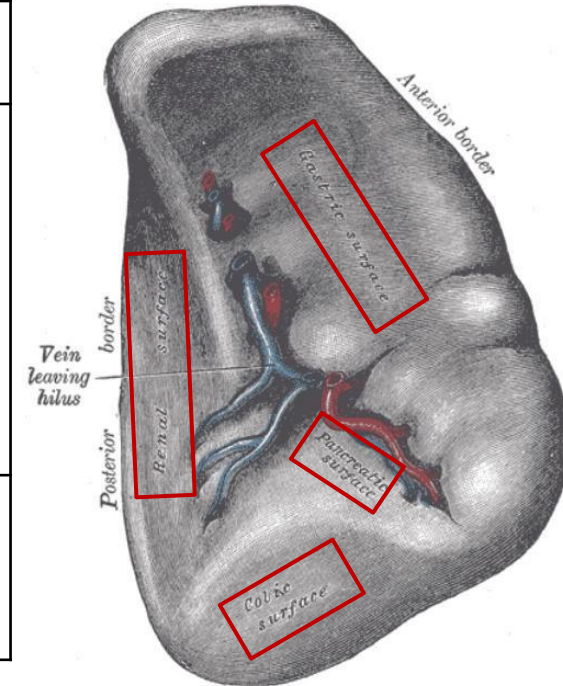
Feature	Description
Surfaces	2 (Visceral and Costal)
Borders	2 (Upper and Lower)
Ends	2 (Upper and Lower)
Ligaments	2 (Gastrosplenic ligament and Splenorenal (Lienorenal) ligament)
Dimensions	<ul style="list-style-type: none"> - 1 inch thick - 3 inches broad - 5 inches long
Weight	Approximately 7 ounces



29- The Spleen

Surfaces

Surface	Relations
Visceral Surface	<ul style="list-style-type: none"> • Stomach • Left kidney • Left colic (splenic) flexure • Tail of the pancreas - Shows impressions for each related structure
Costal Surface	<ul style="list-style-type: none"> • Lies against ribs 9, 10, and 11 - ☹️ Fracture of these ribs may rupture the spleen

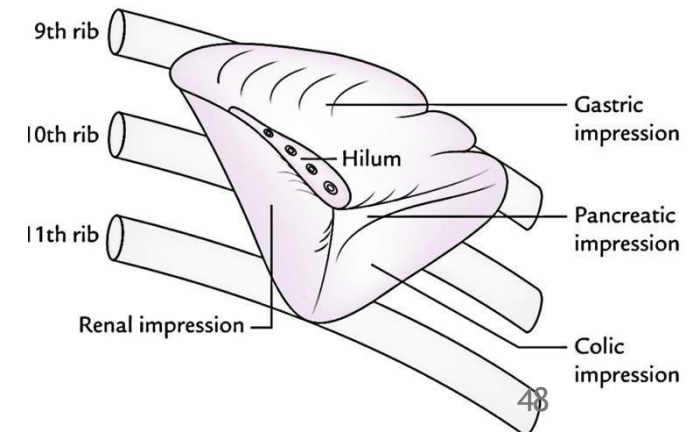


Borders

- **Upper Border:** Sharp with **notches**.
- **Lower Border:** Rounded.

Ends

- **Upper end:** ~4 cm from the **posterior midline**.
- **Lower end:** At the level of the **midaxillary line**.



30- The Spleen supply

Peritoneal Covering & Ligaments

- Completely covered by peritoneum.
- Attached by:
 - Gastrosplenic ligament
 - Splenicorenal (lienorenal) ligament

Blood Supply

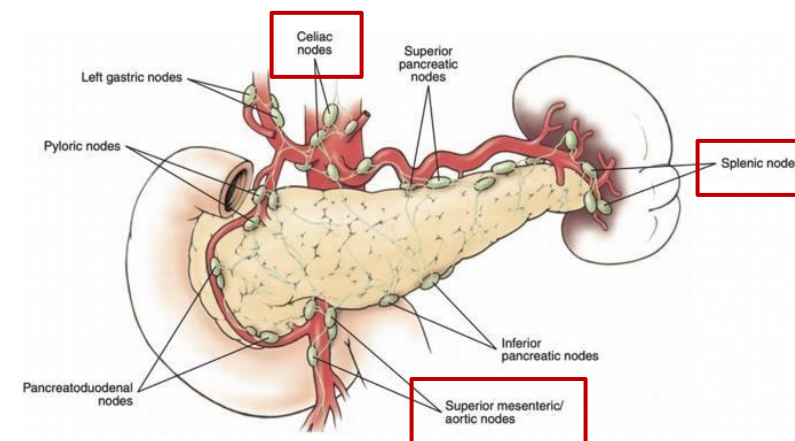
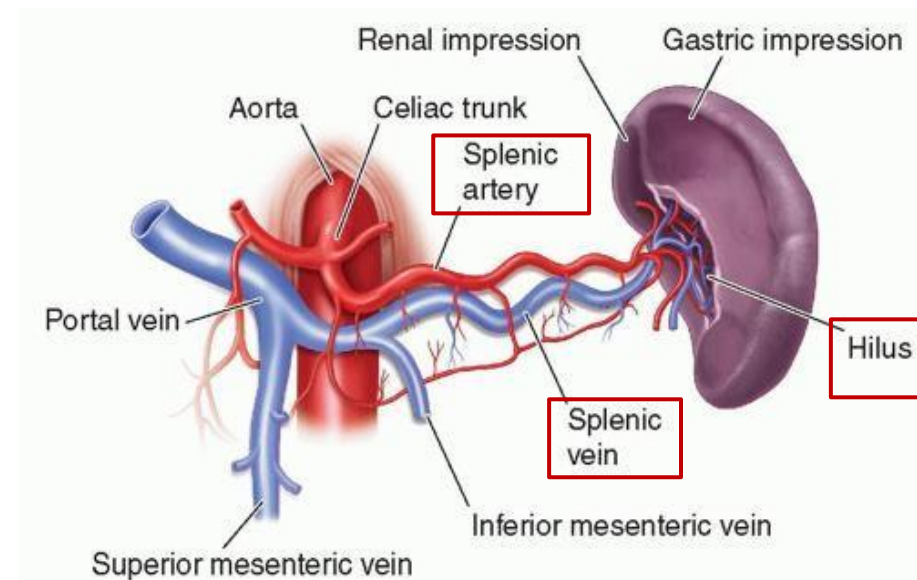
- **Arterial:** Supplied by the **splenic artery**, which divides into **5–6 branches at the hilum**.
- **Venous:** Drained by the **splenic vein** to the **portal vein**.

Lymphatic Drainage

Drains into **splenic lymph nodes** which then drain into the **superior mesenteric** and **celiac lymph nodes**.

Nerve supply

The nerves accompany the splenic artery, mainly as sympathetic fibers running along the artery.



رسالة من الفريق العلمي:

”إن أشد ما أخاف على نفسي يوم القيامة أن يُقال لي:
يا أبا الدرداء قد علمت فكيف عملت فيما علمت؟“

- أبو الدرداء (رضي الله عنه)



For any feedback, scan the code or click on it.



Corrections from previous versions:

Versions	Slide # and Place of Error	Before Correction	After Correction
V0 → V1	Slide 3; Last Note	The diaphragm separates the liver superiorly from the right pleura and right lung on the right side, and from the pericardium and heart on the left side.	The diaphragm separates the liver superiorly from the right pleura and right lung on the right side, and from the pericardium and heart centrally and the left lung and pleura on the left side.
V1 → V2			