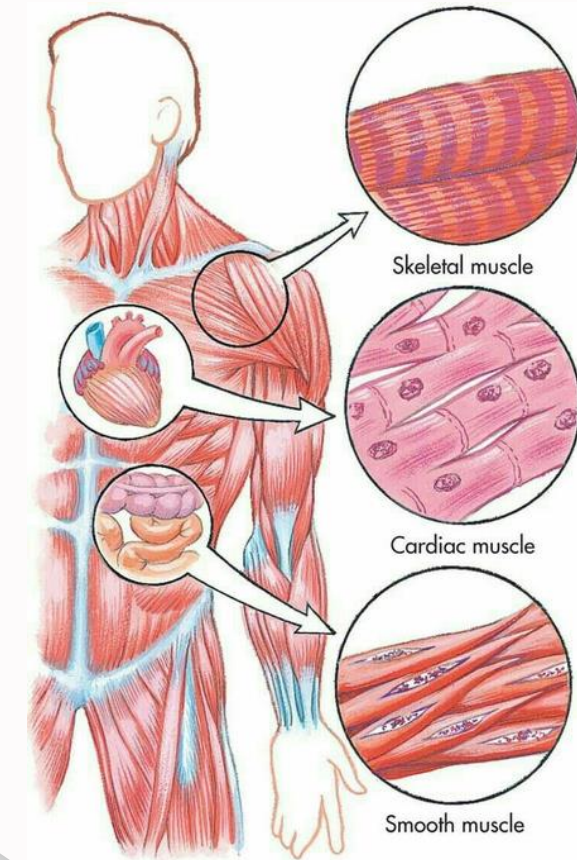


بِسْمِ اللَّهِ الرَّحْمَنِ الرَّحِيمِ



Past Papers



Written by :
Tala Al-ali
Tala Othman
Ruqaiya Moqbel
Sereen Samara
Rasha Alhamraa
Bushra Masalha
Anonymous (Doctor 024)

Reviewed by : Lana Alyaseen

اللَّهُمَّ إِنَّا نَسْتُودِعُكَ أَهْلَنَا فِي غَزَاةٍ

يَا رَبِّ آمِنْ رُوعَاتِهِمْ وَاسْتَرْ عَوْرَاتِهِمْ وَنَجِّهِمْ مِنْ

الْخَوْفِ وَالْفَزَعِ وَمِنْ الْجُوعِ وَالْجَزَعِ وَاجْزِهِمْ

عَنْ مَشَقَّةِ الْحَيَاةِ الْفَانِيَةِ بِمَا صَبَرُوا جَنَّةً وَحَرِيرًا

CARTILAGE & BONE TISSUE

بسم الله الرحمن الرحيم
اللهم لا سهل إلا ما جعلته سهلاً، وأنت تجعل الصعب إذا شئت سهلاً، اللهم سهل لي أمري واشرح لي صدري، ووفقني لما تحب وترضى.

Question : which of the given options is true about articular cartilage

- A) Is a fibrocartilage
- B) Is devoid of periosteum
- C) None of the mentioned
- D) Exhibits a high regenerative capacity
- E) All of the mentioned

Question : Elastic cartilage is present in

- A) External ear
- B) External acoustic meatus.
- C) Costal cartilages.
- D) A+E
- E) Epiglottis.

Ans: D

Question : Regarding fibers in cartilage, choose the **INCORRECT** statement

- A) All of the mentioned
- B) None of the mentioned
- C) Collagen fibers stain well with H&E stain
- D) Collagen type 1 is abundant in fibrocartilage
- E) Collagen type 2 is abundant in hyaline cartilage

Question : How does articular cartilage differ from most other hyaline cartilage?

- A) It undergoes mainly appositional growth.
- B) It contains isogenous groups of chondrocytes.
- C) It lacks a perichondrium.
- D) Its matrix contains aggrecan.
- E) It is derived from embryonic mesenchyme

Question : We can find hyaline cartilage in all of the following except?

- A) Nose
- B) Costal cartilage
- C) Ear
- D) Larynx

Ans: C

Question : Cartilage has a low metabolic activity why?

- A) Tough and compressible
- B) Avascular
- C) Because it contains collagen
- D) Rich in ECM

Ans: B

Question : What is the most abundant proteoglycan in hyaline cartilage?

- A) Aggrecan
- B) Chondronectin
- C) Glycoproteins
- D) Protoglycan

Ans: A

Question : What is common condition causes Osteoarthritis ?

- A) lifestyle
- B) Aging
- C) Over use of the joint
- D) Genes

Ans: B

Question : Which step occurs first in chondrogenesis?

- A) Appositional growth
- B) Conversion of chondroblasts to chondrocytes
- C) Formation of mesenchymal condensations
- D) Interstitial growth
- E) Secretion of collagen-rich and proteoglycan-rich matrix

Ans: C

Question : An osteon is

- A) A cylinder of bone tissue surrounding a central canal
- B) A porous bone composed of trabeculated bone tissue
- C) Involved in the formation of outer circumferential lamellae
- D) The basic structural unit of spongy bone
- E) Composed of woven bone

Ans: A

Question : Hydroxyapatite crystals are made mainly from the combination of ?

- A) Collagen type 1 fibers and carbon molecules
- B) Calcium, phosphate and collagen type 1 fibers
- C) Calcium and phosphate
- D) Chondroitin sulfate and inorganic salts
- E) Glycoproteins and vitamin D

Question : Osteocytes maintain contact with the bloodvessels of the central canal through:

- A) Concentric lamellae
- B) Interstitial lamellae
- C) Canaliculi
- D) Perforating fibers
- E) Periosteum

Question : All of the following statements about bone-cells are correct EXCEPT:

- A) Osteoblasts produce type I collagen
- B) Osteocytes are often grouped in nests inside lacunae as a result of earlier mitoses
- C) Osteoblasts are mononucleate cells
- D) Osteoclasts form the ruffled border that opposes the surface of the bone tissue
- E) Some osteoblasts turn into osteocytes while the new bone is being formed

Question : Which of the following cells is located in Howship's lacuna?

- A) Chondroblast
- B) Osteogenic cell
- C) Osteoblast
- D) Osteocyte
- E) Osteoclast

Question : In epiphyseal plate growth, what happens when the zone of ossification overtakes the zone of resting cartilage?

- A) All of the mentioned
- B) The hyaline cartilage of the plate is replaced by bone
- C) Longitudinal growth of the bone terminates (at least at the end)
- D) The epiphyseal plate becomes the epiphyseal line
- E) The diaphysis and epiphysis portions of the bone fuse together to form a single adult bone

Question : Formation and growth of long bones, choose the **WRONG** statement:

- A) Hyaline cartilage remains on the articular surfaces and persists through adult life
- B) The first site of ossification in long bones occurs in the middle of diaphyseal
- C) Growth in diameter is due to osteoblastic activity in periosteum and osteoclastic activity in endosteum
- D) Bone collar facilitates the diffusion of oxygen and nutrients to the underlying cartilage
- E) The cartilage between the primary and secondary ossification centers is called the epiphyseal plate

Question : Regarding Endosteum, choose the Wrong statement:

- A) Covers trabeculae of spongy bone
- B) Is composed of a single layer of cells
- C) Is attached to bone trabeculae by Sharpey's fibers
- D) Is involved in bone growth in width
- E) Lines the internal cavity of the bone

Question : The CT framework used for the formation of bones by intramembranous ossification

- A) Cartilage
- B) Collagen Fibers
- C) Calcified cartilage matrix
- D) a & c can be correct

Question : Which of the following events occurs firstly during Endochondral bone formation?

- A) Appearance of primary bone at the epiphyseal ends
- B) Invasion by a vascular bud into the forming large cavity
- C) Formation of a bony collar around the diaphysis.
- D) Calcification of the cartilage matrix.

Question : All the followings can be found in the ossification zone EXCEPT:

- A) Chondrocyte within lacunae
- B) Osteocyte within lacunae
- C) Primary bone
- D) Calcified matrix of the cartilage
- E) Osteoblasts

Question : Several layers of cells reside within epiphyseal plates of developing long bones. Which statement best describes the ossification zone?

- A) Cells enlarging and causing the cartilaginous matrix to become calcified
- B) Resting cells
- C) Cells undergoing mitosis and forming long columns of isogenous groups
- D) None of the mentioned
- E) Osteoblasts adhering to the remnants of calcified cartilage matrix and producing woven bone

Ans: E

Question : Which of the following are found in compact bone and cancellous bone?

- A) Lacunae
- B) Circumstantial lamellae
- C) Haversian canals
- D) Trabeculae
- E) Volkmann's canals

Question : All of the followings apply to both endochondral ossification and intramembranous ossification EXCEPT:

- A) They start prenatally
- B) The type of collagen synthesized
- C) The bone matrix is formed by osteoblasts
- D) The formation of bone collar
- E) The first bone produced is immature bone

Question : Woven bone, choose the WRONG statement:

- A) Its collagen fibers are not organized into lamellae
- B) It has a lower mineral content compared to secondary bone
- C) It is the first bone tissue to appear in embryonic development
- D) It is not degraded by osteoclasts
- E) It is formed during repair of fracture sites

Question : Intramembranous ossification, choose the **WRONG** statement:

- A) Involves several points of ossification
- B) Frontanelles are areas of newborn's skull in which the cartilage is not yet ossified
- C) Takes place in mesenchymal condensations
- D) Forms the flat bones of the skull
- E) Contributes to the growth of short bones and thickening of long bones

Question : Which of the following joints are classified as symphyses?

- A) Saddle joints
- B) Interosseous membranes
- C) Sutures
- D) Intervertebral discs
- E) Growth plates

Ans: D

Question : Perichondrium is a?

- A) Loose connective which contains fibroblasts, chondrogenic cells, and other elements.
- B) Reticular connective which contains fibroblasts, chondrogenic cells, and other elements.
- C) Dense connective which contains fibroblasts, chondrocytes, and other elements.
- D) Loose connective which contains chondrocytes, chondrogenic cells, and other elements.
- E) Dense connective which contains fibroblasts, chondrogenic cells, and other elements.

Ans: E

Question : Formation and growth of long bones, choose the **WRONG** statement:

Q28

- A) Hyaline cartilage remains on the articular surfaces and persists through adult life
- B) The first site of ossification in long bones occurs in the middle of diaphysis
- C) Growth in diameter is due to osteoblastic activity in periosteum and osteoclastic activity in endosteum
- D) Bone collar facilitates the diffusion of oxygen and nutrients to the underlying cartilage
- E) The cartilage between the primary and secondary ossification centers is called the epiphyseal plate

Ans: D

Question : All the following represent the elastic fibers except

- A) Contain mainly collagen type II
- B) Found in the auricle of the ear
- C) Found in the costal cartilage
- D) Found in the walls of the external auditory meatus
- E) Found in the epiglottis

Question : The correct statement about bone & cartilage is

- A) Bone is innervated and vascularised, Cartilage neither innervated nor vascularised
- B) Bone innervated and vascularised, Cartilage depend on type
- C) Bone is neither innervated nor vascularised, Cartilage is innervated and vascularised
- D) Bone depend on type, Cartilage depend on type
- E) Bone depend on type, Cartilage neither innervated nor vascularised

Ans: A

Question : Which one of the following does not present in the osteons

- A) Haversian canal
- B) Concentric lamellae
- C) Neurons & vessels
- D) Osteocyte
- E) Interstitial lamellae

Ans: E

Question : Which lamellae of the following surrounds the trabecular

- A) Bone marrow
- B) Interstitial circumferential lamellae
- C) Central circumferential lamellae
- D) Inner circumferential lamellae
- E) Outer circumferential lamellae

Question : All the following statements are true regarding calcification except

- A) Happens especially in costal cartilage
- B) Occur in hyaline cartilage
- C) Common condition due to aging
- D) It is similar to enchondral calcification
- E) It does not include degeneration of chondrocytes

Question : The fate of majority of osteoblasts after completing matrix synthesis

- A) Differentiate to osteocytes
- B) Undergo apoptosis
- C) Flattened
- D) Creat bone lining cells
- E) Digest bone matrix

Ans: B

Question : What is correct regarding osteoporosis and osetopetrosis

- A) Osteoporosis is a genetic disease that results in light bone
- B) Osteoporosis occurs more in males
- C) Osteopetrosis patients suffer from anemia
- D) Osteoporosis and osteopetrosis are normal
- E) Osteoporosis also called marble bone

Ans: C

Question : In which zone does calcification occur

- A) Zone of reserve cartilage
- B) Zone of proliferation
- C) Zone of hypertrophy
- D) Zone of calcified cartilage
- E) Zone of ossification

Ans: D

Question : Collagen type II is found in

- A) Elastic Cartilage & Hyaline Cartilage
- B) Elastic Cartilage & Fibrocartilage
- C) Hyaline Cartilage only
- D) All types of cartilages
- E) Elastic Cartilage only

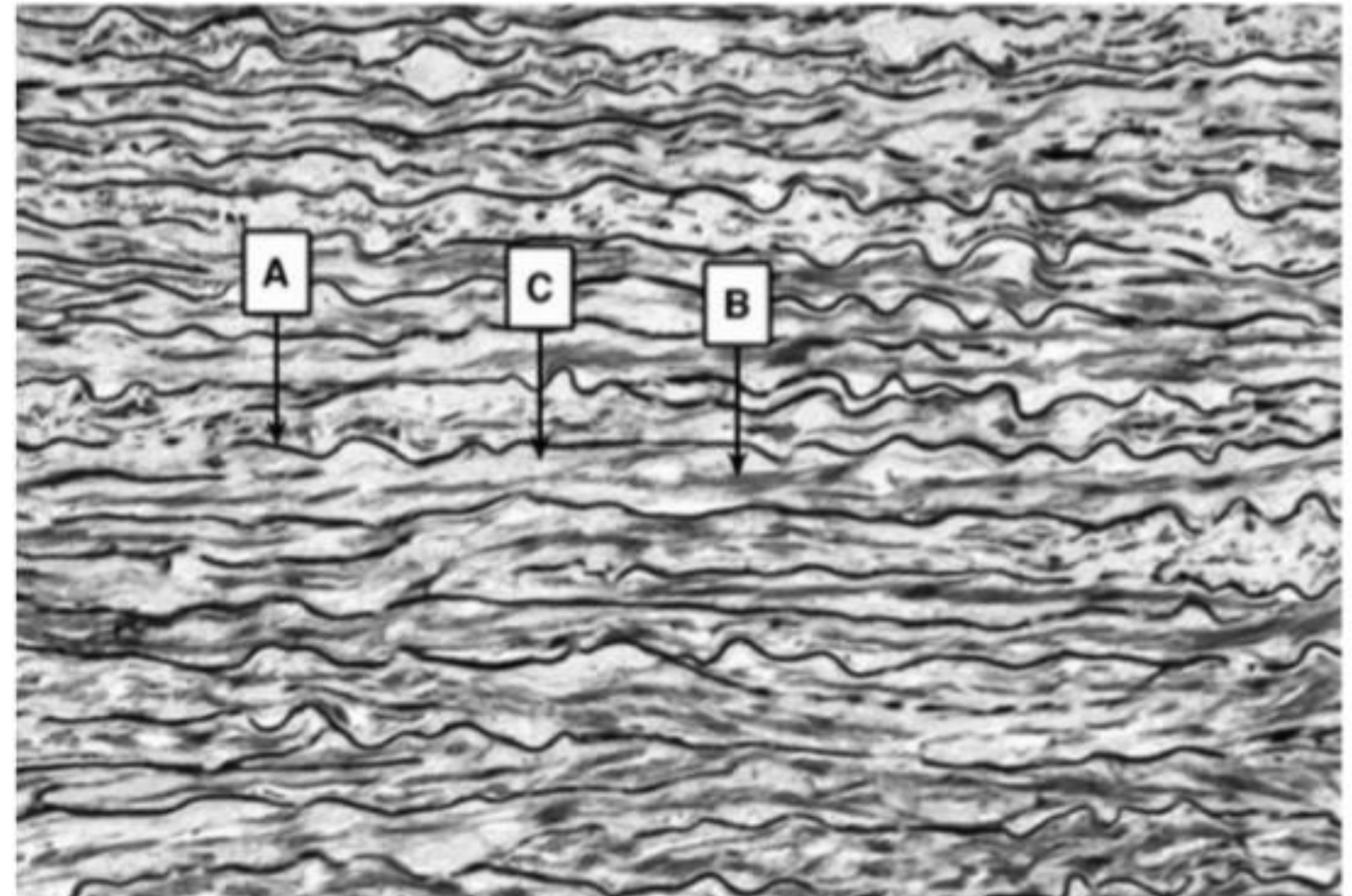
Question : What is incorrect regarding fibrocartilage

- A) It is found in the larynx
- B) It is found in the intervertebral disc
- C) Contain collagen type II
- D) Contain collagen type I
- E) Very strong type of cartilage

Ans:A

Question : This tissue contains

- A) Reticular fibers
- B) Elastic fibers
- C) Collagen fibers
- D) Reticular and elastic fibers
- E) Reticular and collagen fibers



Ans: B

Question : What makes territorial matrix more basophils than inter territorial matrix

- A) More GAGs / More collagen
- B) More collagen / More GAGs
- C) Less GAGs / Less collagen
- D) Less GAGs / More collagen
- E) More GAGs / Less collagen

Question : In the diaphysis of a typical long bone which of the following structures is in closest proximity to the trabeculae of cancellous bone?

- A) Interstitial lamella
- B) Sharpey's fibers
- C) Inner circumferential lamellae
- D) Osteons
- E) Outer circumferential lamellae

Question : Several layers of cells reside within epiphyseal plates of developing long bones. Which layer is responsible for anchoring the plate to the bony epiphysis?

- A) Cells undergoing mitosis
- B) Cells enlarging and becoming calcified
- C) Dead cells with calcified intercellular substance
- D) Resting cells
- E) None of the above

Question : Bone Histology, Choose the wrong statement

- A) the Bone hardness results from the presence of collagen type 1
- B) Both compact and spongy bones are considered lamellar bones
- C) The Lamellae of compact bone are organized into the haverssea system
- D) Bone collar is formed only during endochondral ossification
- E) Interstitial lamellae are remnants of once existed concentric lamellae

Ans: A

Question : after birth growth in the length of long bones occurs primarily through

- A) A)The action of osteoblasts in the primary ossification center
- B) increased bone deposition under periosteum
- C) The action of osteoblasts in the secondary ossification center
- D) Appositional growth from the periphery
- E) Interstitial growth of cartilage cells in the epiphyseal plate

Question : In endochondral ossification, what happens to the chondrocytes

- A) They die in the calcified matrix that surrounds them
- B) They grow and form periosteum
- C) They increase in size and persist throughout life
- D) They group together to form the primary ossification center
- E) They develop into osteocytes

Ans: A

Question : Regarding joints, choose the WRONG match?

- A) Diarthrosis: synovial joints
- B) Symphysis: hyaline cartilage
- C) Synarthrosis: no movement
- D) Syndesmosis: interosseous membrane
- E) Synchondrosis: growth plate

Ans: B

Question : Which of the following is NOT true about canaliculi?

- A) they connect lacunae by tiny channels
- B) they contain cytoplasmic extensions of osteocytes
- C) tiny nerves pass through them
- D) nutrients diffuse through them
- E) all of the above are true

Question : The CT framework used for the formation of bones by intramembranous ossification

- A) cartilage
- B) collagen fibers
- C) calcified cartilage matrix
- D) a and c can be correct

Question : The mesenchymal cells on the edges differentiate into to form the outer layer periosteum in intramembranous ossification:

Q49

- A) osteoblasts
- B) Osteoclasts
- C) Fibroblasts
- D) Osteocytes
- E) none of the above

Ans: C

Question : regarding fetal intramembranous ossification, choose the correct statement -if any

- A) only one centre of ossification can exist simultaneously
- B) both compact and spongy bone are formed at the same time
- C) some parts of fibrous membrane in skull is not be replaced by bone tissue.
- D) It is responsible for long bones formation such as femur
- E) all of the above are incorrect

Question : Choose the incorrect statement, if any, regarding the endochondral ossification

- A) death of chondrocytes creates a porous structure consisting of calcified cartilage remnants
- B) Bone starts solid, and then becomes hollow later on
- C) one or more secondary ossification centers can exist simultaneously
- D) chondrocytes surrounded by bone collar in the mid. Of diaphysis experience “gradual” death
- E) all of the above are correct

Question : Appositional growth is due to bone formation

- A) in epiphysis
- B) in the growth plate
- C) in the medullary cavity
- D) beneath the periosteum
- E) none of the above

Ans: D

"تَاجُ الذِّكْرِ"

لَا إِلَهَ إِلَّا اللَّهُ وَحْدَهُ لَا شَرِيكَ لَهُ

لَهُ الْمُلْكُ وَلَهُ الْحَمْدُ وَهُوَ عَلَى كُلِّ شَيْءٍ قَدِيرٌ

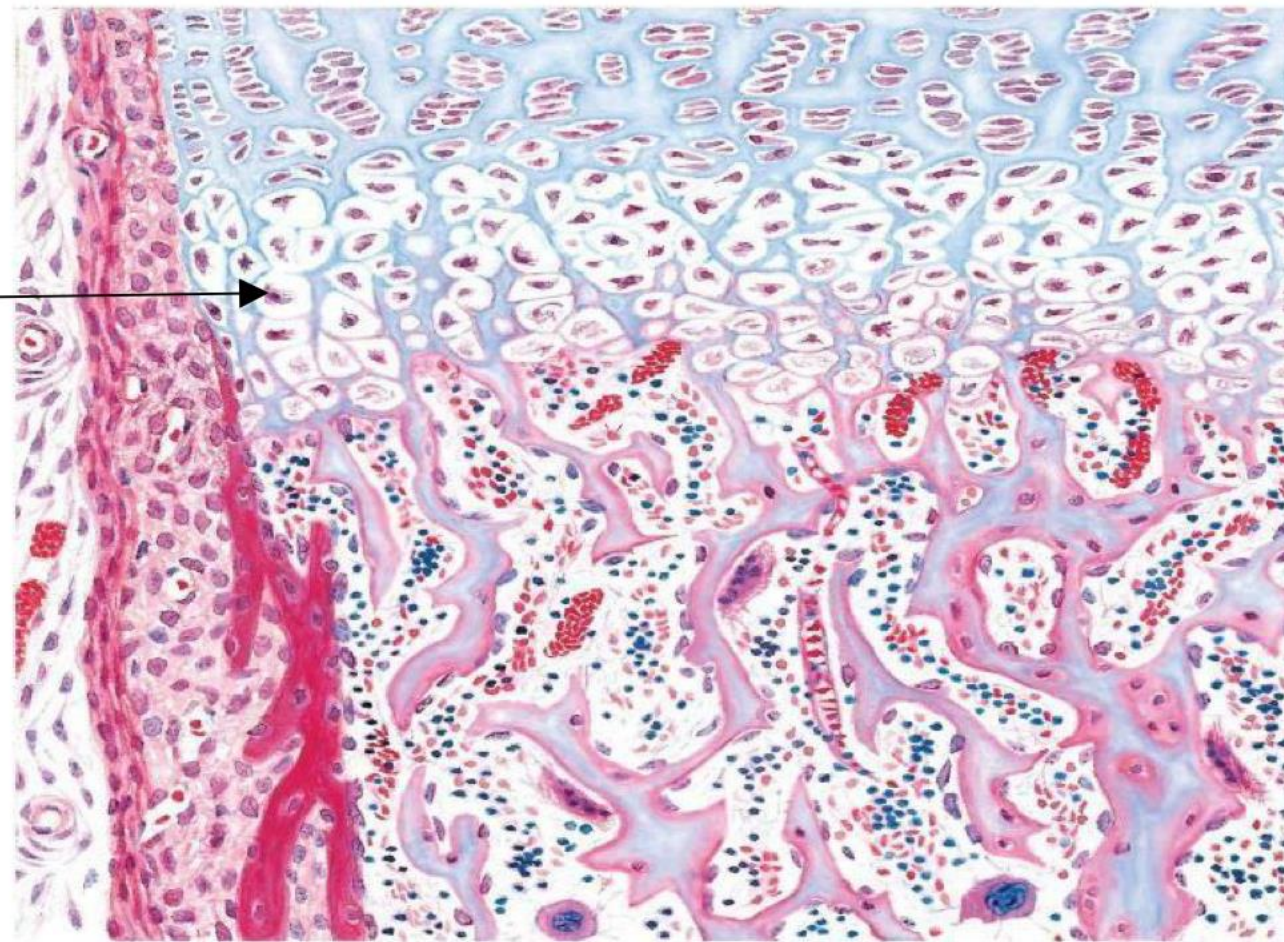
Question : An astronaut has experienced no gravity for a long time, what is your conclusion?

- A) a decrease in bone mass
- B) an increase in bone mass
- C) gravity has nothing to do with bones. It's just physics.

Question : Regarding joints classification, choose the incorrect statement

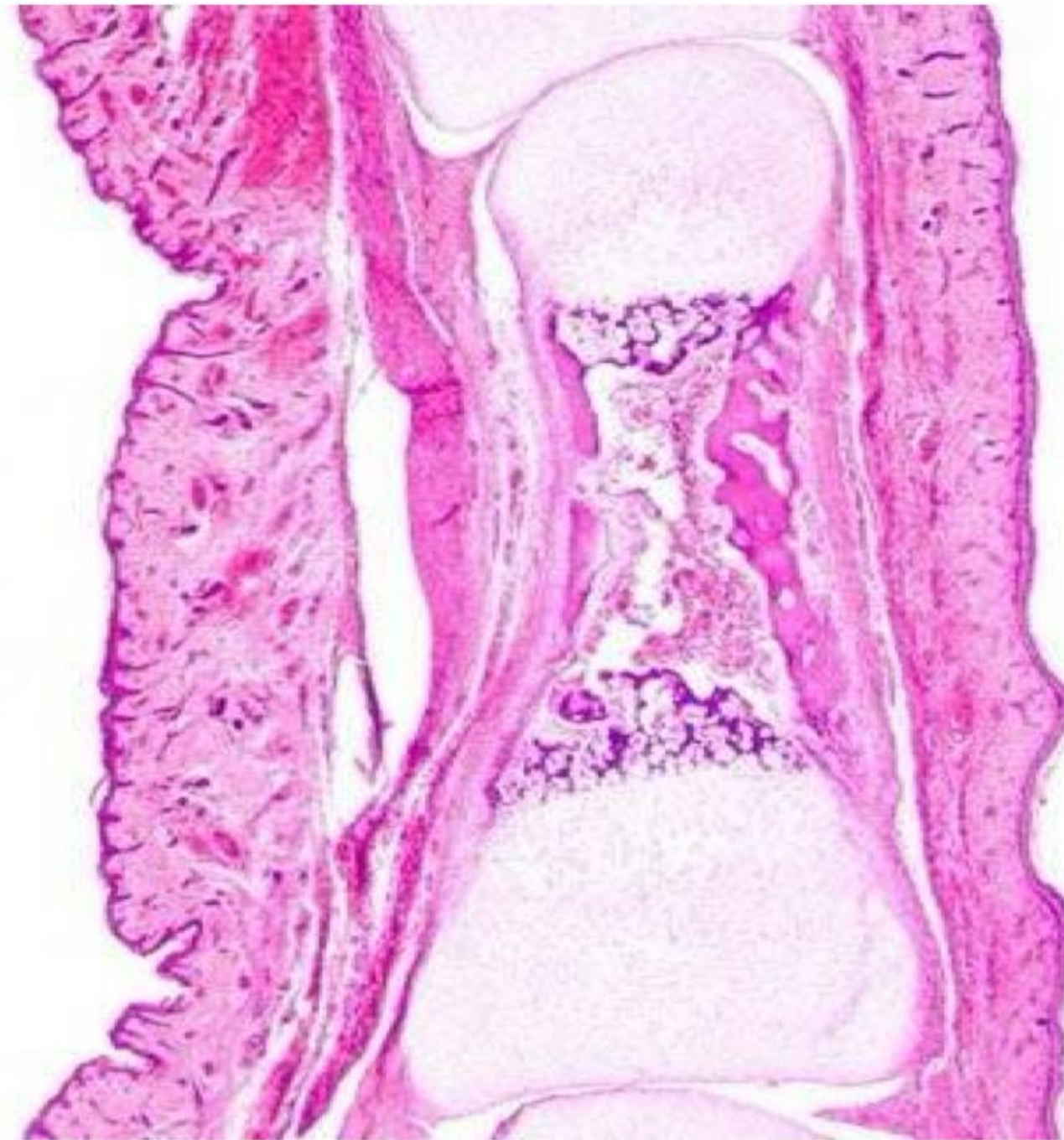
- A) syndesmosis joint is fibrous and amphiarthrotic
- B) sutures have no joint cavities
- C) the capsule of elbow joint is not reinforced by ligaments
- D) The articular surface in synovial joint is covered by articular cartilage
- E) all of the above are true

Question : Identify the pointed zone



Ans: Hypertrophy zone

Which of the following you can't find in this section?



Ans: Secondary ossification center.

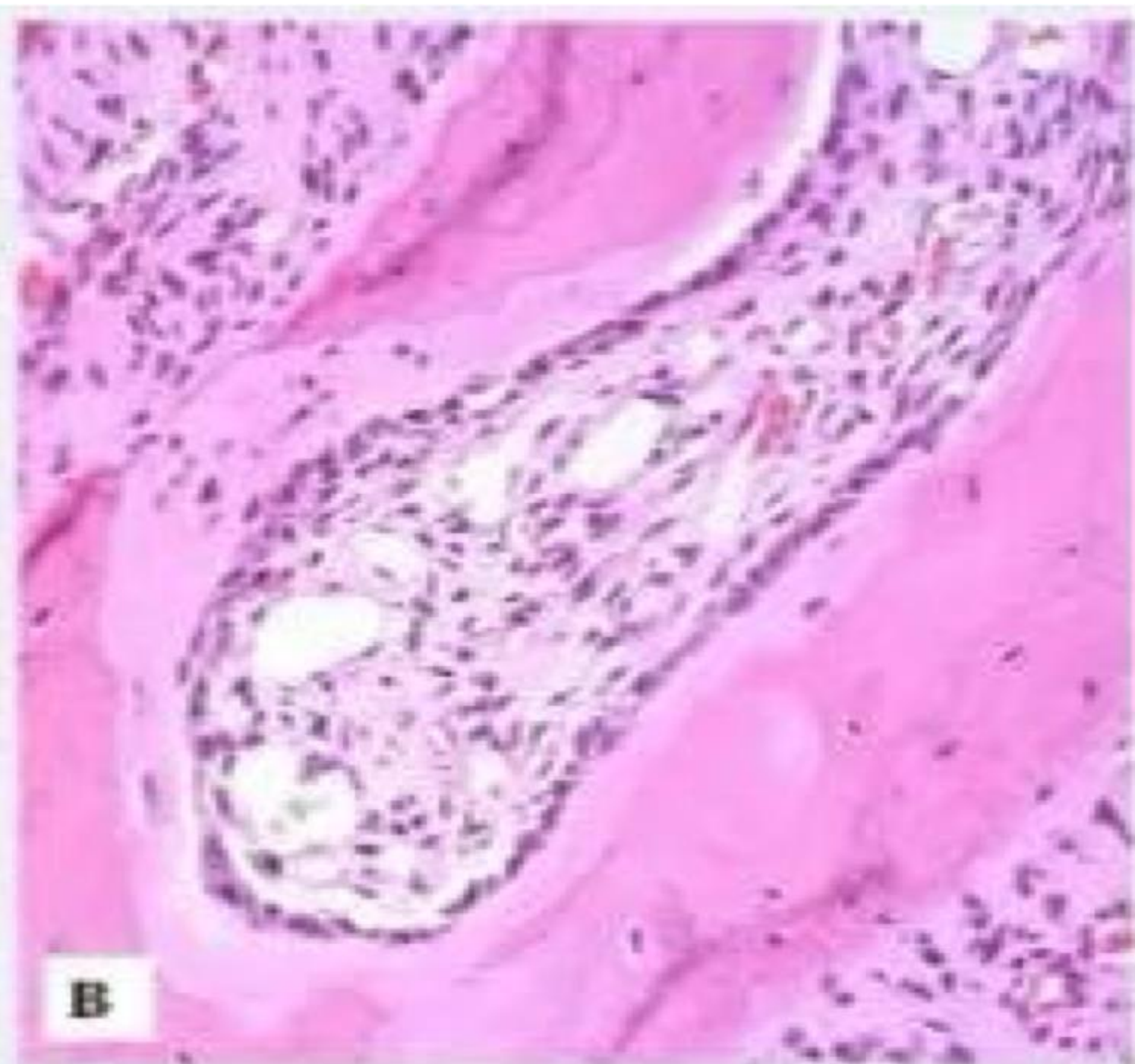
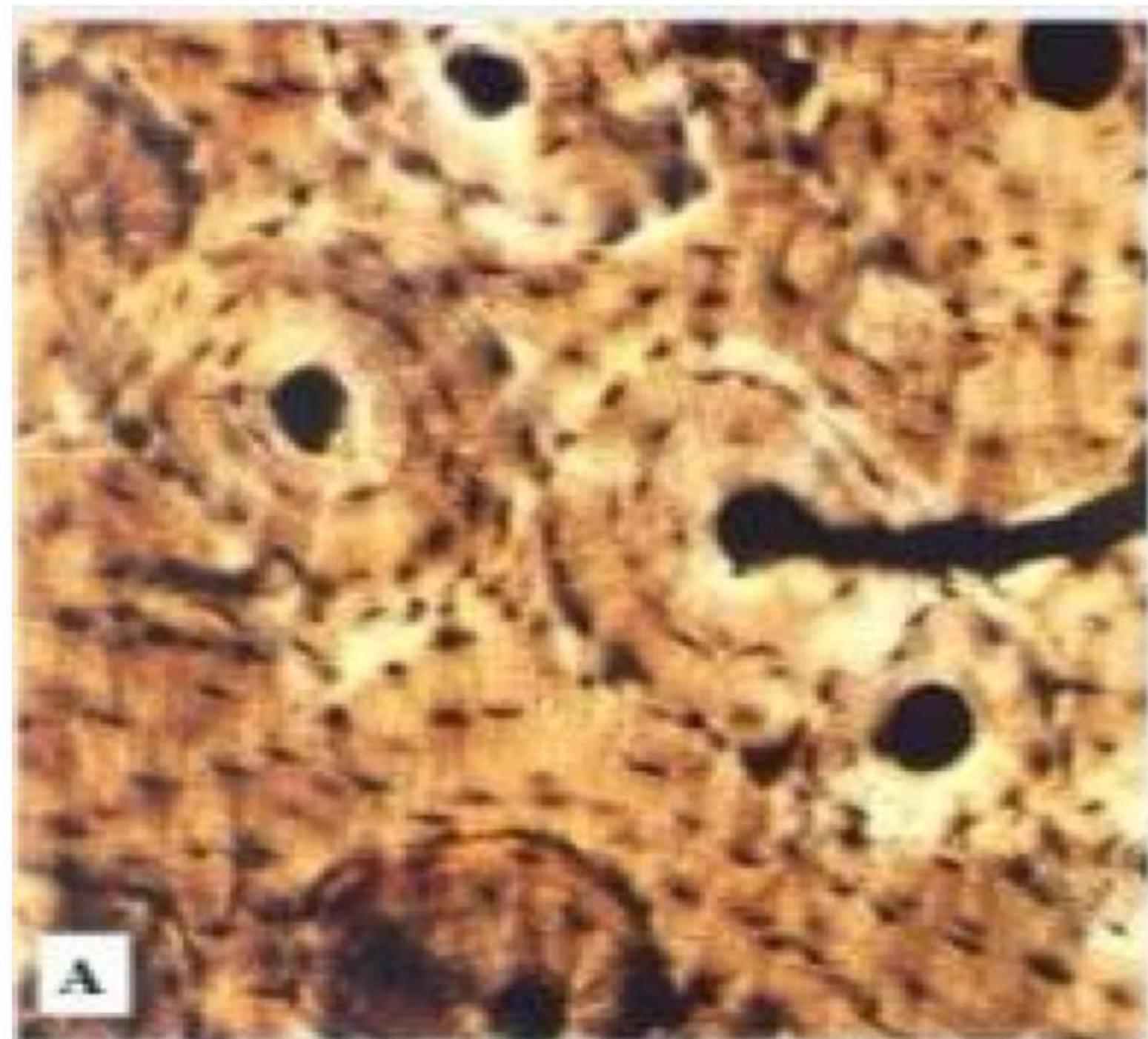Choose the WRONG regarding sections these

Q57

- A) Canaliculi can be identified in section B
- B) Osteoid matrix, red bone marrow and endosteum can be identified in section B
- C) Interstitial lamellae can be identified in section A
- D) Volkmann's canal can be identified in section A
- E) Section A is a ground bone section, while section B is a decalcified section

↳

Ans: A



Question : Bone formation, choose the WRONG statement:

- A) Bones grow in diameter due to bone formation beneath the periosteum
- B) Zone of hypertrophy contains chondrocytes with large amounts of glycogen
- C) Fontanelles are areas of the newborn's skull in which the cartilage is not yet ossified
- D) Postnatal bone growth continues until early adulthood
- E) The cartilage of the epiphyseal plate is a hyaline cartilage

Question : In the diaphysis of a typical long bone which of the following structures is in closest proximity to the trabeculae of cancellous bone?

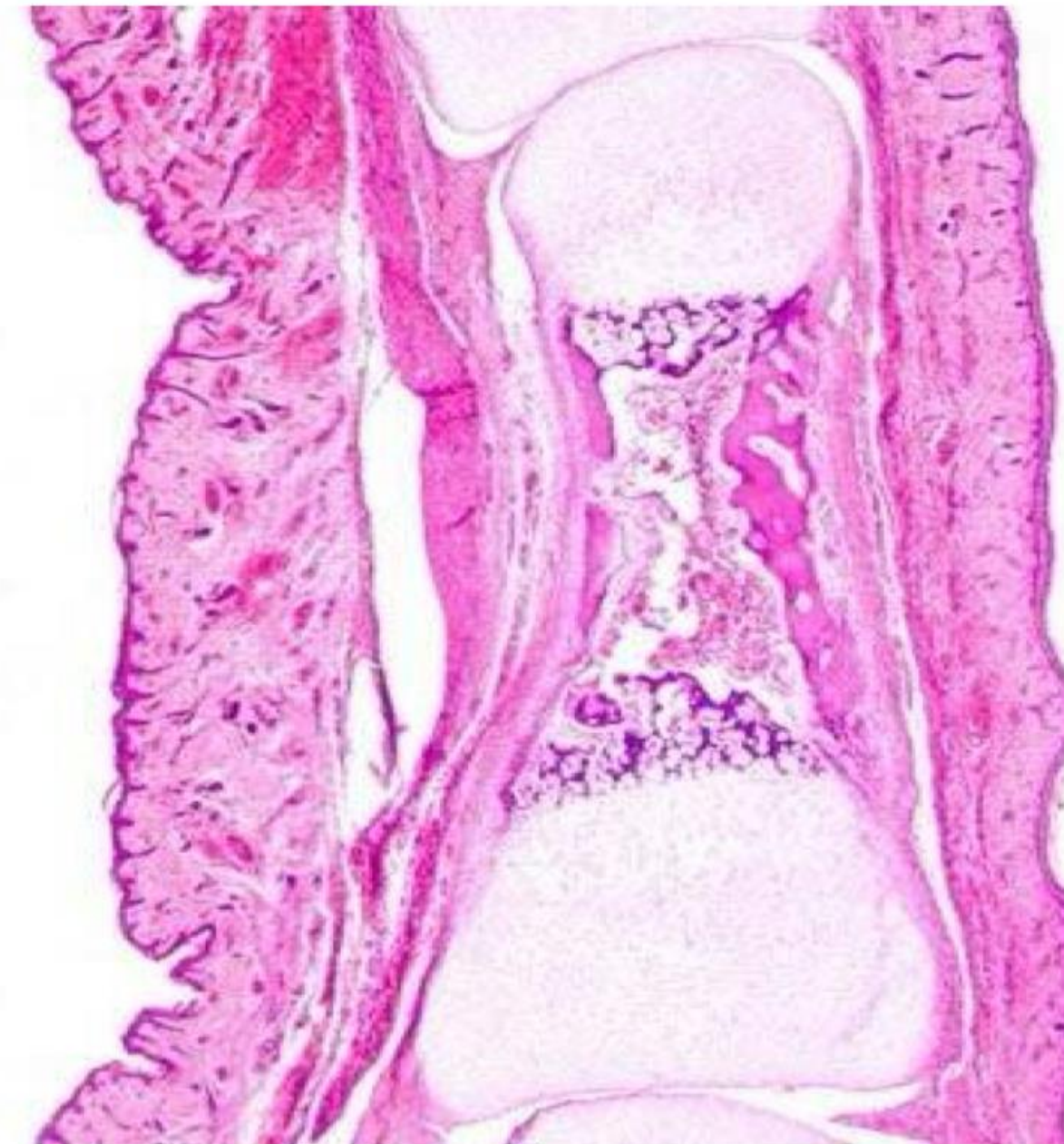- A) Outer circumferential lamellae
- B) Inner circumferential lamellae
- C) Osteons
- D) Interstitial lamellae
- E) Sharpey fibers

Question : Several layers of cells reside within epiphyseal plates of developing long bones. Which layer is responsible for anchoring the plate to the bony epiphysis?

- A) Cells undergoing mitosis
- B) Cells enlarging and becoming calcified
- C) Dead cells with calcified intercellular substance
- D) Resting cells
- E) None of the above

Question : Choose the **WRONG** regarding this section:

- A) Diaphysis and two epiphyses can be identified
- B) Secondary center of ossification can be identified in the epiphyses
- C) Is formed by endochondral ossification
- D) Is taken from a long bone
- E) This section is most probably taken before birth



Ans:B

Question : In endochondral ossification, what happens to the chondrocytes?

- A) They die in the calcified matrix that surrounds them
- B) They group together to form the primary ossification center
- C) They grow and form periosteum
- D) They increase in size and persist throughout life
- E) They develop into osteocytes

Question : After birth, growth in the length of long bones occurs primarily through:

- A) Interstitial growth of cartilage cells in the epiphyseal plate
- B) The action of osteoblasts in the primary ossification center
- C) Appositional growth from the periphery
- D) Increased bone deposition under periosteum
- E) The action of osteoblasts in the secondary ossification center

Question : All of the followings apply to both endochondral and intramembranous ossification EXCEPT:

- A) The bone matrix is formed by osteoblasts
- B) Both start prenatally
- C) The number of ossification centers
- D) The first bone produced is immature bone
- E) The type of collagen synthesized

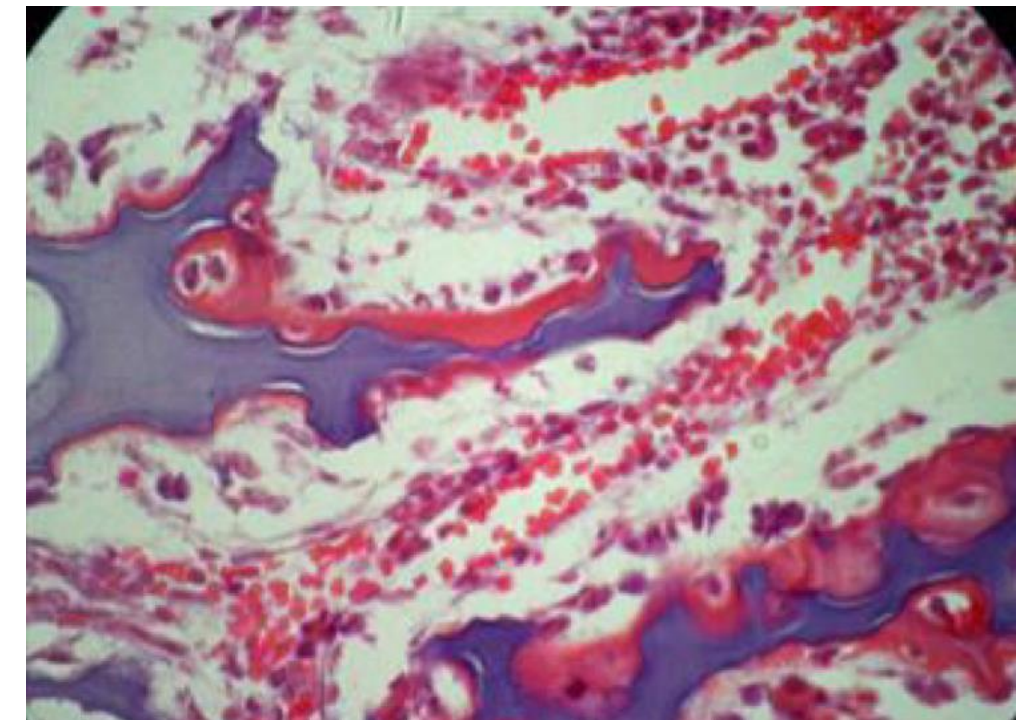
Question : Bone histology, choose the WRONG statement:

- A) Both compact and spongy bones are considered lamellar bones
- B) Interstitial lamellae are remnants of once existed concentric lamellae
- C) Bone collar is formed only during endochondral ossification
- D) The lamellae of compact bone are organized into Haversian system
- E) The hardness of bone results from the presence of collagen type I

Ans:E

Question : All the following can be found in this zone
EXCEPT:

- A) Osteoblasts
- B) Calcified cartilage matrix
- C) Woven bone
- D) Chondrocytes
- E) Osteocytes



Question : Elastic cartilage is present in:

- A) External acoustic meatus
- B) External ear.
- C) Costal cartilage.
- D) There is more than one correct answer.
- E) Epiglottis

Question : Articular cartilage:

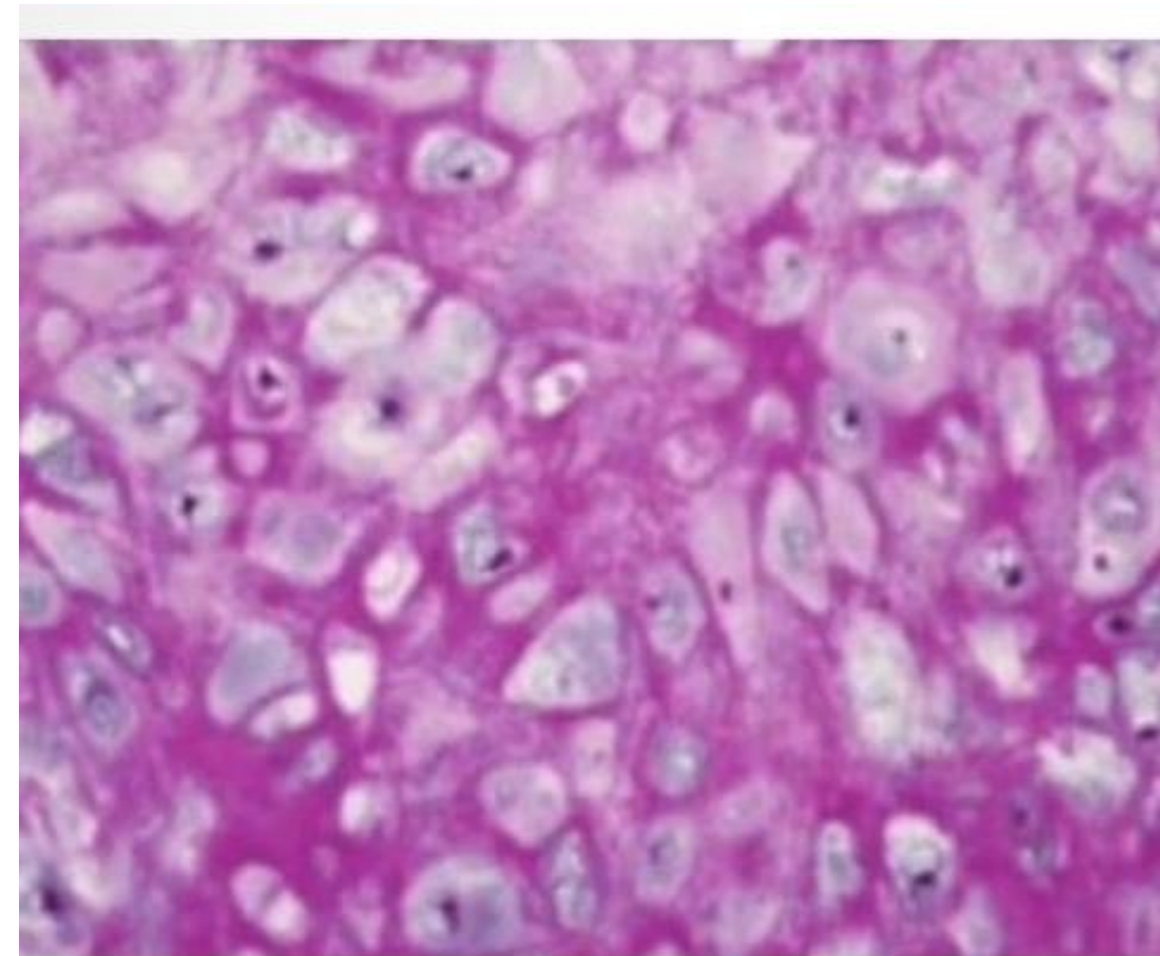
- A) None of the mentioned.
- B) All of the mentioned.
- C) Is a fibrocartilage.
- D) Exhibits a high regenerative capacity.
- E) Is devoid of periosteum.

Question : Regarding fibers in cartilage, choose the INCORRECT statement:

- A) Collagen fibers stain well with H&E stain
- B) Collagen type I is abundant in fibrocartilage.
- C) Collagen type 11 is abundant in hyaline cartilage.
- D) All of the mentioned.
- E) None of the mentioned.

Question : Practical: Identify this tissue:

- A) Brown adipose tissue.
- B) Fibrocartilage.
- C) Hyaline cartilage
- D) Elastic cartilage.



Ans:D

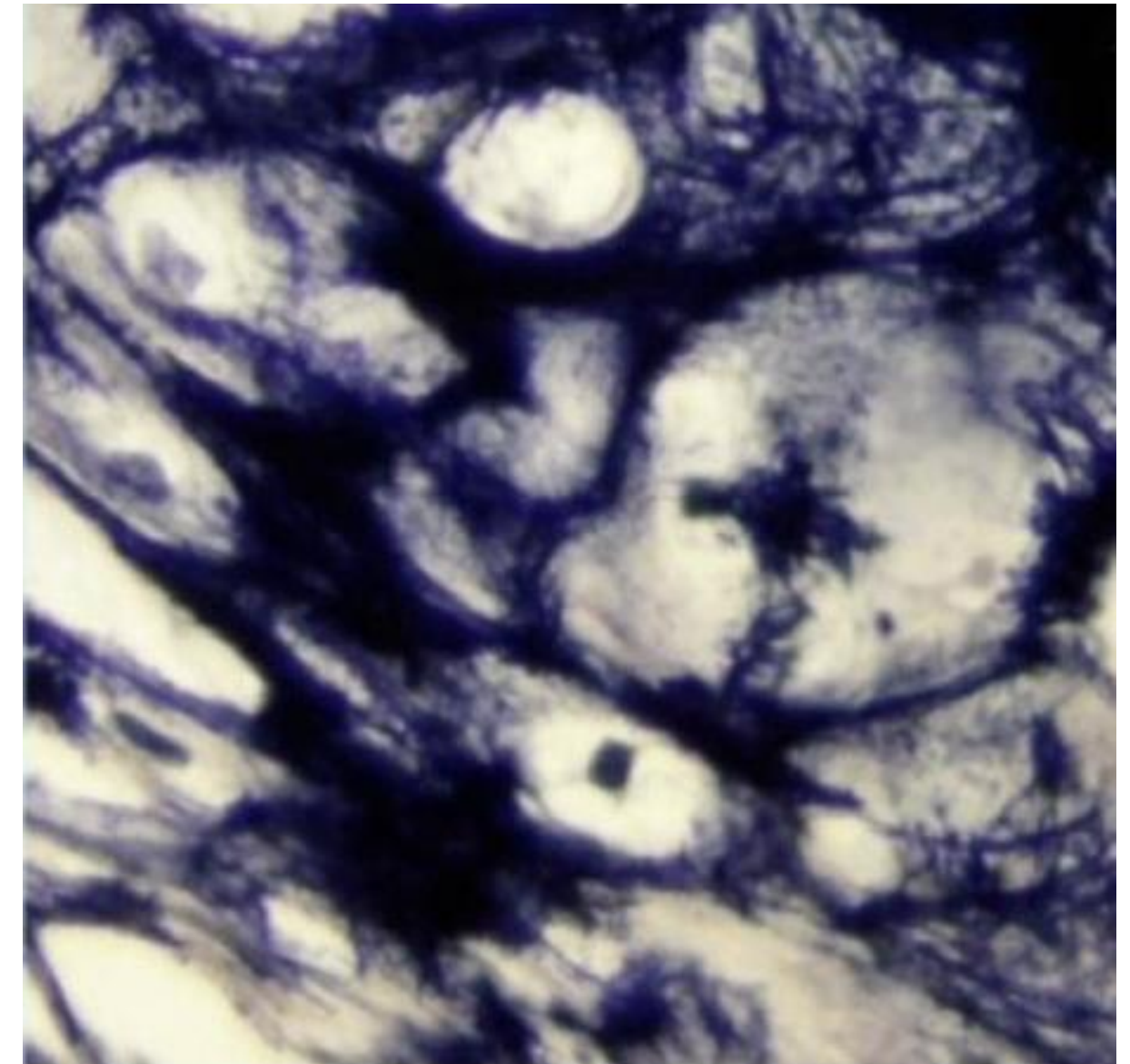
Question : Perichondrium is a:

- A) Loose connective which contains fibroblasts, chondrogenic cells, and other elements.
- B) Dense connective which contains fibroblasts, chondrogenic cells, and other elements.
- C) Dense connective which contains fibroblasts, chondrocytes, and other elements.
- D) Loose connective which contains chondrocytes, chondrogenic cells, and other elements.
- E) Reticular connective which contains fibroblasts, chondrogenic cells, and other elements.

Ans:B

Question : Practical: The black structure in this Image is/are:

- A) Chondroitin sulfate.
- B) Reticular fibers.
- C) Elastic fibers.
- D) Collagen fibers



Ans:C

Question : Which of the following are found in compact bone and cancellous bone?

- A) Haversian canals
- B) Volkmann's canals
- C) circumferential lamellae
- D) Lacunae
- E) Trabeculae


Question : Hydroxyapatite crystals are made mainly from the combination of:

- A) Calcium and phosphate
- B) Chondroitin sulfate and inorganic salts
- C) Collagen type I fibers and carbon molecules
- D) Calcium, phosphate and collagen type I fibers
- E) Glycoproteins and vitamin D

Question : An osteon is:

- A) Composed of woven bone
- B) Involved in the formation of outer circumferential lamellae
- C) A cylinder of bone tissue surrounding a central canal
- D) The basic structural unit of spongy bone
- E) A porous bone composed of trabeculated bone tissue

Ans:C



يَا رَبِّ الْجَنَّةِ وَظِلَالِهَا وَنَعِيمِهَا
رَبَّنَا وَلِمَوْتَانَا وَمَوْتِ الْمُسْلِمِينَ

Question : Practical: Identify the yellow labeled structure:

- A) Osteon
- B) Lamella
- C) Volkmann's canal
- D) Lacuna
- E) Central canal

Ans:C

Question : Which of the following cells is located in Howship's lacuna?

- A) Osteoclast
- B) Osteoblast
- C) Osteogenic cell
- D) Osteocyte
- E) Chondroblast

Question : Osteocytes maintain contact with the blood vessels of the central canal through:

- A) Perforating fibers
- B) Canaliculi
- C) Concentric lamellae
- D) Periosteum
- E) Interstitial lamellae

Question : Woven bone , choose the WRONG statement:

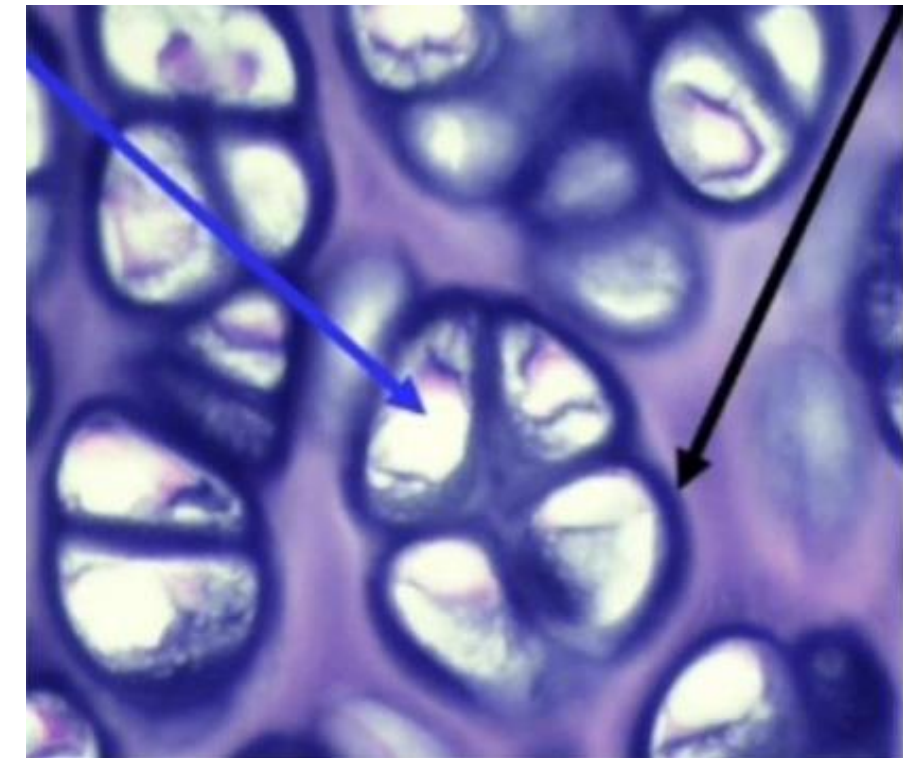
- A) Its collagen fibers are not organized into lamellae
- B) It is not degraded by osteoclasts
- C) It has a lower mineral content compared to secondary bone
- D) It is formed during repair of fracture sites
- E) It is the first bone tissue to appear in embryonic development

Question : Regarding Endosteum, choose the WRONG statement:

- A) Is involved in bone growth in width
- B) Covers trabeculae of spongy bone
- C) Is attached to bone trabeculae by Sharpey's fibers
- D) lines the Internal cavity of the bone
- E) Is composed of a single layer of cells

Question : Practical: The blue and black arrows point to, respectively :

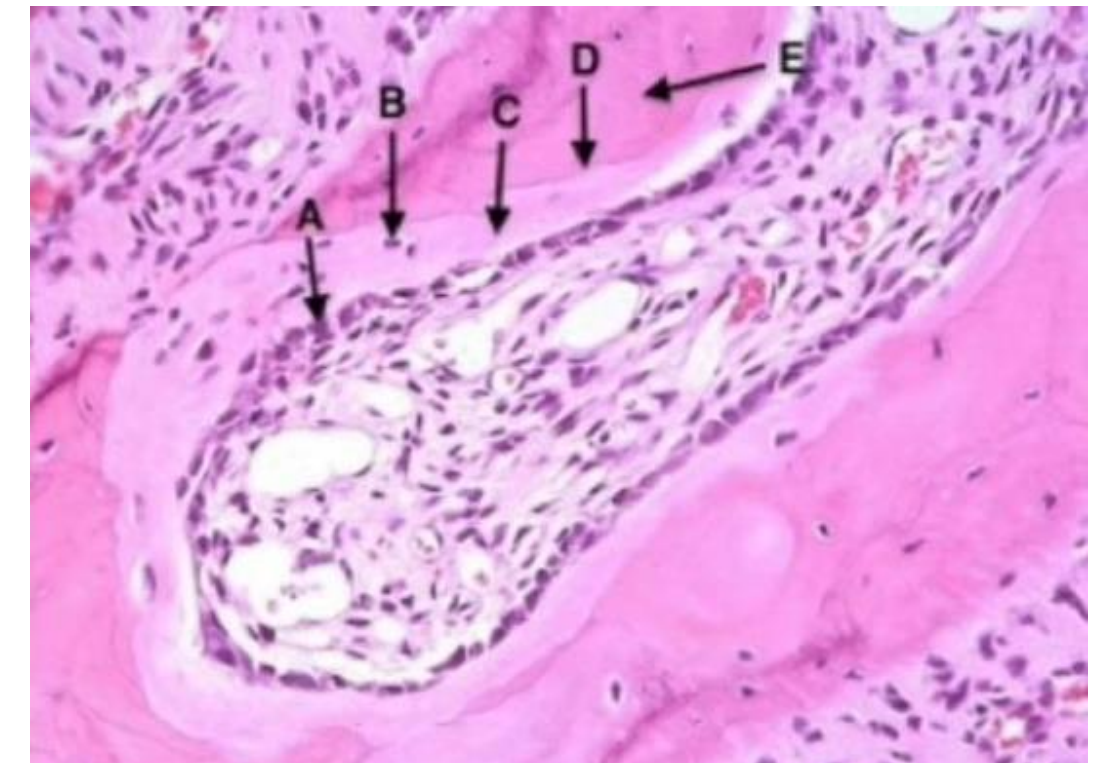
- A) A lacuna and a chondrocyte.
- B) A chondrogenic cell and interterritorial matrix.
- C) A lacuna and the territorial matrix.
- D) The territorial matrix and the Interterritorial matrix.



Ans:A

Question : Practical: Choose the **WRONG** statement regarding this section:

- A) Arrow B points at a cell located within lacuna
- B) Arrow A points at a bone forming cell
- C) It is a trabecular bone
- D) It is a decalcified bone section
- E) Arrow C points at the mineralised bony matrix



Question : All the followings can be found in the ossification zone EXCEPT:

- A) Chondrocyte within lacunae
- B) Osteoblasts
- C) Primary bone
- D) Osteocyte within lacunae
- E) Calcified matrix of the cartilage

Question : All of the following statements about bone cells are correct EXCEPT:

- A) Some osteoblasts turn into osteocytes while the new bone is being formed
- B) Osteocytes are often grouped in nests inside lacunae as a result of earlier mitoses
- C) Osteoclasts form the ruffled border that opposes the surface of the bone tissue
- D) Osteoblasts are mononucleate cells
- E) Osteoblasts produce type I collagen

Ans: B

Question : All of the followings apply to both endochondral ossification and intramembranous ossification EXCEPT:

- A) They start prenatally
- B) The formation of bone collar
- C) The type of collagen synthesized
- D) The bone matrix is formed by osteoblasts
- E) The first bone produced is immature bone

Ans: B

Question : in epiphyseal plate growth, what happens when the zone of ossification overtakes the zone of resting cartilage?

- A) The hyaline cartilage of the plate is replaced by bone
- B) Longitudinal growth at the bone terminates (at least at one end)
- C) The diaphysis and epiphysis portions of the bone fuse together to form a single adult's bone
- D) The epiphyseal plate becomes the epiphyseal line
- E) All of the mentioned

Ans:E

Question : Several layers of cells reside within epiphyseal plates of developing long bones. Which statement best describes the ossification zone?

- A) Cells enlarging and causing the cartilaginous matrix to become calcified
- B) Resting cells
- C) Osteoblasts adhering to the remnants of calcified cartilage matrix and producing woven bone
- D) Cells undergoing mitosis and forming long columns of isogenous groups
- E) None of the mentioned

Ans:c

Which of the following you won't find intramembranous ossification?

ANSWER : Osteoclasts appear Basophilic in H&E sections.

Which of the following is wrong?

Answer : Osteoclasts appear Basophilic in H&E sections.

Which of the following statements is wrong?

Answer : You always find perichondrium around hyaline cartilage.

Which of the following statements is wrong?

Answer: Spongy bone is formed only by intramembranous ossification.

In a section of spongy bone solely formed by intramembranous ossification, which of the following would not be seen?

Answer: Calcified cartilage.

Question : Formation and growth of long bones, choose the **WRONG** statement:

- A) Bone collar facilitates the diffusion of oxygen and nutrients to the underlying cartilage
- B) Hyaline cartilage remains on the articular surfaces and persists through adult life
- C) Growth in diameter is due to osteoblastic activity in periosteum and osteoclast's activity in endosteum
- D) The cartilage between the primary and secondary ossifications centres is called the epiphyseal plate
- E) The first site of ossification in long bones occurs in the middle of diaphysis

Ans: a

In differentiating between bone and hyaline cartilage, which of the following is least valuable?

Answer : Lacunae

Howships's lacunae are found around?

Answer: Osteoclasts

Which of the following is wrong?

Answer: Growth can continue after the closure of epiphyseal growth plate.

Question: All the followings can be found in the ossification zone EXCEPT:

- A) Chondrocyte within lacunae
- B) Osteocyte within lacunae
- C) Primary bone
- D) Calcified matrix of the cartilage
- E) Osteoblasts

Which of the following is correct about woven bone?

Answer: It is formed during fractures repairing.

Common between osteoblasts and chondroblasts?

Answer: Both are differentiated mesenchymal cells.

Question: An osteon is

- A) A cylinder of bone tissue surrounding a central canal
- B) A porous bone composed of trabeculated bone tissue
- C) Involved in the formation of outer circumferential lamellae
- D) The basic structural unit of spongy bone
- E) Composed of woven bone

Ans: A

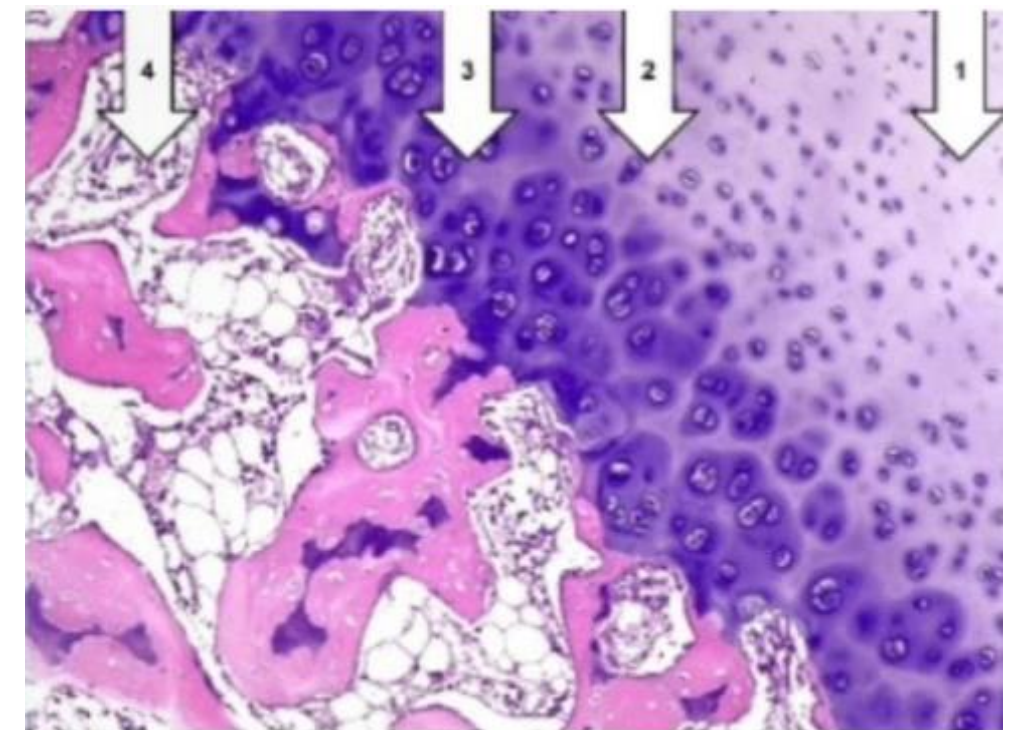
Question: Osteocytes maintain contact with the blood vessels of the central canal through:

- A) Concentric lamellae
- B) Interstitial lamellae
- C) Canaliculi
- D) Perforating fibers
- E) Periosteum

Ans: C

Question* : Practical: Choose the CORRECT match:

- A) Ossification zone: 1
- B) Growth zone: 4
- C) Resting zone: 2
- D) Hypertrophy and calcification: 3



Ans: D

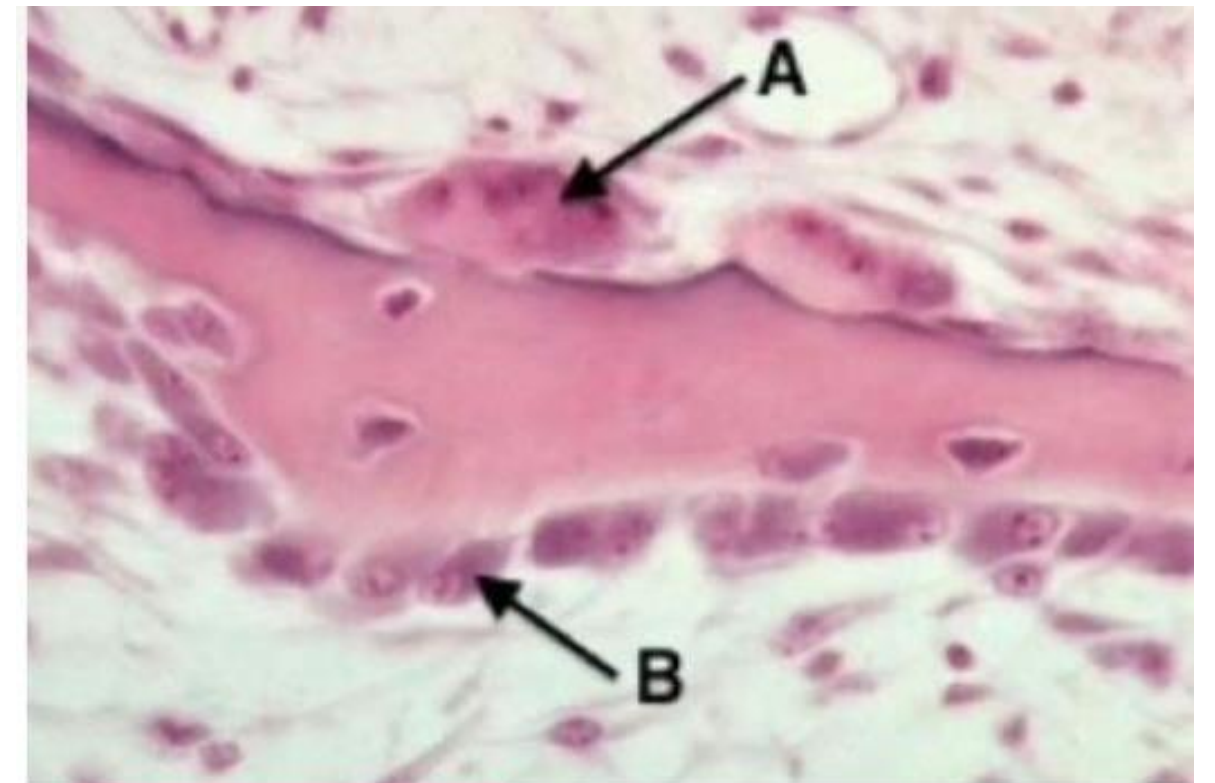Question* : Intramembranous ossification, choose the **WRONG** statement:

- A) Forms the flat bones of the skull
- B) Takes place in mesenchymal condensations
- C) Involves several points of ossification
- D) Contributes to the growth of short bones and thickening of long bones
- E) Fontanelles are areas of the newborn's skull in which the cartilage is not yet ossified .

Ans: E

Question* : Identify A :

- A) Osteoclast
- B) Chondrocyte
- C) Fibrocyte
- D) Osteocyte



Ans: A

Question : All of the following statements about bone cells are correct EXCEPT:

- A) Osteoblasts produce type I collagen
- B) Osteocytes are often grouped in nests inside lacunae as a result of earlier mitoses
- C) Osteoblasts are mononucleate cells
- D) Osteoclasts form the ruffled border that opposes the surface of the bone tissue
- E) Some osteoblasts turn into osteocytes while the new bone is being formed

Ans: B

Question: Articular cartilage:

- A) None of the mentioned.
- B) Is devoid of periosteum.
- C) All of the mentioned.
- D) Exhibits a high regenerative capacity.
- E) Is a fibrocartilage.

Question: Elastic cartilage is present in:

- A) External ear.
- B) External acoustic meatus.
- C) Costal cartilages.
- D) There is more than one correct answer.
- E) Epiglottis.

Question : Several layers of cells reside within epiphyseal plates of developing long bones. Which statement best describes the ossification zone?

Q107

- A) Cells enlarging and causing the cartilaginous matrix to become calcified
- B) Resting cells
- C) Cells undergoing mitosis and forming long columns of isogenous groups
- D) None of the mentioned
- E) Osteoblasts adhering to the remnants of calcified cartilage matrix and producing woven bone

Ans: E

Question : Which of the following are found in compact bone and cancellous bone?

Q108

- A) Lacunae
- B) Circumferential lamellae
- C) Haversian canals
- D) Trabeculae
- E) Volkmann's canals

Ans: A

Question : All of the followings apply to both endochondral ossification and intramembranous ossification EXCEPT:

- A) They start prenatally
- B) The type of collagen synthesized
- C) The bone matrix is formed by osteoblasts
- D) The formation of bone collar
- E) The first bone produced is immature bone

Question : Regarding fibers in cartilage, choose the **INCORRECT** statement:

Q110

- A) All of the mentioned.
- B) None of the mentioned.
- C) Collagen fibers stain well with H&E stain.
- D) Collagen type I is abundant in fibrocartilage.
- E) Collagen type II is abundant in hyaline cartilage.

Ans: B

Question : Endochondral ossification, choose the CORRECT statement:

- A) A process of bone formation involving the replacement of a fibrous membrane
- B) Found in long bones after the closure of the epiphyses
- C) Starts postnatally
- D) Typical of the development of the clavicle
- E) In long bones, the first site of ossification occurs in the middle of diaphysis

Question : Woven bone, choose the WRONG statement:

- A) Its collagen fibers are not organized into lamellae
- B) It has a lower mineral content compared to secondary bone
- C) It is the first bone tissue to appear in embryonic development
- D) It is not degraded by osteoclasts
- E) It is formed during repair of fracture sites

Ans: D



يا حي يا قيوم

برحمتك أستغيثُ
أصلح لي شأني كله
ولا تكلني إلى نفسي طرفة عين



Question : Which of the following cells is located in Howship's lacuna?

- A) Chondroblast
- B) Osteogenic cell
- C) Osteoblast
- D) Osteocyte
- E) Osteoclast

Ans: C

Question : Intramembranous ossification, choose the **WRONG** statement:

- A) Involves several points of ossification
- B) Fontanelles are areas of the newborn's skull in which the cartilage is not yet ossified
- C) Takes place in mesenchymal condensations
- D) Forms the flat bones of the skull
- E) Contributes to the growth of short bones and thickening of long bones.

Ans: B

Question : Which of the following joints are classified as symphyses?

- A) Saddle joints
- B) Interosseous membranes
- C) Sutures
- D) Intervertebral discs
- E) Growth plates

Ans: D

Question : Perichondrium is a:

- A) Loose connective which contains fibroblasts, chondrogenic cells, and other elements.
- B) Reticular connective which contains fibroblasts, chondrogenic cells, and other elements.
- C) Dense connective which contains fibroblasts, chondrocytes, and other elements.
- D) Loose connective which contains chondrocytes, chondrogenic cells, and other elements.
- E) Dense connective which contains fibroblasts, chondrogenic cells, and other elements.

Ans: E

Question : Formation and growth of long bones, choose the **WRONG** statement:

Q117

- A) Hyaline cartilage remains on the articular surfaces and persists through adult life
- B) The first site of ossification in long bones occurs in the middle of diaphysis
- C) Growth in diameter is due to osteoblastic activity in periosteum and osteoclastic activity in endosteum
- D) Bone collar facilitates the diffusion of oxygen and nutrients to the underlying cartilage
- E) The cartilage between the primary and secondary ossification centers is called the epiphyseal plate

Ans: D

Question : Regarding Endosteum, choose the WRONG statement:

- A) Covers trabeculae of spongy bone
- B) Is composed of a single layer of cells
- C) Is attached to bone trabeculae by Sharpey's fibers
- D) Is involved in bone growth in width
- E) Lines the internal cavity of the bone

Ans: C

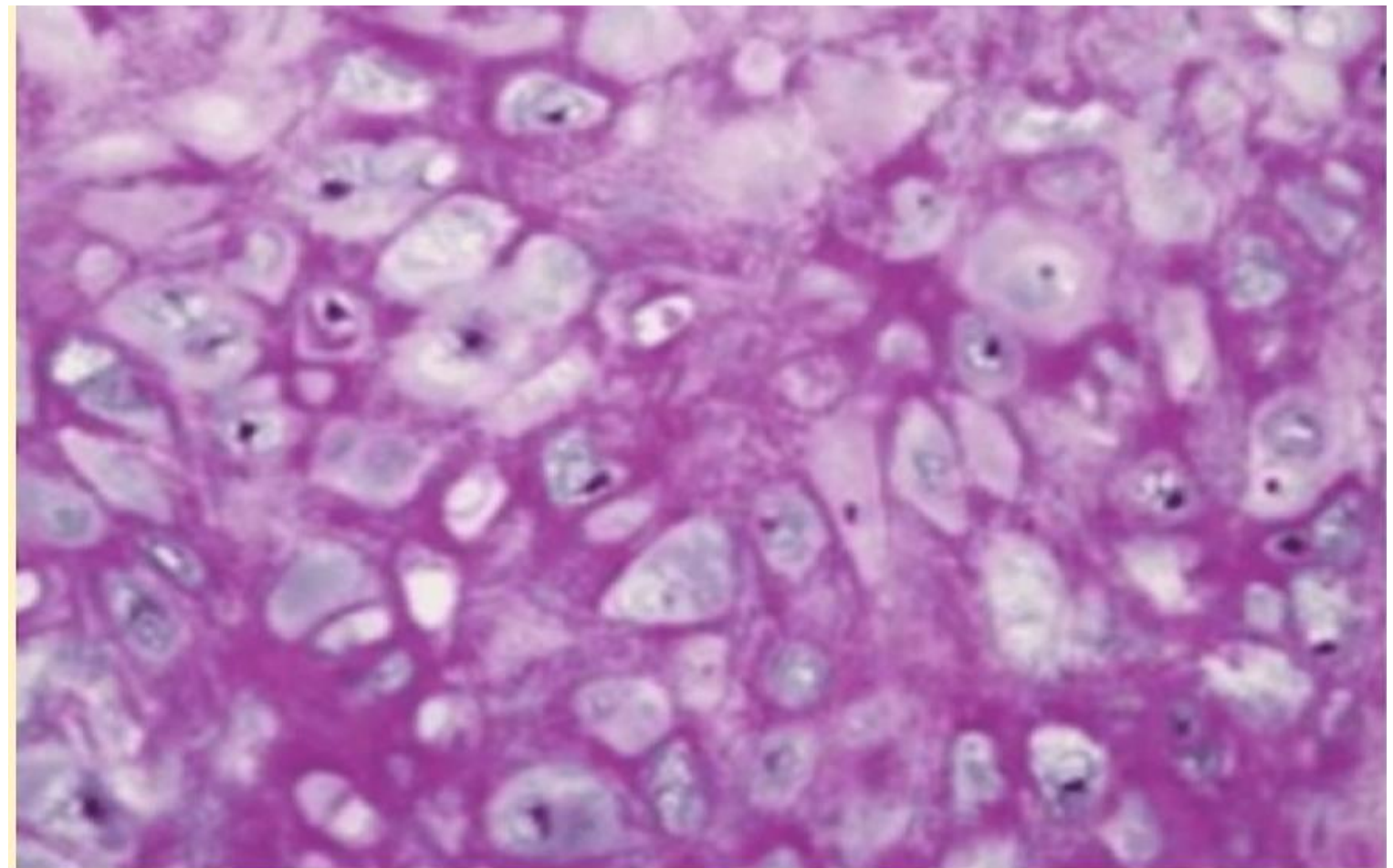
Question : In epiphyseal plate growth, what happens when the zone of ossification overtakes the zone of resting cartilage?

- A) All of the mentioned
- B) The hyaline cartilage of the plate is replaced by bone
- C) Longitudinal growth of the bone terminates (at least at one end)
- D) The epiphyseal plate becomes the epiphyseal line
- E) The diaphysis and epiphysis portions of the bone fuse together to form a single adult bone

Ans: A

Question : Identify this tissue:

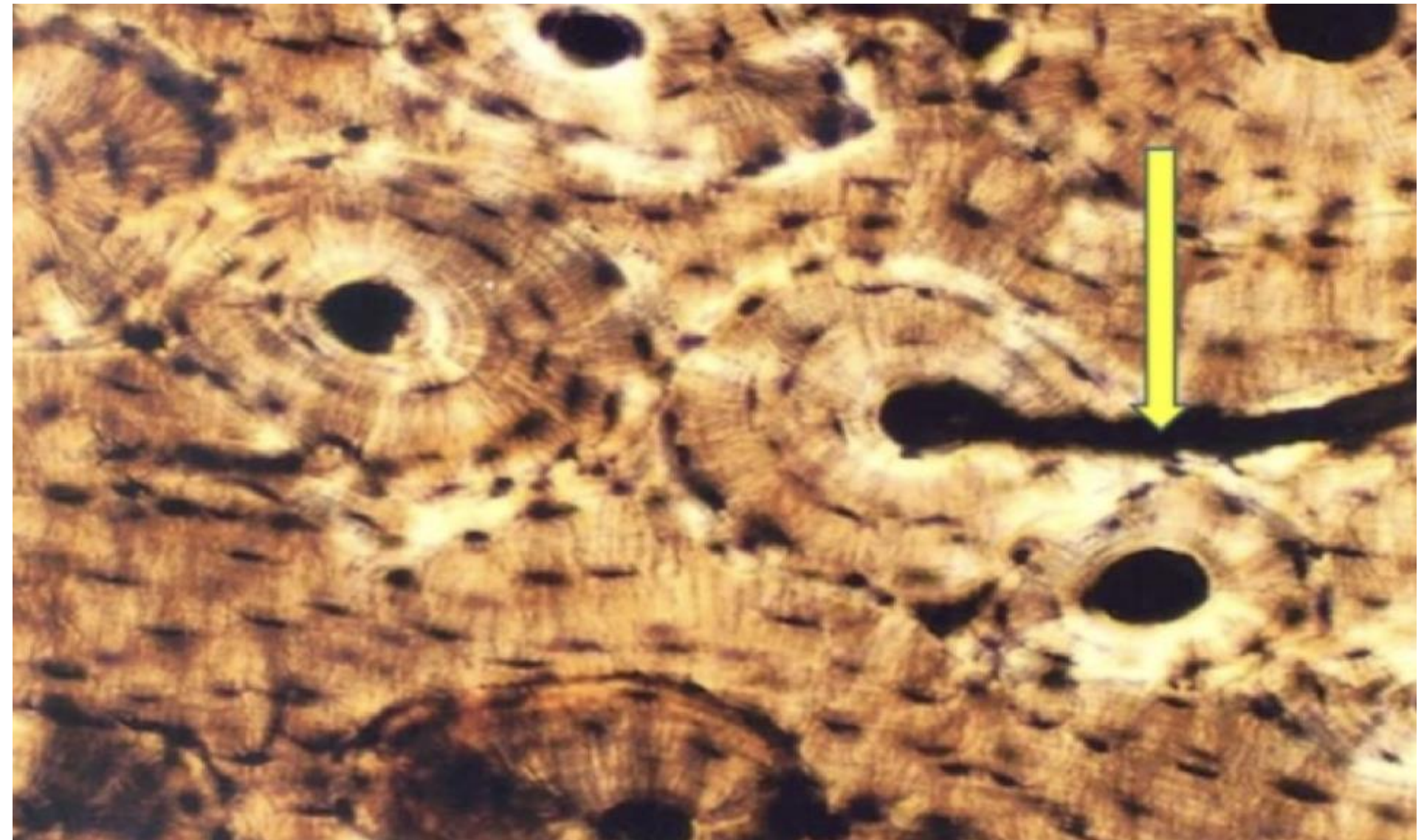
- A) Elastic cartilage.
- B) Hyaline cartilage.
- C) Fibrocartilage.
- D) Brown adipose tissue.



Ans: A

Question : Identify the yellow labeled structure:

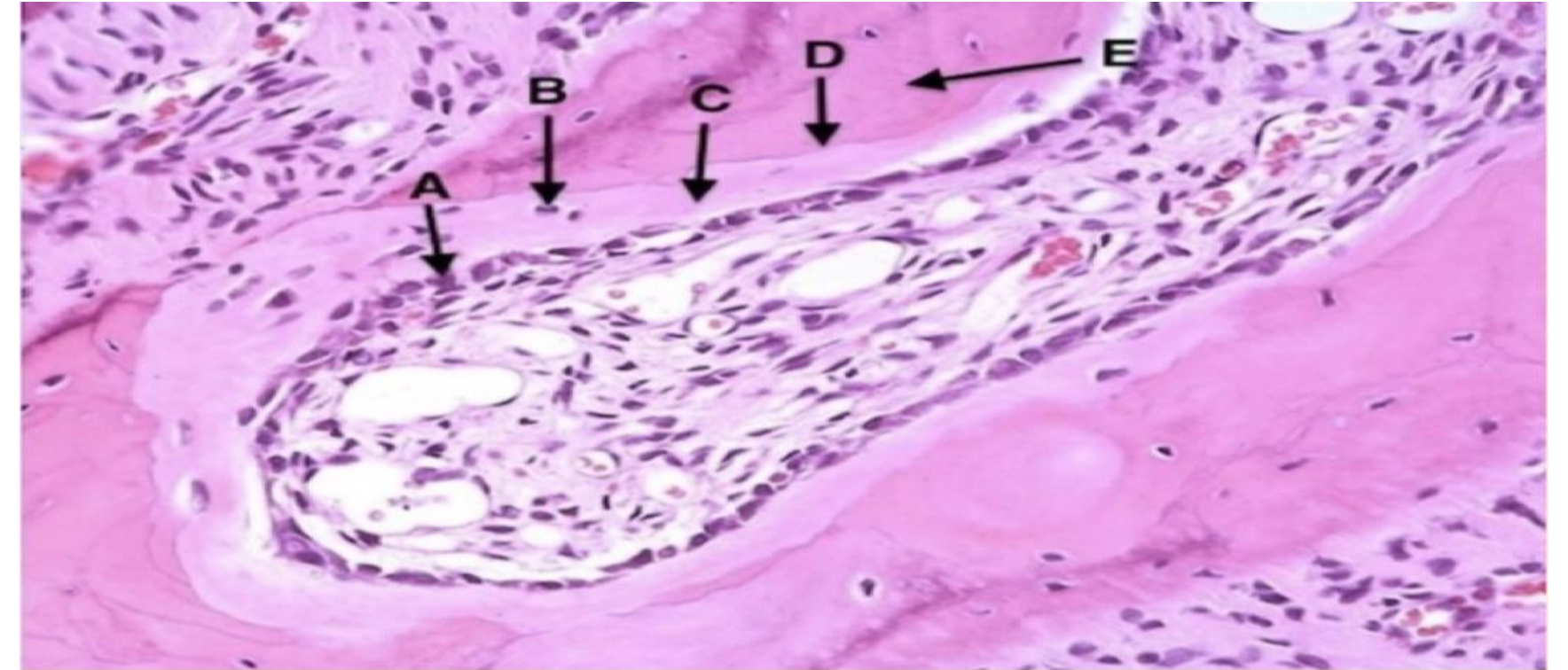
- A) Lamella
- B) Central canal
- C) Lacuna
- D) Volkmann's canal
- E) Osteon



Ans: D

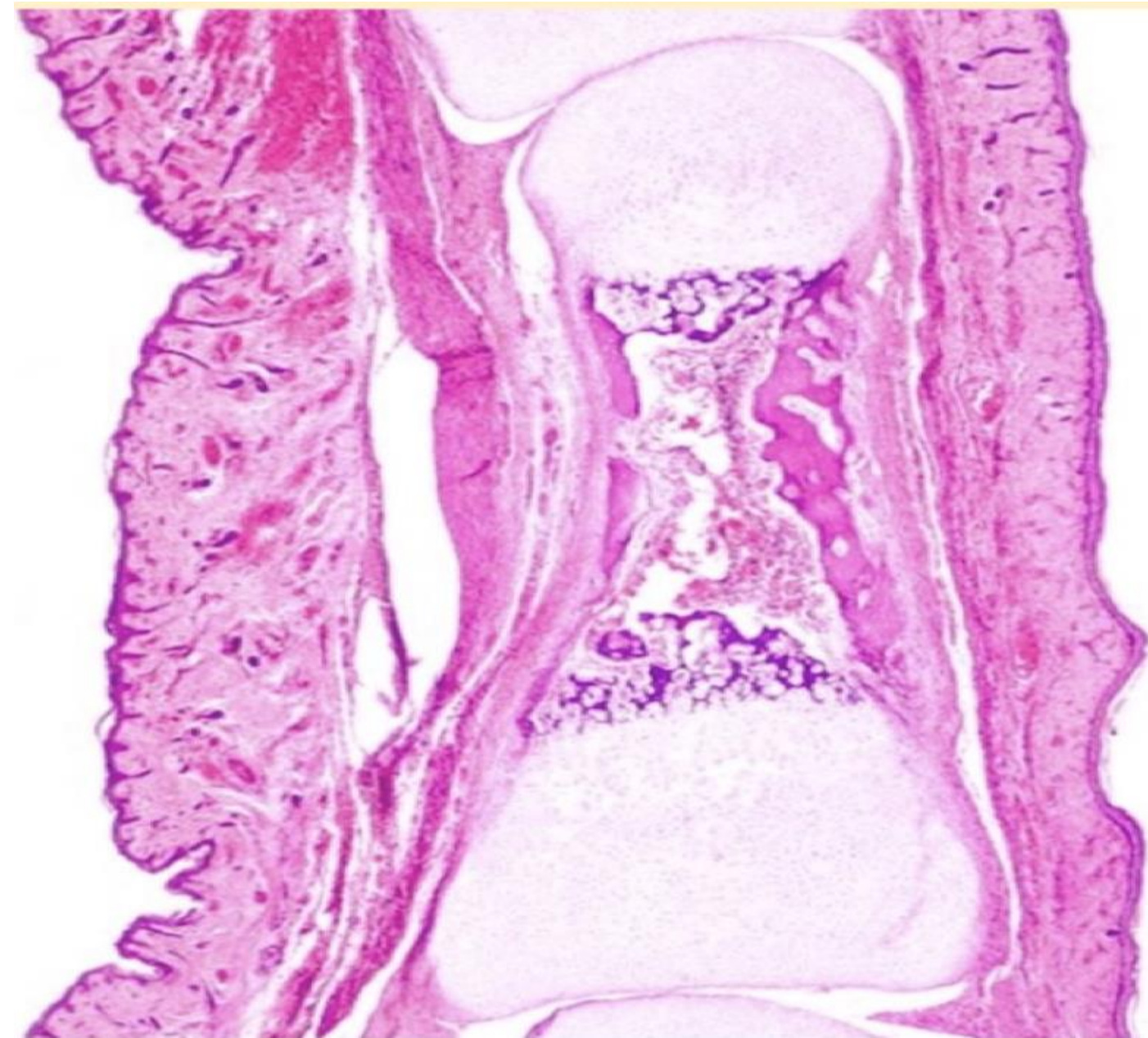
Question : Choose the **WRONG** statement regarding this section:

- A) It is a trabecular bone
- B) Arrow A points at a bone forming cell
- C) It is a decalcified bone section
- D) Arrow B points at a cell located within lacuna
- E) Arrow C points at the mineralized bony matrix



Question : What type of bone formation is taking place?

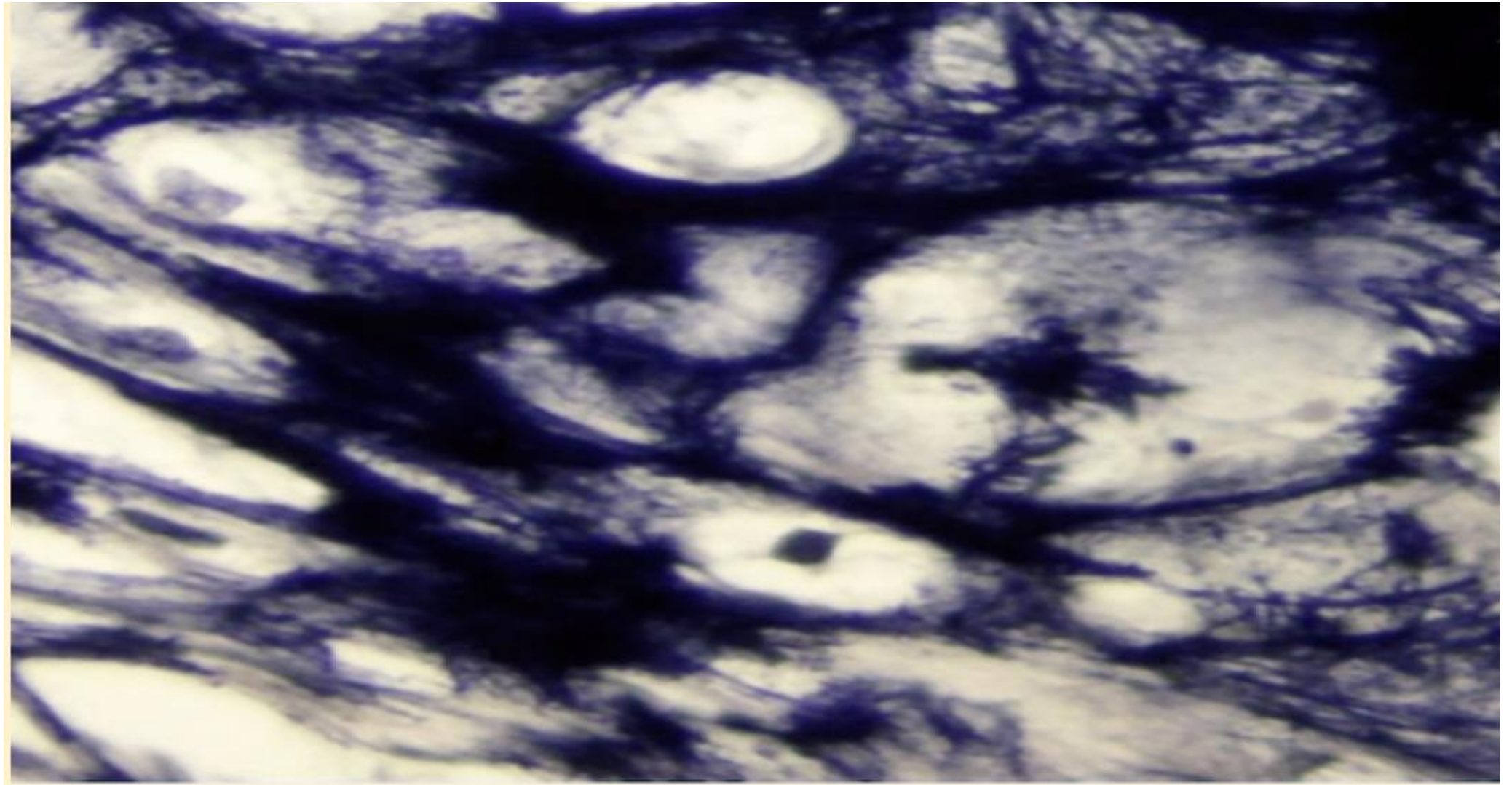
- A) Endochondral ossification
- B) Intramembranous ossification



Ans: A

Question : The black structure in this image is/are:

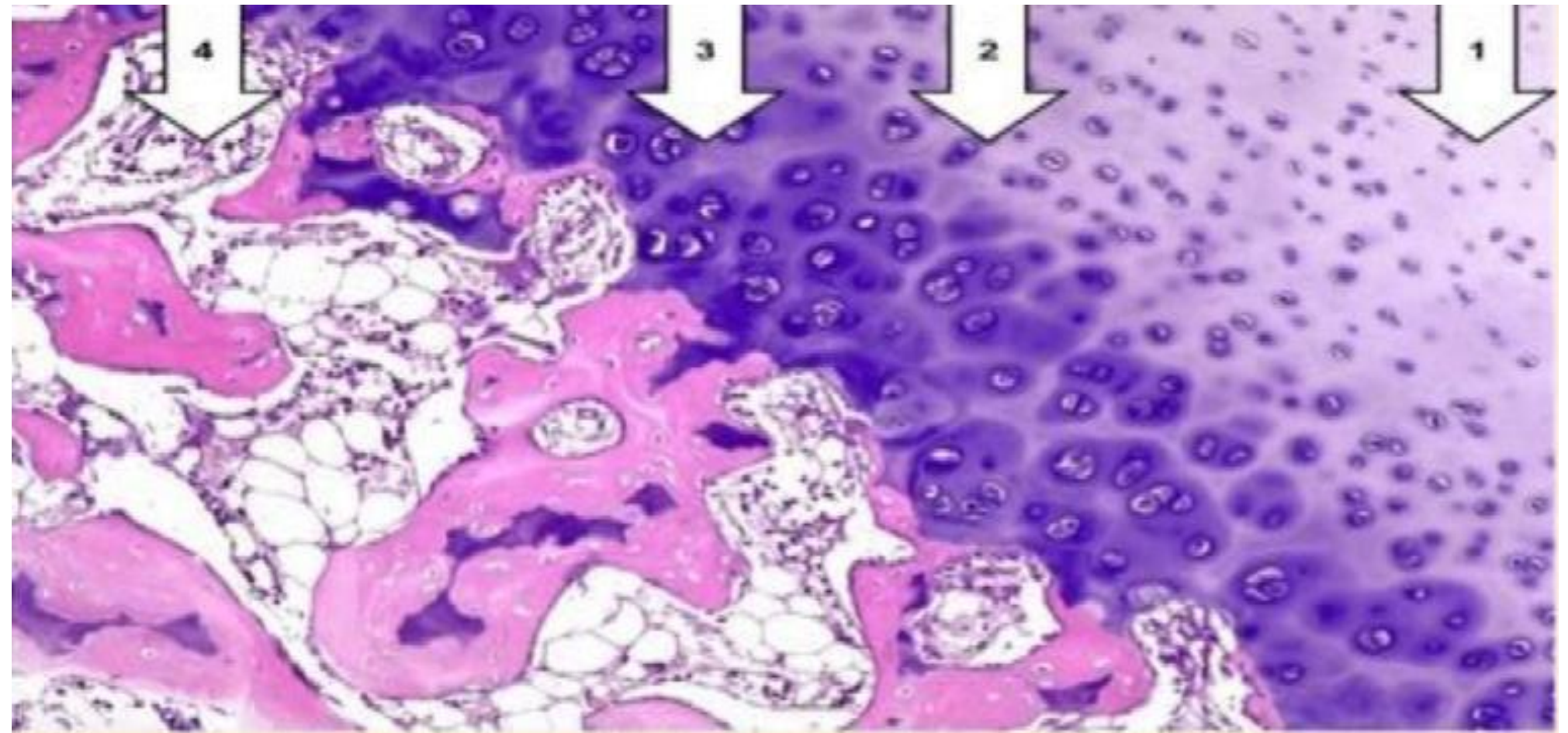
- A) Collagen fibers.
- B) Reticular fibers.
- C) Chondroitin sulfate.
- D) Elastic fibers.



Ans: D

Question : Choose the CORRECT match:

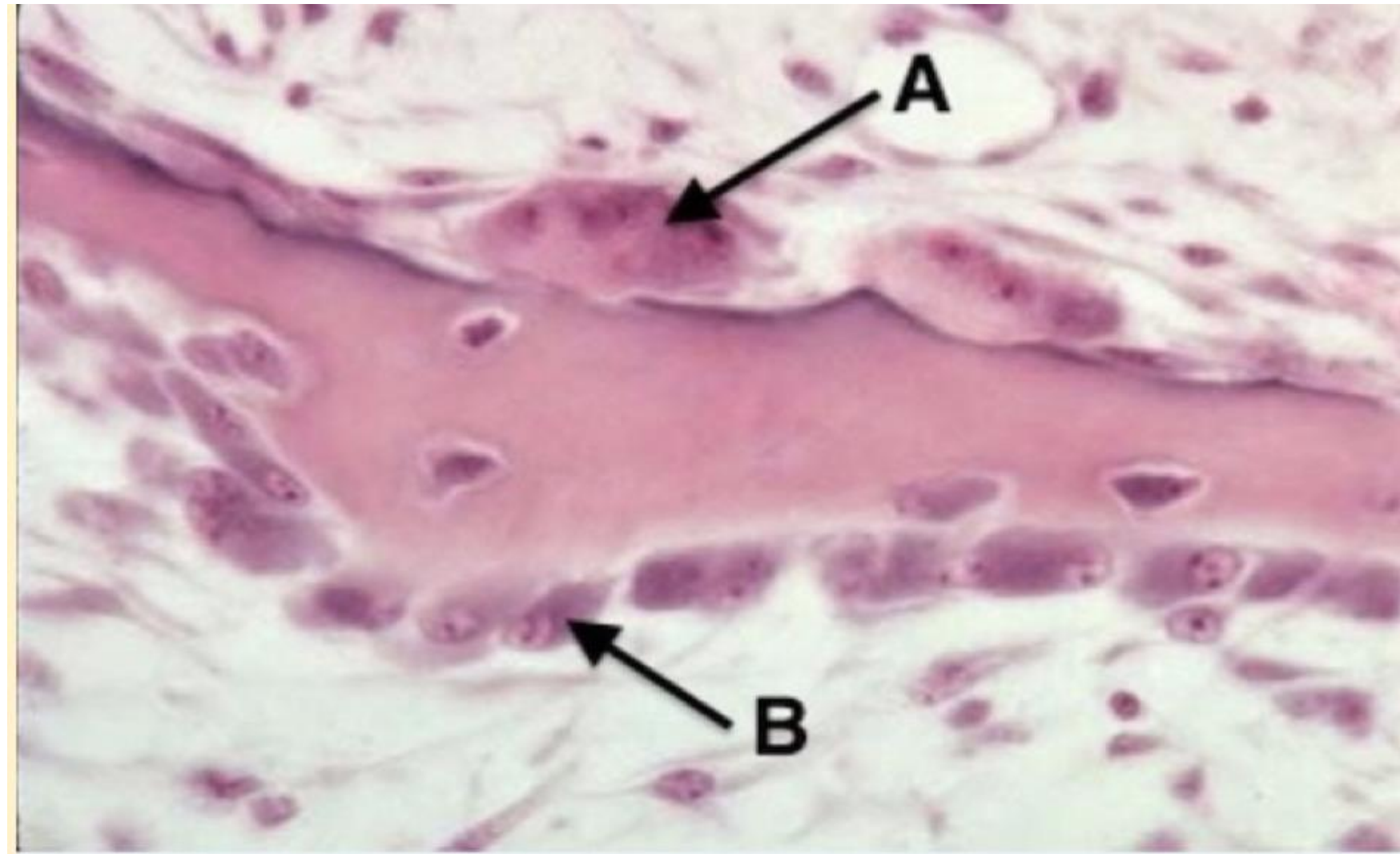
- A) Resting zone: 2
- B) Growth zone: 4
- C) Hypertrophy and calcification: 3
- D) Ossification zone: 1



Ans: C

Question : Identify A:

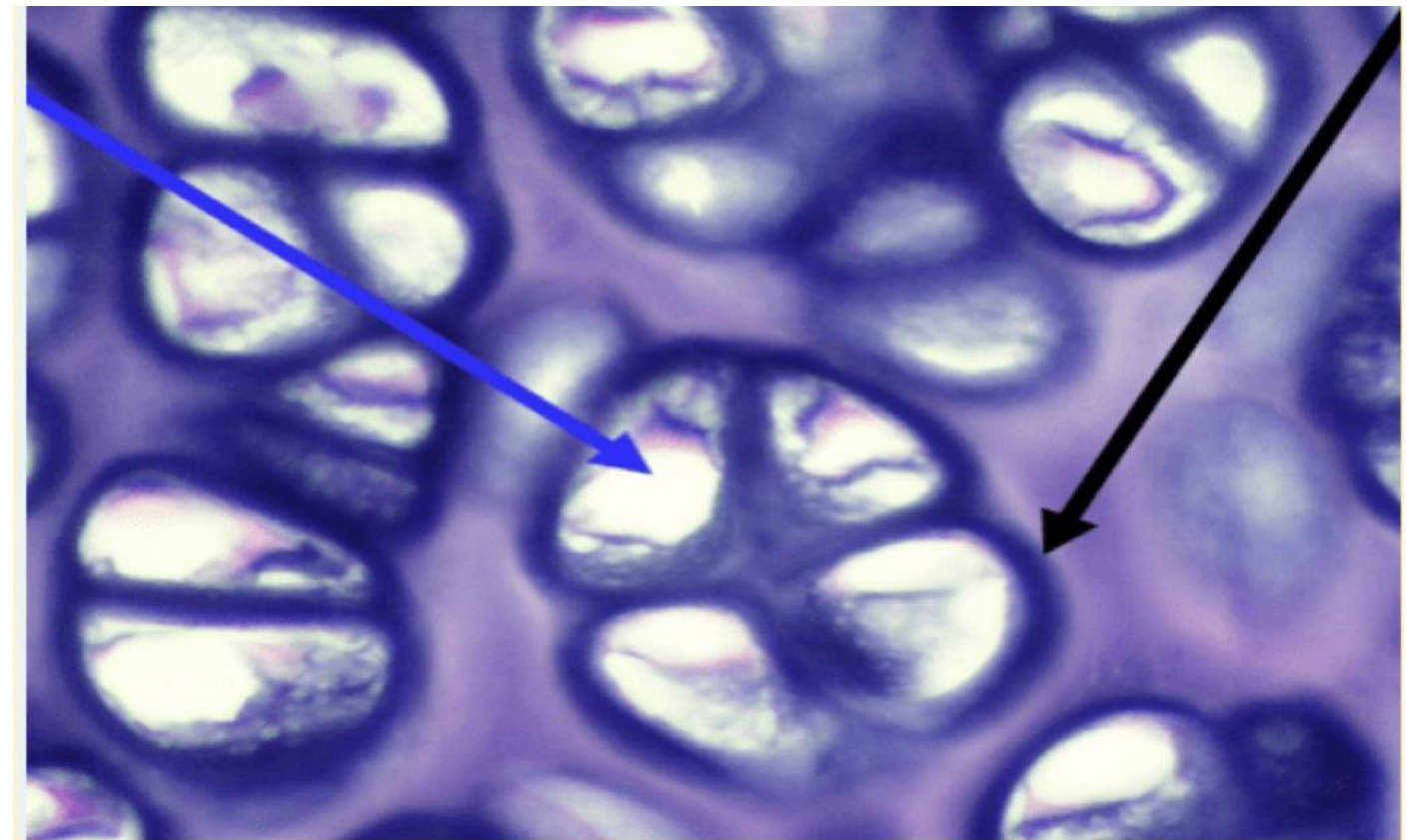
- A) Osteoblast
- B) Chondrocyte
- C) Osteoclast
- D) Fibrocyte
- E) Osteocyte



Ans: C

Question : The blue and black arrows point to, respectively:

- A) The territorial matrix and the interterritorial matrix.
- B) A lacuna and the territorial matrix.
- C) A chondrogenic cell and interterritorial matrix.
- D) A lacuna and a chondrocyte.



Ans: B

Question : Chondrogenic cells are found in:

- A) outer layer of perichondrium
- B) inner layer of perichondrium

Ans: B

Question : Which one is true about bones in terms of vascular its and innervation:

- A) avascular and innervated
- B) Vascular and not innervated
- C) vascular and innervated

Ans: C

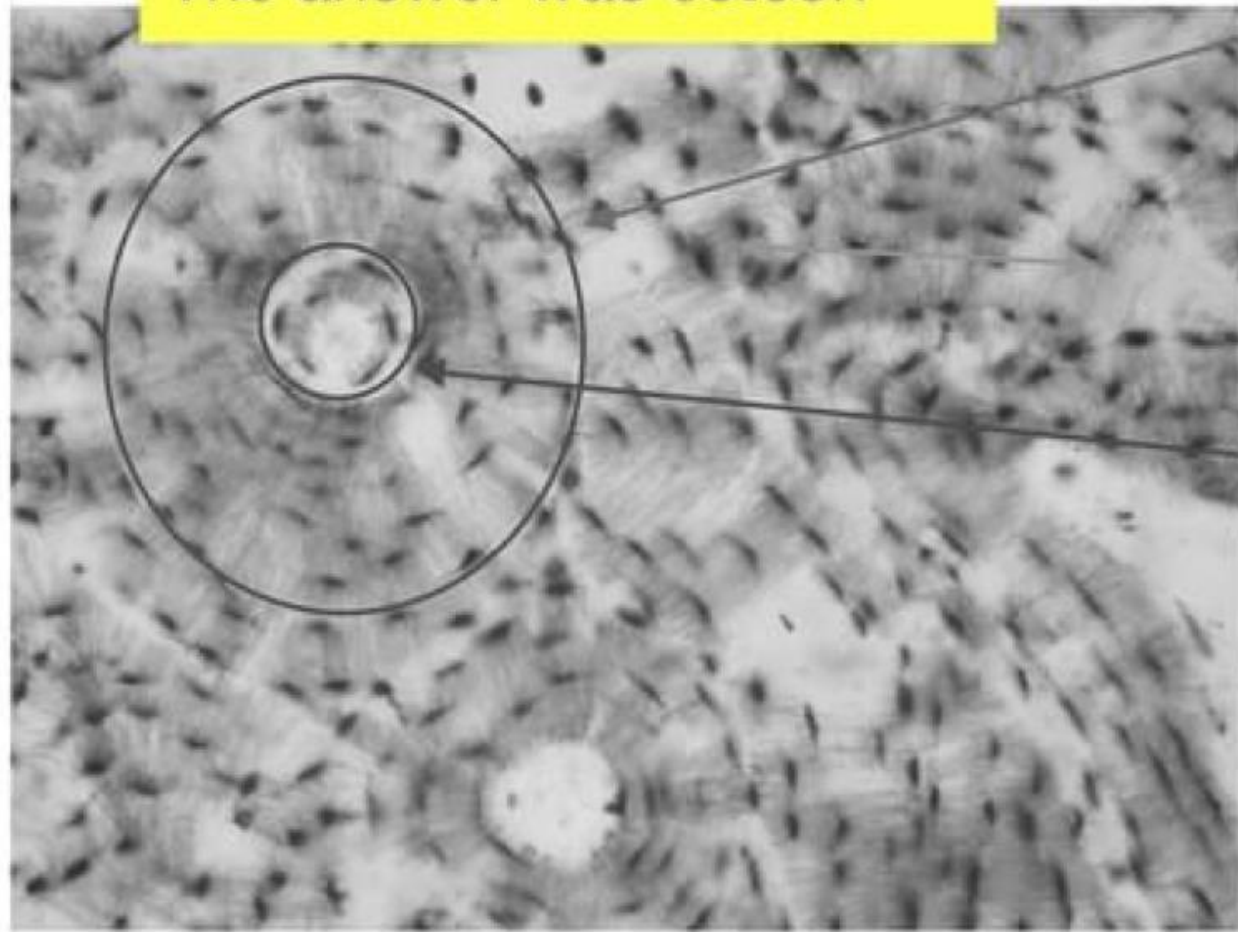
Question : which one is directly deep to periosteum:

- A) external circumferential lamellae
- B) Internal circumferential lamellae
- C) interstitial lamellae

Ans: A

2 Different Questions

Asked about what you see
in this circle
The answer was osteon



During the endochondral ossification where
do osteoblast first appear:

A) perichondrium of the diaphysis

B) بما معناه داخل diaphysis

وكان في خيارين عن epiphysis

Ans:A

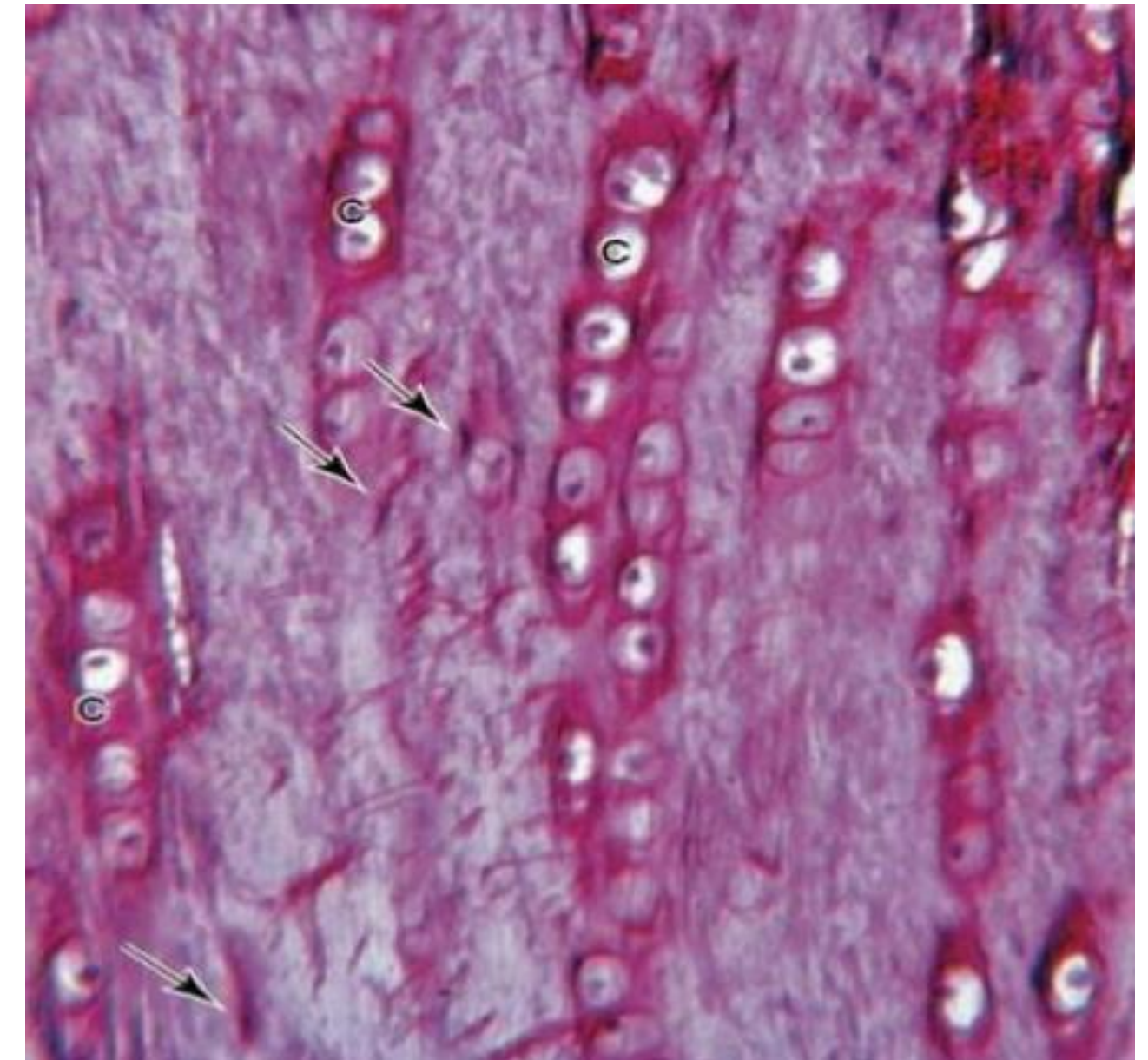
Question : Perichondrium is a:

- A) Loose connective which contains fibroblasts, chondrogenic cells, and other elements.
- B) Reticular connective which contains fibroblasts, chondrogenic cells, and other elements.
- C) Dense connective which contains fibroblasts, chondrocytes, and other elements.
- D) Loose connective which contains chondrocytes, chondrogenic cells, and other elements.
- E) Dense connective which contains fibroblasts, chondrogenic cells ,and other elements

Ans: E

Question : which type of Cartilage ?

- A) elastic cartilage
- B) fibrocartilage
- C) hyaline cartilage
- D) Articular cartilage



Ans: B

Question : How does articular cartilage differ from most other hyaline cartilage?

- A) It undergoes mainly appositional growth.
- B) It contains isogenous groups of chondrocytes.
- C) It lacks a perichondrium
- D) Its matrix contains aggrecan.
- E) It is derived from embryonic mesenchyme

Ans: C

Question : Which step occurs first in chondrogenesis?

- A) Appositional growth
- B) Conversion of chondroblasts to chondrocytes
- C) Formation of mesenchymal condensations
- D) Interstitial growth
- E) Secretion of collagen-rich and proteoglycan-rich matrix

Ans: C

Question : What distinguishes cartilage from most other connective tissues?

- A) Its extracellular matrix is rich in collagen.
- B) Its predominant cell type is a mesenchymal derivative.
- C) Its predominant cell type secretes both fibers and proteoglycans.
- D) It lacks blood vessels
- E) It functions in mechanical support.

Question : A 28-year-old woman visits the family medicine clinic complaining of loss of the sense of smell, nosebleeds, problems with swallowing, and hoarseness. She admits to “casual, social use” of cocaine on a regular basis since her sophomore year of college. A complete examination of her nose with a speculum and otoscope shows severe rhinitis (inflammation). There is also perforation and collapse of the nasal cartilage resulting in a “saddle nose” deformity. Erosions in the enamel of her front-teeth are noted. The breakdown of the nasal cartilage releases collagen fibers primarily of which type?

- A) Type I
- B) Type II
- C) Type III
- D) Type IV
- E) Type VII

Ans: B

Question : Which component of bone impedes the distribution of nutrients and oxygen to osteocytes?

- A) ECM
- B) Canaliculi
- C) Periosteum
- D) Cell processes
- E) Haversian canals

Ans:A

Question : Which if the following most accurately describes compact bone?

- A) Predominant bone type in the epiphyses of adult long bones
- B) Also known as cancellous bone
- C) Characterized by the presence of osteons
- D) Lines the medullary (marrow) cavity
- E) Forms the dipole in cranial bones

Question : Hydroxyapatite crystals are made mainly from the combination of:

- A) Collagen type 1 fibers and carbon molecules
- B) Calcium, phosphate and collagen type 1 fibers
- C) Calcium and phosphate
- D) Chondroitin sulfate and inorganic salts
- E) Glycoproteins and vitamin D

Ans:C

Question : All of the following statements about bone cells are correct EXCEPT:

- A) Osteoblasts produce type I collagen
- B) Osteocytes are often grouped in nests inside lacunae as a result of earlier mitoses
- C) Osteoblasts are mononucleate cells
- D) Osteoclasts form the ruffled border that opposes the surface of the bone tissue
- E) Some osteoblasts turn into osteocytes while the new bone is being formed

Ans: B

Question : All the followings can be found in the ossification zone EXCEPT:

- A) Chondrocyte within lacunae
- B) Osteocyte within lacunae
- C) Primary bone
- D) Calcified matrix of the cartilage
- E) Osteoblasts

Question : Osteocytes maintain contact with the blood vessels of the central canal through:

- A) Concentric lamellae
- B) Interstitial lamellae
- C) Canaliculi
- D) Perforating fibers
- E) Periosteum

Ans: C

Question : Several layers of cells reside within epiphyseal plates of developing long bones. Which statement best describes the ossification zone?

- A) Cells enlarging and causing the cartilaginous matrix to become calcified
- B) Resting cells
- C) Cells undergoing mitosis and forming long columns of isogenous groups
- D) None of the mentioned
- E) Osteoblasts adhering to the remnants of calcified cartilage matrix and producing woven bone

Question : Woven bone, choose the WRONG statement:

- A) Its collagen fibers are not organized into lamellae
- B) It has a lower mineral content compared to secondary bone
- C) It is the first bone tissue to appear in embryonic development
- D) It is not degraded by osteoclasts
- E) It is formed during repair of fracture sites

Ans: D

Question : Endochondral ossification, choose the CORRECT statement:

- A) process of bone formation involving the replacement of a fibrous membrane
- B) Found in long bones after the closure of the epiphyses
- C) Starts postnatally
- D) Typical of the development of the clavicle
- E) In long bones, the first site of ossification occurs in the middle of diaphysis

Question : Which structure covers the cartilage and supplies it with nutrients through diffusion?

- A) Cartilage matrix
- B) Periosteum
- C) Anulus fibrosis of intervertebral disc
- D) Perichondrium
- E) Cartilage lacuna

Ans: D

Question : Which of the following structures represent small spaces that are hosting clusters of chondrocytes within the elastic cartilage?

- A) Osseous spiral lamina of cochlea
- B) Cartilage matrix
- C) Periosteum
- D) Cartilage lacuna
- E) Perichondrium

Ans: D

Question : Regarding Endosteum, choose the **WRONG** statement:

- A) Covers trabeculae of spongy bone
- B) Is composed of a single layer of cells
- C) Is attached to bone trabeculae by Sharpey's fibers
- D) Is involved in bone growth in width
- E) Lines the internal cavity of the bone

Question : In epiphyseal plate growth, what happens when the zone of ossification overtakes the zone of resting cartilage?

- A) The hyaline cartilage of the plate is replaced by bone
- B) Longitudinal growth of the bone terminates (at least at one end)
- C) The epiphyseal plate becomes the epiphyseal line
- D) The diaphysis and epiphysis portions of the bone fuse together to form a single adult bone
- E) All of the mentioned

Ans: E

Question : which type of Cartilage has NO perichondrium ?

- A) elastic cartilage
- B) Fibrocartilage
- C) hyaline cartilage

Ans: B

Question : Fibrocartilage found in except ?

- A) intervertebral discs
- B) Pubic symphysis
- C) Respiratory tract
- D) certain ligaments

Ans: C

Question : Which structures are found in the perichondrium and responsible for the production of cartilage?

Q153

- A) Chondroblast
- B) Epiphyseal plate
- C) Nucleus of chondrocyte
- D) Cartilage lacuna
- E) Cartilage matrix

Ans: A

Question : Which of the following tissues most frequently calcifies with age?

Q154

- A) Loose connective tissue
- B) Brown adipose tissue
- C) Fibrocartilage
- D) Elastic cartilage
- E) Hyaline cartilage

Ans: E

Question : Which of the following statements characterizes osteoclasts?

- A) They are enucleated cells.
- B) They produce collagen.
- C) They secrete osteoid.
- D) They are derived from osteoprogenitor cells.
- E) They occupy Howship lacunae

Ans: E

Question : Which structure surrounds the chondrocytes and contains high concentrations of proteoglycans?

- A) Territorial matrix
- B) Calcified layer
- C) Interterritorial matrix
- D) Cartilage matrix

Question : Which of the following tissues forms the rings of trachea?

- A) Subepicardial connective tissue
- B) Fibrocartilage
- C) Subcutaneous tissue
- D) Bone tissue
- E) Hyaline cartilage of trachea

Ans: E

Question : What are the clusters of chondrocytes situated within one lacuna of the cartilage called?

- A) Isogenous group of chondrocytes
- B) Cartilage matrix
- C) Fibroblast
- D) Perichondrium

Ans: A

Question : What is the name of the basic functional unit of the bone that consists of concentric lamellae of osteocytes surrounding one Haversian canal?

- A) Osteon
- B) Bony trabecula
- C) Periosteum

Question : What is the name of the delicate network of spongy bone surrounding the bone marrow in the medullary cavity?

- A) Interstitial lamellae
- B) Concentric lamellae of osteon
- C) Periosteum
- D) Bony trabecula
- E) Circumferential lamellae

Ans: D

Question : What is the name of the individual circular layers of osteocytes surrounding the Haversian canals in the lamellar bone tissue?

- A) Osteon
- B) Interstitial lamellae
- C) Bony trabecula
- D) Osteoid
- E) Concentric lamellae of osteon

Ans: E

Question : Which of the following structures runs parallel to the bone surface in the center of the osteon, containing small blood vessels and nerves?

- A) Bone canaliculus
- B) Perforating canal (of Volkmann)
- C) Central canal of osteon
- D) Endosteum
- E) Bone marrow

Ans: C

Question : Which of the following structures runs transversely to the bone surface and interconnects the Haversian canals, allowing the small blood vessels running through them to anastomose?

- A) Bone canaliculus
- B) Bony trabecula
- C) Central canal of osteon
- D) Cartilage lacuna
- E) Perforating canal (of Volkmann)

Question : Which of the following structures contain the processes of osteocytes and connect the individual lacunae found in the lamellar bone tissue?

- A) Bone canaliculus
- B) Bony trabecula
- C) Osteoid
- D) Central canal of osteon
- E) Interstitial lamellae

Ans: A

Question : Which one of the following statements is correct concerning the periosteum?

- A) It is devoid of a blood supply.
- B) It produces osteoclasts.
- C) It is responsible for interstitial bone growth
- D) Its inner layer contains osteoprogenitor cells.
- E) Its outer layer is devoid of fibers.

Ans: D

Question : Which one of the following statements is characteristic of osteocytes?

- A) They communicate via gap junctions between their processes.
- B) They contain large amounts of RER.
- C) They are immature bone cells.
- D) They are housed as isogenous groups in lacunae.
- E) They give rise to osteoclasts.

Ans: A

Question : Which one of the following statements concerning hyaline cartilage is correct?

- A) It is vascular.
- B) It contains type IV collagen.
- C) It undergoes appositional growth only.
- D) It is located at the articular ends of long bones.
- E) Its chondrocytes are aligned in rows.

Ans: D

Question : A 7-year-old boy is seen by his pediatrician because the child broke his humerus as he tripped and fell while walking. The pediatrician asked about the child's diet and learned that he might have a dietary deficiency. Which of the following may be lacking in his diet?

- A) Potassium
- B) Calcium
- C) Iron
- D) Carbohydrates
- E) Protein

Ans: B

Question : What is the fundamental functional unit of bone?

- A) Osteophyte
- B) Chondrocyte
- C) Haversian canal
- D) Osteocytes
- E) Osteon

Ans: E

Question : All EXCEPT which of the following choices refer to the same type of bone?

- A) Trabecular bone
- B) Compact bone
- C) Cancellous bone
- D) All the choices provided refer to the same type of bone.
- E) Spongy bone

Question : Which of the following statements is characteristic of bone?

- A) Bone matrix contains primarily type II collagen.
- B) About 65% of the dry weight of bone is organic.
- C) Haversian canals are interconnected via Volkmann canals.
- D) Bone growth occurs via interstitial growth only.
- E) Bone growth occurs via appositional growth only

Question : The molecular basis for the shock absorbing properties of cartilage involves which of the following?

- A) Electrostatic interaction of proteoglycans with type IV collagen
- B) Ability of glycosaminoglycans to bind anions
- C) Non-covalent binding of glycosaminoglycans to protein cores
- D) Sialic acid residues in the glycoproteins
- E) Hydration of glycosaminoglycans

Question : What distinguishes cartilage from most other connective tissues?

- A) Its extracellular matrix is rich in collagen.
- B) Its predominant cell type is a mesenchymal derivative.
- C) Its predominant cell type secretes both fibers and proteoglycans.
- D) It lacks blood vessels.
- E) It functions in mechanical support

Question : Which feature is typical of elastic cartilage?

- A) Primary skeletal tissue in the fetus
- B) No identifiable perichondrium
- C) Found in intervertebral discs
- D) Most widely distributed cartilage type in the body
- E) Collagen is mainly type II

Ans: E

Question : Which area in cartilage is relatively collagen-poor and proteoglycan-rich?

- A) Fibrocartilage
- B) Territorial matrix
- C) Epiphyseal plate
- D) Interterritorial matrix
- E) Perichondrium

Ans: B

Question : What is the source of the mesenchymal progenitor cells activated for the repair of hyaline cartilage of accident-damaged costal cartilages?

- A) Perichondrium
- B) Adjacent loose connective tissue
- C) Bone of the adjacent rib(s) and sternum
- D) Chondrocytes of the injured cartilage
- E) Stem cells circulating with blood

Ans: A

Question : Which “zone” of endochondral ossification in the growing femur of an adolescent is the farthest from that bone’s secondary ossification center?

- A) Zone of proliferation
- B) Zone of hypertrophy
- C) Zone of reserve cartilage
- D) Zone of ossification
- E) Zone of calcified cartilage

Ans: D

Question : How does articular cartilage differ from most other hyaline cartilage?

- A) It undergoes mainly appositional growth.
- B) It contains isogenous groups of chondrocytes.
- C) It lacks a perichondrium.
- D) Its matrix contains aggrecan.
- E) It is derived from embryonic mesenchyme

Question : Which step occurs first in chondrogenesis?

- A) Appositional growth
- B) Conversion of chondroblasts to chondrocytes
- C) Formation of mesenchymal condensations
- D) Interstitial growth
- E) Secretion of collagen-rich and proteoglycan-rich matrix

Ans: C

Question : In healthy bone canaliculi are likely to contain which one of the following?

- A) Capillaries
- B) Nerve axons
- C) Osteocytic processes
- D) Osteoid
- E) Osteoclasts in resorption lacunae

Ans: C

Question : In the diaphysis of a typical long bone which of the following structures is in closest proximity to the trabeculae of cancellous bone?

- A) Interstitial lamellae
- B) Osteons
- C) Sharpey fibers
- D) Outer circumferential lamellae
- E) Inner circumferential lamellae

اللهم وفقني في دراستي وكن لي عوناً معيناً، اللهم
إني أسألك درجاتٍ تشرحُ صدري وتُفرح قلبي.

NERVOUS TISSUE

Question : which the of the following cell types lines the central canal of spinal cord and the ventricular system of the brain ?

- A) Microglia
- B) Oligodendrocytes
- C) Ependymal cells
- D) Astrocytes
- E) Schwann cells

Ans:C

Question : Ganglia of nervous system, choose the correct statement:

- A) Cells of autonomic ganglia are pseudounipolar neurons
- B) Autonomic ganglia are masses of neuronal cell bodies of postganglionic neurons
- C) Cells of sensory ganglia are multipolar neurons
- D) Sensory ganglia contain synapse
- E) Autonomic ganglia do not contain synapse

Question : Schwann cells are characterised by the following
Except:

- A) Each Schwann cell myelinated only internodal segment of one axon
- B) They are interrupted by nodes of Ranvier
- C) They play a role in regeneration of axons in peripheral nervous system
- D) They are similar in function to astrocytes of central nervous system
- E) They support both myelinated and unmyelinated axons in the peripheral nervous system

Ans: D

Question : Neuroglial cells ,choose the WRONG statement

- A) Are smaller in size compared to neurons
- B) Are not able to transmit nervous impulses
- C) Are able to undergo mitosis
- D) Are found in both peripheral and central nervous systems
- E) Are less numerous compared to neurons

Ans: E

Question : Which of the following is the correct layering of the connective sheaths of a peripheral nerve from the superficial to deep?

- A) Endoneurium,perineurium,epineurium
- B)Perineurium,epineurium,endoneurium,
- C) Epineurium,endoneurium,perineurium
- D) Epineurium,perineurium,endoneurium
- E) Epineurium,endoneurium,perineurium

Ans: D

Question : The neuron conducting an impulse from the stomach wall to the central nervous system would be classified as a:

- A) Somatovisceral
- B) Visceral afferent
- C) Visceral efferent
- D) Somatic afferent
- E) Somatic efferent

Ans: B

Question : The axon hillock is found at:

- A) Schwann cells
- B) The dendrites
- C) The end of the axon
- D) The origin of the axon

Question : Small cells closely associate with neurons in peripheral ganglia are:

- A) Schwann cells
- B) Satellite cells
- C) Microglial
- D) Ependymal cells
- E) Oligodendrocyte

Ans: B

Question : Regarding Axons, choose the wrong statement:

- A) Are mostly myelinated
- B) Conduct impulse away from perikaryon
- C) Are longer than dendrites
- D) Their cytoplasm is similar in composition to the cytoplasm of cell bodies

Question : Choose the wrong match:

- A) Epineurium:dense connective tissue
- B) Motor neurons :multipolar
- C) Anaxonic neuron: lack true axon
- D) Neuron : no centrioles
- E) Anterograde axonal transport: movement toward soma

Question : Regarding dendrites, choose the correct:

- A) Are usually myelinated
- B) Are tapering processes
- C) Are usually longer than the axon
- D) Conduct the impulses away from the perikaryon
- E) Are less numerous than axon

Ans: B

Question : Nissan bodies consist of ?

- A) Cluster of synthetic vesicles
- B) Golgi bodies
- C) Rough endoplasmic reticulum and ribosomes
- D) Lysosomes and lipofuscin granules
- E) Microtubules and microfilaments

Ans: C

Question : Nervous tissue ,choose the correct statement:

- A) Motor and sensory inner actions of viscera are mediated by somatic nervous system
- B) The ventral ramus of a spinal nerve is typically motor while the dorsal ramus is sensory
- C) Bundle of axons within peripheral nervous system is called tract
- D) Schwann cells support both myelinated and unmyelinated axons in the peripheral nervous system
- E) Basophilic granular structure within the axon are called Nissl bodies

Ans: D

Question : Which of the following neuroglial cells participate in the formation of blood brain barrier

- A) Microglial
- B) Satellite
- C) Oligodendrocytes
- D) Astrocytes
- E) Schwann cells

Ans: D

Question : Motor neurons are classified as

- A) Unipolar
- B) Bipolar
- C) Multipolar
- D) Pseudounipolar
- E) Unipolar After birth

Ans: B

Question : The myelin forming cells in central nervous system are:

- A) Schwann cells
- B) Oligodendrocytes
- C) Microglial
- D) Astrocytes
- E) Satellite cells

Ans: B

Question : Typical peripheral mixed nerve includes all of the following EXCEPT:

- A) Connective tissue of epineurium, perineurium, endoneurium
- B) Sensory axons
- C) Interneurons
- D) Schwann cells
- E) Motor axons

Ans: C

Question : Structure extending the length of the axon which provide the substrate for axoplasmic transport are the:

- A) Nissl bodies
- B) Synaptic vesicles
- C) Schwann cells
- D) Nodes of Ranvier
- E) Microtubules

Ans: E

Question : What term applies to collection of neuronal cell bodies (somata) in the central nervous system?

- A) Ganglia
- B) Neuroglia
- C) Nodes
- D) White matter
- E) Nuclei

Ans: E

Question : regarding dendrites, choose the correct :

- a) are usually the myelinated
- b) Are tapering processes
- C)are usually longer than the axons
- D)Conduct the impulses away from the perikaryon
- E)are less numerous than axon

Ans: b

Question : The outermost layer of dense irregular connective tissue surrounding a peripheral nerve is called:

- A) Endoneurium
- B) Fascicle
- C) Epineurium
- D) Septum
- E) perineurium

Question : The outermost layer of dense irregular connective tissue surrounding a peripheral nerve is called :

- A) Endoneurium
- B) Fascicle
- C) Epineurium
- D) Septum
- E) Perineurium

Ans C

Question : Ganglia of peripheral nervous system, choose the CORRECT statement:

- A) Cell bodies of motor neurons are located in the ventral root of spinal nerve
- b) Sensory ganglia contain synapse
- c) Autonomic ganglia are located in the dorsal root of spinal nerve
- D) Sensory ganglia contain cell bodies of pseudounipolar neurons
- E) Sympathetic ganglia do not contain synapse

Question : The myelin forming cells in central nervous system are:

- A) Schwann cells
- b) Oligodendrocytes
- C) Microglia
- D) Astrocytes
- E) Satellite cells

Question : Neuroglial cells, choose the CORRECT statement:

- A) Are less numerous than neurons
- b) Are not able to divide
- c) Are found in both peripheral and central nervous systems
- d) Are able to transmit nervous impulses
- E) Are larger in size than neurons

Ans: C

Question : Motor neurons are classified as:

- a) Unipolar OR pseudounipolar
- B) Bipolar
- C) Multipolar
- D) Pseudounipolar
- E) Unipolar After birth

Question : Which of the following neuroglial cells participate in the formation of blood brain barrier:

- A) Microglia
- B) Satellite cells
- C) Oligodendrocytes
- D) Astrocytes
- E) schwann cells

Question : Nervous tissue, choose the CORRECT statement : **Q27**

A) Motor and sensory innervations of viscera are mediated by somatic nervous system

B) The ventral ramus of a spinal nerve is typically motor while the dorsal ramus is sensory

c) Bundle of axons within peripheral nervous system is called tract

D) Schwann cells support both myelinated and unmyelinated axons in the peripheral nervous system

E) Basophilic granular structures within the axon are called Nissl bodies

Ans: D

Question : Structures extending the length of the axon which provide the substrate for axoplasmic transport are the :

- a) Nissl bodies
- b) Synaptic vesicles
- c) Schwann cells
- d) Nodes of Ranvier
- E) Microtubules

Question : Nissl bodies consist of ?

- a) Clusters of synaptic vesicles
- b) Golgi bodies
- c) Rough endoplasmic reticulum and ribosomes
- D) Lysosomes and lipofuscin granules
- E) Microtubules and microfilaments

Question : A typical peripheral mixed nerve includes all of the following EXCEPT:

- A) Connective tissue of epineurium, perineurium and endoneurium
- B) Sensory axons
- C) Interneurons
- D) Schwann cells
- E) Motor axons

Question : The cell that produce myelin sheath in CNS:
ANSWER: Oligodendrocyte.

Question : Ganglia of peripheral nervous system, choose the CORRECT statement:

Q32

- a) Autonomic ganglia are located in the dorsal root of spinal nerve
- b) Sympathetic ganglia do not contain synapse
- c) Sensory ganglia contain cell bodies of pseudounipolar neurons
- d) Cell bodies of motor neurons are located in the ventral root of spinal nerve
- e) Sensory ganglia contain synapse

Ans: C

Question : Neuroglial cells, choose the CORRECT statement: **Q33**

- a) Are able to transmit nervous impulses
- b) Are larger in size than neurons
- c) Are less numerous than neurons
- d) Are not able to divide
- e) Are found in both peripheral and central nervous systems

Ans: e

Question : Motor neurons are classified as:

- a) Unipolar and pseudounipolar
- b) Bipolar
- c) Pseudounipolar
- d) Unipolar
- e) Multipolar

Question : Nervous tissue, choose the CORRECT statement:

- a) Schwann cells support both myelinated and unmyelinated axons in the peripheral nervous system
- b) Basophilic granular structures within the axon are called Nissl bodies
- c) The ventral ramus of a spinal nerve is typically motor while the dorsal ramus is sensory
- d) Motor and sensory innervations of viscera are mediated by somatic nervous system
- e) Bundle of axons within peripheral nervous system is called tract

Question : Structures extending the length of the axon which provide the substrate for axoplasmic transport are the:

- a) Synaptic vesicles
- b) Nissl bodies
- c) Schwann cells
- d) Microtubules
- e) Nodes of Ranvier

Question : Nissl bodies consist of:

- a) Golgi bodies
- b) Microtubules and microfilaments
- c) Lysosomes and lipofuscin granules
- d) Rough endoplasmic reticulum and ribosomes
- e) Clusters of synaptic vesicles

Question : A typical peripheral mixed nerve includes all of the following EXCEPT:

- a) Sensory axons
- b) Motor axons
- c) Schwann cells
- d) Connective tissue of epineurium, perineurium and endoneurium
- e) Interneurons

Question : Structures extending the length of the axon which provide the substrate for axoplasmic transport are the:

- a) Nissl bodies
- b) Nodes of Ranvier
- c) Synaptic vesicles
- d) Microtubules
- e) Schwann cells

Question : Nervous tissue, choose the CORRECT statement: **Q40**

- a) The ventral ramus of a spinal nerve is typically motor while the dorsal ramus is sensory
- b) Bundle of axons within peripheral nervous system is called tract
- c) Schwann cells support both myelinated and unmyelinated axons in the peripheral nervous system
- d) Basophilic granular structures within the axon are called Nissl bodies
- e) Motor and sensory innervations of viscera are mediated by somatic nervous system

Ans: a

Question : A typical peripheral mixed nerve includes all the following EXCEPT:

- a) Sensory axons
- b) Motor axons
- c) Schwann cells
- d) Connective tissue of epineurium, perineurium and endoneurium
- e) Interneurons

Question : Which the of the following cell types lines the central canal of the spinal cord and the ventricular system of the brain:

- a) Microglia
- b) Oligodendrocytes
- c) Ependymal cells
- d) Astrocytes
- e) Schwann cells

Question : Schwann cells are characterized by the followings
EXCEPT:

Q43

- a) Each Schwann cell myelinates only one internodal segment of one axon
- b) They are interrupted by nodes of Ranvier
- c) They play a role in regeneration of axons in peripheral nervous system
- d) They are similar in function to astrocytes of central nervous system
- e) They support both myelinated and unmyelinated axons in the peripheral nervous system

Ans: D

Question : Which of the following is the correct layering of the connective sheaths of a peripheral nerve from the superficial to deep:

- a) Endoneurium, perineurium, epineurium
- b) Perineurium, epineurium, endoneurium
- c) Epineurium, endoneurium, perineurium
- d) Epineurium, perineurium, endoneurium
- e) Epineurium, endoneurium, perineurium

Question : The neuron conducting an impulse from the stomach wall to the central nervous system would be classified as a:

- a) Somatovisceral
- b) Visceral afferent
- c) Visceral efferent
- d) Somatic afferent
- e) Somatic efferent

Question : Choose the WRONG match:

- a) Epineurium: dense connective tissue
- b) Motor neurons: multipolar
- c) Anaxonic neuron: lack true axon
- d) Neurons: no centrioles
- e) Anterograde axonal transport: movement toward soma

Question : A sensory ganglion associated with a spinal sensory nerve root is located:

- a) Within the organ it innervates
- b) In a chain external to the spinal column, adjacent to the vertebral bodies
- c) In the dorsal root of spinal nerve
- d) In the ventral horn of spinal cord
- e) Near the peripheral receptor organ (in skin or muscle)

Question : Regarding Axons, choose the WRONG statement:

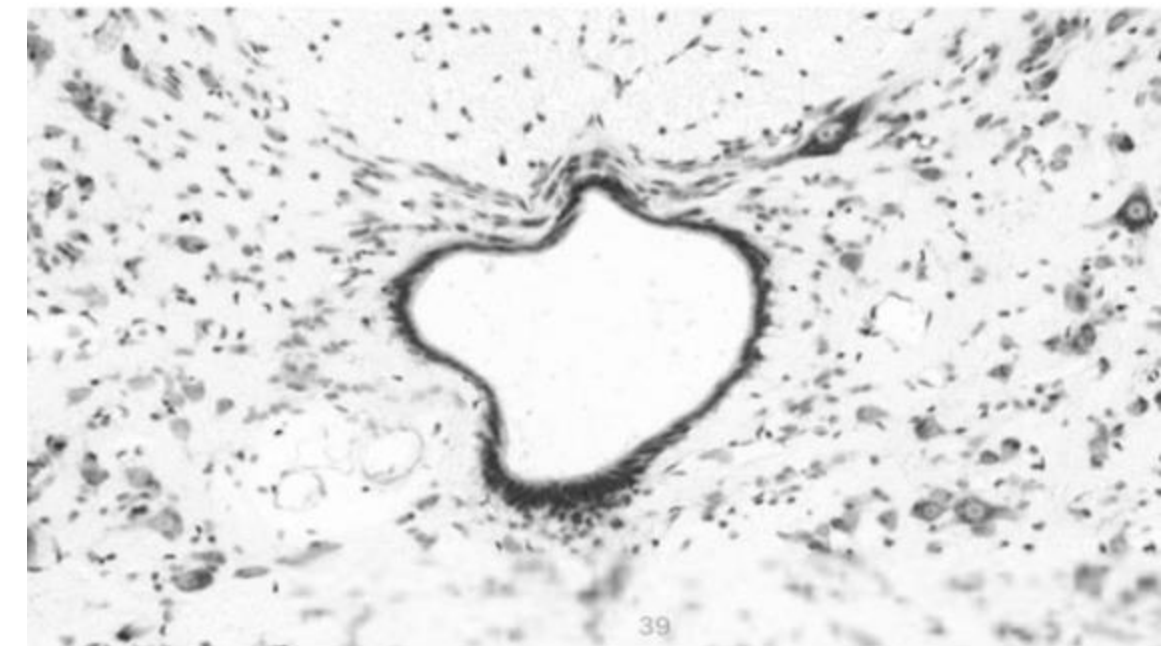
- a) Are mostly myelinated
- b) Conduct impulses away from perikaryon
- c) Are longer than dendrites
- d) Their cytoplasm is similar in composition to the cytoplasm of cell bodies
- e) Have nearly constant diameter

Question : Where are automatic preganglionic cell bodies located:

- A) In the dorsal horn of spinal cord
- B) In the ventral horn of the spinal cord
- C) In the CSF
- D) In certain CNS nuclei and in the lateral horns of the spinal cord
- E) In the target tissue

Question : The attached image represent:

- A) Central canal lined with ependymal cells
- B) Sensory cell bodies located in dorsal root
- C) Astrocyte differentiate from neural tube
- D) Gap junctions in the cardiac muscle
- E) Voluntary contraction of skeletal muscle



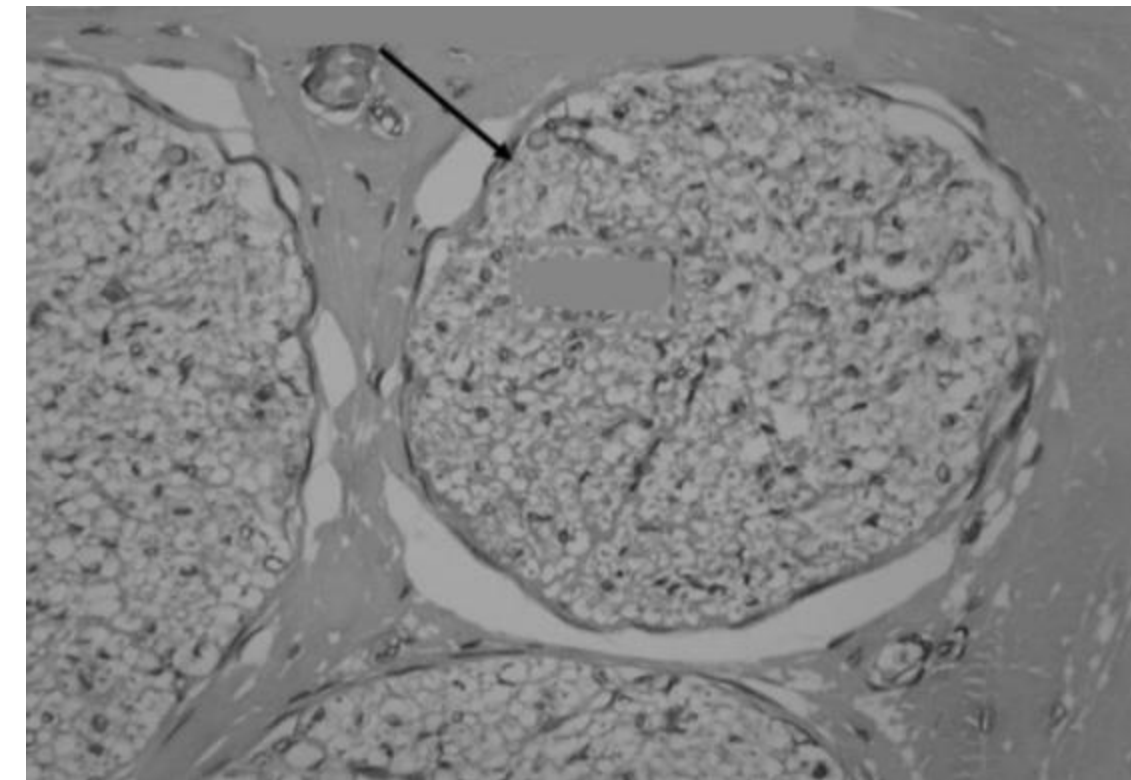
Question : Which of the following statements is not correct regarding spinal cord:

- A) The white matter is peripheral and the gray matter is deeper
- B) The ventral horn contains motor cell bodies
- C) The dorsal horn contains sensory cell bodies
- D) The central canal is continuous with the ventricles of the brain
- E) The central canal is lined by ependymal cells

Ans: C

Question : What structure doesn't exist in the image:

- A) Epineurium
- B) perineurium
- C) Endoneurium
- D) Schwann cells
- E) Astrocyte



Ans: E

Question : what type of neurons present in the a olfactory neuron :

- A) Multipolar
- B) Bipolar
- C) Unipolar
- D) Anaxonic
- E) Motor

Ans: B

Question : what is incorrect about blood brain barrier:

- A) It is present in all CNS cells
- B) It is mainly composed of endothelium
- C) It is not present in the hypothalamus
- D) Protects CNS from bacteria toxins or infection agents
- E) Controls the passage of substances from blood to CNS

Ans: A

Question : which of the following differentiates from mesoderm:

- A) Ependymal cells
- B) Astrocyte
- C) Oligodendrocyte
- D) Glial cells
- E) Microglial cell

Ans: E

Question : Which of the following is not correct:

- A) CSF is present around all CNS
- B) The white matter in the spinal cord is peripheral
- C) CSF is present in the central canal of the spinal cord
- D) Gray matter is abundant in neural cell bodies
- E) pia matter is not directly in contact with the brain tissue

Question : what is correct about meninges

- A) The outermost layer is pia matter
- B) The pia matter is connected directly to neurons
- C) Meninges of the the brain is continuous with the spinal cord
- D) Arachnoid is vascular
- E) Dura is thin

Ans: C

Question : What are the neurotrophins

- A) Neurons & glial cells
- B) Stem cell
- C) Astrocytes
- D) Growth factor
- E) Unmyelinated cells

Ans: D

Question : Which statement is correct about the axon:

- A) Action potential starts in the axon hillock
- B) Abundant of polyribosomes
- C) Don't contain mitochondria
- D) Contain the nucleus and many other organelles
- E) Axons vary in length and diameter

Ans: D

Question : Which of the following doesn't describe neurons:

- A) Large cells
- B) Prominent nucleolus
- C) heterchromatin

Ans: C

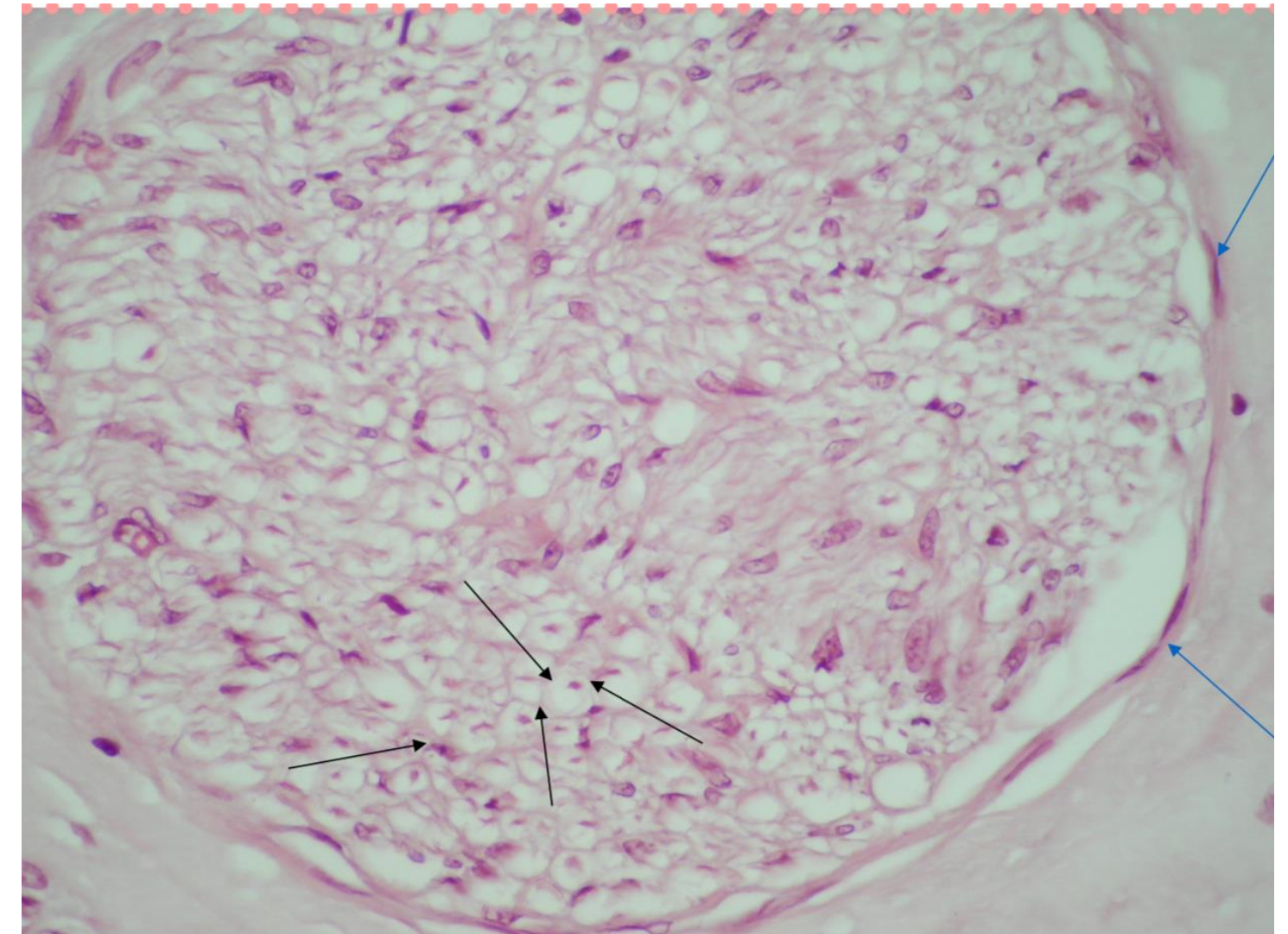
Question : One of the following is incorrect about Astrocytes

- A) Proliferate to fill spaces of died neurons
- B) Contribute in BBB
- C) Don't support neurons

Ans: c

Question : What is the picture represent

- A) Fasicle
- B) Nerve
- C) Epinurium



Ans: A

Question : What type of cell in the picture

A) Multipolar

B) Unipolar

C) Bipolar

D) Anaxonic

Ans: B

Question : Small cells closely associated with neurons in peripheral ganglia are:

- A) Satellite cells
- B) Ependymal cells
- c) Oligodendrocytes
- D) Schwann cells
- E) Microglia

Question : Ganglia of nervous system, choose the CORRECT statement:

- A) a. Sensory ganglia contain synapse
- B) Autonomic ganglia are masses of neuronal cell bodies of postganglionic neurons
- C) Cells of autonomic ganglia are pseudounipolar neurons
- D) Cells of sensory ganglia are multipolar neurons
- E) Autonomic ganglia do not contain synapse

Question : A sensory ganglion associated with a spinal sensory nerve root is located:

- A) Within the organ it innervates
- B) In the ventral horn of spinal cord
- C) Near the peripheral receptor organ (in skin or muscle)
- D) In a chain external to the spinal column, adjacent to the vertebral bodies
- E) In the dorsal root of spinal nerve

Question : Which of the following is the correct layering of the connective sheaths of a peripheral nerve from the superficial to deep?

Q67

- A) Epineurium, endoneurium, perineurium
- B) Endoneurium, perineurium, epineurium
- C) Perineurium, epineurium, endoneurium
- D) Epineurium, perineurium, endoneurium
- E) Epineurium, endoneurium, perineurium

Ans: D

Question : Neuroglial cells, choose the WRONG statement:

Q68

- A) Are able to undergo mitosis
- B) Are not able to transmit nervous impulses
- C) Are smaller in size compared to neurons
- D) Are found in both peripheral and central nervous systems
- E) Are less numerous compared to neurons

Question : Which the of the following cell types lines the central canal of the spinal cord and the ventricular system of the brain?

Q69

- A) Schwann cells
- B) Oligodendrocytes
- C) Astrocytes
- D) Ependymal cells
- E) Microglia

Ans: D

Question : Nervous tissue, choose the CORRECT statement:

Q70

- A) Microtubule and neurofilaments are found in soma, dendrite, and axon
- B) Bipolar neurons do not have axons
- C) Each neuron has as a rule one primary dendrite, and never more than one primary dendrite.
- D) Nissil bodies provide the main cytoskeletal tracks for axonal transport
- E) Bundle of axons within central nervous system is called nerve

Ans: A

Question : Regarding Axons, choose the WRONG statement:

Q71

- A) Are longer than dendrites
- B) Are mostly myelinated
- C) Have nearly constant diameter
- D) Conduct Impulses away from perikaryon
- E) Their cytoplasm is similar in composition to the cytoplasm of cell bodies

Ans: E

Question : The neuron conducting an impulse from the stomach wall to the central nervous system would be classified as a:

Q72

- A) Somatic efferent
- B) Somatovisceral
- C) Visceral afferent
- D) Visceral efferent
- E) Somatic afferent

Ans: C

Question : Schwann cells are characterized by the followings EXCEPT:

Q73

- A) They are similar in function to astrocytes of central nervous system
- B) They play a role in regeneration of axons in peripheral nervous system
- C) Each Schwann cell myelinates only one Internodal segment of one axon
- D) They are Interrupted by nodes of Ranvier
- E) They support both myelinated and unmyelinated axons In the peripheral nervous system

Ans: A

Question : Choose the WRONG match:

- A) Epineurium: dense connective tissue
- B) Motor neurons: multipolar
- C) Neurons: no centrioles
- D) Anterograde axonal transport: movement toward soma
- E) Anaxonic neuron: lack true axon

Question : The axon hillock is found at:

Q75

- A) The origin of the axon
- B) The middle of the axon
- C) Schwann cells
- D) The end of the axon
- E) The dendrites

Ans: A

Question : Which one of the following neurotransmitters functions to increase cardiac output?

Q76

- A) Dopamine
- B) Serotonin
- C) Norepinephrine
- D) Glutamate
- E) GABA

Ans: C

Question : Which of the following statements is characteristic of the perineurium?

- A) It is a fascia surrounding many bundles of nerve fibers.
- B) It is the fascia surrounding a single nerve fiber.
- C) It is a thin layer of reticular fibers covering individual nerve fibers.
- D) It is a fascia that excludes macromolecules and forms the external coat of nerves.
- E) It consists in part of epithelioid cells that surround a bundle (fascicle) of nerve fibers.

Question : Nissl bodies are composed of:

- (A) synaptic vesicles and acetylcholine.
- B) polyribosomes and rough endoplasmic reticulum.
- C) lipoprotein and melanin.
- D) neurofilaments and microtubules.
- E) SER and mitochondria

Question : Myelination of peripheral nerves is accomplished By:

- (A) astrocytes.
- (B) oligodendrocytes.
- (C) Schwann cells.
- (D) neural crest cells.
- (E) basket cells

Question : Which of the following is characteristic of the chromatophilic material called Nissl substance in neural tissue?

- a. Found throughout neurons
- B) Site of mRNA translation for proteins of the axolemma
- C) Most abundant in unipolar neurons
- D) Becomes more abundant as an individual gets older
- E) An example of intermediate filament proteins

Ans: B

Question : Which of the following events occurs immediately after an action potential reaches a synapse at an axon terminal?

- a. Vesicle fusion with the presynaptic terminal membrane
- b. Calcium ion influx at the presynaptic terminal
- c. Neurotransmitter binding to receptors on the postsynaptic Membrane
- d. Neurotransmitter release into the synaptic cleft
- e. Binding of the neurotransmitter at the presynaptic terminal

Ans: B

Question : What term applies to collections of neuronal cell bodies (somata) in the central nervous system?

Q82

- a. Ganglia
- b. Neuroglia
- c. Nodes
- d. White matter
- e. Nuclei

Ans: E

Question : Which of the following components of the peripheral nervous system specifically conveys sensory information to the central nervous system?

Q83

- a. Afferent
- b. Somatic
- c. Autonomic
- d. Motor
- e. Efferent

Ans: A

Question : What are the cells lining blood capillaries in the central nervous system?

- a. Schwann cells
- b. Astrocytes
- c. Neuronal cells
- d. Glial cells
- e. Endothelial cells

Ans: E

Question : Which of the following components allow the transport of substances within the cytoplasm of a neuron and along the length of the axon in two ways ?

Q85

- a. Nissl bodies
- b. Microtubules
- c. Myelin
- d. Microglia
- e. Dendrite

Ans: B

Question : Which of the following is a cluster of neuron cell bodies outside the central nervous system?

- a. Nissl substance
- b. Neurofibril
- c. Synapse
- d. Ganglion
- e. Axon hillock

Ans: D

Question : Which of the following is not a component of a neuron ?

- a. Axon
- b. Nissl substance
- c. Soma
- d. Dendrite
- e. Glia

Question : The neurons of the retina which carry light-elicited signals from photoreceptors in the outer retina to cells in the inner retina are primarily of which of the following type ?

- a. Multipolar
- b. Tripolar
- c. Polypolar
- d. Bipolar
- e. Unipolar

Ans: D

Question : A sensory ganglion associated with a spinal sensory nerve root is located:

- a) Within the organ it innervates
- b) In a chain external to the spinal column, adjacent to the vertebral bodies
- c) In the dorsal root of spinal nerve
- d) In the ventral horn of spinal cord
- e) Near the peripheral receptor organ (in skin or muscle)

Question : Small cells closely associated with neurons in peripheral ganglia are:

- a) Schwann cells
- b) Satellite cells
- c) Microglia
- d) Ependymal cells
- e) Oligodendrocyte

Ans: B

Question : Schwann cells are characterized by the followings EXCEPT:

Q91

- a) Each Schwann cell myelinates only one internodal segment of one axon
- b) They are interrupted by nodes of Ranvier
- c) They play a role in regeneration of axons in peripheral nervous system
- d) They are similar in function to astrocytes of central nervous system
- e) They support both myelinated and unmyelinated axons in the peripheral nervous system

Ans: D

Question : Neuroglial cells, choose the WRONG statement:

- a) Are smaller in size compared to neurons
- b) Are not able to transmit nervous impulses
- c) Are able to undergo mitosis
- d) Are found in both peripheral and central nervous systems
- e) Are less numerous compared to neurons

Ans: E

Question : Which of the following is characteristic of the chromatophilic material called Nissl substance in neural tissue?

- a. Found throughout neurons
- b. Site of mRNA translation for proteins of the axolemma
- c. Most abundant in unipolar neurons
- d. Becomes more abundant as an individual gets older
- e. An example of intermediate filament proteins

Ans: B

Question : Which of the following events occurs immediately after an action potential reaches a synapse at an axon terminal?

- a. Vesicle fusion with the presynaptic terminal membrane
- b. Calcium ion influx at the presynaptic terminal
- c. Neurotransmitter binding to receptors on the postsynaptic membrane
- d. Neurotransmitter release into the synaptic cleft
- e. Binding of the neurotransmitter at the presynaptic termina

Question : What term applies to collections of neuronal cell bodies (somata) in the central nervous system?

- a. Ganglia
- b. Neuroglia
- c. Nodes
- d. White matter
- e. Nuclei

Ans: E

Question : Nervous tissue, choose the CORRECT statement :

- a) Each neuron has as a rule one primary dendrite, and never more than one primary dendrite
- b) Microtubule and neurofilaments are found in soma, dendrite, and axon
- c) Nissl bodies provide the main cytoskeletal tracks for axonal transport
- d) Bundle of axons within central nervous system is called nerve
- e) Bipolar neurons do not have axons

Ans: B

Question : The axon hillock is found at:

- a) Schwann cells
- b) The dendrites
- c) The end of the axon
- d) The origin of the axon
- e) The middle of the axon

Ans: D

Question : A 32-year-old woman comes to the neurology clinic and complains of a stumbling gait and a tendency to fall. Her visual acuity also seems to change periodically during the last several years. After performing a thorough neurological examination and an MRI scan, the neurologist establishes the diagnosis of multiple sclerosis (MS). MS is an autoimmune disease that results in the destruction of the myelin sheath in the central nervous system that is produced by oligodendrocytes. In contrast to oligodendrocytes, which cells are responsible for myelination in the peripheral nervous system?

- a) Astrocyte
- b) Schwann cell
- c) Microglial cell
- d) Fibrocyte
- e) Ependymal cells

Ans: B

Question : The outermost layer of dense irregular connective tissue surrounding a peripheral nerve is called :

A) Endoneurium

B) Fascicle

C) Epineurium

D) Septum

E) Perineurium

Ans: C

Question: Which region of the nerve cell promote rapid impulse transmission along the axon via a process known as saltatory conduction?

- A) Terminal boutons of axon
- B) Dendrites
- C) Microtubule
- D) Axon hillock
- E) Node of ranvier (Myelin sheath gap)

Question: Which layer of connective tissue surrounds the individual nerve fascicles in the peripheral nervous system?

Q99

- A) Perineurium
- B) Epineurium
- C) Myelin sheath
- D) Endomysium
- E) Endoneurium

Ans: A

Question: What is the name of the Schwann cell or oligodendrocyte membrane wrapped many times around an individual axon?

- A) Node of ranvier (myelin sheath gap)
- B) Microtubule
- C) Myelin sheath
- D) Axon hillock
- E) Dendrites

Ans: C

Question: The myelin forming cells in central nervous system are:

- A) Schwann cells
- b)Oligodendrocytes
- C)Microglia
- D)Astrocytes
- E) Satellite cells

Ans: B

Question: A typical peripheral mixed nerve includes all of the following EXCEPT:

- A) Connective tissue of epineurium, perineurium and endoneurium
- B) Sensory axons
- C) Interneurons
- D) Schwann cells
- E) Motor axons

Ans: C

Question: Nissl bodies consist of ?

- a) Clusters of synaptic vesicles
- b) Golgi bodies
- c) Rough endoplasmic reticulum and ribosomes
- D) Lysosomes and lipofuscin granules
- E) Microtubules and microfilaments

Question: Nervous tissue, choose the CORRECT statement :

Q104

- A) Motor and sensory innervations of viscera are mediated by somatic nervous system
- B) The ventral ramus of a spinal nerve is typically motor while the dorsal ramus is sensory
- c) Bundle of axons within peripheral nervous system is called tract
- D) Schwann cells support both myelinated and unmyelinated axons in the peripheral nervous system
- E) Basophilic granular structures within the axon are called Nissl bodies

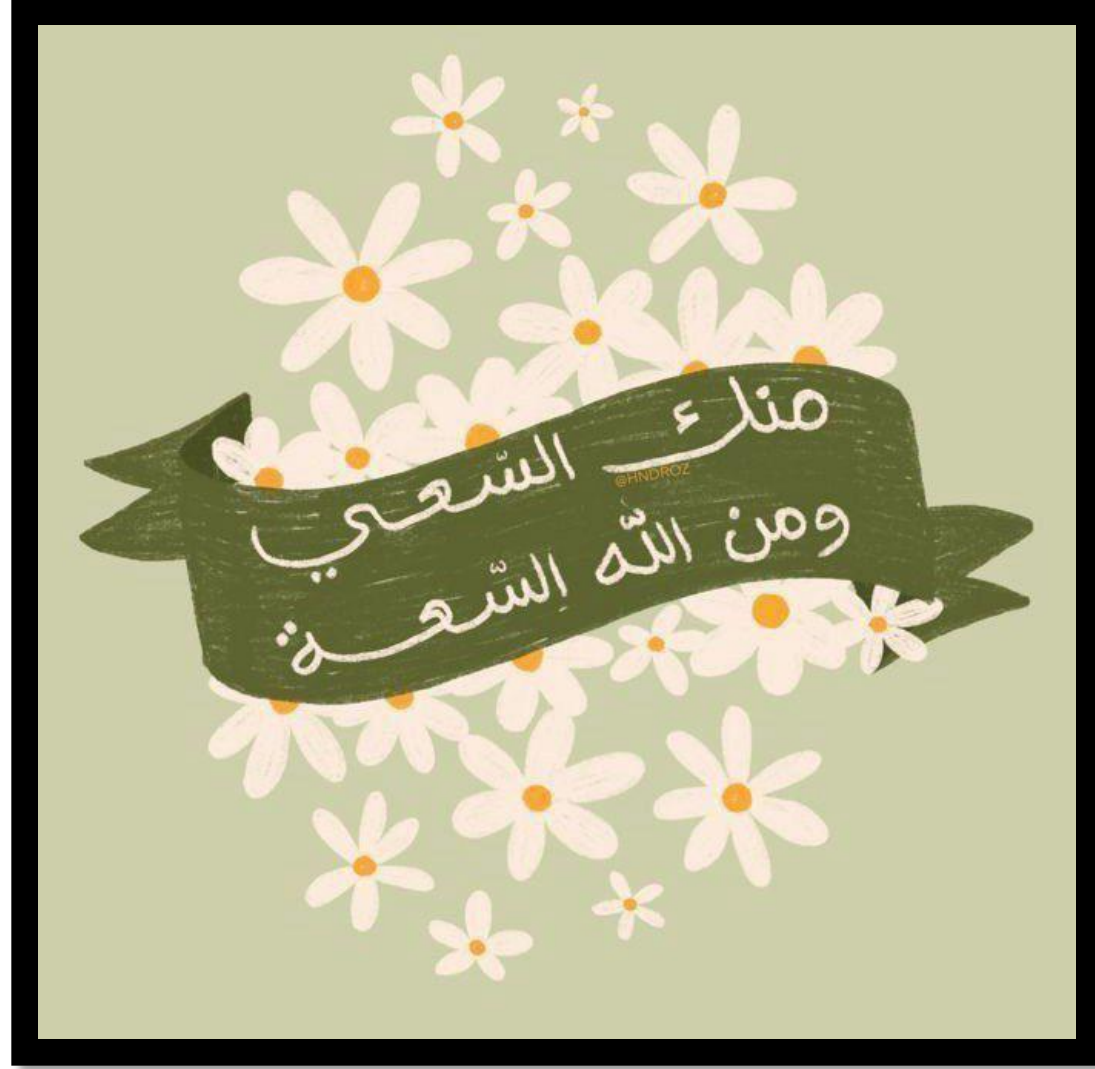Ans: D

Question: Which of the following neuroglial cells participate in the formation of blood brain barrier:

Q105

- A) Microglia
- B) Satellite cells
- C) Oligodendrocytes
- D) Astrocytes
- E) Schwann cells

Ans: D



أطنان من التعب ؛
تحوها فكرة مطمئنة .
«وَأَنَّ سَعِيه سَوْفَ يُرَى»

MUSCLE TISSUE

Question : White fibers, choose the CORRECT statement:

- a) Are smaller in diameter compared to red fibers
- b) Their oxidative capacity is high
- c) Can be differentiated from red fibers using H & E
- d) Their glycolytic capacity is high
- e) Their ATPase activity is low

Ans: d

Question : Which characteristic is unique to skeletal muscle cells compared to cardiac and smooth muscle cells?

- a) Often branched
- b) Multinucleated
- c) Contain centrally located nuclei
- d) Striated
- e) Lack T-tubules

Question : Characteristics of smooth muscle fibers are:

- a) Spindle shaped, branched, unstriated, uninucleate and involuntary
- b) Spindle shaped, unbranched, unstriated, multinucleate and involuntary
- c) Spindle shaped, unbranched, unstriated, uninucleate and involuntary
- d) Cylindrical, unbranched, unstriated, uninucleate and involuntary
- e) Spindle shaped, branched, striated, uninucleate and involuntary

Ans: c

Question : The triad in skeletal muscle, choose the **WRONG** statement:

- a) Is visible by light microscopy
- b) Is found at the site of A-I band junction
- c) Includes two terminal cisternae of sarcoplasmic reticulum
- d) Includes part of T tubule
- e) Is involved in the process of initiating muscle contraction

Question : In the I band of a sarcomere of voluntary muscle

- a) The Z line is found
- b) There are only thick myofilaments
- c) The M line is found
- d) There are overlapping thin and thick myofilaments
- e) There are no myofilaments

Ans: a

Question : Sarcoplasmic reticulum, choose the **WRONG** statement:

- a) Acts as a storage site for calcium ions
- b) Is well developed in smooth muscle cells
- c) Is associated with T-tubules in striated muscle cells
- d) Is more extensive in skeletal muscle cells compared to cardiac
- e) Is visible by electron microscopy

Ans: b

Question : Diads are usually seen in:

- a) Smooth muscles by electron microscope
- b) Cardiac muscles by electron microscope
- c) Cardiac muscles by light microscope
- d) Skeletal muscles by light microscope
- e) Skeletal muscles by electron microscope

Ans: b

Question : In what way are cardiac muscles and skeletal muscles similar?

- a) Both have myogenic activity
- b) Both have tubular myofibrils
- c) Both are controlled by somatic nervous system
- d) Both are highly branched
- e) Both are connected by gap junctions

Ans: b

Question : Intercalated discs , choose the correct statement:

- A)are characteristics of striated muscle cells
- B)containing only two types of junctions
- C)It can be easily visualized when observing a longitudinal section of cardiac muscle cells
- D)producing cross striations of striated muscle
- E)are found at every Z line

Ans: c

Question : Thin filaments of human skeletal muscle, choose the CORRECT statement:

- a) Are attached to Z line by titin
- b) In a relaxed muscle, they completely overlap the myosin thick filaments
- c) Are anisotropic
- d) In a relaxed muscle, they present in the H zone of a sarcomere
- e) Are pulled by the thick filaments toward the center of the sarcomere during contraction

Ans: e

Question : Muscle tissue, choose the WRONG statement:

- a) Endomysium is a loose type of connective tissue
- b) Muscle spindles are also called intrafusal muscle fibers
- c) All muscle fibers of a motor unit are of the same type (red or white)
- d) The area between two Z lines is known as a myofibril
- e) Intracytoplasmatic dense bodies of smooth muscle cells functionally correspond to the Z-lines of the other muscle types

Ans: d

Question : Which of the following is present in all three types of muscle cells?

- a) Myofilaments
- b) Myofibrils
- c) Troponin
- d) Intracytoplasmic dense bodies
- e) Caveolae

Ans: a

Question : Cells of smooth muscles, choose the CORRECT statement:

- a) Their sarcolemma contains caveolae
- b) Have distinct sarcomeres
- c) Lack gap junctions
- d) Have no myofilaments
- e) Lack intermediate filaments

Ans: a

Question : Sarcoplasmic network, choose the correct phrase:

- A) is associated with T tubules in all muscle types
- B) is more extensive in cardiac muscle cells compared to skeletal
- C) is rudimentary in smooth muscle cells
- D) forms diads in skeletal muscle cells
- E) None of the above

Ans: c

Question : Which of the following is incorrect regarding the functions of muscles:

- A) To produce a movement, muscle should at least cross two joints
- B) Contraction of muscles, results in locomotion only
- C) When we feel cold we shiver due to contraction of muscles
- D) All of the above are incorrect except C

Question : All of the following are correct according to skeletal muscle EXCEPT:

- A) Their cells have obvious striations
- B) They represent almost half of body weight
- C) Their contraction is voluntary
- D) It can be found in viscera
- E) All of the above are correct

Question : What type of muscle is mainly composed of spindle shaped cells?

- A) Skeletal muscle
- B) Cardiac muscle
- C) Smooth muscle
- D) Both "a" and "b"

Ans: c

Question : The correct answer according to Intercalated junctional disks in cardiac muscle is:

- A) fascia adherens forms belt like structure around the cardiac cell
- B) Desmosomes are associated with actin filaments
- C) Fascia adherens are associated with intermediate filaments
- D) It contains 3 types of junctions

Question : All of the following are correct regarding **HYPERTROPHY** except:

- A) It is caused by increasing in number of myofibrils only
- B) It is caused by increasing in size of myofibers
- C) It is caused by increasing in size and number of myofibrils
- D) All of the above are correct

Question : The correct arrangement of muscle fibers resistance to fatigue is :

- A) Red > White > Intermediate FIBERS
- B) White > Intermediate > Red FIBERS
- C) Red > Intermediate > White FIBERS
- D) Intermediate > White > Red FIBERS
- E) none of the above

Question : All of the following are correct regarding to myosin filaments, except:

- A) It has 2 heads and one tail
- B) It has 2 binding sites in each head
- C) It is anisotropic
- D) All of the above are correct
- E) none of the above is true

Question : Which of the following is the lightest staining area in the sarcomere:

- A) H band
- B) A band
- C) I band
- D) A and C are correct

Question : The sarcomere is composed of:

- A) One A band, One I band, One T tubules
- B) One A band, Two I band, Two T tubules
- C) One A band, Two halves of I bands, Two T tubules
- D) One A band, Two halves of I bands, We cannot determine the number of T tubules Because we don't know the type of muscle

Question : Concerning Cardiac and Skeletal muscle, which statement is most accurate?

- A) Cardiac Myofibril nuclei are eccentrically located whereas skeletal myofibers nuclei are centrally placed.
- B) Skeletal muscle fibers exhibit more branching than cardiac muscle fibers
- C) The striations of cardiac muscle cells are more distinct than that of skeletal muscles
- D) Cardiac muscle contains structures known as intercalated discs while skeletal muscle does Not

Question : 66-year-old man who lives alone has a severe myocardial infarction and dies during the night. The medical examiner's office is called the following morning and describes the man's body as being in rigor mortis. This state of rigor mortis is due to which one of the following?

- a. Inhibition of Ca^{2+} leakage from the extracellular fluid and sarcoplasmic reticulum
- b. Enhanced retrieval of Ca^{2+} by the sarcoplasmic reticulum
- c. Failure to disengage tropomyosin and troponin from the myosin active sites
- d. Absence of ATP preventing detachment of the myosin heads from actin
- e. Increased lactic acid production

Ans: d

Question : A 5-year-old boy sustains a small tear in his gastrocnemius muscle when he is involved in a bicycle accident. Regeneration of the muscle will occur through which of the following mechanisms?

- a. Dedifferentiation of muscle cells into myoblasts
- b. Differentiation of muscle satellite cells
- c. Fusion of damaged myofibers to form new myotubes
- d. Hyperplasia of existing muscle fibers
- e. Differentiation of fibroblasts to form myoblasts

Ans: b

Question : Cardiac muscle cells, choose the **WRONG** statement:

- a) Are not capable of extensive cell division in repairing damaged heart tissue
- b) Have adherens junctions
- c) Cardiac tissue lacks satellite cells
- d) Lack intermediate filaments
- E) Are electrically coupled to each other via gap junctions

Ans: d

Question : With the transmission electron microscope skeletal muscle fibers can be seen to contain structures called triads. What do the two lateral components of a triad represent?

- a) Sites for ATP production
- b) Sites for synthesis of proteins to be secreted outside the cell
- c) Sites for calcium sequestration and release
- d) Attachment sites for thick myofilaments
- e) Sites for impulse conduction into the fiber

Ans: c

Question : Red fibers, choose the CORRECT statement:

- A) Are larger in diameter compared to white fibers
- B) Can be differentiated from white fibers using H & E
- C) Their oxidative capacity is high
- D) Their glycolytic capacity is high
- E) Their ATPase activity is high

Question : Which of the following is present in all three types of muscle cells:

- A) Intercalated discs
- B) Troponin
- C) Dense bodies
- D) Myosin
- E) A and I bands

Ans: d

Question : muscle tissue, choose the CORRECT statement:

- A) Intrafusal muscle fibers form the bulk of the skeletal muscle
- B) Epimysium is a loose type of connective tissue
- C) Intracytoplasmic dense bodies of smooth muscle cells functionally correspond to the M-lines of the other muscle types
- D) The motor unit may contain both red and white muscle fibers
- E) Skeletal muscle cells are not connected by gap junctions

Ans: e

Question : In the A band of a sarcomere of voluntary muscle:

- A) There are only thin myofilaments
- B The M line is found
- C) The Z line is found
- D) There are no myofilaments
- E) There are only thick myofilaments

Question : Intercalated discs , choose the correct statement:

- A) are characteristics of striated muscle cells
- B) containing only two types of junctions
- C) It can be easily visualized when observing a longitudinal section of cardiac muscle cells
- D) producing cross striations of striated muscle
- E) are found at every Z line

Ans: c

Question : Sarcoplasmic network, choose the correct phrase:

- a) is associated with T tubules in all muscle types
- b) is more extensive in cardiac muscle cells compared to skeletal
- c) is rudimentary in smooth muscle cells
- d) forms diads in skeletal muscle cells
- e) None of the above

Ans: c

Question : cell of smooth muscle , Choose the correct statement:

- A) Upon contraction they become globular
- B) Have a distinct sarcomere
- C) lack gap junctions
- D) often branching
- E) are controlled by somatic neurons

Question : Which of the following is incorrect regarding the functions of muscles:

- A) To produce a movement, muscle should at least cross two joints
- B) Contraction of muscles, results in locomotion only
- C) When we feel cold we shiver due to contraction of muscles
- D) All of the above are incorrect except C

Question : All of the following are correct according to skeletal muscle EXCEPT:

- A) Their cells have obvious striations
- B) They represent almost half of body weight
- C) Their contraction is voluntary
- D) It can be found in viscera
- E) All of the above are correct

Question : Which of the following statements regarding the connective tissue of a skeletal muscle is correct?

- A) the perimysium surrounds the individual muscle fibers within a fascicle
- B) The epimysium separates each muscle fascicle from others
- C) The endomysium consists of loose connective tissue and surrounds the muscle fiber
- D) The perimysium envelopes the whole muscle
- E) endomysium is not involved in formation the tendon that connects the muscle to the bone

Question : All of the following are correct regarding myofibrils in skeletal muscle except:

- A) They are short rows of repeating sarcomeres
- B) They are composed of myosin and actin filaments
- C) They are organelles within the sarcolemma
- D) All of the above are incorrect except B

Question : The sarcomere is composed of:

- A) One A band, One I band, One T tubules
- B) One A band, Two I band, Two T tubules
- C) One A band, Two halves of I bands, Two T tubules
- D) One A band, Two halves of I bands, We cannot determine the number of T tubules because we don't know the type of muscle

Question : Which of the following is the lightest staining area in the sarcomere:

- A) H band
- B) A band
- C) I band
- D) A and C are correct

Question : All of the following are correct regarding to myosin filaments, except

- A) It has 2 heads and one tail
- B) It has 2 binding sites in each head
- C) It is anisotropic
- D) All of the above are correct
- E) none of the above is true

Question : When a skeletal muscle contracts the arrangement of the alternating light and dark bands traversing each skeletal muscle cell changes. Which of the following statements is not correct?

- A) The dark A bands length remains constant
- B) The space occupied by the H zone will not change
- C) The light I bands will shorten
- D) The z lines come closer together
- E) B and D

Question : Which of the following is incorrect:

- A) If T tubules are absent, only the peripheral myofibrils will be stimulated
- B) The triad is located at the junction between A and I bands
- C) Binding between myosin head and actin filaments is called cross bridge
- D) Movement of myosin heads toward M line is called power stroke
- E) All of the above are correct

Question : The correct arrangement of muscle fibers resistance to fatigue is

- A) Red > White > Intermediate FIBERS
- B) White > Intermediate > Red FIBERS
- C) Red > Intermediate > White FIBERS
- D) Intermediate > White > Red FIBERS
- E) none of the above

Question : All of the following are correct regarding **HYPERTROPHY** except:

- A) It is caused by increasing in number of myofibrils only
- B) It is caused by increasing in size of myofibers
- C) It is caused by increasing in size and number of myofibrils
- D) All of the above are correct

Question : Concerning Cardiac and Skeletal muscle, which statement is most accurate?

- A) Cardiac Myofibril nuclei are eccentrically located whereas skeletal myofibers nuclei are centrally placed.
- B) Skeletal muscle fibers exhibit more branching than cardiac muscle fibers
- C) The striations of cardiac muscle cells are more distinct than that of skeletal muscles
- D) Cardiac muscle contains structures known as intercalated discs while skeletal muscle does not

Question : The correct answer according to Intercalated junctional disks in cardiac muscle is:

- A) fascia adherens forms belt like structure around the cardiac cell
- B) Desmosomes are associated with actin filaments
- C) Fascia adherens are associated with intermediate filaments
- D) It contains 3 types of junctions

Question : What type of muscle is mainly composed of spindle shaped cells?

- A) Skeletal muscle
- B) Cardiac muscle
- C) Smooth muscle
- D) Both "a" and "b"

Question : There are certain structures called caveolae. Which of the following is not correct:

- A) They are short depressions of the sarcolemma
- B) They have high concentration of sensory receptors
- C) We can find them on the plasma membrane of skeletal muscle cells
- D) All of the above are correct

Question : All the following are correct regarding all muscle types EXCEPT:

- A) Smooth muscles are the only type that has high regeneration power.
- B) All types of them can undergo hypertrophy
- C) Cardiac muscle lacks satellite cells and has little capacity for regeneration
- D) all of the above are correct

Question : Which of the following is correct?

ANSWER: Desmosomes are perpendicular

Note: (I think what Doctor meant is perpendicular to gap junctions in intercalated discs, desmosomes are found in the vertical part)

Question : Which of the following statements is true regarding Sarcoplasmic reticulum?

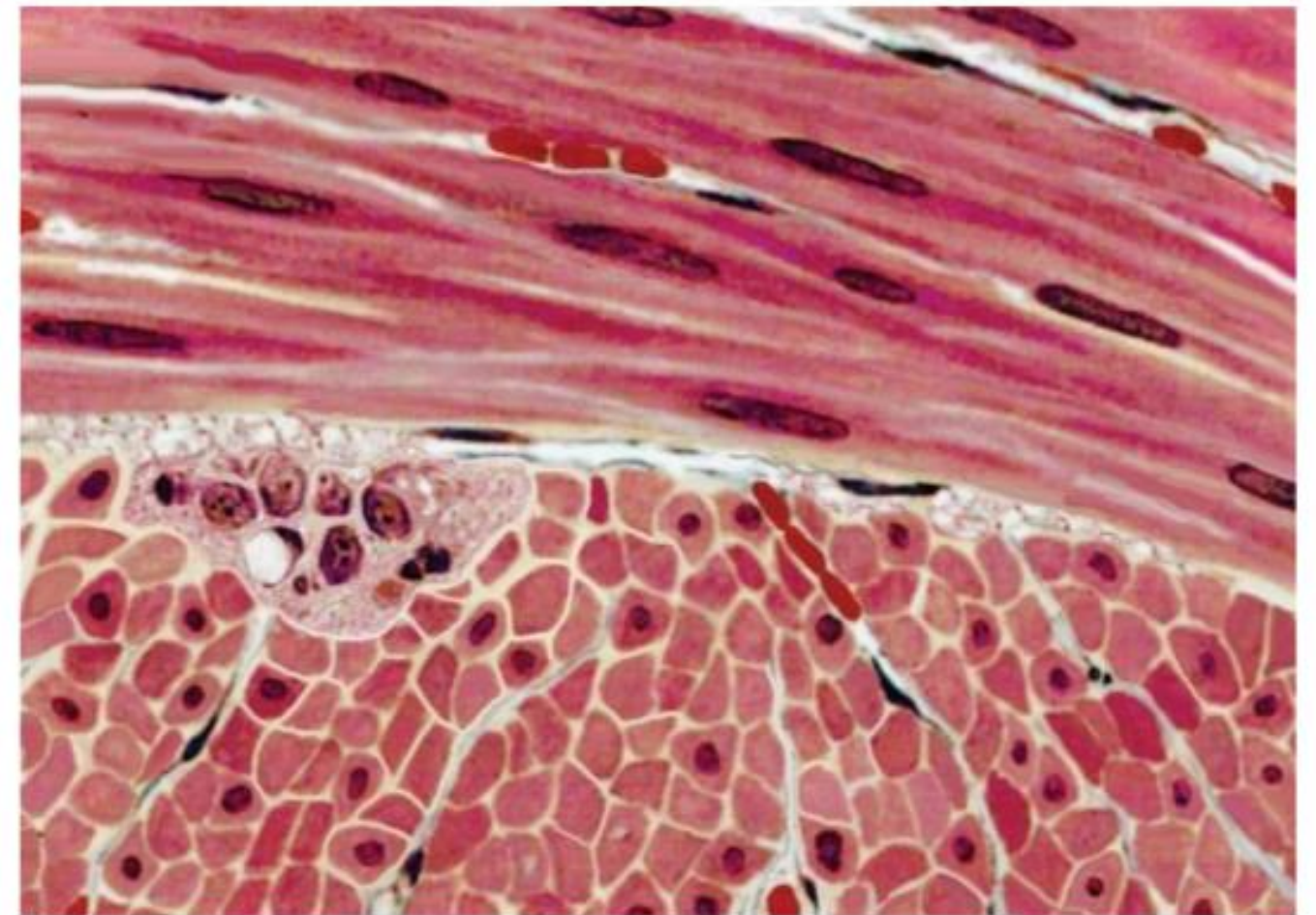
ANSWER: Smooth muscles have less sarcoplasmic reticulum than cardiac and skeletal muscle cells.

Question : Human myosin fibers are?

ANSWER: Anisotropic

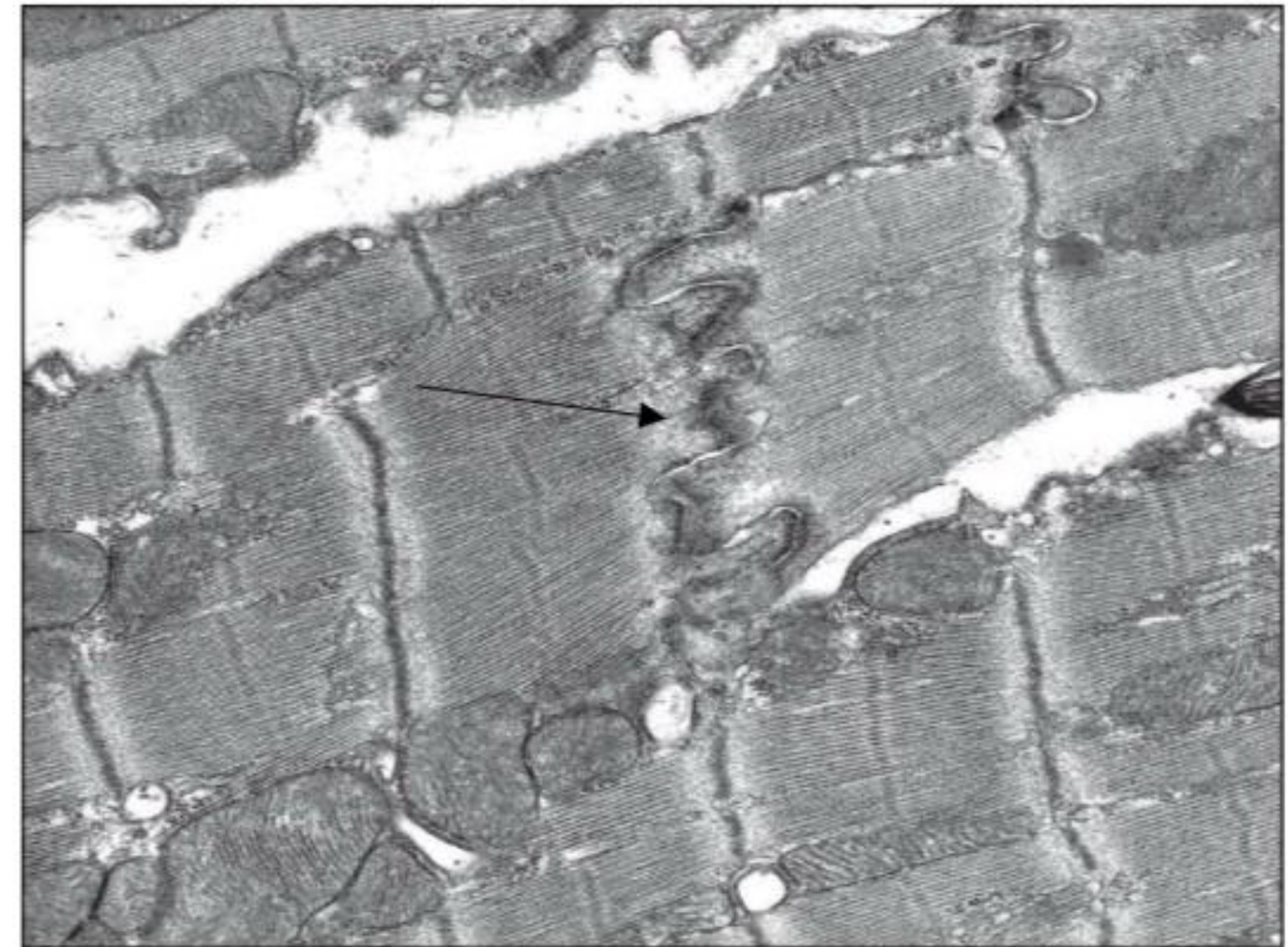
Question : Which if the following is wrong about this type of muscles?

ANSWER: Innervated by somatic PNS.



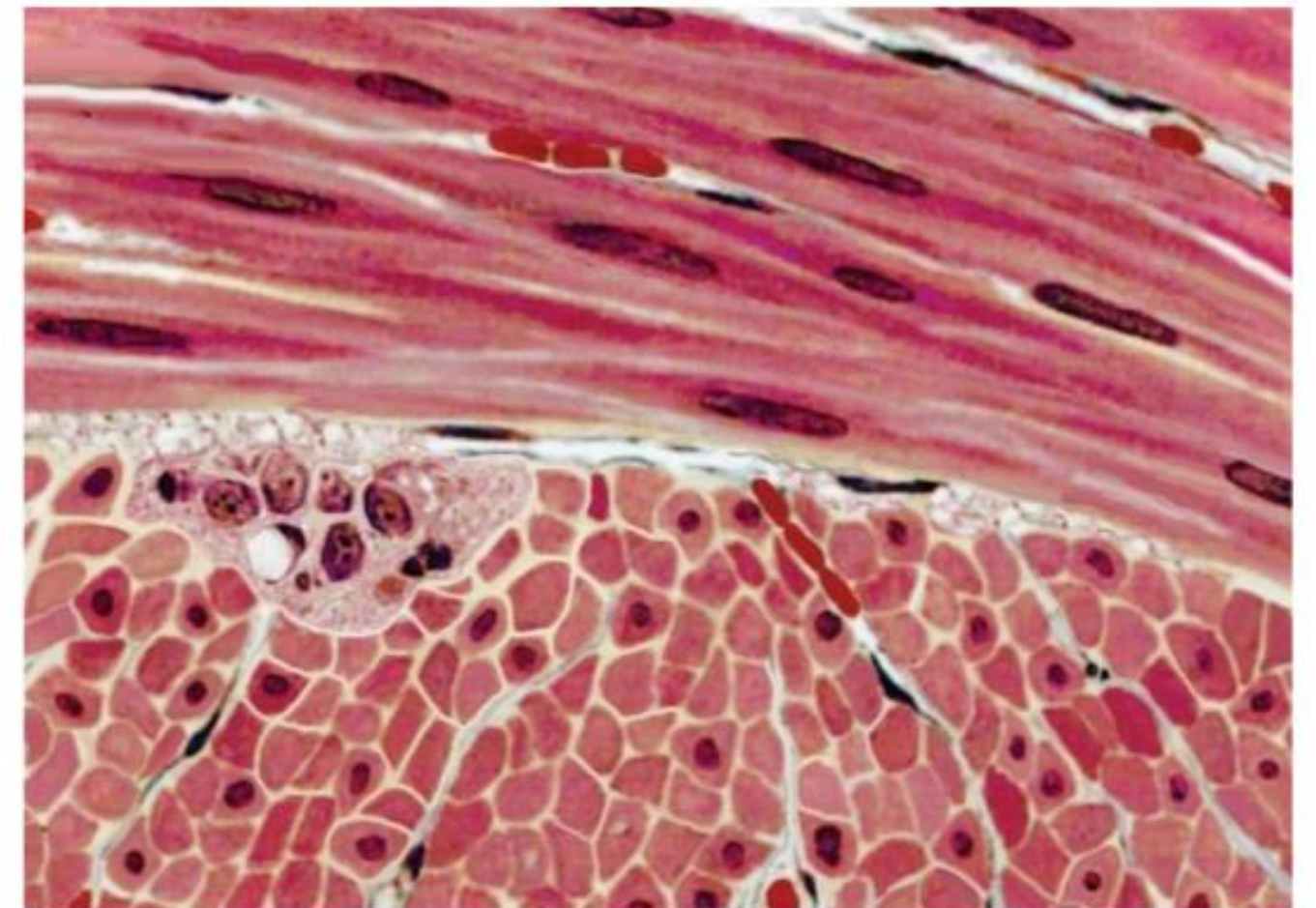
Question : Identify the pointed structure ,and where can you find it?

ANSWER: intercalated discs found in cardiac muscle fibers




Question : Choose the CORRECT regarding the cells in this tissue:

- A) Are cylindrical in shape
- B) Are multinucleated cells
- C) Their plasma membranes lack caveolae
- D) Have peripherally located nucleus
- E) Can undergo hyperplasia and hypertrophy



Question : Choose the correct statement?

- A) Electron microscopy of a slow multinucleated striated muscle fiber
- B) Electron microscopy of an involuntary muscle fiber with sarcomeres
- C) Electron microscopy of a mononucleated striated muscle fiber
- D) Electron microscopy of a fast multinucleated striated muscle fiber



Question : White fibers, choose the CORRECT statement:

- a) Are smaller in diameter compared to red fibers
- b) Their oxidative capacity is high
- c) Can be differentiated from red fibers using H & E
- d) Their glycolytic capacity is high
- e) Their ATPase activity is low

Question : Characteristics of smooth muscle fibers are:

- a) Spindle shaped, branched, unstriated, uninucleate and involuntary
- b) Spindle shaped, unbranched, unstriated, multinucleate and involuntary
- c) Spindle shaped, unbranched, unstriated, uninucleate and involuntary
- d) Cylindrical, unbranched, unstriated, uninucleate and involuntary
- e) Spindle shaped, branched, striated, uninucleate and involuntary

Ans: c

Question : The triad in skeletal muscle, choose the **WRONG** statement:

- a) Is visible by light microscopy
- b) Is found at the site of A-I band junction
- c) Includes two terminal cisternae of sarcoplasmic reticulum
- d) Includes part of T tubule
- e) Is involved in the process of initiating muscle contraction

Question : In the I band of a sarcomere of voluntary muscle:

- a) The Z line is found
- b) There are only thick myofilaments
- c) The M line is found
- d) There are overlapping thin and thick myofilaments
- e) There are no myofilaments

Question : Sarcoplasmic reticulum, choose the **WRONG** statement:

- a) Acts as a storage site for calcium ions
- b) Is well developed in smooth muscle cells
- c) Is associated with T-tubules in striated muscle cells
- d) Is more extensive in skeletal muscle cells compared to cardiac
- e) Is visible by electron microscopy

Ans: b

Question : Diads are usually seen in:

- a) Smooth muscles by electron microscope
- b) Cardiac muscles by electron microscope
- c) Cardiac muscles by light microscope
- d) Skeletal muscles by light microscope
- e) Skeletal muscles by electron microscope

Ans: b

Question : In what way are cardiac muscles and skeletal muscles similar?

- a) Both have myogenic activity
- b) Both have tubular myofibrils
- c) Both are controlled by somatic nervous system
- d) Both are highly branched
- e) Both are connected by gap junctions

Question : Thin filaments of human skeletal muscle, choose the CORRECT statement:

- a) Are attached to Z line by titin
- b) In a relaxed muscle, they completely overlap the myosin thick filaments
- c) Are anisotropic
- d) In a relaxed muscle, they present in the H zone of a sarcomere
- e) Are pulled by the thick filaments toward the center of the sarcomere during contraction

Question : Muscle tissue, choose the WRONG statement:

- a) Endomysium is a loose type of connective tissue
- b) Muscle spindles are also called intrafusal muscle fibers
- c) All muscle fibers of a motor unit are of the same type (red or white)
- d) The area between two Z lines is known as a myofibril
- e) Intracytoplasmatic dense bodies of smooth muscle cells functionally correspond to the Z-lines of the other muscle types

Ans: d

Question : Which of the following is present in all three types of muscle cells?

- a) Myofilaments
- b) Myofibrils
- c) Troponin
- d) Intracytoplasmic dense bodies
- e) Caveolae

Ans: a

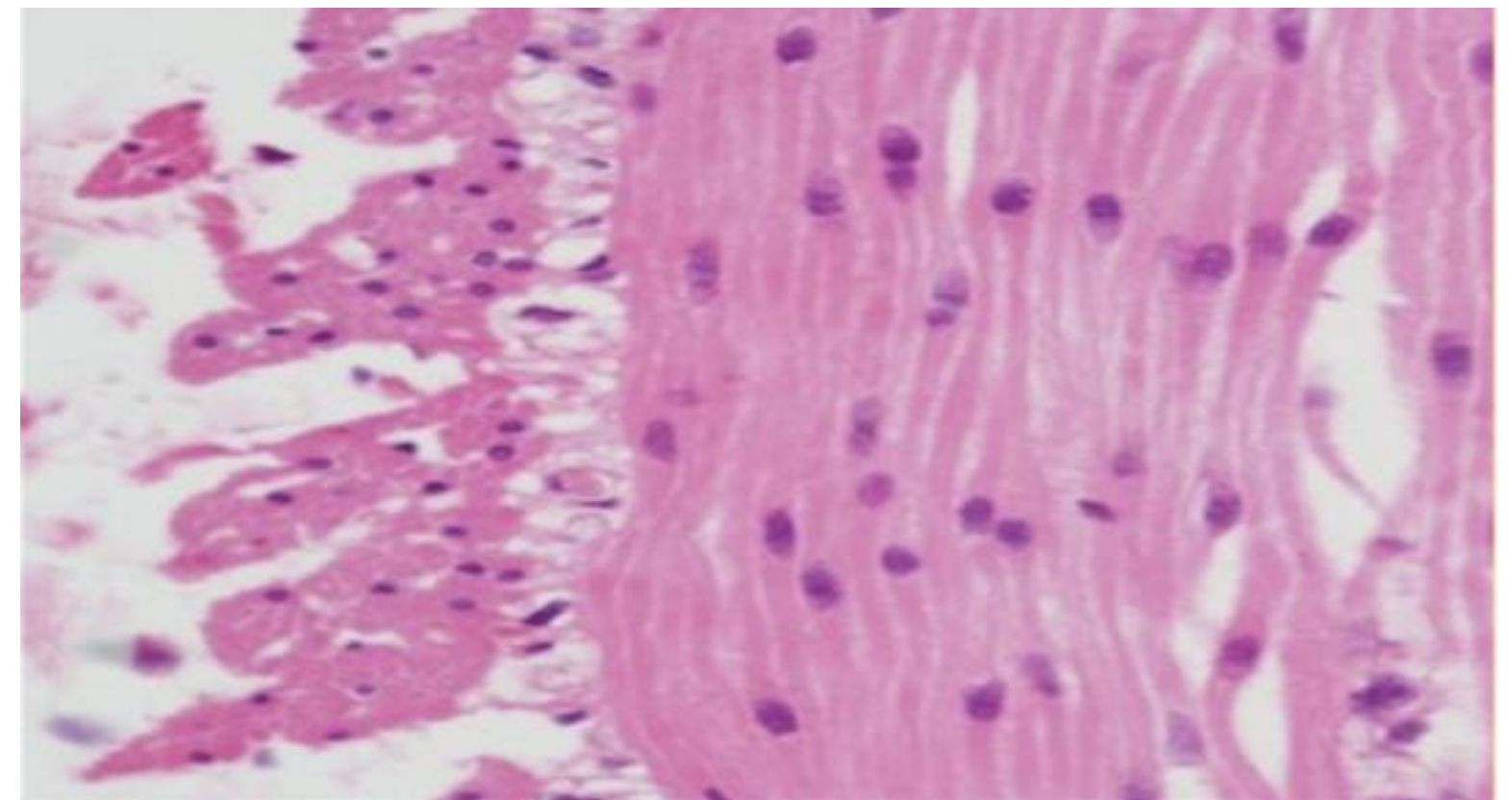
Question : Cells of smooth muscles, choose the CORRECT statement:

- a) Their sarcolemma contains caveolae
- b) Have distinct sarcomeres
- c) Lack gap junctions
- d) Have no myofilaments
- e) Lack intermediate filaments

Ans: a

Question : Choose the CORRECT statement regarding the cells in this histological section

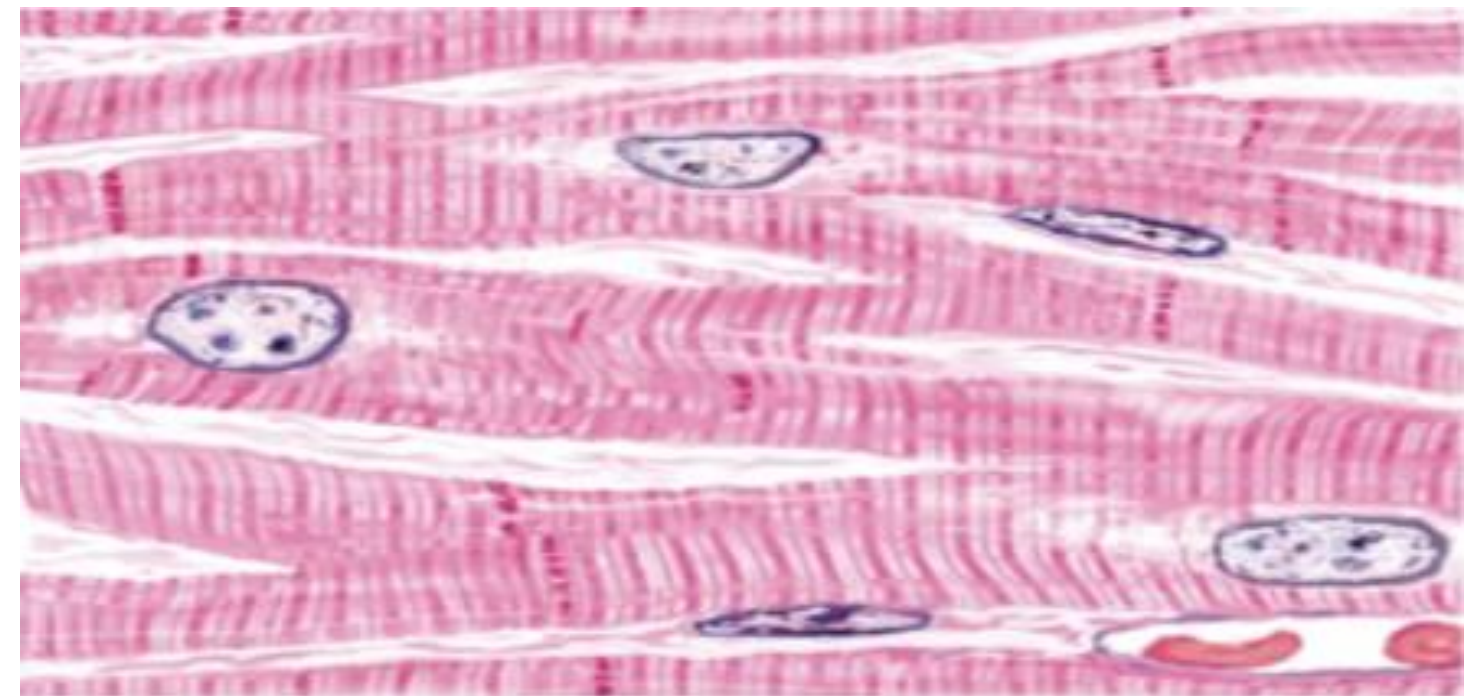
- a) Can undergo hyperplasia and hypertrophy
- b) Are multinucleated cells
- c) Have peripherally located nuclei
- d) Are branching cells
- e) Have striated cytoplasm



Ans: a

Question : Identify this histological section:


- a) Longitudinal section of skeletal muscle cells
- b) Longitudinal section of smooth muscle cells
- c) Cross section of skeletal muscle cells
- d) Longitudinal section of cardiac muscle cells
- e) Cross section of cardiac muscle cells



Ans: d

Question : All the followings can be labeled in this section
EXCEPT:

- a) M and Z lines
- b) Sarcoplasmic reticulum
- c) A, I and H bands
- d) Mitochondria
- e) Dense bodies

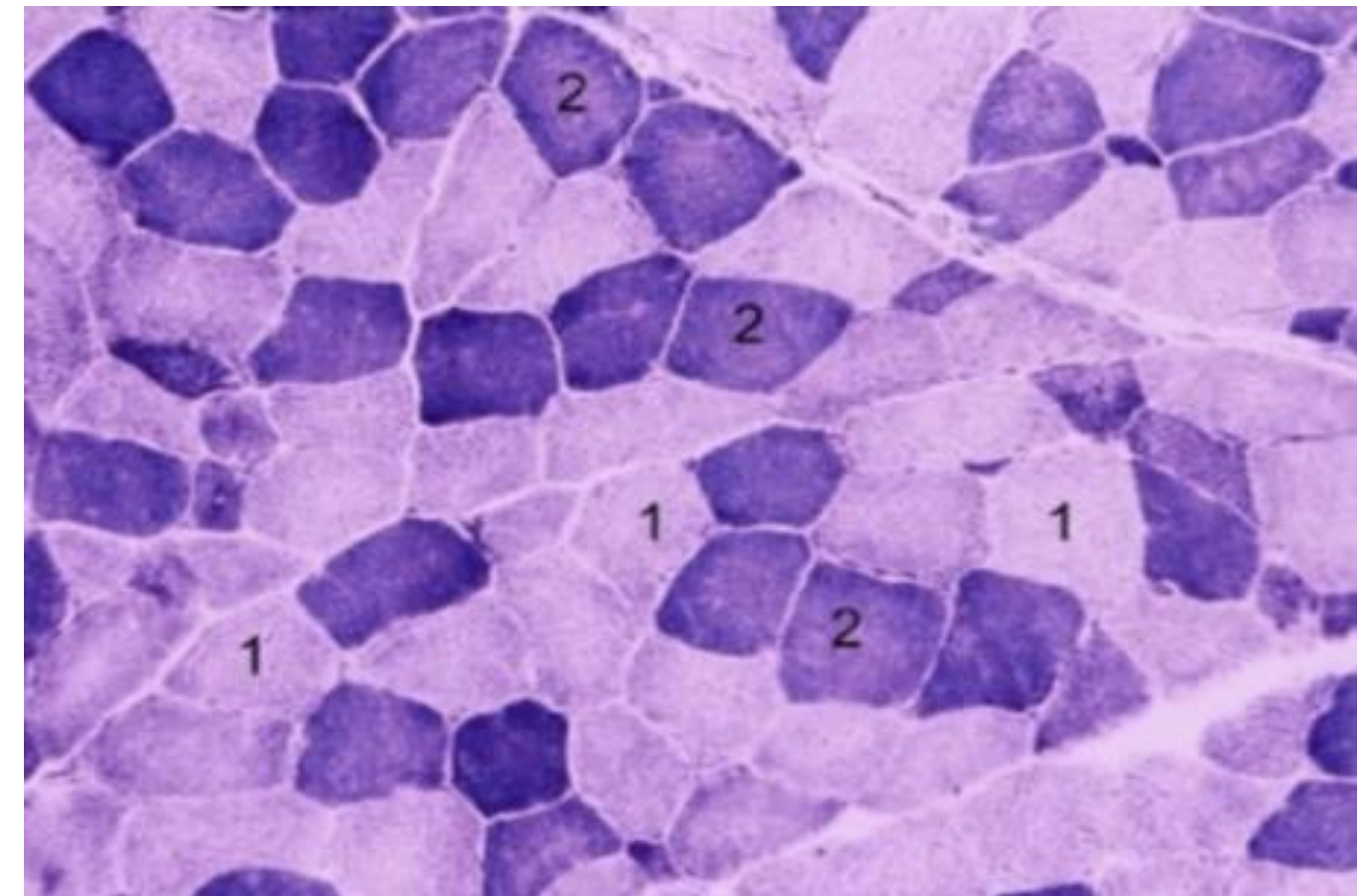


Ans: e

Question : This histological section is stained with a specific mitochondrial stain. Which fiber type is more resistant to fatigue?

a) Fiber 2

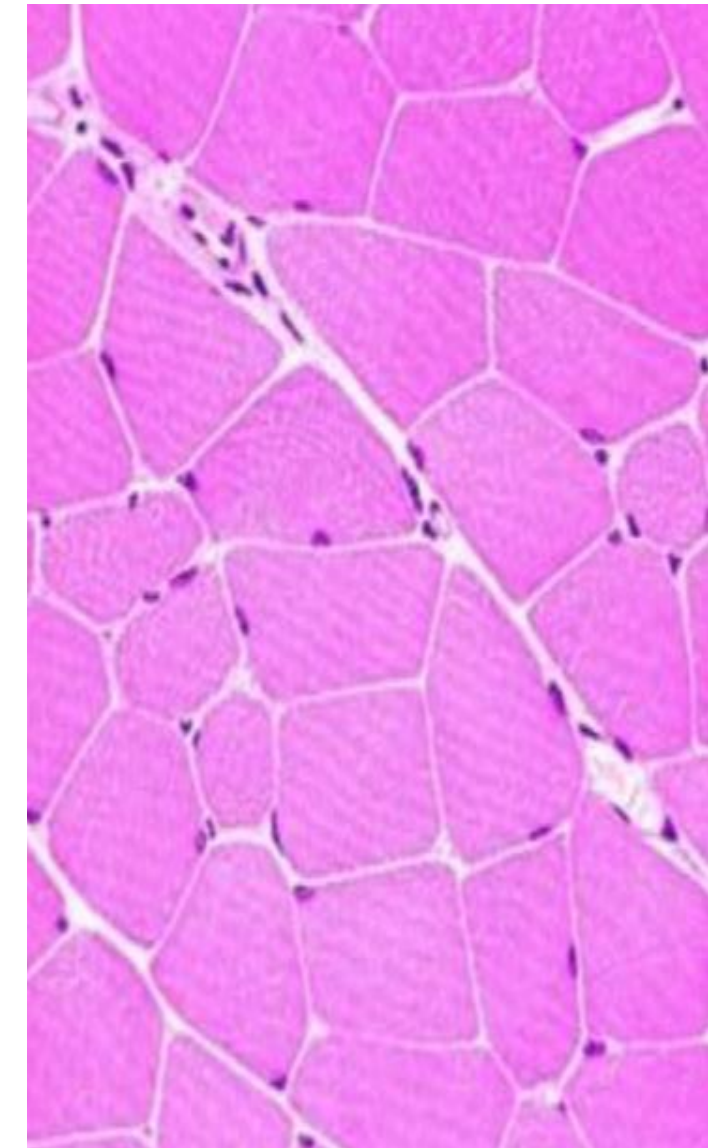
b) Fiber 1



Ans: b

Question : Identify this histological section

- a) Cross section of multinucleated striated muscle cells
- b) Longitudinal section of multinucleated striated muscle cells
- c) Cross section of non-striated smooth muscle cells
- d) Longitudinal section of mononucleated striated muscle cells
- e) Cross section of mononucleated striated muscle cells



Ans: a

Question : Thin Filaments in muscles consists of :

- A- Hundred F-actin
- B- Tropomyosin + troponin + F-actin
- C- Myosin + F-actin
- D- Hundred myosin molecules
- E- Actomyosin ATPase + F-actin

Question : The triad is consist of :

- A- One T-tubule & one terminal cisternae
- B- Two T-tubules & Two terminal cisternae
- C- One T-tubule & two terminal cisternae
- D- Two T-tubule & one terminal cisternae
- E- One T-tubule & three terminal cisternae

Question : Which type of skeletal muscle fibres fatigue the most quickly :

- A- Slow oxidative
- B- Fast oxidative
- C- Slow glycolytic
- D- Fast glycolytic
- E- Fast oxidative – glycolytic

Question : What structure of the cardiac muscle delivers the action potential :

- A- Neuromuscular Junction of each fibre
- B- Neuromuscular Junction of the three muscles
- C- Sarcoplasmic Reticulum
- D- Gap junction
- E- Thin & thick filaments

Question : What is the caveolae :

- A- Invagination of sarcolemma , delivers action potential
- B- Invagination of sarcolemma , facilitate binding to dense bodies
- C- Growth factor
- D- Exists in cardiac muscles
- E- Exists in skeletal muscles

Question : What type of muscles has the most powerful regeneration activity :

- A- Cardiac muscles
- B- Smooth muscles
- C- Skeletal muscles
- D- Bone
- E- Cartilage

Ans: b

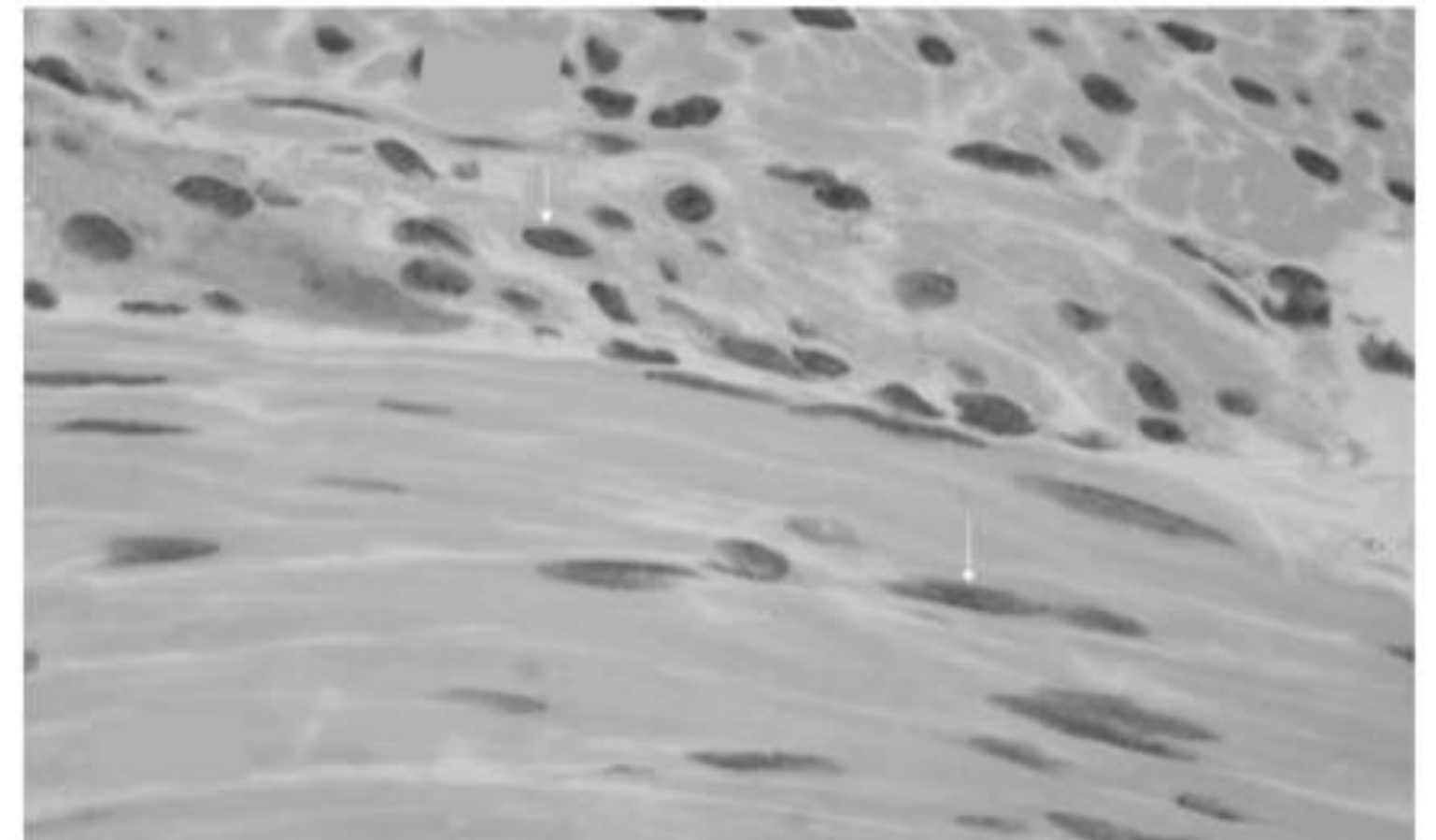
Question : What happened regarding muscle contraction :

- A) A-band does not change , H-zone shortens
- B) A-band does not change , H-zone increases in length
- C) A-band shortens , H-zone shortens
- D) A-band increases , H-zone does not change
- E) A-band shortens , H-zone does not change

Ans: a

Question : This image present :


- A) Cross & longitudinal section in cardiac muscles
- B) Cross & longitudinal section in smooth muscles
- C) Cross & longitudinal section in skeletal muscles
- D) Cross section in smooth muscle
- E) Longitudinal section in cardiac muscle



Ans: b

Question : Identify the structure pointed :

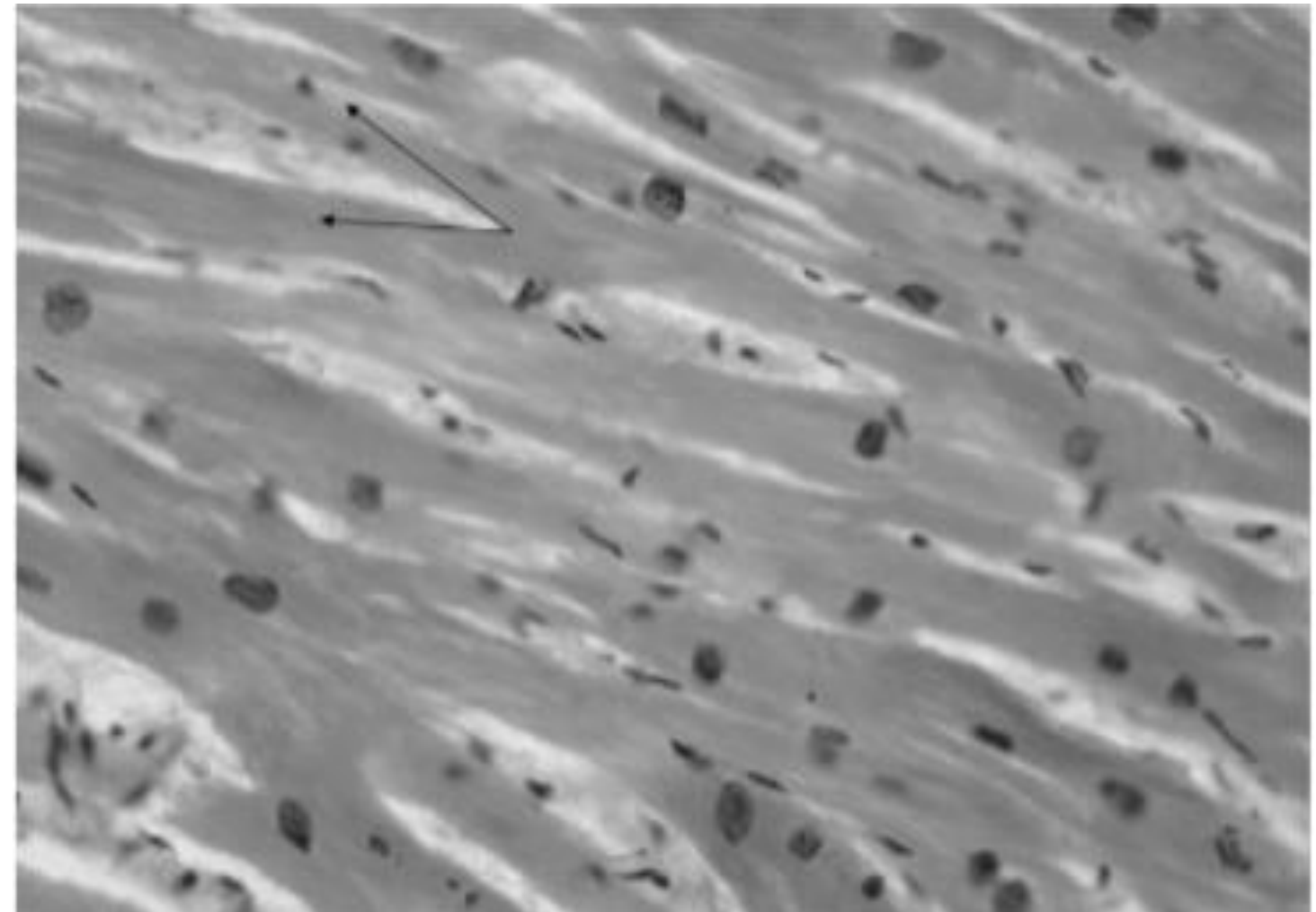
- A- Perimysium
- B- Myomysium
- C- Endomysium
- D- Nucleus of the muscle fiber
- E- Nucleus of the fibrocyte



Ans: c

Question : What is incorrect about this tissue :

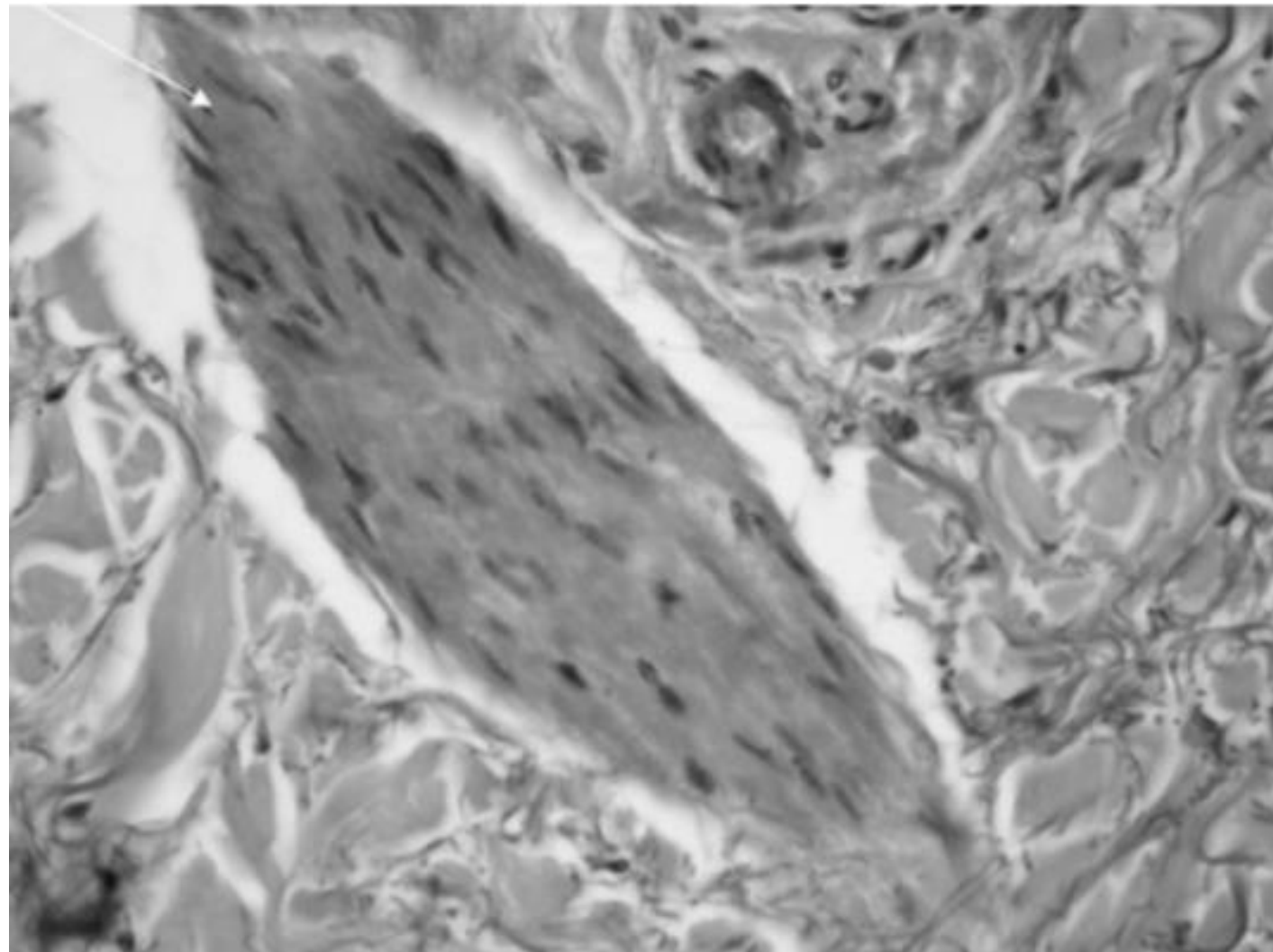
- A- Nucleus located centrally
- B- Involuntary muscles
- C- Contain gap junctions
- D- Uses glycogen as a major fuel
- E- Branched and striated



Ans: d

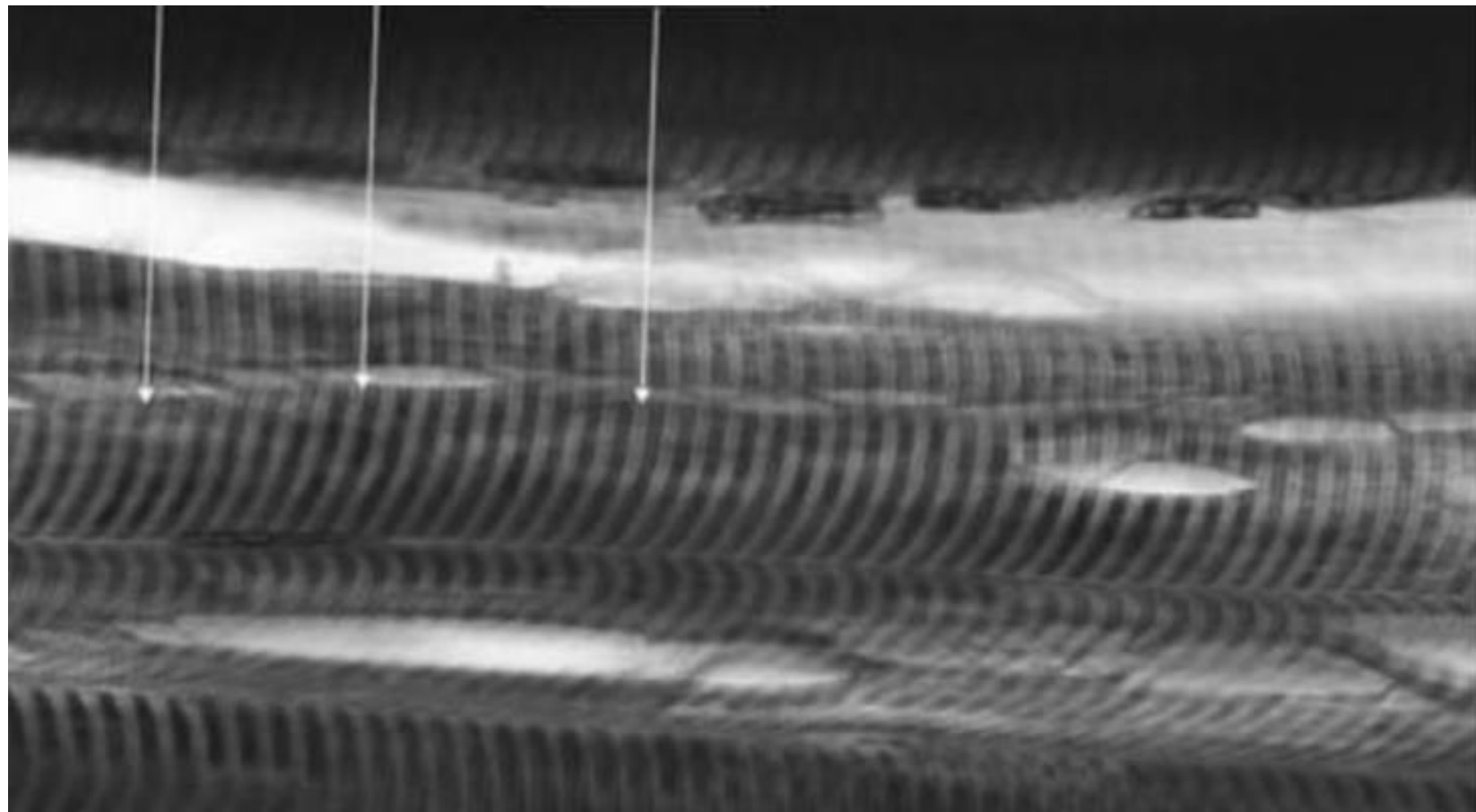
Question : What is correct about this tissue type :

- A- Voluntary
- B- Striated
- C- Branched
- D- Includes gap junctions
- E- Peripheral nucleus




Ans: d

Question : What is the type of the tissue in the following image and is it striated?



ANSWER: Skeletal muscle and yes it is striated

Question : What is the type of tissue in both cross section and longitudinal section in the following?



ANSWER: Skeletal muscle

Question : What does the oxytocin hormone regulate?

ANSWER: smooth muscle

Question : The origin of satellite cell in the skeletal muscle

- A. Mesoderm
- B. Endoderm
- C. Ectoderm
- D. Neural tube
- E. Neural crest

Ans: a

Question : which of the following is not a characteristic of SO:

- A) many mitochondria
- B) fatigue fast
- C) found in postural muscles

Question : Best regenerative capacity

- A) Cardiac
- B) skeletal
- C) smooth

Ans: c

Question : Which of the following is correct in regard to fast glycolytic fibers:

- A) have many mitochondria
- B) have many myoglobins
- C) fiber diameter is large

Question : The protein that binds Ca^{+2} in skeletal and cardiac muscles :

- A) Calmodulin
- B) Troponin
- C) tropomyosin

Question* : Thin filaments of human skeletal muscle, choose the CORRECT statement:

- A) Are attached to Z line by titin
- B) Present in the H zone
- C) Form the I band and extend into the A band
- D) Shorten during muscle contraction
- E) Are anisotropic

Ans: D

Question* : Cardiac muscle cells, choose the **WRONG** statement:

- A) Lack intermediate filaments
- B) Cardiac tissue lacks satellite cells
- C) Have adherens junctions
- D) Are not capable of extensive cell division in repairing damaged heart tissue
- E) Are electrically coupled to each other via gap junctions

Ans: A

Question* : Red fibers, choose the CORRECT statement:

- A) Can be differentiated from white fibers using H & E
- B) Are larger in diameter compared to white fibers
- C) Their glycolytic capacity is high
- D) Their oxidative capacity is high
- E) Their ATPase activity is high

Ans: D

Question* : Which of the following is present in all three types of muscle cells:

- A) Dense bodies
- B) Myosin
- C) A and I bands
- D) Troponin
- E) Intercalated discs

Ans: B

Question* : Muscle tissue, choose the CORRECT statement:

- A) Epimysium is a loose type of connective tissue
- B) Intracytoplasmatic dense bodies of smooth muscle cells functionally correspond to the M-lines of the other muscle types
- C) Skeletal muscle cells are not connected by gap junctions
- D) Intrafusar muscle fibers form the bulk of the skeletal muscle
- E) The motor unit may contain both red and white muscle fibers

Ans: C

Question* : In the A band of a sarcomere of voluntary muscle:

Q100

- A) There are only thick myofilaments
- B) The Z line is found
- C) There are no myofilaments
- D) The M line is found
- E) There are only thin myofilaments

Ans: D

Question* : Intercalated discs, choose the CORRECT statement:

Q101

- A) Produce cross striations of striated muscle cells
- B) Contain only two types of junctions
- C) Can be visualized easily when observing a longitudinal section of cardiac muscle cells
- D) Are found at every Z line
- E) Are characteristic of striated muscle cell

Ans: C

Question* : Sarcoplasmic reticulum, choose the CORRECT statement:

- A) Is associated with T-tubules in all muscle types
- B) Is more extensive in cardiac muscle cells compared to skeletal
- C) Is rudimentary on smooth muscle cells
- D) Forms diads on skeletal muscle cells
- E) None of the above

Ans: C

Question* : Cells of smooth muscles, choose the CORRECT statement:

- A) Have distinct sarcomeres
- B) Upon contraction they become globular
- C) Are controlled by somatic neurons
- D) Lack gap junctions
- E) Often branched

Ans: B

Question* : The T tubules, choose the WRONG statement:

- A) Lie perpendicular to the length of muscle cell
- B) Are larger in cardiac muscle cells
- C) Overlie the A-I junction in skeletal muscle cells
- D) Overlie the Z line in cardiac muscle cells
- E) Produce cross striations of striated muscle cells

Ans:E

Question* : Which of the following is true for mammalian skeletal muscle?

- (A) T tubules are located at the Z disk.
- (B) T tubules are absent.
- (C) Troponin is absent.
- (D) It possesses triads.
- (E) It possesses caveolae

Ans : D

Question* : Which of the following is true for smooth muscle?

- A) T tubules are located at the Z disk.
- B) It possesses dyads
- C) Caveolae store and release calcium ions.
- D) It possesses triads.
- E) T tubules are located at the A–I interface

Ans: C

Question* : Contraction in all types of muscle requires calcium ions. Which of the following muscle components can bind or sequester calcium ions?

- A) Rough endoplasmic reticulum
- B) Tropomyosin
- C) Troponin
- D) Active sites on actin
- E) Titin

Ans: C

Question* : Each smooth muscle cell

- (A) has triads associated with its contraction.
- (B) has dyads associated with its contraction.
- (C) possesses a single central nucleus.
- (D) is characterized by the absence of sarcolemmal

Ans: C

Question* : Thick filaments are anchored to Z disks by

- A) C protein.
- B) Nebulin.
- C) titin.
- D) myomesin.
- E) α -actinin

Ans: C

Question* : The endomysium is a connective tissue investment that surrounds

- (A) individual muscle fibers.
- (B) muscle fascicles.
- (C) individual myofibrils.
- (D) an entire muscle.
- (E) small bundles of muscle cells

Ans: A

Question* : Which of the following statements concerning triads in mammalian skeletal muscle is true?

- A) They are located in the Z disk.
- B) They consist of two terminal cisternae of the SR separated by a T tubule.
- C) They can be observed with the light microscope
- D) They are characterized by a T tubule that sequesters calcium ions.
- E) They consist of two T tubules separated by a central terminal cisterna.

Ans: B

Question* : Which one of the following statements concerning cardiac muscle cells is true?

- A) They are spindle shaped
- B) They require an external stimulus to undergo contraction.
- C) They are multinuclear cells.
- D) They are joined together end to end by intercalated disks.
- E) They possess numerous caveola

Question* : The basal lamina of a muscle fiber is part of which structure?

- A) Perimysium
- B) Epimysium.
- C) Fascia.
- D) Endomysium
- E) . Sarcoplasmic reticulum

Ans: D

Question* : With the transmission electron microscope skeletal muscle fibers can be seen to contain structures called triads. What do the two lateral components of a triad represent?

- A) Attachment sites for thick myofilaments
- B) Sites for calcium sequestration and release.
- C) Sites for impulse conduction into the fiber
- D) Sites for ATP production
- E) Sites for synthesis of proteins to be secreted outside the cell

Ans: B

Question* : Which characteristic is unique to cardiac muscle?

- A) Contain centrally located nuclei
- B) Striated
- C) Often branched
- D) Multinucleated
- E) Lack T-tubules

Ans: C

Question* : Which feature typifies T-tubules?

- A) Evaginations of the sarcoplasmic reticulum
- B) Sequester calcium during muscle relaxation, releasing it during contraction
- C) Carry depolarization to the muscle fiber interior
- D) Overlie the A-I junction in cardiac muscle cells
- E) Rich supply of acetylcholine receptors

Ans: C

Question* : In smooth muscle calcium released by the smooth ER initiates contraction by binding to what protein?

- A) Actin
- B) Calmodulin
- C) Desmin
- D) Myosin light chain kinase
- E) Tropomyosin

Ans: B

Question* : Which characteristic is unique to smooth muscle?

- A) T-tubules lie across Z lines
- B) Each thick filament is surrounded by six thin filaments
- C) Thin filaments attach to dense bodies
- D) Cells are multinucleated
- E) Cells have centrally located nuclei

Ans: C

Question* : In one type of muscle, numerous gap junctions, desmosomes, and adherents junctions are specifically localized in which structures?

- A) Myofilaments
- B) Dense bodies
- C) Sarcomeres
- D) Neuromuscular spindles
- E) Intercalated discs

Ans: E

Question* : A 66-year-old man who lives alone has a severe myocardial infarction and dies during the night. The medical examiner's office is called the following morning and describes the man's body as being in rigor mortis. This state of rigor mortis is due to which one of the following?

- A) Inhibition of Ca^{2+} leakage from the extracellular fluid and sarcoplasmic reticulum
- B) Enhanced retrieval of Ca^{2+} by the sarcoplasmic reticulum
- C) Failure to disengage tropomyosin and troponin from the myosin active sites
- D) Absence of ATP preventing detachment of the myosin heads from actin
- E) Increased lactic acid production

Ans: D

Question* : A 5-year-old boy sustains a small tear in his gastrocnemius muscle when he is involved in a bicycle accident. Regeneration of the muscle will occur through which of the following mechanisms?

- A) Dedifferentiation of muscle cells into myoblasts
- B) Differentiation of muscle satellite cells
- C) Fusion of damaged myofibers to form new myotubes
- D) Hyperplasia of existing muscle fibers
- E) Differentiation of fibroblasts to form myoblasts

Ans: B

Question* : A healthy 32-year-old man lifts weights regularly as part of his workout. In one of his biceps muscle fibers at rest, the length of the I band is $1.0\text{ }\mu\text{m}$ and the A band is $1.5\text{ }\mu\text{m}$. Contraction of that muscle fiber results in a 10% shortening of the length of the sarcomere. What is the length of the A band after the shortening produced by muscle

- A) $1.50\text{ }\mu\text{m}$
- B) $1.35\text{ }\mu\text{m}$
- C) $1.00\text{ }\mu\text{m}$
- D) $1.90\text{ }\mu\text{m}$
- E) $0.45\text{ }\mu\text{m}$

Ans: A

Question* : What is the basic rod-like striated muscle unit consisting of thick and thin filaments organized in sarcomeres called?

Q123

- A) Myofibril
- B) Sarcolemma
- C) Myocyte (muscle fiber)
- D) A band

Ans: A

Question* : Which of the following is the functional unit of skeletal muscle consisting of actin and myosin filaments between two neighboring Z discs?

- A) H zone
- B) Sacromere
- C) I band
- D) A band
- E) Sacrolemma

Ans: B

Question* : In the I band of a sarcomere of voluntary muscle:

Q125

- A) The Z line is found
- B) There are only thick myofilaments
- C) The M line is found
- D) There are overlapping thin and thick myofilaments
- E) There are no myofilaments

Ans: A

Question* : Which characteristic is unique to skeletal muscle cells compared to cardiac and smooth muscle cells?

- A) Often branched
- B) Multinucleated
- C) Contain centrally located nuclei
- D) Striated
- E) Lack T-tubules

Ans: B

Question* : Which structure is a layer of loose connective tissue that fills the space. between the individual muscle fibers?

- A) Epimysium
- B) Muscle fascicle
- C) fascia
- D) Perimysium
- E) Endomysium

Ans: E

Question* : The basal lamina of a muscle fiber is part of which structure?

- A) Perimysium
- B) Epimysium
- C) Fascia
- D) Endomysium
- E) Sarcoplasmic reticulum

Ans: D

Question* : What is the name of the central area the sarcomere containing myosin filaments and overlapping actin filaments?

- A) sacrolemma
- B) I band
- C) M line
- D) H zone
- E) A band

Ans: E

Question* : What is the myocytic cytoplasm containing large amounts of glycosomes called?

A) Myofibril

B) Sacroplasm

C) sacrolemma

Ans: B

Question* : With the transmission electron microscope skeletal muscle fibers can be seen to contain structures called triads. What do the two lateral components of a triad represent ?

- A) Attachment sites for thick myofilaments
- B) Sites for calcium sequestration and release
- C) Sites for impulse conduction into the fiber
- D) Sites for ATP production
- E) Sites for synthesis of proteins to be secreted outside the cell

Ans: B

Question* : The triad in skeletal muscle, choose the **WRONG** statement:

Q132

- A) Is visible by light microscopy
- B) Is found at the site of A-I band junction
- C) Includes two terminal cisternae of sarcoplasmic reticulum
- D) Includes part of T tubule
- E) Is involved in the process of initiating muscle contraction

Ans: a

Question* : White fibers, choose the CORRECT statement:

Q133

- A) Are smaller in diameter compared to red fibers
- B) Their oxidative capacity is high
- C) Can be differentiated from red fibers using H & E
- D) Their glycolytic capacity is high

Ans: D

Question* : In one type of muscle, numerous gap junctions, desmosomes, and adherents junctions are specifically localized in which structures?

Q134

- A) Myofilaments
- B) Dense bodies
- C) Sarcomeres
- D) Neuromuscular spindles
- E) Intercalated discs

Ans: e

Question* : Diads are usually seen in:

- A) Smooth muscles by electron microscope
- B) Cardiac muscles by electron microscope
- C) Cardiac muscles by light microscope
- D) Skeletal muscles by light microscope
- E) Skeletal muscles by electron microscope

Ans: B

Question* : In what way are cardiac muscles and skeletal muscles similar?

Q136

- A) Both have myogenic activity
- B) Both have tubular myofibrils
- C) Both are controlled by somatic nervous system
- D) Both are highly branched
- E) Both are connected by gap junctions

Ans: B

Question* : Thin filaments of human skeletal muscle, choose the CORRECT statement:

- A) Are attached to Z line by titin
- B) In a relaxed muscle, they completely overlap the myosin thick filaments
- C) Are anisotropic
- D) In a relaxed muscle, they present in the H zone of a sarcomere
- E) Are pulled by the thick filaments toward the center of the sarcomere during contraction

Question* : Which of the following types of fibers are fatigue prone motor units?

Q137

- A) Fast oxidative glycolytic fibers
- B) Slow twitch fibers
- C) Type 1 fibers
- D) Fast glycolytic fibers

Ans: D

Question* : Concerning Cardiac and Skeletal muscle, which statement is most accurate?

Q138

- A) Cardiac Myofibril nuclei are eccentrically located whereas skeletal myofibers nuclei are centrally placed.
- B) Skeletal muscle fibers exhibit more branching than cardiac muscle fibers
- C) The striations of cardiac muscle cells are more distinct than that of skeletal muscles
- D) Cardiac muscle contains structures known as intercalated discs while skeletal muscle does not

Ans: D

Question* : Cells of smooth muscles. choose the CORRECT statement:

- A) Lack intermediate filaments
- B) Lack gap junctions
- C) Their sarcolemma contains caveolae
- D) Have no myofilaments
- E) Have distinct sarcomeres

Ans: C

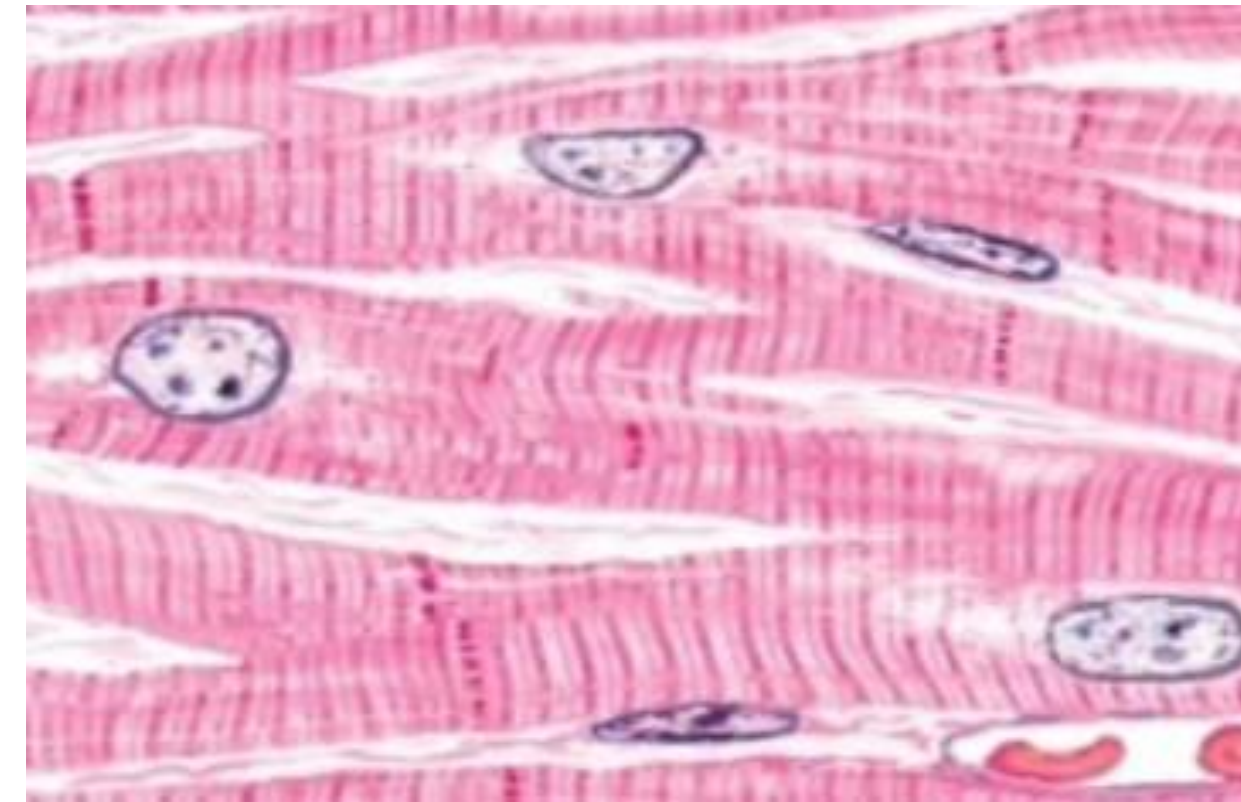
Question* : Which of the following is present in all three types of muscle

- A) Tropoaln
- B) Intracytoplasmic dense bodies
- C) Myofibrils
- D) Caveolae
- E) Myofilaments

Ans: E

Question* : identify this histological section:

- A) Longitudinal section of skeletal muscle cells
- B) Cross section of cardiac muscle cells
- C) Longitudinal section of smooth muscle cells
- D) Cross section of skeletal muscle cells
- E) Longitudinal section of cardiac muscle cells



Ans: E

الحمد لله

اللهم لك الحمد حتى ترضى، ولك الحمد إذا رضيت، ولك الحمد بعد الرضا. اللهم اجعل ما درستُه حجةً لي لا عليّ، وانفعني بما علمتني، وبارك لي في وقتي وجهدي، واجعل علمي طريقاً لرضاك وخدمة عبادك، اللهم ارزقني التوفيق والسداد فيما بقي، ووفقني لما تحب وترضى.

For any feedback, scan the code or click on it.



Corrections from previous versions:

Versions	Question # and Place of Error	Before Correction	After Correction
V0 → V1			
V1 → V2			

رسالة من الفريق العلمي:

سُورَةُ النَّجْمِ

بِسْمِ اللَّهِ الرَّحْمَنِ الرَّحِيمِ

وَأَن لَّيْسَ لِلْإِنسَانِ إِلَّا مَا سَعَى ﴿٢٩﴾